

A New Classification for Idiopathic Genu Vara

Sun Young Joo,¹ Hui Wan Park,¹ Kun Bo Park,² Bom Soo Kim,¹ Jin Soo Park,¹ and Hyun Woo Kim^{1,3}

¹Department of Orthopaedic Surgery, Yonsei University College of Medicine, Seoul; ²Department of Orthopaedic Surgery, Hallym University College of Medicine, Anyang; ³BK21 Research Team of Nanobiomaterials for the Cell-based Implants, Seoul, Korea.

Purpose: Past classification for the treatment of idiopathic genu vara depended simply on the measurement of distance between the knees, without attention to the rotational profile of the lower extremity. We retrospectively analyzed anatomical causes of idiopathic genu vara. **Patients and Methods:** Twenty eight patients with idiopathic genu vara were included in this study. All patients were surgically treated. To evaluate the angular deformity, a standing orthoroentgenogram was taken and the lateral distal femoral angle and the medial proximal tibial angle were measured. In order to assess any accompanying torsional deformity, both femoral anteversion and tibial external rotation were measured using computerized tomographic scans. A derotational osteotomy was performed at the femur or tibia to correct rotational deformity, and a correctional osteotomy was performed at the tibia to correct angular deformity. **Results:** Satisfactory functional results were obtained in all cases. Genu vara was divided into 3 groups according to the nature of the deformity; group 1 (6 patients) with increased femoral anteversion, group 2 (10 patients) with proximal tibial varus deformity alone, and group 3 (12 patients) with proximal tibial varus deformity accompanied by increased external tibial rotation. **Conclusion:** The success seen in our cases highlights the importance of an accurate preoperative analysis that accounts for both rotational and angular deformities that may underlie idiopathic genu vara.

Key Words: Classification, idiopathic genu vara

INTRODUCTION

Most pediatric genu vara is physiologic in nature and resolve spontaneously without any intervention. Accordingly, an accurate knowledge

of the natural history of this angular deformity allows us to avoid unnecessary treatments.^{1,2} However, for those cases of idiopathic genu vara seen in children ages 8 and older, little further spontaneous correction has been known to be expected, and any specific treatment guidelines can not be found in past literatures. Traditionally, when the medial malleoli of the ankle are placed in contact and the distance between the knees is less than 5 cm, a treatment program of skillful neglect and stretching exercises is recommended. If the distance is greater than 7.5 cm, surgery is usually indicated.^{1,3} However, this treatment recommendation was based on the degree of the deformity seen in coronal plane alone. We analyzed the actual anatomical causes of idiopathic genu vara, not only considering the coronal plane but also the rotational profiles of the lower extremity. Hereby, we tried to propose a new classification system for idiopathic genu vara according to actual underlying causes, which may enable us to select a more appropriate surgical treatment.

PATIENTS AND METHODS

From 1991 to 1999, twenty-eight patients received surgical treatment for an idiopathic genu vara. The distance between the knees with feet put together in standing was greater than 7.5 cm in all patients and there were no angular deformities in the hip or ankle joints as evidenced by plain radiographs. Eleven patients were male and 17 were female. The mean age at the time of the operation was 21 years (range, 8 to 31 years), and the mean follow-up period was 3 years

Received November 13, 2006
Accepted March 9, 2007

Reprint address: requests to Dr. Hyun Woo Kim, Department of Orthopaedic Surgery, Yonsei University College of Medicine, 250 Seongsanno, Seodaemun-gu, Seoul 120-752, Korea. Tel: 82-2-2228-2187, Fax: 82-2-363-1139, E-mail: pedhkim@yuhs.ac

(range, 1 to 7 years). To evaluate the angular deformities, an anteroposterior orthoroentgenogram with the patella pointing straight forward were obtained. The lateral distal femoral angle (LDFA, normal range: 85 to 90 degrees) and the medial proximal tibial angle (MPTA, normal range 85 to 90 degrees) were measured (Fig. 1).⁴ To determine any accompanying torsional deformities of the lower extremity, femoral anteversion (normal range, less than 25 degrees at the age of 8 or older for both male and female) was measured using dual CT scanning technique as follows; the long axis of the femoral neck was plotted against the transcondylar plane, which was taken as the line which bisects the two lines tangential to the anterior and posterior aspects of the femoral condyles. External tibial rotation (normal range, less than 20 degrees at the age of 8 or older for both male and female) also was measured using dual CT scanning technique namely, the long axis connecting medial and lateral malleoli of the distal tibia was plotted against the transcondylar plane of the proximal tibia, which was taken as the line which bisects the two lines tangential to the anterior and posterior aspects of the tibial condyles.^{1,5-8}

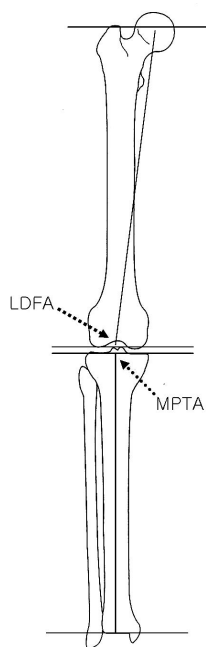


Fig. 1. Frontal plane joint orientation angle relative to the mechanical axis. LDFA, lateral distal femoral angle; MPTA, medial proximal tibial angle.

All operations were performed by a single surgeon. All parameters were measured by 1st, 3rd, 4th, and 5th authors, respectively and averaged. In cases with increased femoral anteversion, a derotational osteotomy was performed at the intertrochanteric or supracondylar level followed by internal fixation with plating or percutaneous pinning with additional casting. Although a femoral derotational osteotomy can be done at any level by the surgeon's preference, the operating surgeon in this paper did a supracondylar osteotomy in an attempt to correct accompanied genu recurvatum as needed. In cases with increased external tibial rotation, a derotational osteotomy was performed at the distal tibia with or without fibular osteotomy in order to prevent any potential neurovascular complications resulting from the operation performed at the tibial tubercle area. Fixation was achieved with percutaneous pinning and casting.⁶ To correct angular deformity at the proximal tibia, a correctional osteotomy was performed, followed by progressive correction using an Ilizarov external fixation apparatus.⁴ In cases where the proximal tibial varus deformity was accompanied by increased external tibial rotation, a derotational osteotomy was performed at the distal tibia and external fixation at the proximal tibia was achieved with an Ilizarov external fixation apparatus. Criteria for functional results after surgery as presented by Meister and James⁹ were modified and applied in the evaluation of postoperative results (Table 1). In the evaluation of post-operative cosmetic outcomes, three grades were used; 1) satisfactory and recommendable, 2) satisfactory except for postoperative scars, and 3) unsatisfactory.

RESULTS

Our cases of idiopathic genu vara were divided into 3 groups according to actual anatomical causes of their deformity: group 1 (6 patients) with increased femoral anteversion (Fig 2), group 2 (10 patients) with a proximal tibial varus deformity alone (Fig. 3), and group 3 (12 patients) with a proximal tibial varus deformity accompanied by increased external tibial rotation (Fig. 4). Patients with increased femoral anteversion had a

Table 1. Criteria for Functional Results after Surgery

	Definition
Excellent	Minimal or no pain, and no limitation of all physical activities
Good	Occasional pain, and some limitation of vigorous sports activities
Fair	Pain with minimal activities such as prolonged periods of walking
Poor	Pain during rest pain, and limitation of daily activities

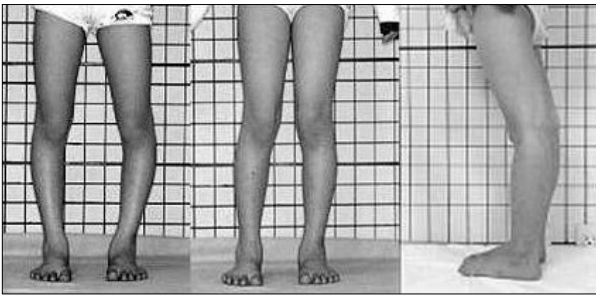


Fig. 2. A 9-year-old boy in Group 1. Inwardly pointing patellar due to increased femoral anteversion assumes apparent genu vara. When the patellar point was forward, normal alignment of the lower extremity ensued. Genu recurvatum was also frequent in this group.

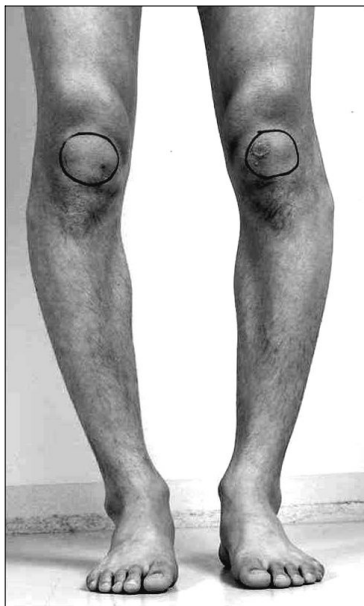


Fig. 3. A 21-year-old patient in Group 2. When the patellar point was forward, tibia vara ensued.

tendency to visit clinic at earlier ages with a mean age of 9 years. Patients in groups 2 and 3 visited clinic at the average ages of 26 and 17, respectively.

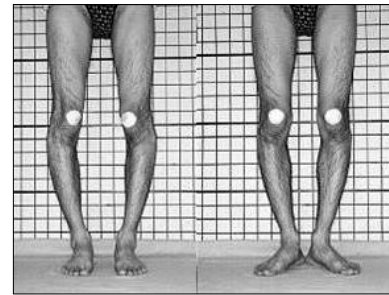


Fig. 4. An 18-year-old patient in Group 3. When the patellar point was forward, tibia vara and increased external rotation of the tibia ensued.

In addition, all patients in group 1 also showed variable degrees of genu recurvatum.

In group 1, the mean preoperative femoral anteversion was 49 degrees (range, 44 to 53 degrees) and the mean tibial external rotation was 17 degrees (range, 13 to 30 degrees). Derotational osteotomies were performed at the intertrochanteric level in 2 cases, and at the supracondylar level of distal femur for 4 cases. Overall an average of 35 degrees of rotational correction was achieved (Table 2).

In group 2, correction of proximal tibial varus deformity was achieved by tibial osteotomy followed by a progressive angular correction using Ilizarov external fixation apparatus. The mean 81 degrees (range, 80 to 85 degrees) of preoperative MPTA was increased to 88 degrees (range, 85 to 89 degrees) postoperatively (Table 2).

In group 3, the mean preoperative femoral anteversion was 20 degrees (range, 17 to 23 degrees) and the mean tibial external rotation was 47 degrees (range, 35 to 60 degrees). After derotational osteotomies at the distal tibia and fibula, an average of 30 degrees of rotational correction was achieved. For correction of a proximal tibial varus deformity, a correctional osteotomy was performed,

Table 2. Preoperative and Postoperative Radiographic Measurements

	Group 1 (n = 6)	Group 2 (n = 10)	Group 3 (n=12)
FA (preop./postop.)	49 (44 - 53) / 15 (14 - 20)	19 (10 - 21) / 19 (10 - 21)	20 (17 - 23) / 20 (17 - 23)
TER (preop./postop.)	17 (13 - 30) / 17 (13 - 30)	18 (16 - 24) / 18 (16 - 24)	47 (35 - 60) / 18 (10 - 28)
MPTA (preop./postop.)	86 (85 - 89) / 87 (85 - 89)	81 (80 - 85) / 88 (85 - 89)	79 (77 - 83) / 89 (87 - 95)
LDFA (preop.)	87 (86 - 89)	87 (86 - 88)	87 (86 - 88)

FA, angle of femoral anteversion; TER, angle of tibial external rotation; MPTA, medial proximal tibial angle; LDFA, lateral distal femoral angle; Preop., preoperative measurement; Postop., postoperative measurement.

followed by a progressive correction using an Ilizarov external fixation apparatus. An average preoperative MPTA of 81 degrees (range, 80 to 85 degrees) was increased to 88 degrees (range, 85 to 89 degrees) postoperatively (Table 2).

Bony union was achieved after a mean of 8 weeks of cast immobilization after derotational tibial or femoral osteotomy. The Ilizarov external fixation apparatus was removed after a mean of 3.5 months postoperatively, followed by 3 weeks of additional cast immobilization, which was discarded after confirming complete bony union. Postoperative complications were as follows: there were 2 cases of delayed union which were treated with autologous bone marrow injection, and 3 cases of partial loss of correction after removal of the external fixation device, which were eventually treated with repeat correctional osteotomy and monolateral external fixation. One case of temporary peroneal nerve palsy due to intraoperative irritation of the nerve by an Ilizarov pin remitted after reinsertion of the pin and conservative treatment. As regards to the functional results after surgery, 27 were excellent and 1 was good. No patients showed fair or poor results in function. However, six patients were not satisfied with postoperative scars.

DISCUSSION

Most genu vara in children is known to correct spontaneously during the course of normal development and achieve normal adult alignment at the age of 7 years. Any residual genu varum after this age, without any underlying diseases, is called "idiopathic genu vara".⁷ However, there

have not been an accurate definition of idiopathic genu vara and it is just regarded as having genu vara when the medial malleoli of the ankle are placed in contact and the distance between the knees is more than 5.0 cm. According to the current study, idiopathic genu vara can be classified into three groups depending on actual anatomical causes of the deformity: those with increased femoral anteversion, those with a proximal tibial varus deformity alone, and those with a proximal tibial varus deformity accompanied by increased tibial torsion.

All patients with idiopathic genu vara without any deformity at the tibia had markedly increased femoral anteversion with genu recurvatum. The effect of this increased femoral anteversion on the lower extremity or on clinical problems in adults is controversial.¹⁰⁻¹⁴ According to Alvik et al.¹⁵ and Eckhoff et al.,¹⁶ increased femoral anteversion causes internal rotation of the femur in order to make the hip abductor muscles function more effectively, followed by internal rotation of the knee joint during movement and consequent loosening of the posterolateral aspect of the knee joint capsule. These rotational problems can be accompanied by compensatory pes planovalgus or tibial external rotational deformities, and can also cause problems in the patellofemoral joint.⁵ Staheli et al.⁷ recommended surgical correction for persistent and severe deformity with more than 45 degrees of anteversion and more than 80 degrees of medial hip rotation in children only after the age of 8 years.

In cases with increased tibial torsion or with a thigh-foot angle greater than 40 degrees, an excellent functional and cosmetic result can be achieved with surgical correction. Meister and

James⁹ reported good results after derotational osteotomy of the tibia performed proximal to the tibial tubercle in patients with anterior knee pain and greater than 40 degrees of external rotation of the tibia. Cooke et al.¹⁷ also achieved a satisfactory result by valgus and derotational osteotomy of the proximal tibia in patients with excessive varus angulation of the tibia accompanied by external tibial torsion. We also achieved good and satisfactory results by correcting rotational deformity at the distal tibia and varus deformity at the proximal tibia, in an effort to avoid any neurovascular complication.^{2,6,18} Shtarker et al.² and Svenningsen et al.¹⁹ reported many complications after femoral and tibial derotational osteotomies. We experienced complications in 6 cases (21%), including 3 cases of partial loss of correction after removal of the external fixation device before complete union had been achieved at the osteotomy site.

According to James,²⁰ greater than 10 degrees of varus deformity at the proximal tibia causes the foot to remain pronated position in order to increase the contact surface area of the sole, which also can induce pain in the patellofemoral joint. Increased external rotation at the distal tibia produces an out-toeing gait. If the patient tries to walk straight, it can produce increasing rotational movement at the lower leg as well as shear force on the knee joint followed by possible pain and an increased Q angle.²¹ Therefore, correction of tibial varus alone is not sufficient in such cases, and concurrent correction of the tibial external rotation is necessary.

The limitation of this study is that it is a retrospective study, only including the patients who received surgical treatments. Therefore, we could not revise the indications of surgery nor could we propose a treatment guideline according to severity of the disease. However, rather than simply selecting a treatment plan according to the distance between the knees, this study suggested that treatment should be guided by an evaluation of the rotational profiles of the lower extremities as well.

In conclusion, when considering surgical intervention for idiopathic genu vara, differentiation of the exact anatomical position of the actual deformity is required. It is essential to know whether the problem is due to a proximal tibial varus

alone and whether there is any accompanying rotational deformity of the femur or tibia. By assessing the actual causes and then performing an appropriate surgery, a satisfactory functional result might be obtained.

REFERENCES

1. Kling TF Jr, Hensinger RN. Angular and torsional deformities of the lower limbs in children. *Clin Orthop Relat Res* 1983;176:136-47.
2. Shtarker H, Volpin G, Stolero J, Kaushansky A, Samchukov M. Correction of combined angular and rotational deformities by the Ilizarov method. *Clin Orthop Relat Res* 2002;402:184-95.
3. Delgado ED, Schoenecker PL, Rich MM, Capelli AM. Treatment of severe torsional malalignment syndrome. *J Pediatr Orthop* 1996;16:484-8.
4. Paley D, Herzenberg JE, Tetsworth K, McKie J, Bhav A. Deformity planning for frontal and sagittal plane corrective osteotomies. *Orthop Clin North Am* 1994;25:425-65.
5. Fabry G, MacEwen GD, Shands AR Jr. Torsion of the femur. A follow-up study in normal and abnormal conditions. *J Bone Joint Surg Am* 1973;55:1726-38.
6. Krengel WF 3rd, Staheli LT. Tibial rotational osteotomy for idiopathic torsion. A comparison of the proximal and distal osteotomy levels. *Clin Orthop Relat Res* 1992;283:285-9.
7. Staheli LT. Rotational problems in children. *Instr Course Lect* 1994;43:199-209.
8. Visser JD, Jonkers A, Hillen B. Hip joint measurements with computerized tomography. *J Pediatr Orthop* 1982;2:143-6.
9. Meister K, James SL. Proximal tibial derotation osteotomy for anterior knee pain in the miserably malaligned extremity. *Am J Orthop* 1995;24:149-55.
10. Halpern AA, Tanner J, Rinsky L. Does persistent fetal femoral anteversion contribute to osteoarthritis?: a preliminary report. *Clin Orthop Relat Res* 1979;145:213-6.
11. Heller MO, Bergmann G, Deuretzbacher G, Claes L, Haas NP, Duda GN. Influence of femoral anteversion on proximal femoral loading: measurement and simulation in four patients. *Clinical Biomech (Bristol, Avon)* 2001;16:644-9.
12. Kitaoka HB, Weiner DS, Cook AJ, Hoyt WA Jr, Askew MJ. Relationship between femoral anteversion and osteoarthritis of the hip. *J Pediatr Orthop* 1989;9:396-404.
13. Turner MS, Smillie IS. The effect of tibial torsion on the pathology of the knee. *J Bone Joint Surg Br* 1981;63:396-8.
14. Wedge JH, Munkacsy I, Loback D. Anteversion of the femur and idiopathic osteoarthritis of the hip. *J Bone Joint Surg Am* 1989;71:1040-3.

15. Alvik I. Increased anteversion of the femur as the only manifestation of dysplasia of the hip. *Clin Orthop* 1962;22:16-20.
16. Eckhoff DG, Kramer RC, Alongi CA, VanGerven DP. Femoral anteversion and arthritis of the knee. *J Pediatr Orthop* 1994;14:608-10.
17. Cooke TD, Price N, Fisher B, Hedden D. The inwardly pointing knee. An unrecognized problem of external rotational malalignment. *Clin Orthop Relat Res* 1990; 260:56-60.
18. Herzenberg JE, Smith JD, Paley D. Correcting torsional deformities with Ilizarov's apparatus. *Clin Orthop Relat Res* 1994;302:36-41.
19. Svenningsen S, Apalset K, Terjesen T, Anda S. Osteotomy for femoral anteversion. Complications in 95 children. *Acta Orthop Scand* 1989;60:401-5.
20. James SL. Chondromalacia of the patella in the adolescent. In: Kennedy JC, editor. *The injured Adolescent Knee*. Baltimore: Williams & Wilkins; 1979. p.205-51.
21. Lee TQ, Anzel SH, Bennett KA, Pang D, Kim WC. The influence of fixed rotational deformities of the femur on the patellofemoral contact pressures in human cadaver knees. *Clin Orthop Relat Res* 1994;302:69-74.