

# Expression and role of estrogen receptor $\alpha$ and $\beta$ in medullary thyroid carcinoma: different roles in cancer growth and apoptosis

Mi Ae Cho<sup>1,2,3</sup>, Mi Kyung Lee<sup>4</sup>, Kee-Hyun Nam<sup>2,3,5</sup>, Woung Youn Chung<sup>2,3,5</sup>, Cheong Soo Park<sup>2,3,5</sup>, Ju Hyeong Lee<sup>1,2,3</sup>, Taewoong Noh<sup>1,2,3</sup>, Woo Ick Yang<sup>6</sup>, Yumie Rhee<sup>1,2,3</sup>, Sung-Kil Lim<sup>1,2,3</sup>, Hyun Chul Lee<sup>1,2,3</sup> and Eun Jig Lee<sup>1,2,3,7,8</sup>

<sup>1</sup>Division of Endocrinology, <sup>2</sup>Thyroid Cancer Clinic and <sup>3</sup>Research Institute of Endocrinology, Yonsei University College of Medicine, Seoul, South Korea

<sup>4</sup>Department of Pathology, National Health Insurance Corporation, Ilsan Hospital, Koyang, South Korea

<sup>5</sup>Department of Surgery, <sup>6</sup>Department of Pathology and <sup>7</sup>Center for Chronic Metabolic Disease Research, Yonsei University College of Medicine, Seoul, South Korea

<sup>8</sup>Endocrinology, Metabolism, and Molecular Medicine, Feinberg School of Medicine, Northwestern University, Chicago, Illinois 60611, USA

(Correspondence should be addressed to E J Lee at Division of Endocrinology, Yonsei University College of Medicine, 262 Seongsanno Seodaemun-gu, Seoul 120-752, South Korea; Email: ejlee423@yuhs.ac)

## Abstract

Medullary thyroid carcinoma (MTC) originates from parafollicular C cells. Estrogen receptor  $\beta$  (ER $\beta$ ) expression was detected in normal parafollicular C cells and MTC tumor tissue, but ER $\alpha$  expression in MTC tumors still remains undetermined. The appearance and loss of ER $\alpha$  or ER $\beta$  expression has been known to play a role in the development and progression of many human cancers. We performed immunohistochemical studies of ER $\alpha$ , ER $\beta$ , and Ki67, a mitotic index, in 11 human MTC tissue samples. ER $\alpha$  was detected in 10 cases (91%), and ER $\beta$  expression was observed in 8 cases (72.7%). A majority (8/10) of ER $\alpha$ -positive tumors showing ER $\beta$  Ki67 expression was detected in three cases (27.3%). Neither clinical parameters nor tumor node metastasis (TNM) tumor staging was correlated with the positivity for ERs or Ki67. To investigate the biological role of each ER, we used ER-negative MTC TT cells and adenoviral vectors carrying ER $\alpha$  (Ad-ER $\alpha$ ), ER $\beta$  (Ad-ER $\beta$ ),

estrogen response element (ERE)-Luc (Ad-ERE-Luc), and activator protein 1 (AP1)-Luc (Ad-AP1-Luc). Estrogen stimulated and anti-estrogen, ICI 182 780, suppressed ERE reporter activity in TT cells expressing ER $\alpha$  or ER $\beta$ , suggesting that both ERs use the same classical ERE-mediated pathway. Ad-ER $\alpha$  infection stimulated TT cell growth; in contrast, Ad-ER $\beta$  infection suppressed their growth. Apoptosis was detected in Ad-ER $\beta$ -infected TT cells. Estrogen and anti-estrogen suppressed AP1 activity in Ad-ER $\alpha$ -infected cells, whereas upon Ad-ER $\beta$  infection estrogen further stimulated AP1 activity which in turn is suppressed by anti-estrogen, suggesting that each ER acts differently through a non-ERE-mediated pathway. Our results suggest that ER $\alpha$  and ER $\beta$  may play different roles in MTC tumor growth and progression.

*Journal of Endocrinology* (2007) **195**, 255–263

## Introduction

Medullary thyroid carcinoma (MTC), which comprises 3–10% of all carcinomas in the thyroid gland, may be either sporadic or familial. Sex ratio is 1:1 with no difference between sporadic and familial MTC (Kebebew *et al.* 2000*a,b*). The familial form is part of the multiple endocrine neoplasia type 2 (MENII) syndrome. MTC arises from the parafollicular C cells of the thyroid gland. Metastases to distant sites including lungs, liver, and bone usually occur early. Therefore, any form of effective therapy with curative intent must be systemic (Messina *et al.* 2000). The primary form of treatment for MTC is total thyroidectomy, but recurrent and metastatic diseases are difficult to manage. Although many patients live with a recurrent or residual tumor for up to a decade, the case fatality rate is ultimately 30–50% over 10

years (Marsh *et al.* 1995). Because MTC responds poorly to both chemotherapy and radiotherapy, targeted therapy through cancer-specific signaling may offer an alternative approach (Petrangolini *et al.* 2006).

Parafollicular C cells secrete a polypeptide hormone, calcitonin. Previously, it has been demonstrated that calcitonin gene expression is elevated in response to estrogen, suggesting the presence of an estrogen receptor (ER; Naveh-Manly *et al.* 1992). Immunohistochemical studies using monoclonal antibody revealed that ER $\beta$ , but not ER $\alpha$ , was detected in normal human thyroid follicular and parafollicular C cells (Taylor & Al-Azzawi 2000). More recently, a study showed that ER $\beta$  was expressed in most of the MTC tissues (Blechet *et al.* 2007). However, immunohistochemistry results (Bur *et al.* 1993, Hiasa *et al.* 1993, Yane *et al.* 1993, Colomer *et al.* 1996, Lewy-Trenda 2002, Arain *et al.* 2003, Blechet *et al.* 2007)

demonstrating ER $\alpha$  expression in thyroid tumors including follicular adenoma or carcinoma, papillary carcinoma, medullary carcinoma, and anaplastic carcinoma remain controversial depending on the antibody source.

Thyroid cancer is more prevalent in women than men, and thyroid cancer incidence decreases after menopause (Cady *et al.* 1979). These facts suggest a possible involvement of estrogens in the carcinogenesis and progression of thyroid cancer. Demonstration of ER $\alpha$  protein (Lee *et al.* 1998) and ER $\alpha$  mRNA (Yane *et al.* 1994) in the normal and malignant tissues of the thyroid seems to further support the hypothesis that there is a direct action of estrogens on the thyroid tissues and tumors. Estrogen has long been known to promote the growth of certain human neoplasms, notably tumors of the breast, endometrium, and pituitary. In contrast, ER $\beta$  appears to play a different role in carcinogenesis. Many reports have shown that a loss of ER $\beta$  expression is associated with the progression of normal prostate epithelium into prostate cancers (Latil *et al.* 2001, Leav *et al.* 2001, Fixemer *et al.* 2003). A similar down-regulation in ER $\beta$  expression is also noted in ovarian, breast, or colon tumors (Pujol *et al.* 1998, Roger *et al.* 2001).

The expression of ERs or their biological role in the MTC remains unclear. In this study, we investigated the ERs expression in human MTC tissues and examined the role of ERs using ER-negative MTC TT cells after expression of ERs by adenoviral vectors.

## Materials and Methods

### *Subjects and immunohistochemistry of human MTC tumor*

Eleven patients (five men and six women, mean age 48 years) with MTC were included in this study. Ten patients had sporadic MTC and one had MENIIa presenting as bilateral MTC. The diagnosis of an MTC was established by the measurement of serum calcitonin and carcino embryonic antigen (CEA), and confirmed in all cases by positive immunohistochemical staining of tumor tissue for calcitonin (10 cases), CEA (11 cases), or chromogranin-A (10 cases). One patient (case 5) with negative for calcitonin and chromogranin-A had elevated serum CEA and immunohistochemical positivity for CEA. Every MTC were poorly differentiated under light microscopic examination. Metastatic cervical lymph nodes were identified in seven patients (63.6%) and distant metastasis occurred in two patients (16.6%). The study design and protocol was approved by the Internal Review Board of Severance Hospital, Yonsei University College of Medicine.

To detect ER $\alpha$  or ER $\beta$  in MTC tumors, 4  $\mu$ m sections of tumor in paraffin blocks were prepared. After deparaffinization, slides were placed in a jar containing 10 mM sodium citrate buffer (pH 6.0), exposed to microwave radiation (1000 W) for 15 min, and cooled to room temperature. After preincubation with serum blocking solution, slides were incubated with mouse

monoclonal anti-human ER $\alpha$  (1:50, sc-8002, Santa Cruz Biotechnology Inc., Santa Cruz, CA, USA specific to C-terminal human ER $\alpha$ ) or ER $\beta$  (1:50, NCL-ER $\beta$ , Novocastra, specific to C-terminal human ER $\beta$ ) respectively, overnight in a cold room. After washing with Tris-buffered saline (TBS)/0.025% Tween, staining was performed by biotinylated horse anti-mouse secondary antibodies (5  $\mu$ g/ml, Vector Laboratories, Burlingame, CA, USA), streptavidin-horseradish peroxidase (RTU, Vector), and diaminobenzidine (DAB; DAKO). The concentration of each antibody was titrated using positive and negative control breast cancer tissues to minimize non-specific staining. Counterstaining was performed by malachite green. To investigate a possible correlation of the presence of ERs with a cell proliferative index, Ki67 immunohistochemistry was also performed by mouse monoclonal antibody (1:50, DAKO, Fort Collins, CO, USA). Images were obtained using a Zeiss microscope (Axioskop, Carl Zeiss Inc., Oberkochen, Germany).

### *Recombinant adenoviral vectors*

Adenoviral vectors carrying the human ER $\alpha$  (Ad-ER $\alpha$ ) and ER $\beta$  (Ad-ER $\beta$ ) were described previously (Cheng *et al.* 2004). E1-deleted adenoviral vector (Ad-E) was used as a negative control. Adenoviral reporter vectors, Ad-3ERE-Luc and Ad-AP1-Luc, were created to investigate transcriptional activity of the ER $\alpha$  or ER $\beta$  delivered by adenoviral vectors. The sequence containing three consensus estrogen response elements (3 ERE) and minimal TATA promoter was generated by oligonucleotide annealing and ligated to the pGL3-basic plasmid (Promega). A portion of the resulting plasmid containing the upstream synthetic p(A) signal, 3 ERE, a minimal TATA promoter, the firefly luciferase gene, and the downstream SV40 p(A) signal was subcloned into an adenoviral transfer plasmid. The resulting plasmid, pC-3ERE-Luc, was used to generate Ad-3ERE-Luc. Similarly, Ad-AP1-Luc was generated from pC-AP1-Luc, in which the sequence containing seven AP1 sites was switched with three ERE sequences in pC-3ERE-Luc. The sequences of the expression cassettes in the adenoviral vectors were confirmed by automated DNA sequencing.

### *Cell culture and infection with recombinant adenoviruses*

TT cells were obtained from the American Type Culture Collection (Rockville, MD, USA) and maintained in Dulbecco's modified Eagle's medium (DMEM)/F12+10% FBS supplemented with 100 units/ml penicillin and 100  $\mu$ g/ml streptomycin and were incubated at 37 °C and 5% CO<sub>2</sub>.

For infection with adenoviral vectors, cells were first depleted of estrogen for 3 days using phenol red-free DMEM/F12 containing 5% dextran/charcoal-stripped FBS. Transduction efficiency of the adenoviral vectors in cell lines was tested using AdGal.  $\beta$ -galactosidase expression was detected in 95–100% of TT cells at 48 h after infection with AdGal at a multiplicity of infection (MOI) of 10

plaque-forming units (PFU) per cell (data not shown). Therefore, subsequent experiments were performed by similar amounts (10 or 20 PFU/cell) of recombinant adenoviral vectors.

The transcriptional activities of ER $\alpha$  or ER $\beta$  were assayed using an artificial estrogen-responsive reporter (Ad-3ERE-luc) or AP1 reporter (Ad-AP1-luc) in a viral vector (Lee *et al.* 2001). Briefly, 12-well plates of TT cells were infected for 5 h with 10 PFU/cell Ad-3ERE-Luc or Ad-AP1-Luc with Ad-ER $\alpha$  or Ad-ER $\beta$ . Fresh medium containing ethanol vehicle, 17 $\beta$ -estradiol (E<sub>2</sub>, 1 nM, Sigma), or ICI 182 780 (100 nM, Tocris, Ellisville, MO, USA), a specific estrogen antagonist, was added; incubation continued for 24 h; and luciferase activity was assayed.

#### Detection of ERs expression using immunofluorescence and western blot analysis

TT cells on glass slides 48 h after infection with adenoviral vectors were fixed in ice-cold methanol for 10 min and permeabilized with 0.4% Triton-X 100 in PBS for 20 min on ice. After blocking with 10% horse serum for 30 min, specimens were incubated with mouse monoclonal anti-human ER $\alpha$  or ER $\beta$  for 1 h at room temperature. After washing with TBS + 0.025% Tween, specimens were incubated with biotinylated horse anti-mouse secondary antibodies (5  $\mu$ g/ml, Vector Laboratories) for 30 min. Streptavidin-fluorescein isothiocyanate (FITC) (1:100, Vector) and Streptavidin-Texas-Red (1:100, Vector) were used for the detection of ER $\alpha$  and ER $\beta$  respectively. Cell images were analyzed using a Zeiss microscope (Axioskop, Carl Zeiss Inc).

Infected TT Cells in 10 cm culture dishes at a density of 5  $\times 10^6$  cells/dish were washed twice with PBS, and whole cell lysates were prepared with lysis buffer (25% glycerol, 0.5 M NaCl, 1.5 mM MgCl<sub>2</sub>, 20 mM HEPES (pH 7.9), 1 mM

phenylmethylsulfonyl fluoride, 0.2 mM EDTA, 25 mM NaF, and protease inhibitor cocktail tablets (Roche Molecular Biochemicals)). Equal amounts of protein (10  $\mu$ g) were resolved by SDS-PAGE on 10% gel and transferred to nitrocellulose paper. ER $\alpha$  or ER $\beta$  was detected using the antibodies as described above.

#### The effect of ERs on TT cell growth

The effect of ER $\alpha$  or ER $\beta$  on TT cell growth was measured with a non-radioactive cell proliferation assay according to the manufacturer's protocol (Cell Titer 96 Aqueous Non-Radioactive Cell Proliferation Assay, Promega). Cells were seeded onto 96-well plates at a density of 8  $\times 10^3$  cells/well and infected the following day with adenoviral vectors at different MOIs (10 and 20 PFU/cell). Medium containing ethanol vehicle, E<sub>2</sub> (1 nM), or ICI 182 780 (100 nM) was replaced at 5 h after infection and every two days thereafter. Octaplicate wells were assayed for viable cell density at day 8. Relative density was calculated as absorbance at 490 nm divided by that of the Ad-E-infected, 0 nM E<sub>2</sub>-treated cells, and expressed as a percentage (mean  $\pm$  s.d.).

#### Terminal deoxynucleotidyltransferase (TdT)-mediated UTP end labeling (TUNEL) assay

TT cells were infected with adenoviral vectors (10 PFU/cell), treated with 1 nM E<sub>2</sub> for 6 days, and then washed twice with PBS and mounted on glass slides. Cells were fixed for 30 min in 4% paraformaldehyde and permeabilized with buffer containing 0.1% sodium acetate and 0.4% Triton X-100 for 10 min on ice. After washing with PBS, a modified TUNEL was performed by the *In Situ* Cell Death Detection Kit, Fluorescein (Boehringer Mannheim Co). TUNEL-positive

**Table 1** Summary of clinical and pathologic characteristics of patients with medullary thyroid carcinoma

| Number | Sex | TNM (staging) | Duration of follow-up (years) | Age at diagnosis | Plasma level       |             | Immunohistochemistry |            |      |
|--------|-----|---------------|-------------------------------|------------------|--------------------|-------------|----------------------|------------|------|
|        |     |               |                               |                  | Calcitonin (pg/ml) | CEA (ng/ml) | ER $\alpha$          | ER $\beta$ | Ki67 |
| 1      | M   | T2N1b M0(IVA) | 13 (A)                        | 32               | 320                | 27.1        | —                    | —          | —    |
| 2      | M   | T2N1a M0(III) | 7 (A)                         | 35               | 156                | 2.3         | +                    | +          | —    |
| 3      | F   | T2N1a M0(III) | 8 (A)                         | 58               | 459.6              | 2.55        | ++                   | —          | —    |
| 4      | F   | T3N0 M0(II)   | 7 (A)                         | 29               | 6.33               | 0.6         | +++                  | +++        | —    |
| 5      | M   | T2N0M0(II)    | 9 (A)                         | 38               | ND                 | 360.3       | +++                  | +++        | +    |
| 6      | F   | T2N1M1(IVC)   | 7 (A)                         | 53               | ND                 | ND          | +++                  | +++        | +    |
| 7      | F   | T2N1b M0(IVA) | 6 (A)                         | 66               | 75.1               | 11.3        | ++                   | +          | —    |
| 8      | M   | T4aN1aM1(IVA) | 1 (L)                         | 36               | 1623               | 65          | +                    | —          | —    |
| 9      | F   | T3N1 M0(III)  | 2 (L)                         | 55               | 2474               | 2.34        | +++                  | +++        | +    |
| 10     | F   | T2N0M0(II)    | 4 (A)                         | 69               | ND                 | ND          | ++                   | +          | —    |
| 11     | M   | T2N0M0(II)    | 1 (L)                         | 63               | ND                 | 1.88        | +++                  | ++++       | —    |

A, alive; L, lost to follow-up; ND, not done. Normal range: calcitonin, male: <90 pg/ml; female: <70 pg/ml; CEA, 0–2.5 ng/ml. Immunohistochemistry score according to the percentage of positive cells: —, negative; +, 5–15%; ++, 15–40%; +++, 40–60%; +++++, >60%.

cells were counted in ten different fields ( $\times 200$ ) and positivity was calculated.

### Statistical analysis

Values are expressed as mean  $\pm$  S.D. Data analysis was performed by the Statistics Package for Social Sciences (SPSS system for Windows 12.0, SPSS Inc., Chicago, IL, USA). Differences between groups were analyzed using Student's *t*-test, and  $P < 0.05$  was considered statistically significant.

## Results

### Expression of ERs in human MTC tumor

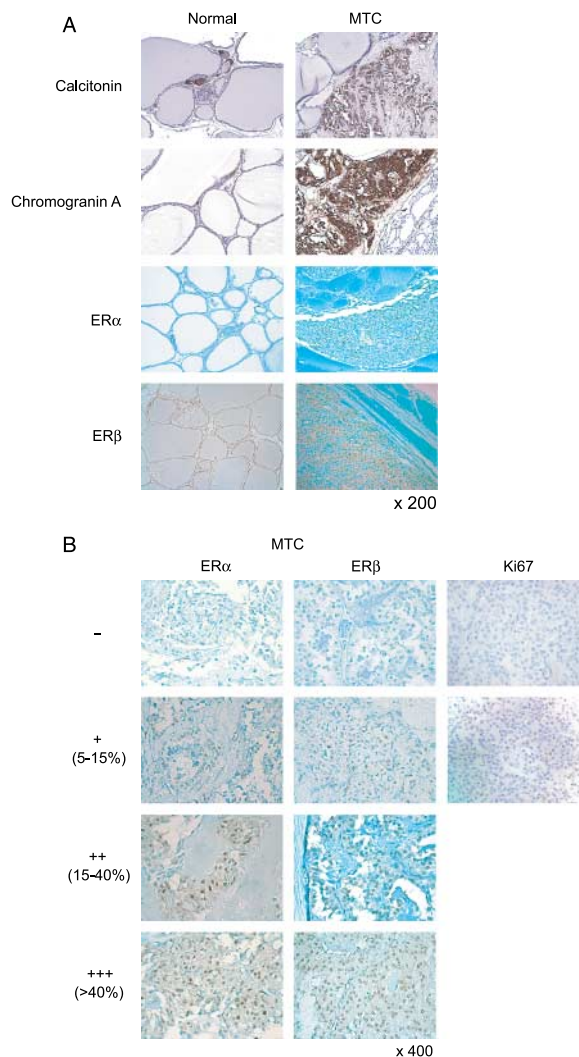
ER $\alpha$  was detected in 10 out of 11 (90.9%) tumors. Five tumor samples exhibited higher (50% cells positive) levels of ER $\alpha$  expression. ER $\beta$  was absent in three (27.3%) tumors. Eight tumor samples were positive for ER $\beta$ , and five of them exhibited higher (>40% cells positive) levels of ER $\beta$  positivity. The one without ER $\alpha$  also did not have ER $\beta$  expression. Five tumors with higher ER $\alpha$  expression also had higher ER $\beta$  expression, and three of these were also positive for Ki67 positivity. There was no difference in ER $\alpha$  and ER $\beta$  expression according to gender, TNM tumor staging, or survival (Table 1). Positivity for ERs or Ki67 was not correlated with serum levels of calcitonin and CEA. We also performed immunohistochemical staining of ERs in normal human thyroid tissue as a control and found ER $\beta$  expression in parafollicular C cells and thyrocytes. ER $\beta$  expression was also detected in parafollicular C cells and thyrocytes surrounding the tumors. However, we did not detect ER $\alpha$  in normal thyrocytes or parafollicular C cells from either normal thyroid gland or normal thyroid tissues adjacent to the tumors (Fig. 1A).

### Expression of ERs in TT cells infected with adenoviral vectors

First, we examined the presence of ER $\alpha$  or ER $\beta$  in MTC TT cells by immunofluorescence staining and western blot analysis. ERs were not detected in TT cells (data not shown). Secondly, we infected TT cells with Ad-ER $\alpha$  or Ad-ER $\beta$ . Ad-E-infected cells served as a negative control. The expression of ER $\alpha$  or ER $\beta$  was detected by immunofluorescence in the nuclei of TT cells infected with Ad-ER $\alpha$  or Ad-ER $\beta$ , but not in cells infected with Ad-E (Fig. 2A and B). The ER expression was detected in 85–95% of TT cells infected with 10 PFU/cell of adenoviral vectors (Fig. 2A and B). Then, further experiments were performed by equivalent amount of adenoviral vectors.

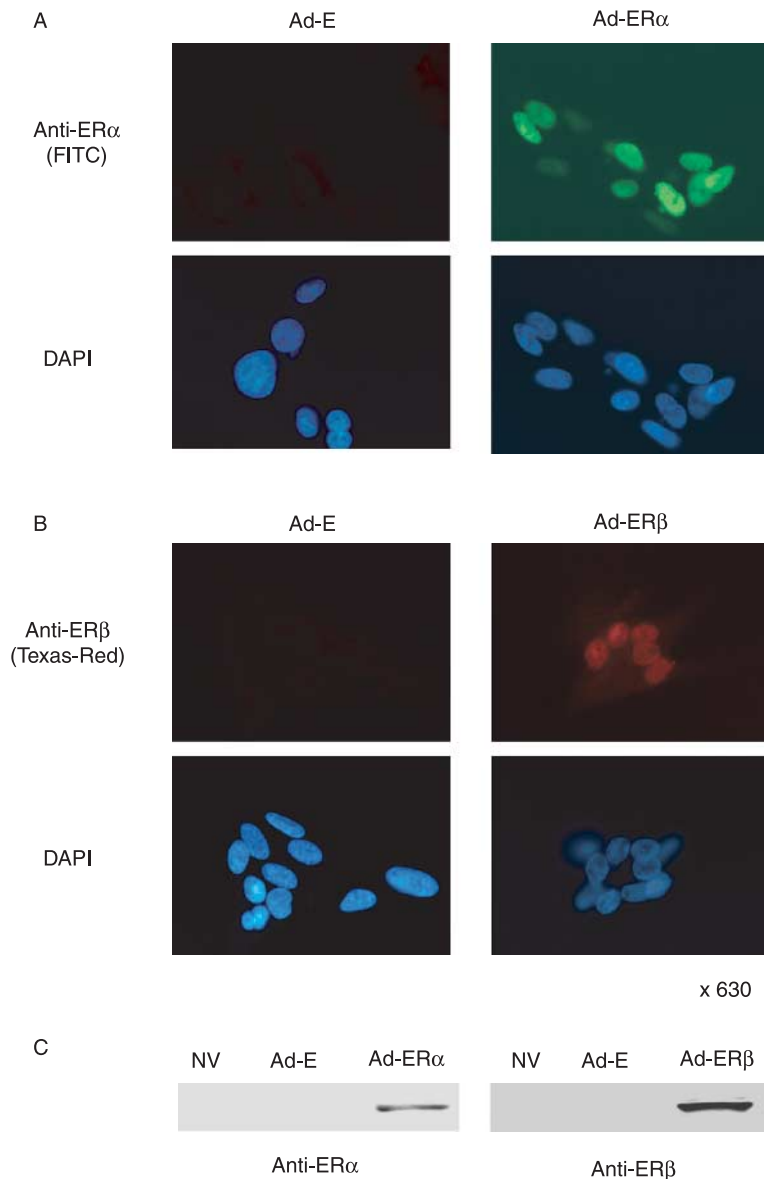
### Transcriptional activity of ERs delivered by adenoviral vectors

We evaluated whether expression of ERs delivered by adenoviral vectors activates an estrogen-responsive reporter gene, by co-infecting Ad-3ERE-Luc into TT cells with



**Figure 1** Immunohistochemical staining of normal thyroid and MTC tumor tissues. Four micrometer sections of paraffin-embedded tumors were subjected to immunohistochemistry to detect calcitonin, chromogranin-A, ER $\alpha$ , ER $\beta$ , and Ki67 using specific antibodies as described in the Materials and Methods section. Red arrow indicates positivity. (A) Photographs of representative samples ( $\times 200$ ). (B) Immunohistochemical positivity for ER $\alpha$ , ER $\beta$ , and Ki67 was scored according to the number of positive cells: -, negative; +, 5–15%; ++, 15–40%; + + +, 40–60%; + + + +, >60% ( $\times 400$ ).

Ad-ER $\alpha$  or Ad-ER $\beta$ . As shown in Fig. 3, ERE reporter gene activity was not detected with or without E<sub>2</sub> in control Ad-E-infected cells. Infection with Ad-ER $\alpha$  or Ad-ER $\beta$  increased reporter activity without ligand, presumably due to residual estrogen in the medium. E<sub>2</sub> (1 nM) addition activated reporter activity by ten- and fivefold in Ad-ER $\alpha$ - and Ad-ER $\beta$ -infected cells respectively. ICI 182 780, an anti-estrogen treatment, suppressed reporter activities. These results suggested that expression of ER $\alpha$  or ER $\beta$  delivered by adenoviral vectors is functionally active in the ERE



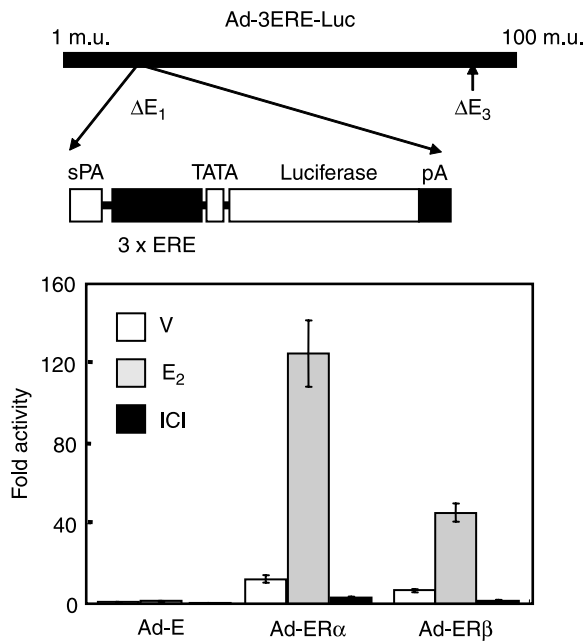
**Figure 2** Expression of ER $\alpha$  or ER $\beta$  in TT cells after infection with Ad-ER $\alpha$  or Ad-ER $\beta$ . Forty-eight hours after adenoviral infection, immunofluorescence staining (A and B) and western blot analysis (C) were performed by mouse monoclonal antibodies as described in the Materials and Methods section ( $\times 630$ ). NV, no virus.

reporter system and that both ERs act similarly in the classical ERE-mediated pathway in TT cells.

#### *Effect of ER $\alpha$ or ER $\beta$ on TT cell growth*

To investigate whether the introduction of ER $\alpha$  or ER $\beta$  in TT cells affects cell growth, we analyzed the proliferation of TT cells infected with two different doses (10 and 20 PFU/cell) of adenoviral vectors. Ten PFU/cell of Ad-ER $\alpha$  stimulated TT cell growth without E<sub>2</sub> treatment, and the

treatment with E<sub>2</sub> (1 nM) for 8 days stimulated cell growth further. With a higher dose (20 PFU/cell) of Ad-ER $\alpha$ , growth stimulation was observed in the E<sub>2</sub> treatment. Ad-ER $\beta$  infection resulted in the suppression of TT cell growth regardless of E<sub>2</sub> treatment. Growth suppression was more prominent with a higher dose (20 PFU/cell) of Ad-ER $\beta$ . ICI 182 780 treatment suppressed the growth of TT cell infected with either Ad-ER $\alpha$  or Ad-ER $\beta$ , and growth suppression was more prominent in Ad-ER $\beta$  than Ad-ER $\alpha$  infection (Fig. 4). A positive TUNEL reaction was



**Figure 3** Transcriptional activity of ERs transduced by adenoviral vectors on artificial ERE reporter system. Ad-3ERE-Luc was co-infected into TT cells with Ad-ER $\alpha$  or Ad-ER $\beta$  and Luciferase activity was assayed as described in the Materials and Methods section. Three independent experiments were normalized to the activity of Ad-E-infected TT cells treated with ethanol vehicle. Results are plotted as mean  $\pm$  s.d. V, vehicle (ethanol); E<sub>2</sub>, E<sub>2</sub> (1 nM); ICI, ICI 182 780 (100 nM).

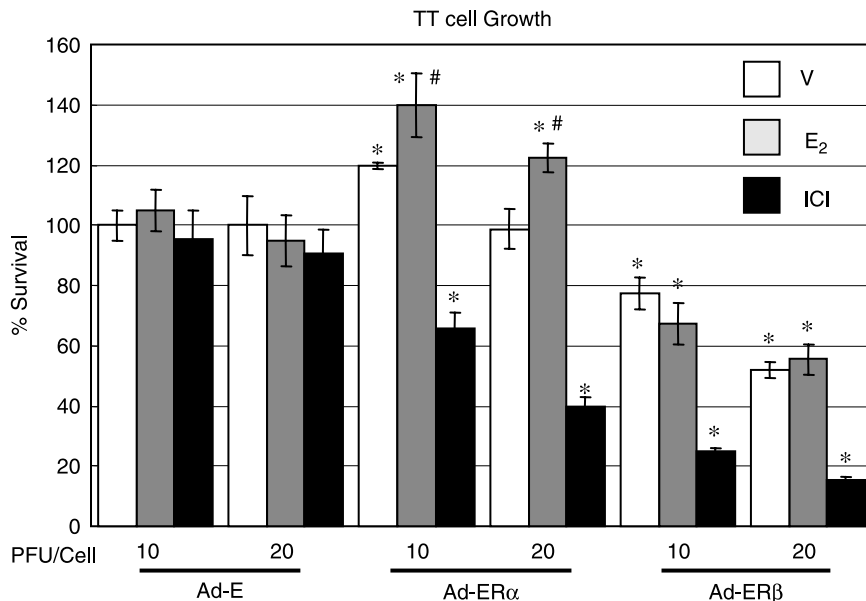
obtained in Ad-ER $\beta$  infection (19.8%), whereas positivity was negligible in Ad-ER $\alpha$ -infected (3.2%) or Ad-E-infected (<1%) cells (Fig. 5).

#### Effect of ERs on AP1 pathway in TT cells

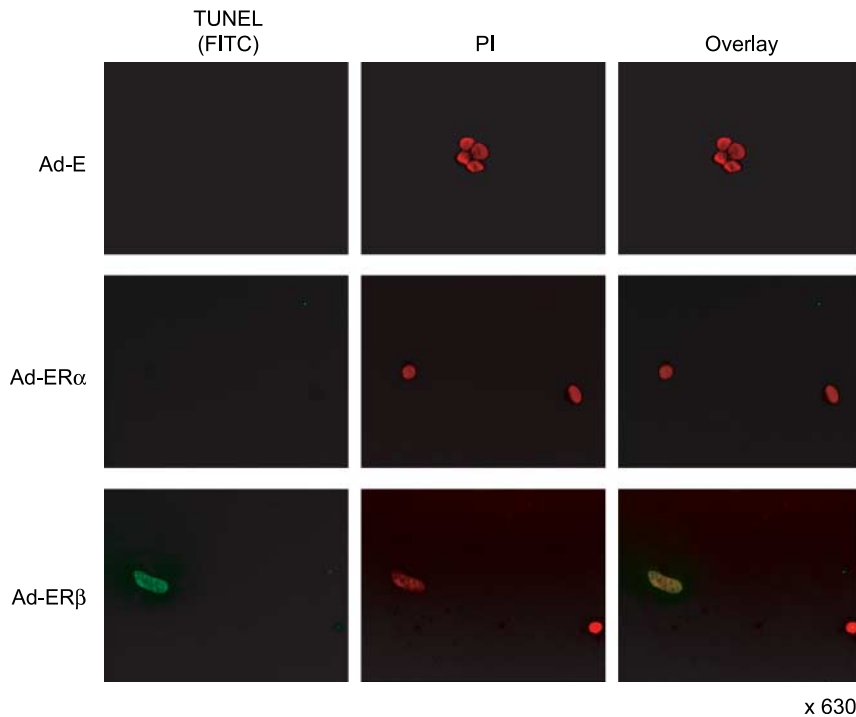
To investigate the possible mechanisms of different effects of ER $\alpha$  or ER $\beta$  expression on TT cell growth, we evaluated a non-ERE-mediated pathway in TT cells using the AP1 reporter system (Paech *et al.* 1997). Co-infection of Ad-AP1-Luc into TT cells with Ad-ER $\alpha$  or Ad-ER $\beta$  was performed. As shown in Fig. 6, AP1 reporter gene activity was negligible in control Ad-E-infected cells. Infection with Ad-ER $\alpha$  or Ad-ER $\beta$  increased AP1 reporter activity without ligand. After the addition of E<sub>2</sub>, AP1 activity was decreased in Ad-ER $\alpha$ -infected cells, but increased in Ad-ER $\beta$ -infected cells. ICI 182 780 treatment decreased AP1 activity in both Ad-ER $\alpha$ - or Ad-ER $\beta$ -infected cells, but its activity was higher in Ad-ER $\beta$ -infected cells than those infected with Ad-ER $\alpha$ . These results suggest that non-ERE-mediated signals are distinct in TT cells expressing ER $\alpha$  or ER $\beta$  and could also explain the different effects on cellular growth and proliferation.

## Discussion

Previously, ER $\beta$  expression has been reported in normal thyroid parafollicular C cells (Taylor & Al-Azzawi 2000) and MTC tumor tissues (Blechet *et al.* 2007). The presence of



**Figure 4** The effect of ER $\alpha$  or ER $\beta$  expression on TT cell growth. Cells were plated, infected, and treated as described in the Materials and Methods section. After treatment for 8 days with E<sub>2</sub> or ICI 182 780, cell growth was determined by cell proliferation assay as described in the Materials and Methods section. All results are plotted as mean  $\pm$  s.d. for three independent experiments. Student's *t*-test was performed between values. \**P* < 0.05 when compared with corresponding condition in Ad-E infection and #*P* < 0.05 when compared with the condition without E<sub>2</sub> treatment in Ad-ER $\alpha$  infection. V, vehicle (ethanol); E<sub>2</sub>, E<sub>2</sub> (1 nM); ICI, ICI 182 780 (100 nM).



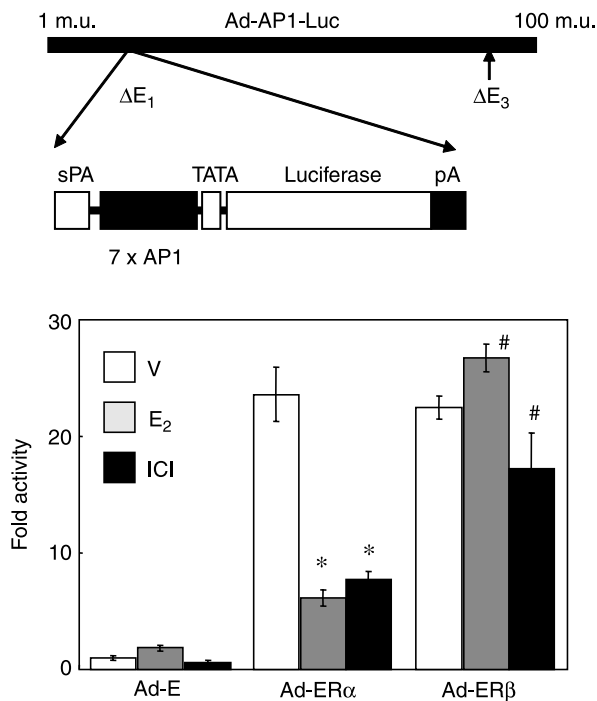
**Figure 5** The effect of ER $\alpha$  or ER $\beta$  on TT cell apoptosis. TT cells were infected with adenoviral vectors at an MOI of 10 PFU/cell. After 6 days of treatment with E<sub>2</sub> (1 nM), TUNEL assays were performed. Green fluorescence indicates TUNEL labeling ( $\times 630$ ).

mRNA for ER $\alpha$  and ER $\beta$  has also been demonstrated in the human MTC tumor tissues (Egawa *et al.* 2001). However, the role of each ER expression is not well defined after cancerous change. In this study, we have shown an appearance of ER $\alpha$  (10/11) and a loss of ER $\beta$  expression (3/11) in the human MTC tissue samples. It has been well demonstrated that expression of ER $\beta$  mRNA and protein decreased or ER $\alpha$ /ER $\beta$  mRNA ratio increased in tumor versus normal tissues in many cancers including breast, ovary, prostate, and colon (Brandenberger *et al.* 1998, Foley *et al.* 2000, Rutherford *et al.* 2000, Campbell-Thompson *et al.* 2001, Roger *et al.* 2001, Fixemer *et al.* 2003, Bardin *et al.* 2004). Consistent with these reports, appearance of ER $\alpha$  and loss of ER $\beta$  in MTC tumor tissue in our study may result in the increased ratio of ER $\alpha$ /ER $\beta$ , suggesting a possible role in tumor growth and progression. Although Ki67, a mitotic index, was detected in both ER $\alpha$ - and ER $\beta$ -positive tumors, its expression did not correlate with ER $\alpha$  and ER $\beta$  expression because these three Ki67-positive tumors had similar levels of both ER $\alpha$  and ER $\beta$ . In addition, the expression of ERs did not correlate with cervical lymphadenopathy or distant metastasis (TNM staging), suggesting other signals (Wang *et al.* 1997, Mustafa *et al.* 2004), besides ERs, are involved in tumor growth and progression. Of note is that the number of MTC cases in our study was also limited.

The presence of ER $\alpha$  expression could also open the possibility of using anti-estrogenic compounds for the treatment

of MTC. In one report, tamoxifen inhibited the growth of medullary carcinoma DR081 cells in an *in vitro* culture and *in vivo* tumor cell xenograft implants (Weber *et al.* 1990). In another report, tamoxifen treatment failed to show clinical or biochemical improvement of two MTC patients (one man and one woman) after 1–3 months of therapy (Garcia-Pascual *et al.* 1993). The presence of ERs was not identified in either of these reports. It has been suggested that ER $\beta$  is significantly up-regulated in tamoxifen-resistant breast cells and could be involved in tamoxifen resistance (Speirs *et al.* 1999a,b). Although ER $\beta$  was still detected in most ER $\alpha$ -expressing MTC tumor tissues in our study, tamoxifen could be a potential therapeutic agent for the treatment of MTC. The effect of this reagent could be evaluated through therapeutic trial as an adjuvant treatment in both genders (Garcia-Pascual *et al.* 1993).

To examine the roles of ER $\alpha$  and ER $\beta$  in MTC, we used adenovirus-mediated expression of each ER in MTC TT cells devoid of both endogenous receptors. We observed that both ER $\alpha$  and ER $\beta$  expressed by adenoviral vector were functional in TT cells, resulting in the activation of ERE-mediated gene transcription in a reporter assay. However, we obtained opposing cellular responses with regard to proliferation and apoptosis. ER $\alpha$  acted as a growth stimulator with estrogen addition, whereas ER $\beta$  suppressed cell growth regardless of estrogen treatment in this study. We also investigated whether the different effects of each ER on TT cell growth could be reversed by ICI 162,780, an anti-estrogen, but ICI 162,780



**Figure 6** Effect of ERs transduced by adenoviral vectors on an artificial AP1 reporter system. Ad-AP1-Luc was co-infected into TT cells with Ad-ER $\alpha$  or Ad-ER $\beta$  and Luciferase activity was assayed as described in the Materials and Methods section. Three independent experiments were normalized to the activity of Ad-E-infected TT cells treated with ethanol vehicle. Results are plotted as mean  $\pm$  s.d. \* $P$  < 0.01 when compared with the condition with vehicle treatment in Ad-ER $\alpha$  infection and # $P$  < 0.05 when compared with the condition with vehicle treatment in Ad-ER $\beta$  infection. V, vehicle (ethanol); E<sub>2</sub>, E<sub>2</sub> (1 nM); ICI, ICI 182 780 (100 nM).

suppressed the growth of TT cells expressing either ER $\alpha$  or ER $\beta$ . Growth suppression was more prominent in Ad-ER $\beta$ -infected cells. This result suggests the presence of other pathways besides the classical ERE-mediated pathway.

The ER has been known to regulate target genes by at least two major pathways. The classical pathway for ER signaling is mediated by receptor binding to EREs. This mode of ER action has been documented for many genes involved in reproduction as well as genes involved in cellular growth and metabolism (Jakacka *et al.* 2001, 2002). In addition to this classical pathway of estrogen action, the ER can also alter gene transcription by a mechanism that does not require direct ER binding to an ERE. This non-classical pathway affects gene expression from promoters containing an AP1 site (Paech *et al.* 1997, Jakacka *et al.* 2001, O'Brien *et al.* 2006). We tested this possibility using AP1-Luc, the representative non-ERE-mediated reporter system (Paech *et al.* 1997). Adenovirus carrying AP1 Luc (Ad-AP1-luc) was created and co-infected into TT cells with Ad-ER $\alpha$  or Ad-ER $\beta$ . The effect of estrogen and anti-estrogen on AP1-reporter in TT cells was distinct according to ER $\alpha$  or ER $\beta$  expression. Estrogen and anti-estrogen treatment suppressed AP1 activity in Ad-ER $\alpha$ -infected cells, whereas

alongside Ad-ER $\beta$  infection, estrogen further stimulated AP1 activity which in turn is suppressed by anti-estrogen. Suppressed AP1 activity by ICI 182 780 was still higher in ER $\beta$  than ER $\alpha$  expression. This result indicates that signals other than the classical ERE-mediated pathway might regulate genes including apoptotic factors and negative cell cycle regulators. Genes responsible for regulating the different actions by ER $\alpha$  or ER $\beta$  still remain to be determined in these TT cell models.

A series of studies revealed that the ER $\beta$  presence confers a more favorable prognosis and is also associated with low-grade tumors, low S-phase fraction, negative axillary node status, and a higher disease-free survival rate (Jarvinen *et al.* 2000, Omoto *et al.* 2001). In addition, exogenously expressing ER $\beta$  not only inhibits proliferation and invasion but also induces apoptosis in many cancer cells (Lazennec *et al.* 2001, Qiu *et al.* 2002, Cheng *et al.* 2004, Paruthiyil *et al.* 2004). Repression of *c-myc*, *cyclin D1*, and *cyclin A* gene transcription and increasing the expression of *p21Cip1* and *p27Kip1* were demonstrated by ER $\beta$  expression (Paruthiyil *et al.* 2004). These result in a G2 cell cycle arrest. The activation of caspase-3 has also been demonstrated in ER-negative prostate cancer cells, in which ER $\beta$  was reintroduced by adenoviral vector (Cheng *et al.* 2004). Although we did not find an association between ER $\beta$  expression and tumor behavior in human MTC tumor samples, an anti-tumor effect of ER $\beta$  expression was observed in the TT cell line. These results indicate a potential anti-neoplastic role of ER $\beta$ , which is in good agreement with previous studies (Lazennec *et al.* 2001, Qiu *et al.* 2002, Cheng *et al.* 2004, Paruthiyil *et al.* 2004), and also suggest different roles of ER $\alpha$  and ER $\beta$  in MTC tumor growth. New therapeutic approaches for MTC might include pharmaceutical agents to block ER activity and gene therapy by delivery of ER $\beta$ .

## Acknowledgements

We thank Su-Il Ji for tissue preparation. This work was supported by the Internal Medicine Research Grant 2006–2007 from the Yonsei University College of Medicine and a New Faculty Grant (2007) from the Yonsei University. The authors declare that there is no conflict of interest that would prejudice the impartiality of this scientific work.

## References

- Arain SA, Shah MH, Meo SA & Jamal Q 2003 Estrogen receptors in human thyroid gland. An immunohistochemical study. *Saudi Medical Journal* **24** 174–178.
- Bardin A, Bouille N, Lazennec G, Vignon F & Pujol P 2004 Loss of ERbeta expression as a common step in estrogen-dependent tumor progression. *Endocrine-Related Cancer* **11** 537–551.
- Blechet C, Lecomte P, De Calan L, Beutter P & Guyétant S 2007 Expression of sex steroid hormone receptors in C cell hyperplasia and medullary thyroid carcinoma. *Virchows Archiv* **450** 433–439.
- Brandenberger AW, Tee MK & Jaffe RB 1998 Estrogen receptor alpha (ER-alpha) and beta (ER-beta) mRNAs in normal ovary, ovarian serous cystadenocarcinoma and ovarian cancer cell lines: down-regulation of ER-beta in neoplastic tissues. *Journal of Clinical Endocrinology and Metabolism* **83** 1025–1028.
- Bur M, Shiraki W & Masood S 1993 Estrogen and progesterone receptor detection in neoplastic and non-neoplastic thyroid tissues. *Modern Pathology* **6** 469–472.



- Cady B, Sedgwick CE, Meissner WA, Wool MS, Salzman FA & Werber J 1979 Risk factor analysis in differentiated thyroid cancer. *Cancer* **43** 810–820.
- Campbell-Thompson M, Lynch IJ & Bhardwaj B 2001 Expression of estrogen receptor (ER) subtypes and ERbeta isoforms in colon cancer. *Cancer Research* **61** 632–640.
- Cheng J, Lee EJ, Madison LD & Lazennec G 2004 Expression of estrogen receptor beta in prostate carcinoma cells inhibits invasion and proliferation and triggers apoptosis. *FEBS Letters* **566** 169–172.
- Colomer A, Martinez-Mas JV, Matias-Guiu X, Llorens A, Cabezas R, Prat J & Garcia-Ameijeiras A 1996 Sex-steroid hormone receptors in human medullary thyroid carcinoma. *Modern Pathology* **9** 68–72.
- Egawa C, Miyoshi Y, Iwao K, Shiba E & Noguchi S 2001 Quantitative analysis of estrogen receptor-alpha and -beta messenger RNA expression in normal and malignant thyroid tissues by real-time polymerase chain reaction. *Oncology* **61** 293–298.
- Fixemer T, Remberger K & Bonkhoff H 2003 Differential expression of the estrogen receptor beta (ERbeta) in human prostate tissue, premalignant changes, and in primary, metastatic, and recurrent prostatic adenocarcinoma. *Prostate* **54** 79–87.
- Foley EF, Jazaeri AA, Shupnik MA, Jazaeri O & Rice LW 2000 Selective loss of estrogen receptor beta in malignant human colon. *Cancer Research* **60** 245–248.
- Garcia-Pascual L, Millan M, Anglada J & Garau J 1993 Tamoxifen failure in medullary thyroid carcinoma. *Tumori* **79** 357–358.
- Hiasa Y, Nishioka H, Kitahori Y, Yane K, Nakaoka S, Ohshima M, Konishi N, Nishii K, Kitamura M & Matsunaga T 1993 Immunohistochemical analysis of estrogen receptors in 313 paraffin section cases of human thyroid tissue. *Oncology* **50** 132–136.
- Jakacka M, Ito M, Weiss J, Chien PY, Gehm BD & Jameson JL 2001 Estrogen receptor binding to DNA is not required for its activity through the nonclassical AP1 pathway. *Journal of Biological Chemistry* **276** 13615–13621.
- Jakacka M, Ito M, Martinson F, Ishikawa T, Lee EJ & Jameson JL 2002 An estrogen receptor (ER)alpha deoxyribonucleic acid-binding domain knock-in mutation provides evidence for nonclassical ER pathway signaling *in vivo*. *Molecular Endocrinology* **16** 2188–2201.
- Jarvinen TA, Pelto-Huikko M, Holli K & Isola J 2000 Estrogen receptor beta is coexpressed with ERalpha and PR and associated with nodal status, grade, and proliferation rate in breast cancer. *American Journal of Pathology* **156** 29–35.
- Kebebew E, Ituarte PH, Siperstein AE, Duh QY & Clark OH 2000a Medullary thyroid carcinoma: clinical characteristics, treatment, prognostic factors, and a comparison of staging systems. *Cancer* **88** 1139–1148.
- Kebebew E, Kikuchi S, Duh QY & Clark OH 2000b Long-term results of reoperation and localizing studies in patients with persistent or recurrent medullary thyroid cancer. *Archives of Surgery* **135** 895–901.
- Latil A, Bieche I, Vidaud D, Lidereau R, Berthon P, Cussenot O & Vidaud M 2001 Evaluation of androgen, estrogen (ER alpha and ER beta), and progesterone receptor expression in human prostate cancer by real-time quantitative reverse transcription-polymerase chain reaction assays. *Cancer Research* **61** 1919–1926.
- Lazennec G, Bresson D, Lucas A, Chauveau C & Vignon F 2001 ER beta inhibits proliferation and invasion of breast cancer cells. *Endocrinology* **142** 4120–4130.
- Leav I, Lau KM, Adams JY, McNeal JE, Taplin ME, Wang J, Singh H & Ho SM 2001 Comparative studies of the estrogen receptors beta and alpha and the androgen receptor in normal human prostate glands, dysplasia, and in primary and metastatic carcinoma. *American Journal of Pathology* **159** 79–92.
- Lee C, Kao H, Lin H, P'Eng F & Chi C 1998 Estrogen receptors and glucocorticoid receptors in human well-differentiated thyroid cancer. *International Journal of Molecular Medicine* **2** 229–233.
- Lee EJ, Jakacka M, Duan WR, Chien PY, Martinson F, Gehm BD & Jameson JL 2001 Adenovirus-directed expression of dominant negative estrogen receptor induces apoptosis in breast cancer cells and regression of tumors in nude mice. *Molecular Medicine* **7** 773–782.
- Lewy-Trenda I 2002 Estrogen and progesterone receptors in neoplastic and non-neoplastic thyroid lesions. *Polish Journal of Pathology* **53** 67–72.
- Marsh DJ, Learoyd DL & Robinson BG 1995 Medullary thyroid carcinoma: recent advances and management update. *Thyroid* **5** 407–424.
- Messina M, Yu DM, Learoyd DL, Both GW, Molloy PL & Robinson BG 2000 High level, tissue-specific expression of a modified calcitonin/calcitonin gene-related peptide promoter in a human medullary thyroid carcinoma cell line. *Molecular and Cellular Endocrinology* **164** 219–224.
- Mustafa T, Klonisch T, Hombach-Klonisch S, Kehlen A, Schmutzler C, Koehrl J, Gimm O, Dralle H & Hoang-Vu C 2004 Expression of CD97 and CD55 in human medullary thyroid carcinomas. *International Journal of Oncology* **24** 285–294.
- Naveh-Manly T, Almogi G, Livni N & Silver J 1992 Estrogen receptors and biologic response in rat parathyroid tissue and C cells. *Journal of Clinical Investigations* **90** 2434–2438.
- O'Brien JE, Peterson TJ, Tong MH, Lee EJ, Pfaff LE, Hewitt SC, Korach KS, Weiss J & Jameson JL 2006 Estrogen-induced proliferation of uterine epithelial cells is independent of estrogen receptor alpha binding to classical estrogen response elements. *Journal of Biological Chemistry* **281** 26683–26692.
- Omoto Y, Inoue S, Ogawa S, Toyama T, Yamashita H, Muramatsu M, Kobayashi S & Iwase H 2001 Clinical value of the wild-type estrogen receptor beta expression in breast cancer. *Cancer Letters* **163** 207–212.
- Paech K, Webb P, Kuiper GG, Nilsson S, Gustafsson J, Kushner PJ & Scanlan TS 1997 Differential ligand activation of estrogen receptors ERalpha and ERbeta at AP1 sites. *Science* **277** 1508–1510.
- Paruthiyil S, Parmar H, Kerekatte V, Cunha GR, Firestone GL & Leitman DC 2004 Estrogen receptor beta inhibits human breast cancer cell proliferation and tumor formation by causing a G2 cell cycle arrest. *Cancer Research* **64** 423–428.
- Petrangolini G, Cuccuru G, Lanzi C, Tortoreto M, Belluco S, Pratesi G, Cassinelli G & Zunino F 2006 Apoptotic cell death induction and angiogenesis inhibition in large established medullary thyroid carcinoma xenografts by Ret inhibitor RPI-1. *Biochemical Pharmacology* **72** 405–414.
- Pujol P, Rey JM, Nirde P, Roger P, Gastaldi M, Laffargue F, Rochefort H & Maudelonde T 1998 Differential expression of estrogen receptor-alpha and -beta messenger RNAs as a potential marker of ovarian carcinogenesis. *Cancer Research* **58** 5367–5373.
- Qiu Y, Waters CE, Lewis AE, Langman MJ & Eggo MC 2002 Oestrogen-induced apoptosis in colonocytes expressing oestrogen receptor beta. *Journal of Endocrinology* **174** 369–377.
- Roger P, Sahla ME, Makela S, Gustafsson JA, Baldet P & Rochefort H 2001 Decreased expression of estrogen receptor beta protein in proliferative preinvasive mammary tumors. *Cancer Research* **61** 2537–2541.
- Rutherford T, Brown WD, Sapi E, Aschkenazi S, Munoz A & Mor G 2000 Absence of estrogen receptor-beta expression in metastatic ovarian cancer. *Obstetrics and Gynecology* **96** 417–421.
- Speirs V, Malone C, Walton DS, Kerin MJ & Atkin SL 1999a Increased expression of estrogen receptor beta mRNA in tamoxifen-resistant breast cancer patients. *Cancer Research* **59** 5421–5424.
- Speirs V, Parkes AT, Kerin MJ, Walton DS, Carleton PJ, Fox JN & Atkin SL 1999b Coexpression of estrogen receptor alpha and beta: poor prognostic factors in human breast cancer? *Cancer Research* **59** 525–528.
- Taylor AH & Al-Azzawi F 2000 Immunolocalisation of oestrogen receptor beta in human tissues. *Journal of Molecular Endocrinology* **24** 145–155.
- Wang W, Johansson HE, Bergholm UI, Westermark KM & Grimelius LE 1997 Expression of c-Myc, TGF-alpha and EGF-receptor in sporadic medullary thyroid carcinoma. *Acta Oncologica* **36** 407–411.
- Weber CJ, Marvin M, Krekun S, Koschitzky T, Karp F, Benson M & Feind CR 1990 Effects of tamoxifen and somatostatin analogue on growth of human medullary, follicular, and papillary thyroid carcinoma cell lines: tissue culture and nude mouse xenograft studies. *Surgery* **108** 1065–1071.
- Yane K, Tanaka O, Miyahara H, Matsunaga T, Kitahori Y & Hiasa Y 1993 Immunohistochemical study of epidermal growth factor receptor and estrogen receptor in human thyroid tumors. *Nippon Jibiinkoka Gakkai Kaiho* **96** 787–790.
- Yane K, Kitahori Y, Konishi N, Okaichi K, Ohnishi T, Miyahara H, Matsunaga T, Lin JC & Hiasa Y 1994 Expression of the estrogen receptor in human thyroid neoplasms. *Cancer Letters* **84** 59–66.

Received in final form 19 August 2007

Accepted 30 August 2007

Made available online as an Accepted Preprint  
30 August 2007