

Bilateral Breast Cancer: Differential Diagnosis Using Histological and Biological Parameters

Soo Jung Gong¹, Sun Young Rha², Hei Cheul Jeung², Jae Kyung Roh², Woo Ick Yang³ and Hyun Cheol Chung²

¹Department of Internal Medicine, Eulji University School of Medicine, ²Cancer Metastasis Research Center, Yonsei Cancer Center and ³Department of Pathology, Yonsei University College of Medicine, Seoul, Korea

Received November 27, 2006; accepted February 11, 2007; published online August 1, 2007

Background: Contralateral breast cancer is either a metastatic lesion or the second primary cancer. From biological and therapeutic viewpoints, it is important to differentiate metastatic lesions from second primary cancer in bilateral breast cancer.

Methods: Based on Chaudary's histological criteria, we analysed the tumors in 14 and 27 patients with synchronous and metachronous bilateral breast cancers with full histological and biological evaluations. The Nottingham combined histological grade and immunohistochemistry (IHC) for the estrogen receptor, progesterone receptor and *cerbB-2* were used.

Results: The median age of the patients at first diagnosis was 41 years (range, 26–68 years) and the median time interval between first and second tumors was 34 months (range; 7–209 months) in metachronous cancers. The histopathological type was found in 93% of synchronous cancers and 59% of metachronous cancers ($P = 0.02$). The concordance rates of T stage and TNM stage were 71 and 64% respectively in synchronous cancers, while they were 24 and 32% respectively in metachronous cancers ($P = 0.03$). For progesterone receptor status, the concordance rates were 86 and 52% in synchronous and metachronous cancers respectively ($P = 0.03$). In addition, there was no statistically significant difference in terms of N stage, histological grade, intraductal component, estrogen receptor status, or *cerbB-2* expression.

Conclusion: In spite of the limitation of Chaudary's criteria and the number of patients involved, the combination of histopathological type, T stage and TNM stage shows that synchronous cancers are closer to same clonal lesions (metastatic lesions) than metachronous cancers and that a biomarker, such as progesterone receptor status, plays a role in addition to the histological parameters in differentiating metastatic cancers from second primary cancers.

Key words: bilateral breast cancer – histology – biomarker

INTRODUCTION

Bilateral breast cancer has an overall incidence of 4–20% in patients with primary operable breast cancer (1). The risk factors associated with bilateral occurrence are: familial or hereditary breast cancer, young age at primary breast cancer diagnosis, lobular invasive carcinoma, multicentricity and radiation exposure (1,2).

Contralateral breast cancer is either a metastatic lesion or the second primary cancer, and occurs either synchronously or metachronously. Chaudary et al. (3) categorized

contralateral breast cancer into a metastatic lesion or second primary cancer based only on pathologic criteria.

Several reports showed that the prognosis in bilateral breast cancer was worse than that of unilateral breast cancer (4–7). There have also been many debates regarding biological and therapeutic aspects of bilateral breast cancers (8,9). Considering these points, it is important to know whether contralateral breast cancer is a metastatic lesion or the second primary cancer.

In the late 1990s the cDNA microarray-based comparative genomic hybridization (CGH) method has been employed to investigate the clonality of bilateral breast cancers and it showed higher DNA copy number changes in metachronous than in synchronous bilateral breast cancers (10). However, this method is complicated,

For reprints and all correspondence: Hyun Cheol Chung, Cancer Metastasis Research Center, Department of Internal Medicine, Yonsei University College of Medicine, Seoul 120-752, Korea. E-mail: unchung8@yumc.yonsei.ac.kr

expensive and needs further validation for general use. Therefore, although a caveat of the pathologic criteria of Chaudary is that a synchronous bilateral breast cancer is considered as a metastatic lesion and not a multifocal monoclonal lesion, this criterion is simple and easily available in clinical practice.

In addition to genetic and pathological features, biological features have been evaluated as well. Some researchers reported that histological and biological features in synchronous bilateral breast cancers were similar (11,12). However, there are still controversies about the patterns of biological phenotypes in metachronous cancers (13,14).

The aim of this study was to analyse the concordance rates of histological and biological parameters that are easily accessible in synchronous and metachronous bilateral breast cancers and thus to differentiate a metastatic lesion from the second primary cancer in bilateral breast cancer.

PATIENTS AND METHODS

PATIENTS

Among the 4702 patients diagnosed with breast cancer from 1974 to 2003 at Yonsei Cancer Center, Yonsei University College of Medicine, 73 patients were diagnosed with bilateral breast cancer without any systemic lesions. From these patients, 41 patients were enrolled (14 synchronous, 27 metachronous) with full evaluation for histological and biological phenotypes from archive paraffin blocks. Contralateral breast lesions were examined by breast ultrasonography and cancer was confirmed histologically.

Bilateral breast cancer was defined as synchronous when contralateral cancer was identified within 6 months after the first breast cancer (1). Contralateral breast cancer, diagnosed with the interval of more than 6 months, was defined as metachronous bilateral breast cancer.

The overall median age of the patients at the time of diagnosis of the first breast cancer was 41 years (range, 26–68 years). The median time intervals between the first and the subsequent breast cancer diagnosis were 0 months and 34 months (range; 7–209 months) in synchronous and metachronous cancers, respectively. The characteristics of the patients are summarized in Table 1.

HISTOLOGICAL EVALUATION

The paraffin-embedded tumor sections were analysed according to the Nottingham combined histological grade (Elston-Ellis modification of the Scarff-Bloom-Richardson grading system) after staining with hematoxyline and eosin (15). The histological grade was not scored in eight tumors of medullary and lobular type. Intraductal components (IDCs) were not checked in four lobular type tumors and three mucinous type tumors.

Table 1. Patient characteristics of bilateral breast cancer

Variable	Synchronous (<i>n</i> = 14)		Metachronous (<i>n</i> = 27)	
	1st tumor	2nd tumor	1st tumor	2nd tumor
Age at diagnosis (yr), [median (range)]	47 (28–64)		39 (26–68)	44 (28–70)
Time-interval of different tumors (yr), [median (range)]	0		34 (7–209)	
Stage				
O	0	0	4	1
I	0	3	1	11
II	8	6	19	12
III	6	5	3	1
IV	0	0	0	2

IMMUNOHISTOCHEMISTRY FOR STEROID RECEPTOR STATUS AND *cerbB-2* EXPRESSION

For immunohistochemistry (IHC), deparaffinized sections were immunostained with primary antibodies to estrogen receptor, progesterone receptor (1:50; Novocastra, Newcastle, UK), and *cerbB-2* oncoprotein (1:50; Dako, CA, USA). In negative controls, distilled water was applied as a substitute for primary antibodies. Sections were subjected to heat-induced epitope retrieval for 20 min in a citrate buffer (pH 6.0), using a microwave (800 W) and a pressure cooker. Antigens were localized using a labeled streptavidin method (Universal LSAB2 kit, Dako) with 3,3'-diaminobenzidine as a chromogen (16).

In estrogen and progesterone receptor stain, a 20% nuclear positivity rate was regarded as receptor positive (17). Distinct membrane staining was considered to be specific for *cerbB-2* gene expression (18). Two positive (++, a weak to moderate membrane staining is observed in more than 10% of the tumor cells) and three positive (+++, a strong complete membrane staining is observed in more than 10% of the tumor cells) were regarded as *cerbB-2* expression positive.

STAGING OF BREAST CANCER

Cancer staging was done in all bilateral breast cancer patients by AJCC criteria (19).

STATISTICAL METHODS

Student's *t*-test was used for the analysis of group comparison with histologic and biologic parameters. Correlation between variables was estimated with Pearson's correlation. Statistical values of $P < 0.05$ were considered as significant.

RESULTS

HISTOLOGICAL DIFFERENCES IN BILATERAL BREAST CANCER

The most common histopathological type was infiltrating ductal carcinoma (78% in all) (Table 2). The rates of the same histopathological type were 93% in synchronous cancers but only 59% in metachronous cancers ($P = 0.02$) (Fig. 1). The concordance rates of histological grade were 50% in synchronous cancers and 33% in metachronous cancers (Fig. 1). The rate that tumors belonged to the high intraductal component (IDC) group was 20% in two tumors of synchronous cancer and 16% in second tumors of metachronous cancer (Table 2).

STAGING DIFFERENCES IN BILATERAL BREAST CANCER TISSUE

The concordance rates of T stage, N stage and TNM stage were seen to be 71, 79 and 64% respectively in synchronous cancers whereas they were 24, 74 and 32% respectively, in metachronous cancers. T stages and TNM stages are more diverse in metachronous cancers than in synchronous cancers ($P = 0.03$) (Fig. 1).

STEROID RECEPTOR STATUS IN BILATERAL BREAST CANCER TISSUE

In synchronous cancers, the concordance rate of estrogen receptor expression was 71% and that of progesterone

receptor was 86%. However, in metachronous cancers, the concordance rates of both estrogen and progesterone receptor expression were 52% (Fig. 2). In terms of progesterone receptor status, the difference in the concordance rates of expression in synchronous and metachronous cancers was significant ($P = 0.03$) (Fig. 2).

The positivity of steroid receptor status was evaluated according to the age of the patient. In synchronous cancers, patients older than 50 years showed higher estrogen receptor positivity (71%) than those under 50 years old ($P = 0.02$) (Table 3). Progesterone receptor status in synchronous and metachronous cancers, and estrogen receptor status in metachronous cancers were not significantly different between the two age groups.

COMPARISON OF *cerbB-2* GENE EXPRESSION IN BILATERAL BREAST CANCER TISSUE

In synchronous cancers, *cerbB-2* expression was concordant in 71% of patients: both positive, 29% and both negative, 43% (Fig. 2, Table 4). In metachronous cancers, the concordance rate was 63% (Fig. 2, Table 4).

DISCUSSION

In bilateral breast cancer, it is important to know whether contralateral breast lesion is metastatic or second primary, but the distinction is not always easy. Chaudary *et al.* (3) proposed criteria for the diagnosis of second primary breast cancer in 1984 as follows: (i) there must be *in situ* change in the contralateral tumor, (ii) the tumor in the second breast is histologically different from the cancer in the first breast, (iii) the degree of histological differentiation of the tumor in the second breast is distinctly greater than that of the lesion in the first breast, (iv) there is no evidence of local, regional, or distant metastases from the cancer in the ipsilateral breast. Despite novel methods such as cDNA microarray-based CGH, Chaudary's criteria have been hitherto the most widely accepted method to distinguish second primary lesion from metastatic lesion. Using these criteria, we attempted to characterize synchronous and metachronous bilateral breast cancers.

The concordance rates of histopathologic type were 93% and 59% in synchronous and metachronous cancers respectively ($P = 0.02$). In terms of the tumor grade and *in situ* change, no significant differences were found between synchronous and metachronous cancers. The proportion of the patients with the same T and TNM stages between the first and the second tumors is higher in synchronous cancers than in metachronous cancers ($P = 0.03$). These results show that synchronous cancers are more of the same clonal origin than metachronous ones in Asian bilateral breast cancer, which has low compared with its prevalence in Western countries, and was in accordance with the results of large scale Korean studies (20).

Table 2. Characteristics of histological parameters in bilateral breast cancers

Variable	Synchronous (n = 14)		Metachronous (n = 27)	
	1st tumor	2nd tumor	1st tumor	2nd tumor
Histopathologic type				
IDC ¹	12	11	18	23
DCIS ²	0	0	3	1
medullary ca.	0	0	3	1
lobular ca.	1	1	1	1
tubular	1	1	0	0
mucinous	0	1	1	1
papillary	0	0	1	0
Histological grade ³				
1	1	2	2	6
2	6	5	14	9
3	6	5	6	9
Intraductal component ⁴				
0–50%	11	9	19	21
50–100%	2	3	6	4

¹Infiltrating ductal carcinoma. ²Ductal carcinoma *in situ*. ³Not scored in medullary and lobular type. ⁴Not checked in lobular and mucinous type.

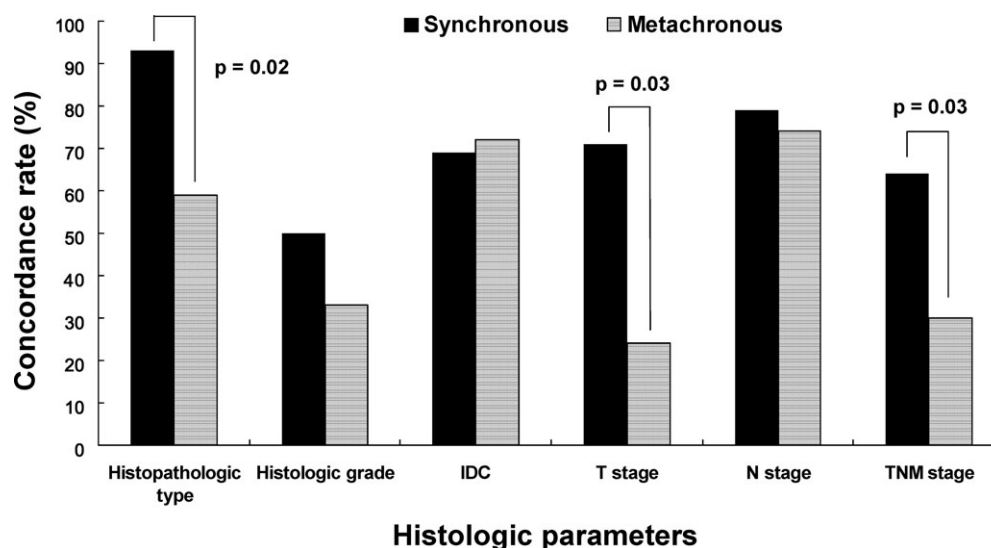


Figure 1. Concordance rates (%) of histologic parameters in synchronous and metachronous bilateral breast cancers. IDC, intraductal component.

Steroid receptor expressions in bilateral breast cancers have been evaluated in several reports (11–14). Some authors have found that the concordance rate of estrogen receptor level and its positivity rate are high in synchronous cancers (11,12). In our study, no differences were found in the concordance rate of estrogen receptor expression in synchronous and metachronous bilateral breast cancers. However, the concordance rate of progesterone receptor expression was significantly higher in synchronous cases ($P = 0.03$). Considering the results of previous studies and the positive regulation of progesterone receptor expression by estrogen (21), the results of steroid hormone receptor expression in this study show that further validation in a large-scale study is required.

The steroid hormone receptor expression was more commonly negative in synchronous cancers than in metachronous

cancers. Because the steroid hormone receptor expression in breast cancer is age dependent (22), we compared the hormone receptor expression between the patients younger and older than 50 years. Estrogen receptor positivity was higher in patients over 50 years old than in those under 50 years in synchronous cancers ($P = 0.02$). These findings are in accordance with one of the explanations of bilaterality in breast cancer; namely hormone dependence. In metachronous cancers, significant differences of the estrogen receptor expression rate were not found between the two age groups. Relatively long periods between the diagnosis of the first tumor and the second tumor may contribute to this result; five of 27 patients with metachronous bilateral breast cancers had the first breast cancer before the age of 50 and the second breast cancer after the age of 50. Moreover, administration of tamoxifen for the treatment of the first breast

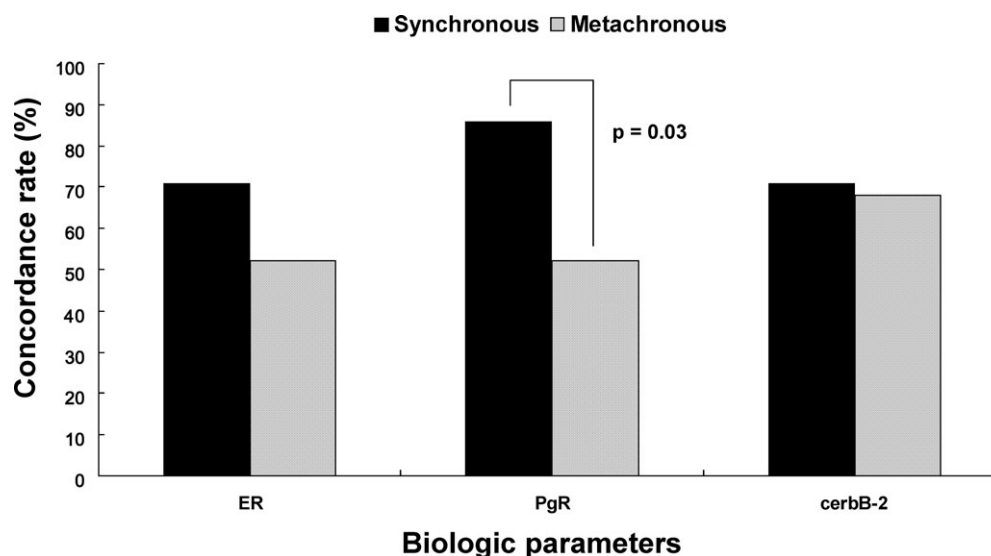


Figure 2. Concordance rates (%) of biologic parameters in synchronous and metachronous bilateral breast cancers.

Table 3. Steroid receptor positivity¹ in synchronous and metachronous bilateral breast cancers according to age

Variable	Synchronous			Metachronous		
	Negative (%)	Positive (%)	P value	Negative (%)	Positive (%)	P value
Estrogen receptor						
Age <50	71	29		38	62	
Age ≥50	29	71	0.02	54	46	0.53
Progesterone receptor						
Age <50	71	29		60	40	
Age ≥50	71	29	1.00	69	31	0.75

¹All tumors (first and second tumors) are separately evaluated.

cancer might influence estrogen receptor status in contralateral breast cancer (23,24). In this small number of patients, the tamoxifen effect on estrogen receptor expression of the subsequent breast cancer was not conclusive in a subgroup analysis.

Several genetic alterations had been identified in breast cancer (20): p53 and *cerbB-2* expression were investigated in

Table 4. Steroid receptor and *cerbB-2* expression in bilateral breast cancers¹

Variable	Synchronous (n = 14)	Metachronous (n = 27)
Estrogen receptor		
both (+)	5 (36)	9 (33)
both (−)	5 (36)	5 (19)
(−) → (+)	—	5 (19)
(+) → (−)	—	8 (30)
same	10 (71)	14 (52)
different	4 (29)	13 (48)
Progesterone receptor		
both (+)	3 (21)	4 (15)
both (−)	9 (64)	10 (37)
(−) → (+)	—	4 (15)
(+) → (−)	—	9 (33)
same	12 (86)	14 (52)
different	2 (14)	13 (48)
<i>cerbB-2</i>		
both (+)	4 (29)	4 (15)
both (−)	6 (43)	13 (48)
(−) → (+)	—	6 (22)
(+) → (−)	—	4 (15)
same	10 (71)	17 (63)
different	4 (29)	10 (37)

¹Numbers within parentheses in both columns represent expression rate (%).

bilateral breast cancers (25–29). *cerbB-2* protein overexpression is more common in ductal cancer *in situ* (DCIS) than in infiltrating ductal carcinoma, suggesting that *cerbB-2* gene amplification is an early event of breast cancer development.

In the present study, staining for *cerbB-2* was positive in 44% of all tumor tissues, regardless of the first or the second tumors, which was higher than the *cerbB-2* expression rate of about 26% in unilateral breast cancer (30). Safar et al. (29) produced similar results and suggested that, in comparison with the unilateral breast cancer, the increased mortality of patients with bilateral synchronous breast cancer may be associated with the higher rate of *cerbB-2* overexpression. Van Agthoven et al. (31) investigated EGFR expression in bilateral breast cancer tissues and found no significant correlation between EGFR expression and the interval between the first and second tumors. We also were unable to find differences of the *cerbB-2* expression rate between synchronous and metachronous breast cancer tissues.

The concordance rates of histopathological type, T stage, TNM stage and progesterone receptor expression were significantly higher in synchronous cancers than in metachronous bilateral breast cancers ($P = 0.032$). That means synchronously developed pairs of bilateral breast cancers are biologically closer than metachronous bilateral breast cancers. Accordingly, with respect to treatment strategies, synchronous bilateral breast cancers can be considered as the same origin but treatment for metachronous bilateral breast cancers should be individualized.

Although this study is limited owing to the number of patients involved, this report shows that biological marker can be an indicator in addition to the histological factors in order to differentiate metastatic cancer from second primary cancer in synchronous and metachronous bilateral cancers of the breast.

Acknowledgment

This work was supported by the Korea Science and Engineering Foundation (KOSEF) through the Cancer Metastasis Research Center (CMRC) at Yonsei University.

Conflict of interest statement

None declared.

References

- Dawson LA, Chow E, Goss PE. Evolving perspectives in contralateral breast cancer. *Eur J Cancer* 1998;34:2000–9.
- Chuba PJ, Hamre MR, Yap J, Severson RK, Lucas D, Shamsa F, et al. Bilateral risk for subsequent breast cancer after lobular carcinoma in-situ: analysis of surveillance, epidemiology, and end results data. *J Clin Oncol* 2005;23:5534–41.
- Chaudary MA, Millis RR, Hoskins EOL, Halder M, Bulbrook RD. Bilateral breast cancer: A prospective study of disease incidence. *Br J Surg* 1984;71:711–4.
- Takahashi H, Watanabe K, Takahashi M, Taguchi K, Sasaki F, Todo S. The impact of bilateral breast cancer on the prognosis of breast cancer:

- a comparative study with unilateral breast cancer. *Breast Cancer* 2005;12:196–202.
5. Levi F, Randimbison L, Te VC, La Vecchia C. Prognosis of bilateral synchronous breast cancer in Vaud, Switzerland. *The Breast* 2003;12:89–91.
 6. Carmichael AR, Bendall S, Lockerbie L, Prescott R, Bates T. The long-term outcome of synchronous bilateral breast cancer is worse than metachronous or unilateral tumours. *Eur J Surg Oncol* 2002;28:388–91.
 7. Kollias J, Ellis IO, Elston CW, Blamey RW. Prognostic significance of synchronous and metachronous bilateral breast cancer. *World J Surg* 2001;25:1117–24.
 8. Mose S, Adamietz IA, Thilmann C, Saran F, Bernhard M, Pahnke R, et al. Bilateral breast carcinoma versus unilateral disease. Review of 498 patients. *Am J Clin Oncol* 1997;20:541–5.
 9. Deo SV, Shridhar D, Purkayastha J, Bhutani M, Shukla NK, Raina V. Therapeutic controversies in bilateral breast cancer. *Clin Oncol (R Coll Radiol)* 2003;13:297–8.
 10. Seo MY, Rha SY, Yang SH, Kim SC, Lee GY, Park CH, et al. The pattern of gene copy number changes in bilateral breast cancer surveyed by cDNA microarray-based comparative genomic hybridization. *Int J Mol Med* 2004;13:17–24.
 11. Intra M, Rotmensz N, Viale G, Mariani L, Bonanni B, Mastropasqua MG, et al. Clinicopathologic characteristics of 143 patients with synchronous bilateral invasive breast carcinomas treated in a single institution. *Cancer* 2004;101:905–12.
 12. de la Rochefordiere A, Asselain B, Scholl S, Campana F, Ucla L, Vilcoq JR, et al. Simultaneous bilateral breast carcinomas: a retrospective review of 149 cases. *Int J Radiat Oncol Biol Phys* 1994;30:35–41.
 13. Brankovic-Magic M, Nikolic-Vukosavljevic D, Neskovic-Konstantinovic Z, Kanjer K, Spuzic I. Estrogen and progesterone receptor content in bilateral breast cancer. *Pathol Res Pract* 1995;191:16–24.
 14. Hahnel R, Twaddle E. The relationship between estrogen receptors in primary and secondary breast carcinomas and in sequential primary breast carcinoma. *Breast Cancer Res Treat* 1985;5:155–63.
 15. Elston CW, Ellis IO. Pathological prognostic factors in breast cancer. I. The value of histological grade in breast cancer: experience from a large study with long-term follow-up. *Histopathology* 1991;19:403–10.
 16. Shi SR, Cote RJ, Chaiwun B, Young LL, Shi Y, Hawes D, et al. Standardization of immunohistochemistry based on antigen retrieval technique for routine formalin-fixed tissue sections. *Appl Immunohistochem* 1998;6:89–96.
 17. Layfield LJ, Gupta D, Mooney EE. Assessment of tissue estrogen and progesterone receptor levels: a survey of current practice, techniques, and quantitation methods. *Breast J* 2000;6:189–96.
 18. Hanna W, Kahn HJ, Trudeau M. Evaluation of HER-2/neu(erbB-2) status in breast cancer: from bench to bedside. *Mol Pathol* 1999;12:827–34.
 19. Greene FL, Page DL, Fleming ID. *AJCC Cancer Staging Manual*. New York: Springer-Verlag 2002;257–81.
 20. Son BH, Kwak BS, Kim JK, Kim HJ, Hong SJ, Lee JS, et al. Changing patterns in the clinical characteristics of Korean patients with breast cancer during the last 15 years. *Arch Surg* 2006;141:155–60.
 21. Dickson RB, Pestell RG, Lippman ME. Molecular biology of breast cancer. In DeVita VT, Hellman S, Rosenberg SA, editors. *Cancer: Principles & Practice of Oncology*. Philadelphia, PA: Lippincott Williams & Wilkins 2005;1399–414.
 22. Colleoni M, Rotmensz N, Robertson C, Orlando L, Viale G, Renne G, et al. Very young women (<35 years) with operable breast cancer: features of disease at presentation. *Ann Oncol* 2002;13:273–9.
 23. Arpino G, Weiss HL, Clark GM, Hilsenbeck SG, Osborne CK. Hormone receptor status of a contralateral breast cancer is independent of the receptor status of the first primary in patients not receiving adjuvant tamoxifen. *J Clin Oncol* 2005;23:4687–94.
 24. Swain SM, Wilson JW, Mamounas EP, Bryant J, Wickerham DL, Fisher B, et al. Estrogen receptor status of primary breast cancer is predictive of estrogen receptor status of contralateral breast cancer. *J Natl Cancer Inst* 2004;96:516–23.
 25. Cavaliere A, Bellezza G, Scheibel M, Vitali R, Sidoni A. Biopathological profile of multiple synchronous homolateral and bilateral breast cancers. *Pathol Res Pract* 2004;200:9–12.
 26. Matsuo K, Fukutomi T, Akashi-Tanaka S, Hasegawa T, Tsuda H. Histological grade, p53, HER2 and hormone receptor status of synchronous bilateral breast carcinoma. *Breast Cancer* 2002;9:127–33.
 27. Matsuo K, Fukutomi T, Tsuda H, Akashi-Tanaka S, Shimizu C, Hasegawa T. Differences in estrogen receptor status, HER2, and p53 comparing metachronous bilateral breast carcinoma. *J Surg Oncol* 2001;77:31–4.
 28. Kinoshita T, Ueda M, Enomoto K, Lkeda T, Kikuchi K, Ishii S, et al. Comparison of p53 gene abnormalities in bilateral and unilateral breast cancer. *Cancer* 1995;76:2504–9.
 29. Safal M, Lower EE, Hasselgren PO, Hungness ES, Gazder P, Aron B, et al. Bilateral synchronous breast cancer and HER-2/neu overexpression. *Breast Cancer Res Treat* 2002;72:195–201.
 30. Revillion F, Bonnetterre J, Peyrat JP. ERBB2 oncogene in human breast cancer and its clinical significance. *Eur J Cancer* 1998;34:791–808.
 31. van Agthoven T, Timmermans M, Dorssers LC, Henzen-Logmans SC. Expression of estrogen, progesterone and epidermal growth factor receptor in primary and metastatic breast cancer. *Int J Cancer* 1995;63:790–3.