

Calcinosis Cutis at the Tarsus of the Upper Eyelid

Ikhyun Jun¹, Sung Eun Kim¹, Sang Yeul Lee¹, Gi Jeong Kim², Jin Sook Yoon¹

¹*Institute of Vision Research, Department of Ophthalmology, Yonsei University College of Medicine, Seoul, Korea*

²*Department of Pathology, Yonsei University College of Medicine, Seoul, Korea*

Calcinosis cutis involves the inappropriate deposition of calcium within the dermis layer of the skin, and is often associated with rheumatoid disease. A 42-year-old woman presented for evaluation of a hard palpable mass on the left upper eyelid. After everting the eyelid, a large papillomatous mass with a broad base was identified on the superior area of the tarsus. The lesion was partially excised posteriorly under local anesthesia, and pathologists identified the mass as calcinosis cutis. The patient had no systemic or trauma history, and the serum levels of calcium and phosphorous were normal. Idiopathic calcinosis cutis should be included in the differential diagnosis for a protruding papillomatous mass of the tarsal plate, and surgical debulking could be a viable option for large protruding lesions, although more follow-up is necessary to monitor regrowth.

Key Words: Calcinosis cutis, Idiopathic, Papillomatous mass, Tarsus

Calcinosis cutis is a recognizable disorder characterized by the deposition of amorphous calcium and phosphate salts under the epidermal layer [1,2]. This condition is frequently associated with rheumatoid disease, and can lead to pain and disability in these patients [3]. Calcinosis cutis can be divided into four types: dystrophic, metastatic, iatrogenic, and idiopathic. The dystrophic type is observed in damaged or devitalized tissues, while the metastatic type is associated with high serum levels of calcium or phosphate, as can be seen with various systemic diseases. The iatrogenic type of calcinosis cutis is generally associated with calcium-containing medical devices or medications [2], and the idiopathic type occurs in the absence of tissue injury or detectable disease in otherwise healthy individuals.

Several cases of idiopathic calcinosis cutis involving the scrotum, penis, vulva, breast, or extremities have been described [1,3,4]. A subepidermal calcified nodule, which is a form of calcinosis cutis, on the eyelid beneath the skin has also been reported [5]. There is a case of ossification of the eyelid and orbit in a patient with pseudo-pseudohypoparathyroidism [6]. However, there has been no report of idiopathic calcinosis cutis protruding from the tarsus. This is the

first case report of idiopathic calcinosis cutis occurring at the upper tarsus in a healthy woman.

Case Report

A 42-year-old woman presented for evaluation of a slow-growing, painless, palpable mass on the left upper eyelid, which initially developed several years earlier. She was a hepatitis B virus carrier, but otherwise in a healthy condition. No history of orbital trauma or filler injection was reported. At the time of her first visit, her uncorrected vision was 1.0 for both eyes. Under slit-lamp examination, slight conjunctival

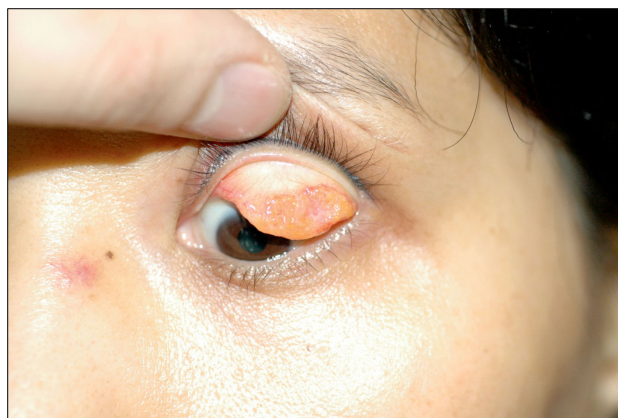

Fig. 1. Papillomatous mass involving the tarsus is shown in the left eye.

Received: October 26, 2010 Accepted: December 16, 2010

Corresponding Author: Jin Sook Yoon, MD. Department of Ophthalmology, Yonsei University College of Medicine, #250 Seongsan-ro, Seodaemun-gu, Seoul 120-752, Korea. Tel: 82-2-2228-3570, Fax: 82-2-3463-1049, E-mail: yoonjs@yuhs.ac

© 2011 The Korean Ophthalmological Society

This is an Open Access article distributed under the terms of the Creative Commons Attribution Non-Commercial License (<http://creativecommons.org/licenses/by-nc/3.0/>) which permits unrestricted non-commercial use, distribution, and reproduction in any medium, provided the original work is properly cited.

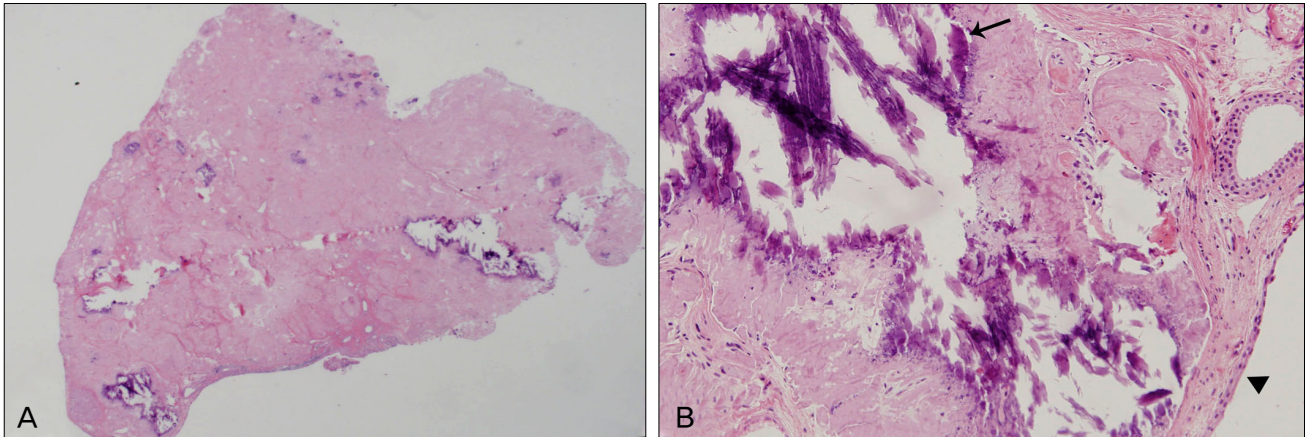


Fig. 2. Histopathologic finding of the tarsal lesion. (A) Low power view of the lesion (H&E, $\times 12$) with a significant amount of amorphous calcium material (stained pink) and multiple calcium crystals (stained purple). (B) High power view showing the calcium crystals in the lesion (H&E, $\times 100$). Arrow, calcium crystal; arrow head, tarsal epithelium.

injection of the left eye was noted, but the cornea was clear. The laboratory data showed no abnormalities. Serum calcium and phosphorous levels were also normal. On inspection, the left eyelid was slightly elevated, and a hard, palpable mass was detected in the upper eyelid. Everting the upper eyelid revealed a large papillomatous mass attached to the upper margin of the tarsus (Fig. 1).

As the patient did not want to risk possible disfigurement with a complete excision, the protruding mass above the tarsal border was partially debulked at the conjunctival side under local anesthesia, and was sent to the pathology department where it was identified as calcinosis cutis. Fig. 2 shows a massive amorphous calcium material beneath the epithelial lining and basophilic-stained crystallized calcification deposits. The normal tarsus tissue was scarcely present.

Discussion

Calcinosis cutis is pathologically defined as the deposition of calcium material beneath the epithelial lining. It mostly affects patients with connective tissue disorders, such as dermatomyositis, systemic lupus erythematosus, or systemic sclerosis [3]. Other types of calcifications, such as band keratopathy, bulbar calcification, or palpebral, conjunctival, or eyelid calcification, have been reported in patients with ocular inflammation, systemic hyperparathyroidism, or hyperphosphatemia [5,7]. However, in this case, the patient had normal serum levels of calcium and phosphate, and no previous systemic or trauma history. Based upon this information, this case represents the first incidence of idiopathic calcinosis cutis affecting the tarsus of the eyelid.

No standard treatment has been recommended for the removal or reduction of the lesion in cases of calcinosis cutis [3,8]. Colchicine, warfarin, bisphosphonates, probenecid, and diltiazem have been used with varying degrees of success [8]. Carbon dioxide laser therapy, minocycline [9], salicylates,

and aluminum hydroxide could also be used. The aforementioned treatments were only used for skin lesions, demonstrating limited efficiency. Therefore, surgical excision for a large protruding mass of calcinosis cutis might be the best option. In this case, we performed partial debulking of the lesion, and more follow-up is required to monitor for regrowth. If the regrowth occurs rapidly, complete excision with free margin control will be necessary. However, such a decision would not be easy, as the base of the lesion is quite broad, including the normal tissue of the tarsus, and more importantly, the patient does not feel much irritation from this lesion. Complete excision might cause a serious cosmetic disfigurement or discomfort.

Clinicians should consider calcinosis cutis in the differential diagnosis of papillomatous mass lesions involving the tarsus.

Conflict of Interest

No potential conflict of interest relevant to this article was reported.

References

1. Llamas-Velasco M, Eguren C, Santiago D, et al. Calcinosis cutis and Sjogren's syndrome. *Lupus* 2010;19:762-4.
2. Goldminz D, Barnhill R, McGuire J, Stenn KS. Calcinosis cutis following extravasation of calcium chloride. *Arch Dermatol* 1988;124:922-5.
3. Boulman N, Slobodin G, Rozenbaum M, Rosner I. Calcinosis in rheumatic diseases. *Semin Arthritis Rheum* 2005;34:805-12.
4. Tristano AG, Villarroel JL, Rodriguez MA, Millan A. Calcinosis cutis universalis in a patient with systemic lupus erythematosus. *Clin Rheumatol* 2006;25:70-4.
5. Ferry AP. Subepidermal calcified nodules of the eyelid. *Am J Ophthalmol* 1990;109:85-8.
6. Klauber S, Heegaard S, Prause JU. Primary palpebral and orbital ossification in pseudo-pseudohypoparathyroidism. *Acta Ophthalmol Scand* 2002;80:543-5.

7. Ghanchi F, Ramsay A, Coupland S, et al. Ocular tumoral calcinosis. A clinicopathologic study. *Arch Ophthalmol* 1996;114:341-5.
8. Dutz J. Treatment options for the cutaneous manifestations of systemic sclerosis. *Skin Therapy Lett* 2000;6:3-5.
9. Robertson LP, Marshall RW, Hickling P. Treatment of cutaneous calcinosis in limited systemic sclerosis with minocycline. *Ann Rheum Dis* 2003;62:267-9.