

Cytological Results of Ultrasound-Guided Fine-Needle Aspiration Cytology for Thyroid Nodules: Emphasis on Correlation with Sonographic Findings

Mi-Jung Lee,¹ Soon Won Hong,² Woung Youn Chung,³ Jin Young Kwak,¹
Min Jung Kim,¹ and Eun-Kyung Kim¹

Departments of ¹Radiology and Research Institute of Radiological Science, ²Pathology, and ³Surgery,
Yonsei University College of Medicine, Seoul, Korea.

Received: October 22, 2010

Revised: December 22, 2010

Accepted: December 23, 2010

Corresponding author: Dr. Eun-Kyung Kim,
Department of Radiology and Research
Institute of Radiological Science,
Severance Hospital,
Yonsei University College of Medicine,
50 Yonsei-ro, Seodaemun-gu,
Seoul 120-752, Korea.
Tel: 82-2-2228-7400, Fax: 82-2-393-3035
E-mail: ekkim@yuhs.ac

The authors have no financial conflicts of interest.

Purpose: To compare the cytological results of ultrasound-guided fine-needle aspiration (US-FNA) cytology of thyroid nodules to sonographic findings and determine whether US findings are helpful in the interpretation of cytological results.

Materials and Methods: Among the thyroid nodules that underwent US-FNA cytology, we included the 819 nodules which had a conclusive diagnosis. Final diagnosis was based on pathology from surgery, repeated FNA cytology or follow-up of more than one year. Cytological results were divided into five groups: benign, indeterminate (follicular or Hurthle cell neoplasm), suspicious for malignancy, malignant, and inadequate. US findings were categorized as benign or suspicious. Cytological results and US categories were analyzed. **Results:** Final diagnosis was concluded upon in 819 nodules based on pathology (n=311), repeated FNA cytology (n=204) and follow-up (n=304), of which 634 were benign and 185 were malignant. There were 560 benign nodules, 141 malignant nodules, 49 nodules with inadequate results, 21 with indeterminate results, and 48 that were suspicious for malignancy. The positive and negative predictive values of the US categories were 59.1% and 97.0%, and those of the cytological results were 93.7% and 98.9%. The US categories were significantly correlated with final diagnosis in the benign ($p=0.014$) and suspicious for malignancy ($p<0.001$) cytological result groups, but not in the inadequate and indeterminate cytological results groups. The false positive and negative rates of cytological results were 1.9% and 3.2%. **Conclusion:** Sonographic findings can be useful when used alongside cytological results, especially in nodules with cytological results that are benign or suspicious for malignancy.

Key Words: Thyroid nodule, ultrasonography, fine-needle aspiration, cytology

© Copyright:

Yonsei University College of Medicine 2011

This is an Open Access article distributed under the terms of the Creative Commons Attribution Non-Commercial License (<http://creativecommons.org/licenses/by-nc/3.0>) which permits unrestricted non-commercial use, distribution, and reproduction in any medium, provided the original work is properly cited.

INTRODUCTION

Fine-needle aspiration (FNA) cytology is a widely accepted diagnostic modality for thyroid nodule evaluation¹⁻⁷ and several reports have suggested that ultrasound (US)-guided FNA cytology has many advantages over palpation-guided biopsy.^{5,8}

Real-time US permits needle visualization within the lesion, thereby facilitating an accurate biopsy on small non-palpable nodules. Even with palpable nodules, US-FNA cytology is superior in obtaining adequate tissue for accurate cytological evaluation.^{5,9,10}

However, there are limitations to US-FNA cytology, including results that are categorized as inadequate, indeterminate, or suspicious aspirates. Additionally, false-negative cytological results were reported to be as low as 0-6.2%.¹⁰⁻¹² To date, there have only been a few studies investigating the correlation between cytological results and sonographic classification. The purpose of this study was to compare the cytological results of thyroid nodules to sonographic findings in nodules that have been clinically proven benign by repeated FNA cytology or follow-up, and to determine whether US findings are helpful in the interpretation of cytological results.

MATERIALS AND METHODS

Patients

This retrospective study was approved by the institutional review board. Informed consent was not required. From September 2002 to July 2003, 1048 thyroid nodules in 999 consecutive patients underwent US and US-FNA cytology performed by one radiologist. There were 928 women and 71 men between the ages of 12 and 82 years (mean age: 48 years). Final diagnoses were based not only on pathology from surgery but also repeated FNA cytology or follow-up of more than one year. When there was no change after more than one year of follow-up or the nodule showed the same cytological results after repeated FNA cytology, we designated the nodule as benign. Indeterminate, suspicious for malignancy, or inadequate cytological results were excluded if patients had not undergone an operation.

Sonographic evaluation

Thyroid US was performed by an HDI 3000 or 5000 scanner (Phillips, Bothell, WA, USA) with a 7- to 12-MHz bandwidth transducer. Compound imaging was performed with the HDI 5000 in all cases. Sonographic classification based on sonographic features was performed before FNA cytology by one experienced radiologist. Size was measured as the longest diameter. Sonographic features included echogenicity, margin, calcifications, and shape, based on our previous publication.¹³ Color Doppler imaging was not routinely ob-

tained. Echogenicity was classified as hyperechogenicity, isoechoogenicity, hypoechogenicity, and marked hypoechogenicity. When the echogenicity was similar to thyroid parenchyma, the nodule was classified as isoechoogenic. Marked hypoechogenicity indicated lower echogenicity than the surrounding strap muscle. The margin was characterized as well- or not well-circumscribed (microlobulated/irregular). Calcifications were categorized as microcalcifications, macrocalcifications, mixed calcifications, or none. Microcalcifications were defined as tiny (less than 2 mm in size), punctuate, and hyperechoic foci, either with or without acoustic shadows. Macrocalcifications were defined as larger than 2 mm. Mixed calcifications were defined as a combination of micro- and macrocalcifications. Shape was assessed by the ratio of anteroposterior (A) and transverse (T) diameter ($A/T \geq 1$ or $A/T < 1$). Mixed nodules, composed of both cystic and solid portions, were classified according to the solid portion. Malignant sonographic features were defined as showing marked hypoechogenicity, not well-circumscribed margin, microcalcifications or mixed calcifications, and $A/T \geq 1$. If any single feature suggestive of malignancy was present, the nodule was classified as suspicious. If a nodule had no suspicious features, it was classified as benign.

FNA cytology procedure

Informed consent for the procedure was obtained from all patients. FNA cytology was performed by an experienced radiologist using US guidance. FNA cytology was not done for purely cystic lesions. Immediate specimen adequacy evaluation by a cytopathologist was not conducted. During US-FNA cytology, patients were placed supine with the neck slightly extended. After lesion localization, the neck was prepared in a sterile environment and draped. Local anesthetic was not used. A 23-gauge needle attached to a 20-mL syringe with holder was placed just above the transducer. Under observation, the needle tip was inserted perpendicularly to the neck, seen visibly as a bright spot on the monitor. With mixed nodules, the needle was introduced toward the solid portion. The biopsy was performed with to-and-fro movements; suction was released before the needle was removed. During the procedure, all needle movements were continuously monitored in real time. A minimum of 2 passes were employed. Aspirated material was placed, smeared, and fixed on glass slides and stained with Papanicolaou and Giemsa stain. Flushed material was placed in sterile normal saline for cell block.

Cytological and pathological evaluation

Cytology was interpreted by five cytopathologists and the results were reported as adequate or inadequate. A specimen was considered adequate if there were a minimum of six groupings of well-preserved thyroid cells, consisting of at least 10 cells per group.¹⁴ Specimens were diagnosed as benign, indeterminate (follicular or Hurthle cell neoplasm), suspicious for malignancy, or malignant. Benign cytology included colloid nodules, adenomatous hyperplasia, lymphocytic thyroiditis, Graves’ disease, and postpartum thyroiditis. The interpretation of “suspicious for malignancy” on cytology was defined when the specimen manifested varying cytological abnormalities associated with papillary carcinoma such as nuclear membrane irregularity, nucleolar abnormality, abnormal nucleus-to-cytoplasm ratio, but did not fulfill the criteria for a diagnosis of papillary carcinoma. Pathological results were recorded as benign or malignant in the medical records. Malignant results included papillary, follicular, medullary and undifferentiated thyroid carcinoma.

Follow-up after FNA cytology

On principle, we recommended operation in cases where the cytological results are malignant, suspicious for malignancy, or indeterminate. We also recommended follow-up FNA cytology for cases with inadequate cytology and follow-up US for those with benign cytology. Therefore, we retrospectively reviewed the medical records of follow-up FNA cytology or US results in patients who did not undergo operation. When the cytological results from repeated FNA cytology were benign, these nodules were included in the final diagnosis, and

when the cytologically proven benign nodules showed no change on follow-up US after more than a year, they were also included in the ultimately benign group.

Statistical analysis

Sonographic findings were analyzed according to cytological results in cases with final diagnoses. The positive predictive value (PPV), negative predictive value (NPV) and accuracy of US categories and cytological results were calculated. Only benign, suspicious for malignancy and malignant cytological results were included in these analyses; inadequate and indeterminate cases were excluded. The mean sizes of benign and malignant nodules were compared using a t-test. In each cytological results group, US categories and final diagnoses were compared using Fisher’s exact test. Statistically significant differences were defined as those with *p*-values of less than 0.05, and analyses were performed using the Statistical Package for the Social Sciences (SPSS, version 18; SPSS, Chicago, IL, USA).

RESULTS

Fig. 1. shows the schematic flow of this study and final diagnosis. Among the 1,048 thyroid nodules underwent FNA cytology, final diagnoses were concluded in 819 nodules based on pathology from surgery (n=311), repeated FNA cytology (n=204) or follow-up of over a year (n=304). There were 634 (77.4%) benign (35 male and 599 female; age 12-79 years old) and 185 (22.6%) malignant (14 male and 171

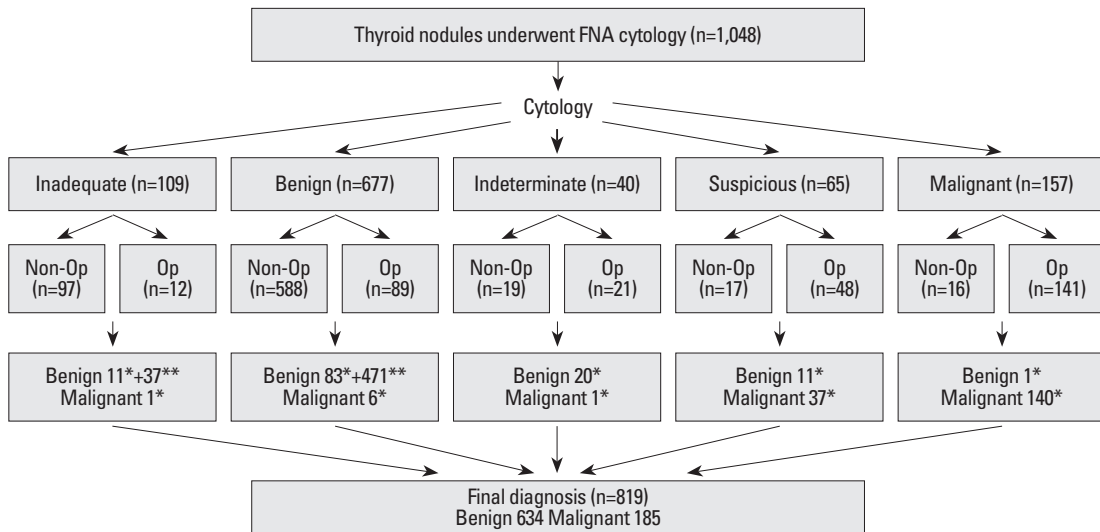


Fig. 1. Final diagnosis of the study population. FNA, fine-needle aspiration; Op, operation; NIC, no interval change. *from operation, **from repeated FNA cytology or NIC.

female; age 19-77 years old) thyroid nodules. The malignant results were: papillary thyroid carcinoma in 183 cases (including two follicular variants), medullary carcinoma in one, and minimally invasive follicular carcinoma in one. The mean size was larger in benign nodules [18.3 mm, (3-100)] than in malignant nodules [11.8 mm (3-52)] ($p<0.001$). The analysis of US categories and the final diagnoses according to the cytological results are summarized in Table 1.

The PPV, NPV and accuracy of the US categories using cytological results as the gold standard were 60.9%, 95.6% and 82.8%. When using the final diagnosis as the gold standard, the PPV, NPV and accuracy of the US categories were 59.1%, 97.0% and 83.8%, and those of the cytological results were 93.7%, 98.9% and 97.6%. When only histological results were considered as the gold standard, the accuracy of cytological results dropped to 34.7%.

Among the 560 nodules with benign cytological results,

there were fewer malignant nodules (2/452, 0.4%) in the benign US category, while there were more malignant nodules (4/108, 3.7%) in the suspicious US category ($p=0.014$) (Fig. 2). The US categories were also correlated with final diagnosis in the suspicious for malignancy cytological results group ($p<0.001$). Among 48 nodules with suspicious cytological results, 91.7% (33) of the 36 nodules in the suspicious US category turned out to be malignant, and 33.3% (4) of the 12 in the benign US category were found to be malignant (Fig. 3). However, US categories were not definitely correlated with final diagnosis in the inadequate, indeterminate and malignant cytological result groups (Table 1). In the benign cytological result group, two nodules (2/560, 0.4%) turned out to be malignant even though the US findings were also benign. The false negative rate of the cytological result was 3.2% (6/185). Among those with suspicious for malignancy or malignant cytological results, four nodules

Table 1. US Categories and Final Diagnoses According to Cytological Results

Cytological results	US categories	Mean size (range, mm)	Final diagnosis		
			Benign (%)	Malignant (%)	<i>p</i> value*
Inadequate (n=49)	Benign (n=40)	20.1 (5-43)	40 (83.3)	0	0.184
	Suspicious (n=9)	9.2 (4-15)	8 (16.7)	1	
Benign (n=560)	Benign (n=452)	19.1 (3-100)	450 (81.2)	2 (33.3)	0.014
	Suspicious (n=108)	13.5 (3-60)	104 (18.8)	4 (66.7)	
Indeterminate (n=21)	Benign (n=20)	26.1 (12-70)	19 (95)	1	1.000
	Suspicious (n=1)	6	1 (5)	0	
Suspicious for malignancy (n=48)	Benign (n=12)	14.9 (5-40)	8 (72.7)	4 (10.8)	<0.001
	Suspicious (n=36)	9.3 (3-34)	3 (27.3)	33 (89.2)	
Malignant (n=141)	Benign (n=9)	18.4 (4-33)	0	9 (6.4)	1.000
	Suspicious (n=132)	11.9 (3-52)	1	131 (93.6)	

*from Fisher's exact test.

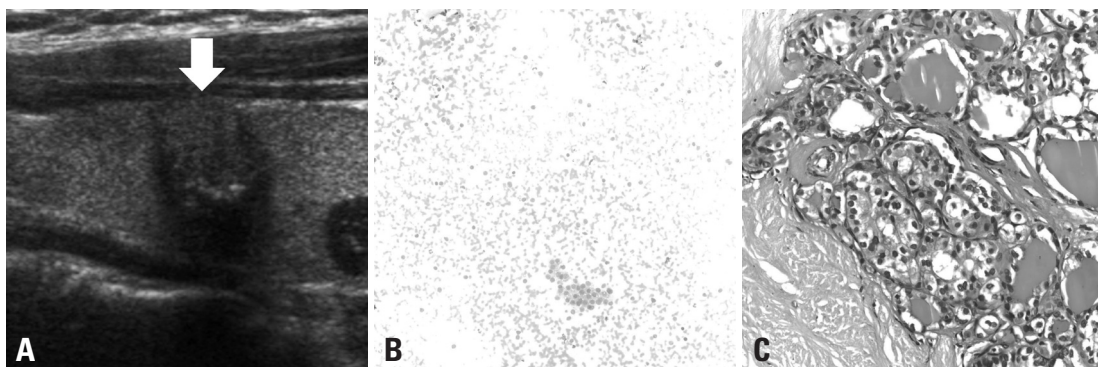


Fig. 2. A 50-year-old female with papillary thyroid carcinoma. (A) Ultrasonography shows well-circumscribed and isoechoic nodule (arrow) with a shape that is taller than it is wide and internal microcalcification in the thyroid gland; this nodule was considered suspicious. (B) Fine-needle aspiration cytology was interpreted as adenomatous hyperplasia based on the presence of flat sheets of follicular cells in the bloody background (Giemsa stain $\times 200$ original magnification). Because of the discordant results between the sonographic findings and the cytological results, surgical excision was performed. (C) Thyroidectomy specimen shows a typical papillary carcinoma nucleus with a few grooves, clearing and pseudoinclusions, compatible with papillary thyroid carcinoma (hematoxylin and eosin (H&E) $\times 400$ original magnification).

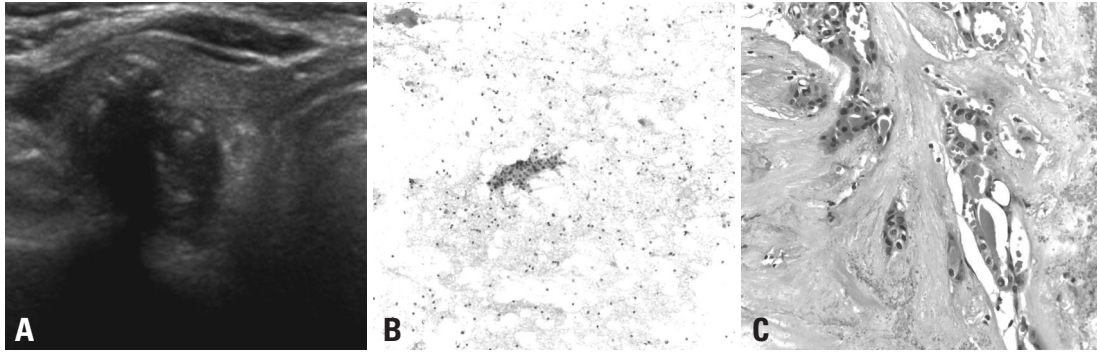


Fig. 3. A 61-year-old female with papillary thyroid carcinoma. (A) Ultrasonography shows an irregular and marked hypoechoic nodule with a shape that is taller than it is wide and internal mixed calcification in the right thyroid gland; this nodule was considered suspicious. (B) This fine-needle aspiration cytology was interpreted as suspicious for papillary thyroid carcinoma based on the presence of a rare cluster of follicular cells cytological overlapping and nuclear clearing and grooves (Papanicolaou stain $\times 200$ original magnification). (C) This thyroidectomy specimen shows a few papillae with typical nuclear features of papillary carcinoma, such as nuclear pseudo-inclusion, clearing and grooves, compatible with papillary carcinoma (H&E, $\times 400$ original magnification).

(4/189, 2.1%) were ultimately benign even though the US findings were also suspicious. The false positive rate of the cytological results was 1.9% (12/634).

DISCUSSION

FNA cytology is the most accurate and cost-effective method of evaluating thyroid nodules, although ongoing research is being done on variable methods including genetic studies.¹⁵⁻¹⁷ In recent studies, the sensitivity, specificity and accuracy of FNA cytology have been reported as 76-98%, 71-100%, and 69-97%, respectively.^{8,10-12,18-25} However, thyroid FNA cytology has some limitations in cases of suspicious, inadequate, and indeterminate cytology. In addition, there are false-positive and false-negative results. Therefore, another method is needed to compensate for these limits, and we hypothesized that US could provide useful additional information.

In considering the cytological results that are suspicious for malignancy, the sonographic findings were significantly correlated with final diagnosis in our study ($p < 0.001$), which has also been revealed in previous reports.^{26,27} Therefore, US features of nodules with suspicious cytological results are useful in planning the extent of surgery. If US findings suggest benign results, an intra-operative frozen section is needed and if suspicious, positive operation should be considered with informed consent for surgery.²⁸

Inadequate cytological results are also problematic. In 2007, the British Thyroid Association and Royal College of Physicians suggested that FNA cytology should be repeated in cases of inadequate cytology.²⁹ With US guidance, the rate of inadequacy has been decreased, but it is still unavoidable.

The rate is reported to be 6.4-23% in US-FNA cytology,^{8,10} and it was 10.4% (109/1,048) in our study. Only 1 out of 49 (2%) was malignant on pathology, and it showed suspicious sonographic findings (Table 1). However, the correlation between sonographic findings and pathologic results could not be evaluated because of the small number of malignant results ($n=1$). A prospective study with more patients is needed to resolve this issue.

In considering indeterminate cytology, there have been several attempts to make definite clinical or imaging parameters for identifying patients at higher risk of malignancy among follicular neoplasms on cytology, but none of these parameters have proved satisfactory.³⁰⁻³² As in our study, sonographic findings are not helpful in these cases. There was only one malignancy (invasive follicular carcinoma) out of 21 indeterminate cytological results in our study, and it was interpreted as benign on the preoperative US evaluation. However, the correlation between sonographic findings and pathologic results also cannot be evaluated in this group because of the small number of malignant results.

To reduce the occurrence of false-negative results, imaging analysis is also important in benign cytological results. Our study showed that, even in benign cytology results, there was more malignancy in the suspicious US group than in the benign US group (3.7% vs. 0.4%; $p=0.014$). Therefore, even if the cytological results are benign, US findings should be considered for patient management. Repeated FNA cytology is recommended in cases with suspicious sonographic findings, even when benign cytological results are obtained.

Our study has several limitations. First, we excluded cases that were not pathologically proven and that had indeterminate ($n=19$) and suspicious ($n=17$) cytological results.

These made up a relatively large portion of each cytological result category [47.5% (19/40) of the indeterminate group and 27.4% (17/65) of the suspicious group]. This may have caused a selection bias. The second limitation is that we included nodules that were not pathologically proven and that had inadequate (n=37) and benign (n=471) cytological results. In clinical situations, a large number of thyroid nodules are benign and almost none of these nodules undergo operation. When a thyroid nodule is diagnosed as benign, it requires follow-up or repeated FNA cytology because of a low (but not negligible) false-negative rate of up to 5% with FNA cytology.^{33,34} Our study also showed a 3.2% false-negative rate. Therefore, we may have included malignant nodules that were considered to be benign in our study as a false-negative case. The repeated benign cytological results (n=167) can be accepted as benign with a less than 1% false negative rate. However, benign cytological results (n=37) on repeated FNA cytology from inadequate cytological results may be controversial. Also, the follow-up duration was not long enough to exclude differentiated thyroid carcinoma. In clinical practice, all cases with benign cytological results on repeated FNA cytology or no interval change on follow-up US are not operated upon; a study including these data may be more realistic. However, additional study is needed regarding the results of repeated FNA cytology and follow-up US results in the long-term.

In conclusion, sonographic findings can be useful when used alongside cytology in the overall assessment of thyroid nodules and their likelihood of malignancy. If the nodule that is suspicious for malignancy on cytology also has suspicious findings on US, it is highly likely that it is malignant. In addition, if a cytologically benign nodule shows suspicious sonographic findings, repeated FNA cytology is recommended.

REFERENCES

1. Nguyen GK, Lee MW, Ginsberg J, Wrapp T, Bilodeau D. Fine-needle aspiration of the thyroid: an overview. *Cytojournal* 2005;2:12.
2. Mazzaferri EL, de los Santos ET, Rofagha-Keyhani S. Solitary thyroid nodule: diagnosis and management. *Med Clin North Am* 1988;72:1177-211.
3. Gharib H, Goellner JR. Fine-needle aspiration biopsy of the thyroid: an appraisal. *Ann Intern Med* 1993;118:282-9.
4. Kelly NP, Lim JC, DeJong S, Harmath C, Dudiak C, Wojcik EM. Specimen adequacy and diagnostic specificity of ultrasound-guided fine needle aspirations of nonpalpable thyroid nodules. *Diagn Cytopathol* 2006;34:188-90.
5. Cesur M, Corapcioglu D, Bulut S, Gursoy A, Yilmaz AE, Erdogan N, et al. Comparison of palpation-guided fine-needle aspiration biopsy to ultrasound-guided fine-needle aspiration biopsy in the evaluation of thyroid nodules. *Thyroid* 2006;16:555-61.
6. Khalid AN, Hollenbeak CS, Quraishi SA, Fan CY, Stack BC Jr. The cost-effectiveness of iodine 131 scintigraphy, ultrasonography, and fine-needle aspiration biopsy in the initial diagnosis of solitary thyroid nodules. *Arch Otolaryngol Head Neck Surg* 2006;132:244-50.
7. Bellantone R, Lombardi CP, Raffaelli M, Traini E, De Crea C, Rossi ED, et al. Management of cystic or predominantly cystic thyroid nodules: the role of ultrasound-guided fine-needle aspiration biopsy. *Thyroid* 2004;14:43-7.
8. Cai XJ, Valiyaparambath N, Nixon P, Waghorn A, Giles T, Helliwell T. Ultrasound-guided fine needle aspiration cytology in the diagnosis and management of thyroid nodules. *Cytopathology* 2006;17:251-6.
9. Yokozawa T, Fukata S, Kuma K, Matsuzuka F, Kobayashi A, Hirai K, et al. Thyroid cancer detected by ultrasound-guided fine-needle aspiration biopsy. *World J Surg* 1996;20:848-53.
10. Mittendorf EA, Tamarin SW, McHenry CR. The results of ultrasound-guided fine-needle aspiration biopsy for evaluation of nodular thyroid disease. *Surgery* 2002;132:648-53.
11. Sangalli G, Serio G, Zampatti C, Bellotti M, Lomuscio G. Fine needle aspiration cytology of the thyroid: a comparison of 5469 cytological and final histological diagnoses. *Cytopathology* 2006;17:245-50.
12. Wu HH, Jones JN, Osman J. Fine-needle aspiration cytology of the thyroid: ten years experience in a community teaching hospital. *Diagn Cytopathol* 2006;34:93-6.
13. Kim EK, Park CS, Chung WY, Oh KK, Kim DI, Lee JT, et al. New sonographic criteria for recommending fine-needle aspiration biopsy of nonpalpable solid nodules of the thyroid. *AJR Am J Roentgenol* 2002;178:687-91.
14. Gharib H, Papini E, Valcavi R, Baskin HJ, Crescenzi A, Dottorini ME, et al. American Association of Clinical Endocrinologists and Associazione Medici Endocrinologi medical guidelines for clinical practice for the diagnosis and management of thyroid nodules. *Endocr Pract* 2006;12:63-102.
15. Lee KY, Huang SM, Li S, Kim JM. Identification of differentially expressed genes in papillary thyroid cancers. *Yonsei Med J* 2009;50:60-7.
16. Akdi A, Perez G, Pastor S, Castell J, Biarnes J, Marcos R, et al. Common variants of the thyroglobulin gene are associated with differentiated thyroid cancer risk. *Thyroid* 2011;21:519-25.
17. Murugan AK, Xing M. Anaplastic Thyroid Cancers Harbor Novel Oncogenic Mutations of the ALK Gene. *Cancer Res* 2011;71:4403-11.
18. Serna de la Saravia C, Cuellar F, Saravio Day E, Harach HR. Accuracy of aspiration cytology in thyroid cancer: a study in 1 institution. *Acta Cytol* 2006;50:384-7.
19. Sahin M, Sengul A, Berki Z, Tutuncu NB, Guvener ND. Ultrasound-guided fine-needle aspiration biopsy and ultrasonographic features of infracentimetric nodules in patients with nodular goiter: correlation with pathological findings. *Endocr Pathol* 2006;17:67-74.
20. Zagorianakou P, Malamou-Mitsi V, Zagorianakou N, Stefanou D, Tsatsoulis A, Agnantis NJ. The role of fine-needle aspiration biopsy in the management of patients with thyroid nodules. *In Vivo* 2005;19:605-9.

21. Sclabas GM, Staerkel GA, Shapiro SE, Fornage BD, Sherman SI, Vassilopoulos-Sellin R, et al. Fine-needle aspiration of the thyroid and correlation with histopathology in a contemporary series of 240 patients. *Am J Surg* 2003;186:702-9.
22. Ogawa Y, Kato Y, Ikeda K, Aya M, Ogisawa K, Kitani K, et al. The value of ultrasound-guided fine-needle aspiration cytology for thyroid nodules: an assessment of its diagnostic potential and pitfalls. *Surg Today* 2001;31:97-101.
23. Kessler A, Gavriel H, Zahav S, Vaiman M, Shlamkovitch N, Segal S, et al. Accuracy and consistency of fine-needle aspiration biopsy in the diagnosis and management of solitary thyroid nodules. *Isr Med Assoc J* 2005;7:371-3.
24. Blanco Carrera C, Garcia-Diaz JD, Maqueda Villaizan E, Martinez-Onsurbe P, Pelaez Torres N, Saavedra Vallejo P. [Diagnostic efficacy of fine needle aspiration biopsy in patients with thyroid nodular disease. Analysis of 510 cases]. *Rev Clin Esp* 2005;205:374-8.
25. Kim MJ, Kim EK, Park SI, Kim BM, Kwak JY, Kim SJ, et al. US-guided fine-needle aspiration of thyroid nodules: indications, techniques, results. *Radiographics* 2008;28:1869-86.
26. Kwak JY, Kim EK, Kim MJ, Hong SW, Choi SH, Son EJ, et al. The role of ultrasound in thyroid nodules with a cytology reading of "suspicious for papillary thyroid carcinoma". *Thyroid* 2008;18:517-22.
27. Kwak JY, Kim EK, Kim HJ, Kim MJ, Son EJ, Moon HJ. How to combine ultrasound and cytological information in decision making about thyroid nodules. *Eur Radiol* 2009;19:1923-31.
28. Moon HJ, Kwak JY, Kim EK, Kim MJ, Park CS, Chung WY, et al. The combined role of ultrasound and frozen section in surgical management of thyroid nodules read as suspicious for papillary thyroid carcinoma on fine needle aspiration biopsy: a retrospective study. *World J Surg* 2009;33:950-7.
29. BTA/RCP. Guidelines for the management of thyroid cancer. 2nd ed. London: The Lavenham Press; 2007.
30. Baloch ZW, Fleisher S, LiVolsi VA, Gupta PK. Diagnosis of "follicular neoplasm": a gray zone in thyroid fine-needle aspiration cytology. *Diagn Cytopathol* 2002;26:41-4.
31. Rago T, Di Coscio G, Basolo F, Scutari M, Elisei R, Berti P, et al. Combined clinical, thyroid ultrasound and cytological features help to predict thyroid malignancy in follicular and Hupsilonrthle cell thyroid lesions: results from a series of 505 consecutive patients. *Clin Endocrinol (Oxf)* 2007;66:13-20.
32. Choi YJ, Yun JS, Kim DH. Clinical and ultrasound features of cytology diagnosed follicular neoplasm. *Endocr J* 2009;56:383-9.
33. Ylagan LR, Farkas T, Dehner LP. Fine needle aspiration of the thyroid: a cytohistologic correlation and study of discrepant cases. *Thyroid* 2004;14:35-41.
34. Carmeci C, Jeffrey RB, McDougall IR, Nowels KW, Weigel RJ. Ultrasound-guided fine-needle aspiration biopsy of thyroid masses. *Thyroid* 1998;8:283-9.