

복강경 수술 환자의 백혈구 분포 및 자궁 부속기 종양 크기에 따른 악성 가능성 예측

연세대학교 의과대학 강남세브란스병원 산부인과¹, 세브란스병원 산부인과², 용인세브란스병원 산부인과³
최보람¹ · 홍 연¹ · 백정혜¹ · 허지수¹ · 장민영¹ · 전영은¹ · 이경은¹ · 임경진² ·
양효인² · 최영식² · 김혜연³ · 서석교² · 조시현¹ · 이병석¹

= Abstract =

White blood cell differential count and adnexal mass size may predict potential malignancies in laparoscopic surgery

Bo Ram Choi, M.D.¹, Yeon Hong, M.D.¹, Jeong Hye Baek, M.D.¹, Ji Su Huh, M.D.¹, Min Young Jang, M.D.¹,
Young Eun Jeun, M.D.¹, Kyoung Eun Lee, M.D.¹, Kyung Jin Lim, M.D.², Hyo In Yang, M.D.²,
Young Sik Choi, M.D.², Hye Yeon Kim, M.D.³, Seok Kyo Seo, M.D.², SiHyun Cho, M.D.¹, Byung Seok Lee, M.D.¹

¹Department of Obstetrics and Gynecology, Gangnam Severance Hospital,

²Department of Obstetrics and Gynecology, Severance Hospital, Yonsei University College of Medicine, Seoul,

³Department of Obstetrics and Gynecology, Yongin Severance Hospital, Yongin, Korea

Objective: We investigated the clinical value of using preoperative differential white blood cell (WBC) count to predict the potential for malignancy of adnexal masses in laparoscopic surgery.

Methods: The electronic medical records of 1325 patients who underwent laparoscopic surgery for adnexal masses between July 2005 and December 2008 were analyzed retrospectively.

Results: Of 1325 patients, 30 (2.3%) had adnexal masses with malignant potential. Analysis of differential WBC count, neutrophil to lymphocyte ratio (NLR), neutrophil to monocyte ratio (NMR), serum CA 125, mass size showed that only cyst size was significantly different between patients with potentially malignant adnexal masses, those with benign disease (averages of 9.45 cm vs. 6.23 cm, $p=0.001$). Further analysis was performed using a combination of various markers and multiplication of cyst size and NMR yielded the highest area under the curve, at 0.711(95% confidential interval 0.619~0.806, $p<0.001$), with a sensitivity and specificity of 86.7% and 48.3% respectively, at a cut off value of 67.23. These values were also significantly different between patients with potentially malignant adnexal masses, and dermoid cyst or endometrioma ($p=0.038$ and 0.002 respectively, by analysis of variance, post hoc test).

Conclusion: Preoperative measurement of NMR in conjunction with cyst size may be used as a simple, non invasive marker for predicting the malignant potential of adnexal masses before laparoscopic surgery.

KEY WORDS: Laparoscopy, Adnexal masses, Malignant potential, WBC differential, Size

접 수 일 2011년 1월 28일
게재허가일 2011년 2월 14일
교신저자 조시현

*Acknowledgements: This research was supported by New Faculty Research Grant from Yonsei University, College of Medicine, Seoul, Korea (6-2009-0093).

Introduction

Operative laparoscopy has become the gold standard treatment for several benign gynecological conditions. Compared to laparotomy, laparoscopy is associated with less postoperative pain, shorter hospital stay, and more rapid return to normal activity.¹⁾ Although the safety and effectiveness of laparoscopic management has been well established for small- and moderate-sized ovarian cysts, the use of laparoscopic surgery for treatment of adnexal mass remains controversial because of the possibility of discovering an unexpected ovarian malignancy during surgery.²⁻⁶⁾ Since spillage of tumor or cystic contents is common during laparoscopic surgery, and is thought to be an important prognostic factor for malignancy, appropriate patient selection is critical.⁵⁾ Although subjective evaluation of transvaginal sonography and color Doppler images of adnexal masses has shown to be a fairly good method for discriminating between benign and malignant adnexal masses, it depends on the experience of sonologists, and the diagnostic accuracy of borderline ovarian tumors is lower even by an experienced sonologist.⁷⁻¹¹⁾ Preoperative assessment of adnexal masses by serum tumor markers would be more feasible and objective method, however, none of serologic markers has not yet reached an adequate level of accuracy.

Recently, the role of the immune system in disease cessation or progression has been examined, and hematological markers such as white blood cells (WBCs) and neutrophil-to-lymphocyte ratio (NLR) have been proposed as diagnostic or prognostic factors for a variety of cancers, including ovarian cancer.¹²⁻¹⁵⁾ However, use of these simple hematologic markers for correctly identifying the risk of malignant adnexal tumors, and selecting low risk tumors for laparoscopic surgery has not yet been assessed. Therefore, the aim of this study was to evaluate differential WBC counts in patients with adnexal masses managed laparoscopically, and to investigate which markers, either alone or in combination with other clinical markers, can

be used to identify potentially malignant adnexal masses before laparoscopic surgery.

Materials and Methods

We conducted a retrospective review of the electronic medical records of 1325 patients who underwent elective laparoscopic surgery for adnexal masses, with subsequent pathological evaluation, between July 2005 and December 2008. This study was approved by the ethics committee of Gangnam Severance Hospital, and Institutional Review Board approval was obtained.

Of 1325 patients, 1295 patients had pathologically confirmed benign adnexal masses. Of these, 667 patients (50.3%) had endometriosis, 370 (27.9%) had dermoid cysts, 116 (8.8%) had serous cystadenoma and 141 patients (10.6%) had mucinous cystadenoma. Potentially malignant adnexal masses were pathologically confirmed for 30 patients (2.3%), including 27 cases of borderline ovarian tumor and three cases of ovarian cancer. Of the 27 patients with borderline ovarian tumors, 14 were diagnosed with a mucinous tumor and 10 with a serous tumor. The remaining three included one case of mixed germ cell tumor, one case of ovarian steroid cell tumor, and one case of granulosa cell tumor. The three cases of ovarian cancer included one case of endometrioid adenocarcinoma, one case of papillary serous ovarian cancer, and one case of mucinous cystadenocarcinoma.

Differential WBC counts and CA-125 levels were recorded from full blood counts routinely performed the day before surgery. Differential WBC counts were analyzed by an ADVIA 120/2120 Hematology system (Bayer HealthCare, Diagnostics Division, Tarrytown, NY, USA), and serum CA-125 levels were measured with CA125 II ECLIA (electrochemiluminescence immunoassay) on a Roche/Hitachi Modular Analytics E170 (Roche Diagnostics, Tokyo, Japan). WBC differential count and serum CA-125 levels were ex-

pressed as the mean±standard deviation of each group. The neutrophil-to-lymphocyte ratio (NLR) was defined as the absolute neutrophil count divided by the absolute lymphocyte count and the neutrophil-to-monocyte ratio (NMR) was defined as absolute neutrophil count divided by the absolute monocyte count. Tumor size was calculated and recorded by maximum diameter in centimeters, and expressed as the mean±standard deviation, from either a preoperative ultrasound examination and/or abdominal and pelvic computed tomography scan.

The differences in means between groups were compared using one-way analysis of variance, *post-hoc* tests, or Student's *t*-test, where appropriate. The sensitivity and specificity of each marker was assessed using receiver operating characteristic (ROC) curves.¹⁶⁾ The area under the ROC curve was calculated as a measure of the ability of each potential marker to discriminate between potentially malignant adnexal masses and healthy controls. An area under the curve (AUC) of 0.5 indicated classifications assigned by chance. ROC were plotted to find the optimal cutoff values for maximum sensi-

tivity and specificity. The SPSS 12.0 package (SPSS Inc, Chicago, IL, USA) was used for statistical analysis and $p < 0.05$ was considered to be statistically significant.

Results

The clinical characteristics of the study subjects are shown in Table 1. The overall mean age of the participants was 34.97±10.97. The mean age of patients with benign adnexal masses was 34.92±10.92 years, and the mean age of patients with potentially malignant adnexal masses was 37.13±13.01 years. No significant differences in clinical characteristics were noted between the two groups, except for adnexal mass size, with the mean size of potentially malignant adnexal masses significantly higher than that of benign tumors (9.45±4.88 cm vs. 6.35±3.28 cm, $p=0.001$).

Mean WBC differential counts are shown in Table 2. Neutrophil counts increased, and lymphocyte and the monocyte counts decreased in patients with potentially malignant adnexal masses compared to patients with benign adnexal

Table 1. Clinical characteristics of patients

	Benign adnexal mass (n=1295)	Potentially malignant adnexal mass (n=30)	<i>p</i> -value
Age	34.92±10.92	37.13±13.01	0.274
Gravidarum	1.61±3.35	2.10±2.17	0.427
Parity	0.89±2.97	1.22±1.34	0.533
Size of the mass (cm)	6.35±3.28	9.45±4.88	0.001

Values are expressed as mean±standard deviation.

Table 2. Mean and area under the receiver operating characteristic curves (AUC) of differential WBC counts, combined markers and serum CA-125 by study group

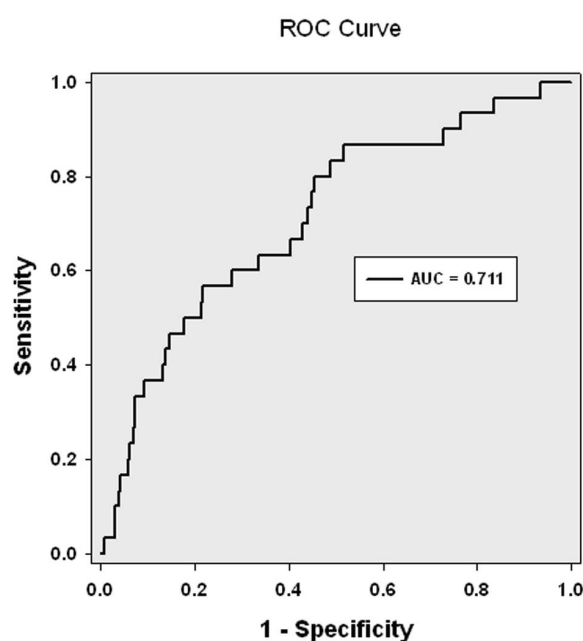
	Benign adnexal mass (n=1295)	Adnexal mass of malignant potentials (n=30)	<i>p</i> -value	AUC (95% CI)
WBC	6452.70±2024.28	6880.67±2747.02	0.257	0.526 (0.424~0.629)
Neutrophil	3934.35±1831.88	4418.00±2805.97	0.355	0.523 (0.418~0.628)
Lymphocyte	1961.88±662.33	1898.09±518.96	0.601	0.495 (0.391~0.600)
Monocyte	309.47±116.76	299.94±91.89	0.657	0.497 (0.396~0.599)
Eosinophil	135.52±134.05	141.29±112.41	0.815	0.557 (0.465~0.649)
Basophil	33.78±27.85	35.00±18.98	0.812	0.564 (0.481~0.649)
CA-125 (IU/mL)	43.42±97.86	41.97±48.49	0.935	0.530 (0.440~0.619)
NLR	2.26±1.63	2.65±2.51	0.407	0.532 (0.430~0.649)
NMR	13.67±7.16	14.94±6.75	0.338	0.564 (0.459~0.669)

Values are expressed as mean±standard deviation; CI, confidence interval; NLR, neutrophil-to-lymphocyte ratio; NMR, neutrophil-to-monocyte ratio.

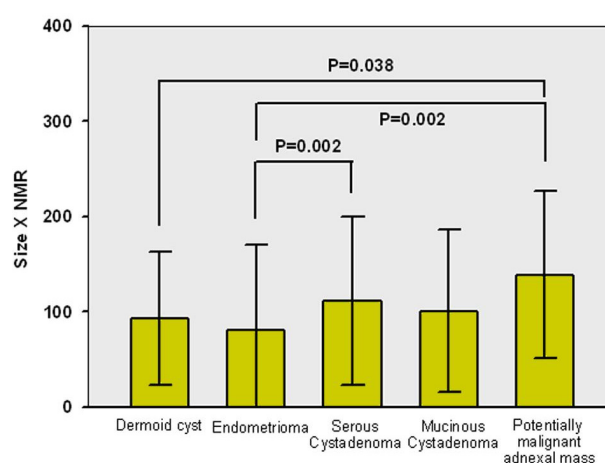
Table 3. Diagnostic sensitivity and specificity of mass size multiplied by WBC differentials, serum CA-125 and combined markers in patients with potentially malignant adnexal masses

	AUC (95% CI)	Sensitivity (%)	Specificity (%)	Cutoff value	p-value
WBC	0.450 (0.313~0.587)	10.0	92.7	64540.00	0.474
Neutrophil	0.680 (0.574~0.786)	50.0	86.4	40247.24	0.001
Eosinophil	0.644 (0.552~0.736)	50.0	73.9	1001.13	0.007
Basophil	0.679 (0.592~0.767)	50.0	77.9	278.75	0.001
CA-125 (IU/mL)	0.692 (0.612~0.771)	76.7	49.9	146.80	<0.001
NLR	0.685 (0.590~0.779)	53.3	79.6	19.10	0.001
NMR	0.711 (0.619~0.806)	86.7	48.3	67.23	<0.001

CI, confidence interval; NLR, neutrophil-to-lymphocyte ratio; NMR, neutrophil-to-monocyte ratio.

**Fig. 1.** Receiver operating characteristic curves of cyst size multiplied by neutrophil-to-monocyte ratio. Differential diagnosis between patients with benign adnexal masses excluding endometriomas and adnexal masses with malignant potentials is shown.

masses, but the differences were not significant. Serum CA-125 was also not significantly different between the groups. Both NLR and NMR showed higher values in patients with potentially malignant adnexal masses, although differences were not significant. To compare the predictive usefulness of differential WBC counts, serum CA-125, NLR and NMR, we examined ROC curves. Basophil counts and NMR showed the highest AUC, with 0.564 (Table 2). Since no single marker displayed a sufficient AUC, and since only cyst size showed significant differences between the two patient

**Fig. 2.** Mean values of cyst size multiplied by neutrophil-to-monocyte ratio (NMR) by study group. The values were significantly higher for adnexal masses with malignant potential, than for dermoid cysts and endometrioma, by ANOVA and post-hoc test.

groups, we decided to use a combination marker that included cyst size. Markers with an AUC above 0.5 were multiplied by cyst size, and the ROC was reevaluated for each marker (Table 3). The combination of NMR and cyst size showed the highest AUC, at 0.711 (95% confidence interval of 0.619~0.806), with a sensitivity of 86.7% and specificity of 48.3% at a cut-off value of 67.23, with $p < 0.001$ (Table 3, Fig. 1). Positive and negative predictive values were 3.7% and 99.4% respectively. The combination of basophil count and cyst size showed an AUC of 0.679 (95% confidence interval of 0.592~0.767) with a sensitivity of 50.0% and specificity of 77.9%, at a cut-off value of 278.75. Positive and negative predictive values were 5.0% and 98.5% respectively. The sensitivity of serum CA-125 multiplied by cyst size was 76.7% and

specificity was 49.9%, at a the cutoff value of 146.80. Positive and negative predictive values were 3.8% and 98.8% respectively.

The combined value of NMR and cyst size was further evaluated according to adnexal mass histological type. The mean combined values were 92.59±9.90 for dermoid cyst, 80.03±89.71 for endometrioma, 111.37±88.17 for serous cystadenoma, 100.39±85.31 for mucinous cystadenoma, and 138.82±87.34 for adnexal mass (Fig. 2). Differences between groups were statistically significant ($p<0.001$ using analysis of variance). Post-hoc tests discriminated between the observed differences, showing that the combined value was significantly higher for adnexal masses with malignant potential than for dermoid cysts or endometrioma ($p=0.038$ and $p=0.002$, respectively), while the serous cystadenoma group showed a significantly higher level than the endometrioma group ($p=0.002$).

Discussion

In this retrospective review of patients with adnexal masses managed laparoscopically, we demonstrated that a combined marker of NMR and the cyst size was significantly increased in patients with potentially malignant adnexal masses, and that this marker had a sensitivity of 86.7% and a specificity of 48.3%, at a cutoff value of 67.23.

Although operative laparoscopy is the gold standard for treating adnexal masses because of technical and surgical progress, treating ovarian tumors laproscopically remains controversial, because of concern about discovering an unrecognized ovarian malignancy or tumor spillage, either of which lead to an inability to proceed with an immediate staging laparotomy, and a delay in treatment. While laparotomy with a longitudinal median incision is advocated ovarian cancer patients to ensure adequate surgical staging and removal of all obvious tumor sites, some studies indicated the feasibility

and effectiveness of laparoscopic management of borderline ovarian tumors, since most patients with these tumors have an excellent prognosis.^{17,18)} However, even in borderline ovarian tumors, proper staging is important, as the cornerstone of correct treatment. Proper staging can be achieved only by performing a midline laparotomy and exploring the complete abdominal cavity for extraovarian implants.¹⁹⁾ In any case, an accurate preoperative diagnosis appears to be the best approach, in which the patient is referred to an oncological surgeon, and laparotomy is used only when necessary.

The value of preoperative ultrasound examination for selecting women with adnexal masses for laparoscopic surgery has been examined, and preoperative ultrasound assessment predicted the successful outcome of laparoscopic surgery with a sensitivity of 98% and a specificity of 79%.⁷⁾ However, the accuracy of ultrasound is dependent on operator skill and subjective assessment.²⁰⁾ Also, a retrospective evaluation of 21 possible prognostic models to distinguish benign from malignant adnexal masses showed that for any model, diagnostic performance is much lower when used by investigators other than the initiators.²¹⁾ Pattern recognition for preoperative ultrasound diagnosis of borderline ovarian tumors is difficult, leading to fairly high specificity, but a failure to see typical features in one third of cases, which are typically misdiagnosed as benign.¹⁰⁾

Use of serological markers for preoperative detection of adnexal masses with malignant potential before laparoscopic surgery would ideally be more objective. However, no single marker, including serum CA-125, has shown sufficient sensitivity and specificity to be used for early detection of ovarian cancer. Recent studies focus on using serum tumor markers in combination with serum CA-125. These combined markers have increased sensitivity and specificity.²²⁾ Therefore, in this study, we evaluated combinations of preoperative differential WBC count, serum CA-125 levels, and cyst size, to see if combined markers could predict the malignant potential of adnexal

masses before laparoscopic surgery.

Inflammatory cells can both suppress and stimulate tumor growth, and WBC differential count is a diagnostic and prognostic indicator for various cancers including ovarian cancers.¹²⁻¹⁵⁾ In contrast to previous works on ovarian cancer, neutrophilia accompanied by relative lymphocytopenia was not prominent in our study,^{14,15)} probably because most of the adnexal masses with malignant potential in our study were borderline ovarian tumors with low potential for malignancy, and a majority of the benign cysts included endometrioma, which were associated with increased NLR.²³⁾ Instead, neutrophilia accompanied by relative monocytopenia, NMR, and increased basophil count showed the highest AUC among the WBC differentials. NMR combined with cyst size showed the highest AUC, and was significantly higher in patients with potentially malignant adnexal masses than in those with benign conditions.

The association between the monocyte count and adnexal mass with malignant potential, especially for borderline ovarian tumors with low malignancy potential, is not fully understood and must be clarified. Although a higher monocyte count in peripheral blood is associated with poor prognosis of ovarian cancer and melanoma, little is known about the association between monocyte count and borderline ovarian tumors with low malignancy potential.^{14,24)} Previous investigations on the role of monocyte chemoattractant protein (MCP-1) indicated that MCP-1 is a potent chemotactic factor that attracts circulating monocytes and macrophages to the site of tumor growth and inflammation, and is secreted by a variety of human tumors including ovarian cancer.^{25,26)} MCP-1 levels in serum and ascites were increased in patients with ovarian cancer, compared to control patients.^{25,26)} These findings suggest that MCP-1 has a role in recruiting circulating monocytes to become tumor-associated macrophages in ovarian cancer. However, previous work on MCP-1 mRNA expression in ovarian cancer tissue showed that only one borderline tumor

of three was positive for MCP-1 mRNA expression, in stromal and focal epithelial tissue.²⁵⁾ This finding suggests that the role and function of MCP-1 in borderline ovarian tumor is different its role in malignant ovarian cancer, and warrants further study on the relationship between MCP-1 expression, peripheral monocyte levels, and tumor-associated macrophage activity in borderline ovarian tumors.

Adnexal mass size is an independent predictor of malignancy risk.²⁷⁾ Our results showed that the size of potentially malignant adnexal masses was significantly increased compared to benign cysts. However, many large ovarian tumors are benign. A large prospective study involving 1304 women with unilocular cysts who underwent operation over a 10-year period showed benign pathology in 93.2% of cases with diameters of 8 cm or more.²⁸⁾ If size is the only criterion on which the operative approach is based, many women with large benign tumors will have an unnecessary laparotomy, rather than laparoscopic surgery. Therefore, in this study, we used cyst size in conjunction with WBC differential count to discriminate adnexal masses with malignant potential from benign cysts. Assessment of this combined marker appears to be less dependent on operator skill, and can be achieved more easily and objectively.

A limitation of this study is its retrospective design, so our findings must be confirmed with prospective studies. Also, there exists a selection bias since when preoperative findings such as ultrasound examination and/or abdominal and pelvic computed tomography scan suggested malignancy, the choice of surgical procedure was laparotomy, rather than laparoscopy. Although subgroup analysis revealed significant differences between endometrioma and adnexal masses with malignant potential, changes in WBC differential counts are involved in the inflammatory process. Therefore, the possibility of an acute inflammatory process such as tubo-ovarian abscess should be considered before applying these markers for predicting malignant potential prior to laparoscopic surgery.

In conclusion, our study has shown that the multiplication of cyst size with NMR may be useful in predicting malignant potential before laparoscopic surgery. The major advantage of using these markers in practice is that they are easily obtained and can be interpreted from routine complete blood counts taken during preoperative evaluation, without additional costs or testing. Although the sensitivity and specificity of these markers are not sufficient enough to use them as novel markers, they can be helpful in making decisions to conduct further evaluations, such as computed tomography or magnetic resonance imaging, on the adnexal mass before laparoscopy. This could lead to a more meticulous approach during surgery to prevent tumor spillage, the decision to have an oncological surgeon available for complete staging if necessary, and may even minimize the number of unexpected malignancies encountered during laparoscopic surgery.

국문 요약

목 적:

복강경 수술에서 자궁 부속기 종양의 악성 가능성을 예측하기 위해 수술 전 백혈구 분포를 이용한 임상적 가치를 연구하고자 한다.

방 법:

2005년 07월부터 2008년 12월 사이 자궁 부속기 종양으로 복강경 수술을 한 1325명의 전자 의료 기록을 소급하여 분석하였다.

결 과:

1325명의 환자 중 30명(2.3%)에서 악성 가능성이 있는 자궁 부속기가 있었으며, 백혈구 분포, 중성구 대 단구의 비율(NMR), 혈청 CA-125, 종양 크기를 분석한 결과, 악성 가능성 있는 자궁 부속기를 가진 환자와 양성 질환을 가진 환자 사이에서 낭종 크기만이 중요한 차이가 있었다(평균 9.45 cm 대 6.23 cm, $p=0.001$). 다양한 표지자의 조합을 이용해 추가적으로 분석하였으며, 낭종 크기와 NMR의 곱이 0.711로 가장 높은 곡선 아래의 면적을 내었으며, 민감도 86.7%, 특이성

48.3%, 절단 값 67.23을 보였다 (95% 신뢰 구간 0.619~0.806, $p<0.001$). 이 수치 또한 악성 가능성 있는 자궁 부속기를 가진 환자와 유피낭종 또는 자궁내막종을 가진 환자들 사이에서 중요한 차이가 있었다($p=0.038$, $p=0.02$).

결 론:

수술 전 NMR 수치와 낭종 크기의 조합은 복강경 수술 이전 자궁 부속기 종양의 악성 가능성을 예측하는 간단하고, 비침습적인 표지자로 사용될 수 있다.

중심단어: 복강경, 자궁부속기 종양, 악성 가능성, 백혈구 분포 크기

References

1. Luciano AA, Lowney J, Jacobs SL. Endoscopic treatment of endometriosis-associated infertility. Therapeutic, economic and social benefits. J Reprod Med 1992;37:573-6.
2. Mendilcioglu I, Zorlu CG, Trak B, Ciftci C, Akinci Z. Laparoscopic management of adnexal masses. Safety and effectiveness. J Reprod Med 2002;47:36-40.
3. Yuen PM, Yu KM, Yip SK, Lau WC, Rogers MS, Chang A. A randomized prospective study of laparoscopy and laparotomy in the management of benign ovarian masses. Am J Obstet Gynecol 1997;177:109-14.
4. Argenta PA, Nezhat F. Approaching the adnexal mass in the new millennium. J Am Assoc Gynecol Laparosc 2000;7:455-71.
5. Vergote I, De Brabanter J, Fyles A, Bertelsen K, Einhorn N, Sevelde P, et al. Prognostic importance of degree of differentiation and cyst rupture in stage I invasive epithelial ovarian carcinoma. Lancet 2001;357:176-82.
6. Mayer C, Miller DM, Ehlen TG. Peritoneal implantation of squamous cell carcinoma following rupture of a dermoid cyst during laparoscopic removal. Gynecol Oncol 2002;84:180-3.
7. Yazbek J, Helmy S, Ben-Nagi J, Holland T, Sawyer E, Jurkovic D. Value of preoperative ultrasound examination in the selection of women with adnexal masses for laparoscopic surgery. Ultrasound Obstet Gynecol 2007;30:883-8.
8. Van Holsbeke C, Daemen A, Yazbek J, Holland TK, Bourne T, Mesens T, et al. Ultrasound methods to distinguish between malignant and benign adnexal masses in the hands of examiners with different levels of experience. Ultrasound Obstet Gynecol 2009;34: 454-61.
9. Van Holsbeke C, Daemen A, Yazbek J, Holland TK, Bourne T, Mesens T, et al. Ultrasound Experience Substantially Impacts on Diagnostic Performance and Confidence when Adnexal Masses Are Classified Using Pattern Recognition. Gynecol Obstet Invest 2009;69:160-8.

10. **Yazbek J, Raju KS, Ben-Nagi J, Holland T, Hillaby K, Jurkovic D.** Accuracy of ultrasound subjective 'pattern recognition' for the diagnosis of borderline ovarian tumors. *Ultrasound Obstet Gynecol* 2007;29:489-95.
11. **Yazbek J, Ameye L, Timmerman D, Testa AC, Valentin L, Holland TK, et al.** Use of ultrasound pattern recognition by expert operators to identify borderline ovarian tumors: a study of diagnostic performance and interobserver agreement. *Ultrasound Obstet Gynecol* 2010;35: 84-8.
12. **De Angulo G, Yuen C, Palla SL, Anderson PM, Zweidler-McKay PA.** Absolute lymphocyte count is a novel prognostic indicator in ALL and AML: implications for risk stratification and future studies. *Cancer* 2008;112:407-15.
13. **Yamanaka T, Matsumoto S, Teramukai S, Ishiwata R, Nagai Y, Fukushima M.** The baseline ratio of neutrophils to lymphocytes is associated with patient prognosis in advanced gastric cancer. *Oncology* 2007;73:215-20.
14. **Bishara S, Griffin M, Cargill A, Bali A, Gore ME, Kaye SB, et al.** Pre-treatment white blood cell subtypes as prognostic indicators in ovarian cancer. *Eur J Obstet Gynecol Reprod Biol* 2008;138:71-5.
15. **Cho H, Hur HW, Kim SW, Kim SH, Kim JH, Kim YT, et al.** Pre-treatment neutrophil to lymphocyte ratio is elevated in epithelial ovarian cancer and predicts survival after treatment. *Cancer Immunol Immunother* 2009;58:15-23.
16. **Hanley JA, McNeil BJ.** The meaning and use of the area under a receiver operating characteristic (ROC) curve. *Radiology* 1982;143:29-36.
17. **Brosi N, Deckardt R.** Endoscopic surgery in patients with borderline tumor of the ovary: a follow-up study of thirty-five patients. *J Minim Invasive Gynecol* 2007;14:606-9.
18. **Odegaard E, Staff AC, Langebrenne A, Engh V, Onsrud M.** Surgery of borderline tumors of the ovary: retrospective comparison of short-term outcome after laparoscopy or laparotomy. *Acta Obstet Gynecol Scand* 2007;86:620-6.
19. **Cadron I, Leunen K, Van Gorp T, Amant F, Neven P, Vergote I.** Management of borderline ovarian neoplasms. *J Clin Oncol* 2007;25: 2928-37.
20. **Timmerman D, Schwarzler P, Collins WP, Claerhout F, Coenen M, Amant F, et al.** Subjective assessment of adnexal masses with the use of ultrasonography: an analysis of interobserver variability and experience. *Ultrasound Obstet Gynecol* 1999;13:11-6.
21. **Mol BW, Boll D, De Kanter M, Heintz AP, Sijmons EA, Oei SG, et al.** Distinguishing the benign and malignant adnexal mass: an external validation of prognostic models. *Gynecol Oncol* 2001;80:162-7.
22. **Bast RC Jr.** Status of tumor markers in ovarian cancer screening. *J Clin Oncol* 2003;21:200s-5s.
23. **Cho S, Cho H, Nam A, Kim HY, Choi YS, Park KH, et al.** Neutrophil-to-lymphocyte ratio as an adjunct to CA-125 for the diagnosis of endometriosis. *Fertil Steril* 2008;90:2073-9.
24. **Schmidt H, Bastholt L, Geertsen P, Christensen IJ, Larsen S, Gehl J, et al.** Elevated neutrophil and monocyte counts in peripheral blood are associated with poor survival in patients with metastatic melanoma: a prognostic model. *Br J Cancer* 2005;93:273-8.
25. **Negus RP, Stamp GW, Relf MG, Burke F, Malik ST, Bernasconi S, et al.** The detection and localization of monocyte chemoattractant protein-1 (MCP-1) in human ovarian cancer. *J Clin Invest* 1995;95:2391-6.
26. **Hefler L, Tempfer C, Heinze G, Mayerhofer K, Breitenecker G, Leodolter S, et al.** Monocyte chemoattractant protein-1 serum levels in ovarian cancer patients. *Br J Cancer* 1999;81:855-9.
27. **Timmerman D, Testa AC, Bourne T, Ferrazzi E, Ameye L, Konstantinovic ML, et al.** Logistic regression model to distinguish between the benign and malignant adnexal mass before surgery: a multicenter study by the International Ovarian Tumor Analysis Group. *J Clin Oncol* 2005;23: 8794-801.
28. **Ekerhovd E, Wienerroith H, Staudach A, Granberg S.** Preoperative assessment of unilocular adnexal cysts by transvaginal ultrasonography: a comparison between ultrasonographic morphologic imaging and histopathologic diagnosis. *Am J Obstet Gynecol* 2001;184:48-54.