

Iatrogenic Injury in the Lateral Segment of the Liver after Pancreatoduodenectomy: Early Follow-Up CT Features and Clinical Implications

췌십이지장절제술 후 발생한 간 외분절의 익인성 손상: 초기 추적 CT 소견 및 임상적 의의

Yaena Kim, MD, Jeong-Sik Yu, MD, Jae-Joon Chung, MD, Joo Hee Kim, MD, Eun-Suk Cho, MD, Jhii-Hyun Ahn, MD, Ki Whang Kim, MD

Department of Radiology and Research Institute of Radiological Science, Gangnam Severance Hospital, Yonsei University College of Medicine, Seoul, Korea

Purpose: To investigate the incidence, predisposing factors and image features of iatrogenically-induced focal parenchymal changes in the lateral segment of the liver after a pancreatoduodenectomy.

Materials and Methods: A follow-up CT taken on the seventh day after an uneventful pancreatoduodenectomy were retrospectively reviewed for 123 patients for newly developed focal hepatic lesions. The location, size, and shape of the lesions were analyzed along with preoperative anatomic variation of the hepatic artery, for the degree of intrahepatic bile duct dilatation and procedure duration.

Results: Other than two patients with hepatic metastases, 13 (10.6%) patients showed newly developed irregular ($n = 9$), linear ($n = 2$) or wedge-like ($n = 2$) hypovascular areas (1.4-8.5 cm; mean, 2.8 cm) in the posterior subcapsular portion of the lateral segment. There were only two patients (15.4%) with an aberrant origin of the segmental hepatic artery from the left gastric artery, and the degree of bile duct dilatation was nonspecific for the 13 subjected patients. Mean procedure time was not significantly different between the subjected patients and the others (541 min vs. 507 min; $p = 0.160$).

Conclusion: Focal iatrogenic injury in the lateral segment after a pancreatoduodenectomy would not be a common event regardless of preoperative vascular anatomic variation, bile duct dilatation, or procedure duration.

Index terms

Liver
Liver Disease
Ischemia
Computed Tomography

Received January 19, 2012; Accepted March 20, 2012
Corresponding author: Jeong-Sik Yu, MD
Department of Radiology, Gangnam Severance Hospital,
Yonsei University College of Medicine, 211 Eonju-ro,
Gangnam-gu, Seoul 135-720, Korea.
Tel. 82-2-2019-3510 Fax. 82-2-3462-5472
E-mail: yjsrad97@yuhs.ac

Copyrights © 2012 The Korean Society of Radiology

INTRODUCTION

During open surgery of the upper abdomen for treatment of an extrahepatic lesion, various iatrogenic insults to the liver are possible. Other than unintentional parenchymal laceration or bile duct injury, there have been some reports of localized hypoxic injuries which were supposed to be related to the parenchymal compression by surgical retractor with or without the presence of major vascular injury supplying the hepatic segment during the surgical procedure (1-4).

Because of the dual blood supply and potentially extensive

collateral pathways in the liver, focal hepatic ischemic injury is a rare condition (5). Only a few reports have dealt with the imaging findings of hepatic ischemic injuries caused by vascular insufficiency or low attenuation ischemic lesions of the liver with various shapes and locations on contrast-enhanced computed tomography (CT). The shapes can be round, oval or wedge-shaped with sharp or poor margins and can be located in the peripheral or central portions of the hepatic parenchyma (6-8). Because of the nonspecific imaging findings, focal hepatic ischemia could be confused with a newly developed tumorous condition. Even on early follow-up CT after surgery, the

presence of newly defined hepatic lesions can potentially represent overlooked malignant lesions, such as preexisting primary or metastatic lesions that were present before surgery.

Meanwhile, an early follow-up CT conducted on the seventh postoperative day has been generally used to assess pancreatic fistula formation after pancreatoduodenectomy (9). To the best of our knowledge, there have been no studies reporting the early incidence and risk factors of iatrogenically-induced focal hepatic lesions after the open surgery for extrahepatic malignancy in the upper abdomen. The aim of this study was to investigate the incidence, possible predisposing factors, and imaging features of iatrogenically-induced focal ischemic changes in the lateral segment of the liver after an uneventful open pancreatoduodenectomy.

MATERIALS AND METHODS

Patients

Approval for this study was obtained from the institutional review board at our hospital, which waived the requirement for informed consent from individual patients. Between February 2006 and June 2010, 195 consecutive patients underwent Whipple's procedure or a pylorus-preserving pancreatoduodenectomy, and a seven-day follow-up CT, were used to evaluate for early post-surgical complications of pancreatic fistula formation. The results were available for retrospective review for 193 patients. A study coordinator with 20 years of abdominal imaging experience conducted a preliminary review of all available CT images on picture archiving and communication system (PACS) monitors and excluded 68 of the 193 patients that had no multiplanar reformation images for detailed evaluation of newly developed focal lesions and two other patients; one with previous left hemihepatectomy and one patient with preexisting marked atrophic change of the lateral segment of the liver. A total of 123 patients (63 men and 60 women; mean age 63 years; range 30-81 years) were finally subjected to a review of the pre- and post-operative axial and coronal CT images for assessment of iatrogenically-induced focal lesions in the liver.

CT Protocol

All patients underwent an unenhanced and contrast-enhanced CT examination of the abdomen or abdomen-pelvis using a

64-MDCT scanner (Somatom Sensation 64, Siemens Medical Solutions, Erlangen, Germany). Scanning was performed using the following parameters: detector configuration, 0.6×64 mm; effective section thickness, 3.0 mm; reconstruction interval, 3.0 mm; gantry rotation time, 0.33 sec; pitch, 1.0; effective mAs, 250; and kVp, 120. Each acquisition was performed during one breath-hold of up to 10 sec, depending on the scan range. After unenhanced imaging of the upper abdomen, a warmed contrast medium (2 mL/kg, Ultravist 300; Schering AG, Berlin, Germany) was administered intravenously using an automatic injector (EnVision CT; Medrad Inc., Pittsburgh, PA, USA) at a rate of 1.5 mL/s through an 18-gauge IV catheter inserted into an antecubital vein. The scan start time was 20 seconds after completion of contrast injection. Axial section data were reconstructed for contrast-enhanced scanning: first with 5-mm-thick sections at 5.0-mm intervals in the transverse plane and then with 0.6-mm-thick sections at 0.6-mm intervals. The second set of reconstructed axial scans was then reformatted in the coronal plane with 2.0-mm sections at 2.0-mm intervals. All images were routinely transferred to a PACS as a separate series of scans.

Image Analysis

To determine the presence of lesions suggestive of iatrogenically-induced focal hepatic lesions after open pancreatoduodenectomy, two observers, including the study coordinator and a senior resident from the radiology department, used PACS monitors to evaluate the seven-day postoperative follow-up CT images for newly developed focal lesions in the left hepatic lobe using the preoperative CT scans as a reference. For the patients with newly developed lesions, the intrahepatic location and appearance of the lesions, in addition to the attenuation characteristics, were determined by consensus. The location of the lesion was classified into central and subcapsular portions. The subcapsular portion was classified into anterior, posterior, and anteroposterior portions. The anteroposterior portion was defined as the subcapsular portion that traversed the anterior and posterior margins of the lateral segment. The appearance of the lesion was classified as being a round/oval, wedge-shape, linear, or irregular. We also classified whether the lesion had a well or ill-defined margin. Each observer measured the longest dimension of each lesion using the electronic calipers on the axial or coronal images, and the mean value was determined as the le-

sion size.

For patients with newly developed lesions, both observers reviewed the preoperative CT studies for any anatomic variation of the hepatic artery and degree of preoperative intrahepatic bile duct dilatation (absent/minimal, moderate, severe). All available further follow-up CT studies were also reviewed to determine the fate of the iatrogenically-induced lesions as well as to exclude any overlooked metastases before surgery for the newly defined lesions. Mean procedure time for patients with newly developed lesions and the other patients were also compared to each other using the independent-sample *t*-test. *p*-values < 0.05 were considered to be statistically significant.

RESULTS

Among the 123 patients reviewed, 15 patients each had a newly defined focal low attenuation density lesion in the lateral

segment of the liver. Among the 15 lesions, a 1.7 cm anterior subcapsular wedge-shaped hypovascular density lesion showed a nodular change with hypermetabolism on the further follow-up positron emission tomography (PET)/CT, and one other hypovascular lesion involving the entire lateral segment showed enlargement and further extension over the other segments during subsequent follow-up. After exclusion of these two patients, 13 patients (10.6%) had lesions suggestive of postoperative iatrogenically-induced parenchymal injury in the lateral segment of the liver. All lesions (1.4-8.5 cm; mean, 2.8 cm) were located in the posterior subcapsular portion of the lateral segment (Fig. 1); three lesions crossed the parenchyma of the lateral segment in the anterior-posterior direction (Fig. 2). No lesion was located in the central portion. Nine lesions were irregularly-shaped, and the other lesions had a linear (*n* = 2) or wedge-shaped (*n* = 2) appearance. All lesions were well-defined as hypovascular areas on post-contrast images, while they showed slightly lower or

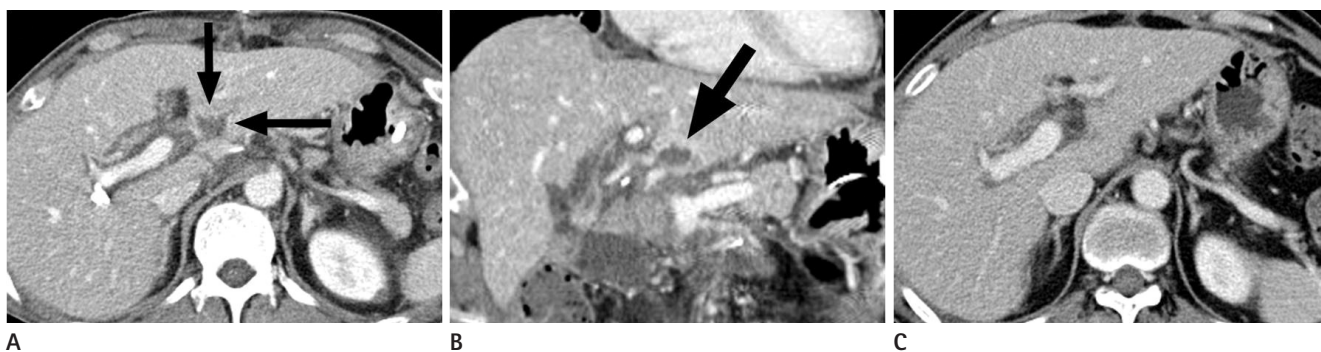


Fig. 1. A 55-year-old male treated by Whipple's procedure for pancreatic head cancer.

A, B. Axial (**A**) and coronal (**B**) images of contrast-enhanced CT performed seven days after the operation revealed a wedge-shaped, low-density lesion involving the posterior subcapsular portion of the lateral segment of the liver (arrows).

C. Contrast-enhanced CT performed three months after surgery shows complete resolution of the lesion in the liver.

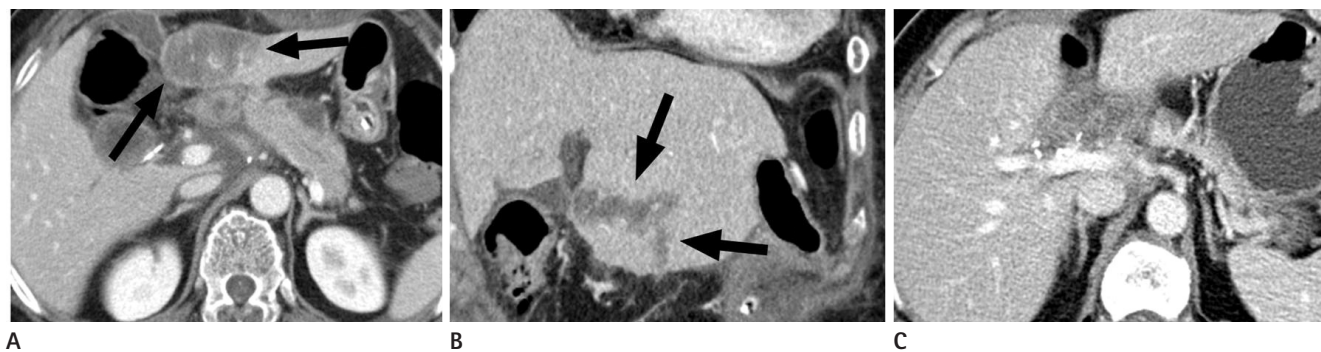


Fig. 2. A 66-year-old female treated by a pylorus-preserving pancreatoduodenectomy for treatment of common bile duct cancer.

A, B. Axial (**A**) and coronal (**B**) images of the contrast-enhanced CT performed seven days after the operation revealed an irregularly shaped, low-density lesion that involves the anterior-posterior subcapsular portion of the lateral segment of the liver (arrows). Normal subsegmental hepatic vasculature is shown as linear high densities in the infarcted low attenuation density area of the liver.

C. Contrast-enhanced CT performed five months after surgery shows complete resolution of the lesion in the liver.

iso-attenuation densities not well distinguished from background parenchyma on the pre-contrast images.

Only two patients (15.4%) showed an aberrant origin of the segmental hepatic artery from the left gastric artery, and the degree of bile duct dilatation was nonspecific (absent/minimal, $n = 4$; moderate, $n = 5$; severe, $n = 4$) on preoperative CT images. All lesions were shown iso- or low density compared to normal parenchyma of the liver on a precontrast CT image. For the 13 patients with subjected lesions, the mean operation time was 541 ± 109 minutes and longer than that of the other 108 patients with 507 ± 108 minutes; however, there was no statistically significant difference ($p = 0.160$). All lesions disappeared on CT during the nine-month follow-up period (Table 1).

DISCUSSION

There was an early report of CT findings concerning focal hepatic injury for 10 patients (4%) out of 250 after surgery for malignancy involving the gastric cardia by Yassa and Peters (1); all lesions were located in the lateral segment extending to the liver surface, and were wedge-shaped ($n = 6$), rectangular ($n = 2$) or rounded ($n = 2$) in appearance. Other previous reports had supported the CT appearance of the lateral segment ischemic lesions induced by the surgical retractor in a few cases (2-4). Depending on the specific location of the posterior subcapsular portion of the lateral segment of the liver, the subjected

lesions in our present study were also suggested as iatrogenically-induced parenchymal injury related to the compression effect by the surgical retractor.

Except for the cases with early postoperative complications, immediate follow-up CT is not generally indicated for cancer surgery patients. Even though prolonged hepatic compression by the surgical retractor is a routine event during open surgery for upper abdominal malignancies, there have been no reports about the early incidence or typical imaging features of anticipated iatrogenic injury in the liver after upper abdominal surgery. Even in the only prior cohort study on iatrogenic liver injury by surgical retractor, CT was performed 2-6 months after surgery (1). Meanwhile, a seven-day follow-up CT examination has become standardized to evaluate for post-operative pancreatic fistula formation after pancreatoduodenectomy (9). In a large group of these patients, it was possible to estimate the overall incidence and early imaging features of the focal hepatic injuries induced by the prolonged compression effect of the surgical retractor during uneventful cancer surgery of the upper abdomen with longer than seven hours of routine operation time (10). The higher incidence of the subjected lesions in the present study was higher than the previous report (11% vs. 4%) by Yassa and Peters (1); and this discrepancy might be partially related to the difference of timing for the follow-up CT examination depending on the nature of minor hepatic injury showing early resolution.

Table 1. Clinical and Radiologic Findings of Patients with Iatrogenically-Induced Focal Ischemic Change on CT

| | Sex/Age | Op. | IHD Dilatation | Origin of Segmental Hepatic a. | Size (mm) | Location | Shape | Period of 1st Follow-Up CT Scan (Months) | Period of Disappearance (Months) |
|-------|---------|---------------|----------------|--------------------------------|-----------|-----------------|-----------|--|----------------------------------|
| Pt 1 | F/47 | PPPD | Severe | Lt. gastric a. | 26 | Posterior | Linear | 4 | 4 |
| Pt 2 | M/58 | PPPD | Severe | No variant | 21 | Posterior | Wedge | 3 | 3 |
| Pt 3 | M/69 | PPPD | Absent/Minimal | No variant | 21 | Posterior | Irregular | 6 | 6 |
| Pt 4 | F/63 | Whipple's op. | Moderate | No variant | 23 | Posterior | Linear | 2 | 2 |
| Pt 5 | M/71 | PPPD | Absent/Minimal | No variant | 39 | Posterior | Irregular | 4 | 4 |
| Pt 6 | M/60 | PPPD | Severe | No variant | 23 | Posterior | Irregular | 9 | 9 |
| Pt 7 | F/67 | PPPD | Moderate | Lt. gastric a. | 27 | Posterior | Irregular | 5 | 8 |
| Pt 8 | F/76 | Whipple's op. | Absent/Minimal | No variant | 16 | Posterior | Irregular | 4 | 4 |
| Pt 9 | F/68 | Whipple's op. | Absent/Minimal | No variant | 14 | Posterior | Irregular | 3 | 3 |
| Pt 10 | F/66 | PPPD | Moderate | No variant | 85 | Anteroposterior | Wedge | 5 | 8 |
| Pt 11 | M/55 | PPPD | Severe | No variant | 23 | Posterior | Irregular | 4 | 4 |
| Pt 12 | M/62 | PPPD | Moderate | No variant | 22 | Anteroposterior | Irregular | 2 | 2 |
| Pt 13 | F/76 | PPPD | Moderate | No variant | 18 | Anteroposterior | Irregular | 4 | 4 |

Note.—IHD = intrahepatic bile duct, PPPD = pylorus preserving pancreatoduodenectomy, Whipple's op. = Whipple's operation

Besides the localized ischemic injury from a suggestive mechanism of minor vascular compromise, iatrogenic focal hepatic lesions could have other possible parenchymal contusions with hematoma, localized inflammation, fatty change or fibrosis which were also iatrogenically-induced. All of the subjected lesions in the present study with no instance of major hepatic laceration or intraperitoneal bleeding showed low or iso-attenuation densities on the precontrast images without mass effect, and there was a low possibility of intraparenchymal or subcapsular hematomas with the expectation of a higher attenuation density and mass effect of acute hemorrhage. Focal fatty change can be induced by chronic ischemia (11), and it was unlikely to make a gross fatty deposition 7 days after the procedure, even though the subcapsular wedge-shaped hypovascular area without mass effect could mimic the appearance of our cases. In the previous report (1), many subcapsular lesions of retractor injury showed various degrees of contrast enhancement after contrast material injection, which was not defined in and around the lesions of our present study. Depending on the nature of the localized necrotic infarct, it is unlikely to show prominent contrast enhancement for the area of deficient blood supply as in our cases (2-4, 6-8). In the previous study (1), such contrast enhancement was explained as fibrotic change in the chronic stage of ischemic damage, which could be observed 2-6 months after surgery. In the present study, there was no lesion with a round or oval shape with variable contrast enhancement of usual metastatic lesions or intrahepatic abscesses after surgery (10, 12-14).

Among the patients with newly defined lesions in the lateral segment of the liver after pancreatoduodenectomy, two lesions, which had previously been overlooked, were found to be metastatic due to further growth on the follow-up studies. These lesions were located in the anterior subcapsular portion of the lateral segment, and covered the entire lateral segment of liver. Due to the different location and wide involvement after an uneventful pancreatoduodenectomy, we inferred that these lesions were not related to the retractor compression.

In our evaluation of predisposing factors related to vascular compromise, there was no specific hepatic vascular injury, and only two patients showed anatomic variation of the left hepatic artery, which originated from the left gastric artery on a preoperative CT. In the general population, the incidence of the left hepatic artery originating from the left gastric artery is 9.7-

34.0%, and there seemed to be no relationship between the vascular anatomical variation and focal ischemic change after a pancreatoduodenectomy (15, 16). We also considered the possibility that bile duct dilatation before surgery could be another factor that might compromise adjacent portal venous flow in the portal tract (17). In the present study, nine of 13 patients with iatrogenic infarction in the lateral segment showed moderate or severe intrahepatic bile duct dilatation. However, all of the bile duct dilatation was related to extrahepatic bile duct obstruction by the primary pancreatic or bile duct mass lesions in this study, and we did not observe any association between hepatic ischemia and generalized bile duct dilatation in this study. A previous report of a retractor-related catastrophic liver lobe necrosis after laparoscopic gastric surgery (12), and the duration of retraction and the amount of liver tissue trapped, were mentioned to be the cause of ischemic injury by localized intraparenchymal venous compression. In the present study, there was no significant difference of mean operation time between the patients with iatrogenic liver lesions and the others; however, it was not possible to compare the real compression time and the extent of the trapped hepatic parenchyma due to the lack of such information.

Our study had several limitations. First, the lesions suggestive of focal hepatic ischemia could not be pathologically confirmed because of the benign and temporary nature of the lesion. All of the lesions disappeared on follow-up CT during the nine-month follow-up, and malignant lesions were pre-excluded due to further growth. Therefore, the possibility of a subclinical inflammatory lesion, minor laceration or contusional injury could not be excluded as an explanation of these iatrogenically induced benign lesions that disappeared on follow-up studies. Second, aside from the mean procedure duration, there was no control group to compare the possible predisposing or risk factors for focal ischemic injury. Because of the small number and low overall incidence of focal ischemic change in addition to the lack of discernable vascular anatomic variation or the degree of bile duct dilatation, we did not perform a statistical analysis. Third, the duration of follow-up imaging varied between two and nine months for the 13 patients with ischemic hepatic lesions, and the exact timing of complete resolution of the ischemic lesions could not be firmly validated.

In conclusion, localized parenchymal iatrogenic injuries at-

tributable to prolonged compression of the lateral segment of the liver by a surgical retractor were uncommon, even in a pancreatoduodenectomy with a long procedure duration which was completely resolved on short-term follow-up imaging studies. Such changes are usually defined as small, well-defined, low-attenuation areas in the subcapsular portion of lateral segment with an irregular, linear, or wedge-shaped appearance on contrast-enhanced CT. The incidence of these lesions was not related to vascular anatomic variations, degree of bile duct dilatation before surgery or total procedure duration. Because of the benign nature of these lesions showing spontaneous resolution within a short time after the insult, immediate additional diagnostic work-up or close follow-up studies are not recommended for these temporary manifestations.

REFERENCES

1. Yassa NA, Peters JH. CT of focal hepatic injury due to surgical retractor. *AJR Am J Roentgenol* 1996;166:599-602
2. Kitagawa T, Iriyama K. Hepatic infarction as a complication of gastric cancer surgery: report of four cases. *Surg Today* 1998;28:542-546
3. Park MS, Yu JS, Kim KW, Choi SH, Yoon SW, Park KY, et al. Case report: focal hepatic necrosis as a complication of gastric cancer surgery: imaging features in one patient. *Clin Radiol* 2002;57:858-860
4. Tamhankar AP, Kelty CJ, Jacob G. Retraction-related liver lobe necrosis after laparoscopic gastric surgery. *JSLs* 2011; 15:117-121
5. Lemasters J. Hypoxic, ischemic, and reperfusion injury to liver. In Arias I, Boyer J, Chisari F, Fausto N, Schachter D, Shafritz D. *The liver: biology and pathobiology*. 4th ed. Philadelphia: Lippincott Williams & Wilkins, 2001;258-259
6. Adler DD, Glazer GM, Silver TM. Computed tomography of liver infarction. *AJR Am J Roentgenol* 1984;142:315-318
7. Holbert BL, Baron RL, Dodd GD 3rd. Hepatic infarction caused by arterial insufficiency: spectrum and evolution of CT findings. *AJR Am J Roentgenol* 1996;166:815-820
8. Lev-Toaff AS, Friedman AC, Cohen LM, Radecki PD, Caroline DF. Hepatic infarcts: new observations by CT and sonography. *AJR Am J Roentgenol* 1987;149:87-90
9. Pratt WB, Maithel SK, Vanounou T, Huang ZS, Callery MP, Vollmer CM Jr. Clinical and economic validation of the International Study Group of Pancreatic Fistula (ISGPF) classification scheme. *Ann Surg* 2007;245:443-451
10. Yeo CJ, Cameron JL, Sohn TA, Lillemoe KD, Pitt HA, Talami-ni MA, et al. Six hundred fifty consecutive pancreaticoduodenectomies in the 1990s: pathology, complications, and outcomes. *Ann Surg* 1997;226:248-257; discussion 257-260
11. Grove A, Vyberg B, Vyberg M. Focal fatty change of the liver. A review and a case associated with continuous ambulatory peritoneal dialysis. *Virchows Arch A Pathol Anat Histopathol* 1991;419:69-75
12. Coombs RJ, Zeiss J, Howard JM, Thomford NR, Merrick HW. CT of the abdomen after the Whipple procedure: value in depicting postoperative anatomy, surgical complications, and tumor recurrence. *AJR Am J Roentgenol* 1990; 154:1011-1014
13. Mortelé KJ, Lemmerling M, de Hemptinne B, De Vos M, De Bock G, Kunnen M. Postoperative findings following the Whipple procedure: determination of prevalence and morphologic abdominal CT features. *Eur Radiol* 2000;10:123-128
14. Gervais DA, Fernandez-del Castillo C, O'Neill MJ, Hahn PF, Mueller PR. Complications after pancreatoduodenectomy: imaging and imaging-guided interventional procedures. *Radiographics* 2001;21:673-690
15. Hiatt JR, Gabbay J, Busuttil RW. Surgical anatomy of the hepatic arteries in 1000 cases. *Ann Surg* 1994;220:50-52
16. Abid B, Douard R, Chevallier JM, Delmas V. [Left hepatic artery: anatomical variations and clinical implications]. *Morphologie* 2008;92:154-161
17. Yu JS, Kim KW, Park MS, Yoon SW. Bile duct injuries leading to portal vein obliteration after transcatheter arterial chemoembolization in the liver: CT findings and initial observations. *Radiology* 2001;221:429-436

췌십이지장절제술 후 발생한 간 외분절의 의인성 손상: 초기 추적 CT 소견 및 임상적 의의

김예나 · 유정식 · 정재준 · 김주희 · 조은석 · 안지현 · 김기황

목적: 췌십이지장절제술 후 발생하는 간 외분절의 국소적인 의인성 변화의 빈도, 발생요인과 해당병소의 영상소견을 알아보고자 하였다.

대상과 방법: 췌십이지장절제술을 시행 받은 123명의 환자를 대상으로 7일째 추적 CT에서 새로이 발생한 간의 국소 병변을 후향적으로 조사하였다. 그러한 병변에 대해 간내 위치, 크기, 모양을 분석하고 수술 전 CT에서 간동맥의 해부학적 변이의 유무와 간내 담관이 늘어난 정도, 그리고 수술시간의 차이에 대해 분석하였다.

결과: 전이암으로 확인된 2명을 제외하고 13명의 환자(10.6%)에서 간의 외분절 후면의 피막 하부에 불규칙적($n = 9$), 선형($n = 2$), 또는 썩기모양($n = 2$)의 저혈관성 부위(1.4~8.5 cm; 평균 2.8 cm)가 새로이 발견되었다. 13명의 환자 중 오직 2명(15.4%)에서만 수술 전 CT에서 좌위동맥에서 나오는 간 분절 동맥이 있었고 간내 담관이 늘어난 정도는 비특이적이었다. 대상환자와 나머지 환자 간에 수술시간의 차이는 유의하지 않았다(541분 대 507분, $p = 0.160$).

결론: 췌십이지장절제술 후에 간의 외분절에 발생하는 국소적인 의인성 손상의 빈도는 그리 높지 않으며 병소의 발생과 수술 전 혈관의 해부학적 변이, 담관확장이나 수술시간과는 연관이 없어 보인다.

연세대학교 의과대학 강남세브란스병원 영상의학교실