

## Mini-review: Eosinophils, a Useful Diagnostic Clue in Surgical Neuropathology

Junjeong Choi<sup>1</sup>, Tai Seung Kim<sup>2</sup>, Se Hoon Kim<sup>2</sup>

<sup>1</sup>*Department of Pathology, Wonju College of Medicine, Yonsei University, Wonju, Korea*

<sup>2</sup>*Department of Pathology, College of Medicine, Yonsei University, Seoul, Korea*

Eosinophils are one of the polymorphonuclear granulocytes derived from bone marrow stem cells, and they contain many small cytoplasmic granules that stain bright red with eosin or brick-red with Romanowsky staining. Eosinophilic infiltration is also present in various human central nervous system (CNS) diseases such as parasitic infection, transverse myelitis, vasculitis, Langerhans cell histiocytosis, glioblastoma and etc... Due to the morphologic and functional characteristics, the presence of eosinophils in certain lesions may provide useful diagnostic clues in the right clinical setting. Consideration of this finding may facilitate the diagnosis of CNS pathologic lesions, especially in a small specimen such as a stereotactic biopsy.

**Key Words:** Central nervous system, Eosinophil, Pathology

Eosinophils are one of the polymorphonuclear granulocytes derived from bone marrow stem cells, and they contain many small cytoplasmic granules that stain bright red with eosin or brick-red with Romanowsky staining. They are normally present in the peripheral blood and in the bone marrow. The granules contain many chemical mediators including histamine and proteins such as eosinophil peroxidase, ribonuclease, deoxyribonuclease, lipase, plasminogen and major basic protein, which may provoke toxic damage to adjacent tissue and microorganisms (especially helminths) upon degranulation and release.<sup>1</sup>

The morphology of eosinophils is easily recognized under routine histochemical preparation due to their large specific granules and unique chromaticity. They

are 12–17  $\mu$ m in diameter and most of them have a bi-lobed or segmented nucleus that is often partly obscured by densely packed, coarse, spherical, uniform, refractile cytoplasmic granules.<sup>1</sup> Known immunohistochemical markers include BMK-13, CD69, and eosinophil cationic protein, among others.

Eosinophilia, a condition with increased numbers of eosinophils in the peripheral blood is seen in various pathological conditions. Particularly, it is a characteristic clinical sign in many types of parasitic infections and the defensive role against parasitic infection seems one of the principal roles of eosinophils in animals. The number of eosinophils is increased in tissues in many allergic disorders (e.g. in the nasal and bronchial mucosae in hay fever and asthma).<sup>1</sup>

**Corresponding Author:** Se Hoon Kim, Department of Pathology, College of Medicine, Yonsei University, 50 Yonsei-ro, Seodaemun-gu, Seoul, 120-752, Korea  
TEL: +82-2-2228-1769 FAX: +82-2-362-0860 E-mail: paxco@yuhs.ac

\* This work was supported by the Basic Science Research Program through a National Research Foundation grant funded by Korean Ministry of Education, Science & Technology to Se Hoon Kim (2010-0021092).

\* The first author and corresponding authors (J Choi and SH Kim) appreciate Dr. Tai Seung Kim for his inspiring and passionate teaching of neuropathology.

**Received:** August 30, 2012  
**Revised:** September 10, 2012  
**Accepted:** October 2, 2012

After differentiation in the bone marrow and release into the bloodstream, eosinophils persist in the circulation for 8–12 hours and can survive in tissues for an additional 8–12 days in the absence of stimulation.<sup>1</sup> Eosinophils in the context of chronic inflammatory processes and repair, can be observed in the organizing phase of cerebral hematoma (Fig. 1), but eosinophilic infiltration is also present in various human central nervous system (CNS) diseases including eosinophilic meningoencephalitis, hyper-eosinophilic encephalopathy syndrome, eosinophilic meningitis, peripheral neuropathy, and neoplastic lesions such as neuroblastoma, leiomyoma and glioblastoma.<sup>2</sup> Although the role of eosinophils in the pathogenesis of these diseases is not yet clearly defined, eosinophilia as well as the presence of eosinophils in the tissue specimen may provide surgical pathologists with a valuable clue to the diagnosis of a particular disease. In this short review, we will describe cases in which the identification of eosinophils on pathologic examination of a CNS lesion facilitated the diagnosis and highlight the diagnostic pitfalls that may be encountered in daily practice.

## EOSINOPHILS IN CEREBROSPINAL FLUID

A 32-year-old female patient presented with paresthesias of the leg and trunk. A lumbar puncture was performed for CSF analysis, which was consistent with myelitis. Many acute inflammatory cells were noted in the specimen (Fig. 2). The clinical diagnosis was transverse myelitis.

Lumbar puncture for cerebrospinal fluid (CSF) examination is one of the key procedures in the diagnosis of diseases of the central nervous system.<sup>3</sup> Since the CSF specimen is often stained using the

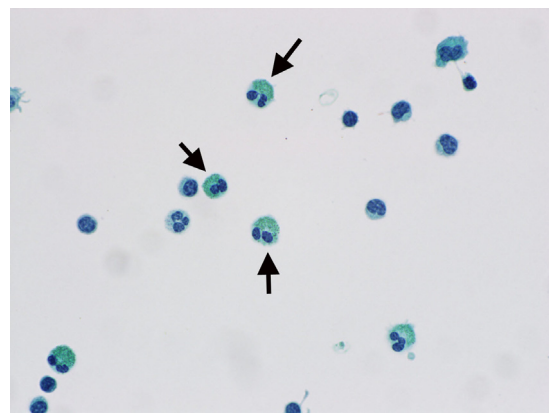


Fig. 2. Eosinophils in CSF (Papanicolaou stain, x 600). Green granulated cytoplasm with bi-lobed nuclei is characteristic (arrows).

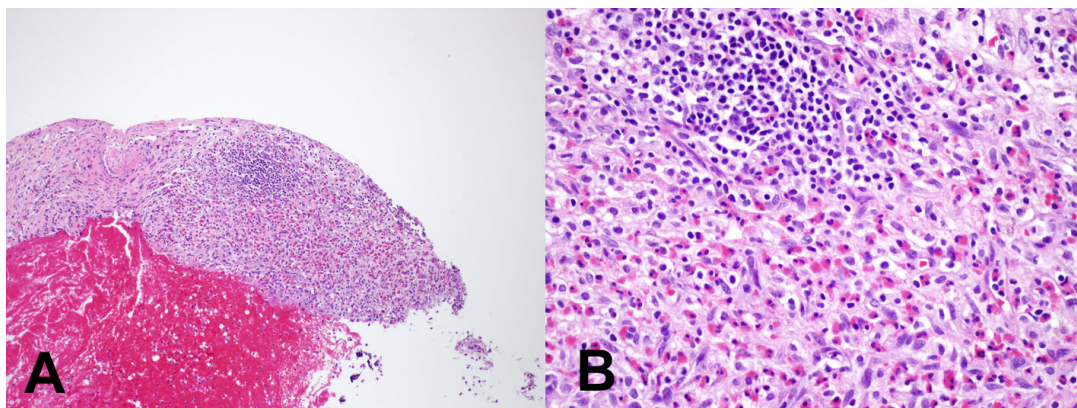


Fig. 1. Organizing hematoma: Low power view shows fresh hemorrhage with organization (A. H-E x 40). High power view shows eosinophilic infiltration into the granulation tissue (B. H-E x 200).

Papanicolaou method, it is very important to remember that the granules within eosinophils are not stained red or pink as usually described with the Papanicolaou method, but rather the granules are yellowish and refractile. Noting the characteristic bi-lobed nucleus of the cell enables the screener to recognize them more easily.<sup>4</sup> This finding may provide the physician with valuable information since eosinophils may be found in a certain form of tumefactive demyelinating disease. On routine histologic examination, eosinophils are easily identified with adequate hematoxylin-eosin (H-E) stain.<sup>5</sup> Overstaining by either one of hematoxylin or eosin or both, may lead to the inadequate staining of eosinophils. Therefore, it is important to consider that granulocytes with bi-lobed nuclei may represent eosinophils in inadequately processed histologic sections.

## EOSINOPHILS IN PARASITIC INFECTION

A 71-year-old man was admitted for generalized tonic-clonic seizures. The MRI study revealed a ring-enhancing lesion with edema in the right temporal lobe, suggestive of parasitic infection or

metastatic carcinoma. Peripheral eosinophilia was not present. During the operation, the surgeon found an abscess-like lesion with a hard shell without a grossly identifiable parasitic organism. The histologic examination revealed fragments of parasitic worms with acute and chronic inflammatory infiltrates with dense fibrosis, consistent with infection with *Taenia solium*, also known as cysticercosis. A few eosinophils in the fibrotic capsule were noted (Fig. 3).

Parasitic infection is one of the most common diagnoses encountered in a histologic section with eosinophilic infiltration in central nervous system specimens. Although the incidence of parasitic infection has markedly decreased in South Korea, it still comprises a large proportion of infectious disease in the CNS and the incidence of parasitic infection may increase as traveling outside of the country to endemic areas becomes more common. Among the variable etiologies of brain abscess, parasitic infection is higher on the differential diagnoses when eosinophils are present in the area adjacent to the lesion, although the infiltration of plasma cells rather than eosinophils dominates in many cases of parasitic infection, especially in those with chronic infection. Moreover, parts of the worm may not be identified or may have

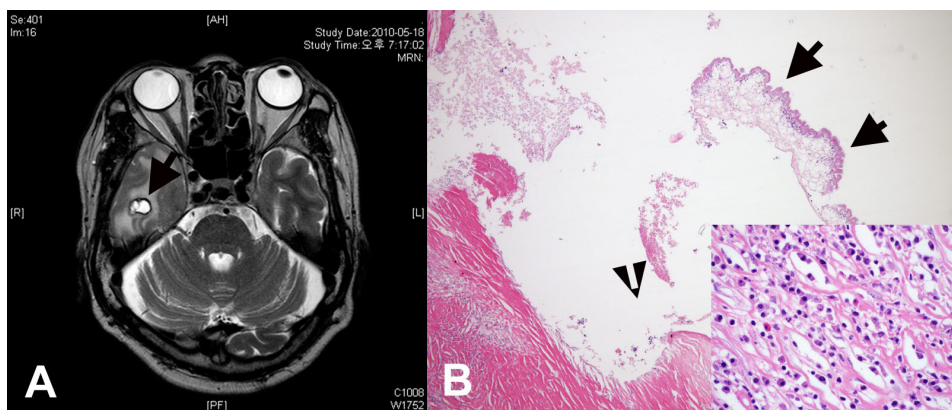


Fig. 3. A rim-enhancing lesion with edema in the right temporal lobe (A. arrow). Histologic section revealed a fragment of the worm (arrows) and dense fibrosis with a few eosinophilic infiltration (B. H-E x 40; inset. H-E x 200).

degenerated with calcification in many cases. Thus, identifying rare eosinophils in the lesion may provide a clue to the diagnosis. Additional serologic studies together with this finding may help the clinical diagnosis.

## EOSINOPHILS AS A POTENTIAL KEY PLAYER OF PATHOGENESIS OF TRANSVERSE MYELITIS

Transverse myelitis is a heterogeneous group of intramedullary inflammatory disorders of the spinal cord with acute and/or subacute clinical onset, and is likely an immune-mediated process. Postulated causes of the disease include infection, vaccination,

Guillain–Barre syndrome (GBS), multiple sclerosis (MS), acute disseminated encephalomyelitis (ADEM), neuromyelitis optica, paraneoplastic myelopathy, vascular insufficiency, and autoimmune disorders.<sup>6–8</sup>

Myelopathy with eosinophilic infiltration has been reported in parasitic myelitis<sup>9–12</sup> and idiopathic hypereosinophilic syndrome.<sup>12</sup> Especially in Japan, Kira et al. investigated myelitis with eosinophilic infiltration<sup>13–15</sup> and proposed the entity of ‘atopic myelitis (eosinophilic myelitis)’.<sup>16</sup> We have seen several cases of biopsy-confirmed myelitis with eosinophilic infiltration. The clinical findings of the patients are summarized in Table 1. All patients were male, and the age at the time of onset ranged from 35 to 46 years old. The lesions were in the cervical

Table 1. The clinicoradiologic features of 4 cases of transverse myelitis

	Case 1	Case 2	Case 3	Case 4
Age of onset	41	36	46	35
Sex	M	M	M	M
Level of lesions	T2–4	C1–5	C2–3	T6–9
Past Medical History	EGC*	–	–	–
Allergic History	–	Allergic rhinitis	–	–
Time course	Subacute	Subacute	Subacute	Subacute /chronic
Clinical course	Fluctuant	Persistent	Persistent	Persistent
Initial Symptoms	Hyperesthesia below right chest	Pain on post. Neck & Hyperesthesia on Lt hand	Hyperesthesia on Rt chest and back	Pain on both legs
Main symptom at biopsy				
Paresthesia/Dysesthesia	+	+	+	+
Sensory impairment	+	+	+	+
Motor weakness	+	+/-	–	–
Steroid therapy & Response	+	+	–	+
	/poor	/poor		/poor
Duration before biopsy	13 months	3 months	3 months	4 months
Lab findings				
% of eosinophil on CBC	5.2	5.2	5.9	3.0
Serum IgE concentration (U/ml)	Not checked	2010	Not checked	Not checked
MRI				
T2WI	High	High	High	Not done
T1WI	Iso	Iso	Iso	Not done
T1 Gd	+	+	+	Not done
CT	Not done	Not done	Not done	Mass like lesion

EGC\*: Early Gastric Cancer, MRI: Magnetic Resonance Imaging, CT: Computer Tomography

or thoracic spinal cords. The duration of the disease before biopsy ranged from 3 to 13 months. All patients had subacute or chronic onset of symptoms. Biopsies were undertaken in all patients to exclude spinal cord tumor. All patients had a similar clinical presentation with pain or hyperesthesia. All but one patient (Case No. 3) received steroid pulse therapy before biopsy without clinical response. Interestingly, there was no evidence of parasitic infection or autoimmune disease in four cases. Only one patient (Case No. 2) had mild allergic symptoms (allergic rhinitis) and a high serum IgE level. However, none had high peripheral eosinophil counts. All patients showed improvement in their symptoms after biopsy and high-dose steroid treatment, but none of the patients fully recovered. The clinical findings of four patients were similar to those of the patients described by Osoegawa et al.<sup>16</sup> The main histopathologic findings (Fig. 4) were: (1) perivascular and parenchymal lymphocytic infiltrations with many eosinophils, (Fig. 4A, 4B), (2)

degranulation of eosinophils, (Fig. 4B, 4D) and (3) reactive gliosis (Fig. 4C). In addition, giant cells (Fig. 4D), Charcot-Leyden crystal protein (Fig. 4E), and the degeneration of myelin and axons (Fig. 4F) were present in Case 1.

Osoegawa et al. suggested eosinophil-induced neural damage as one of the effector mechanisms in this clinical manifestation.<sup>15</sup> They stated that eosinophil infiltration was a unique histologic feature of atopic myelitis, and had never been reported in other spinal cord diseases such as neuromyelitis optica (NMO).<sup>16</sup> In contrast to their argument, another group reported eosinophilic infiltration in NMO<sup>17</sup> and the mouse experimental allergic encephalomyelitis model (experimental multiple sclerosis model) showed eosinophilic infiltration into the optic nerve in the early phase.<sup>18</sup> Considering previously described cases and our cases, it is reasonable to conclude that eosinophilic infiltration may not be the specific pathologic feature of atopic myelitis as they suggested.

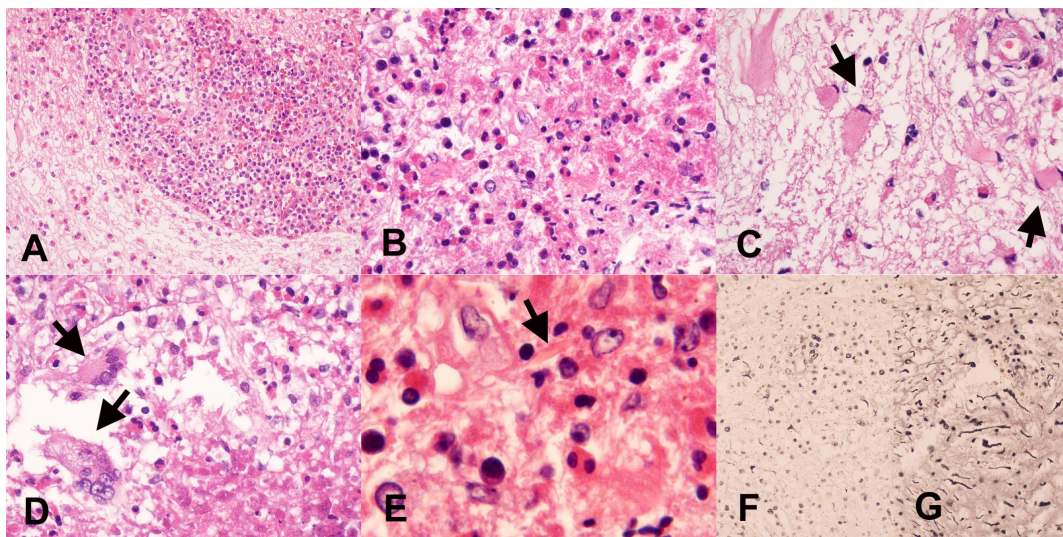


Fig. 4. The histologic findings of transverse myelitis. 1) perivascular and parenchymal lymphocytic infiltration with many eosinophils, (A. H-E x 200, B. H-E x 400), 2) degranulation of eosinophils, (B and D. H-E x 400) and 3) reactive gliosis (C. H-E x 400, arrows). In addition, giant cells (D. H-E x 400, arrows), Charcot-Leyden crystal protein (E. H-E x 1000, arrow), and the degeneration of myelin and axons (F. Bielschowsky's silver x 200) compared to control tissue (G. Bielschowsky's silver x 200) stain were present in Case 1.

Usually, clinically proven transverse myelitis is not an indication for biopsy and only the cases suspicious for neoplasm or with poor steroid response were biopsied. Thus, the histopathologic findings of transverse myelitis are not well described. We speculate that some of the cases reported as atopic myelitis may be related to so-called transverse myelitis given that they showed common histopathological characteristics, such as eosinophilic infiltration in the lesion. The patients in the present cases did not have any history of allergy or atopy, so the histopathologic finding of eosinophilic infiltration does not necessarily represent an allergic etiology of the disease. Rather, eosinophils may be recognized as one of the effector cells in this type of clinical disease. Our opinion is that the entity of atopic myelitis may belong to the larger clinical categories of transverse myelitis. Further investigation into the pathogenesis of those clinical entities is required, but the histological finding of eosinophilic

infiltration may provide a diagnostic clue to aid in the diagnosis of so-called transverse myelitis in a given clinical situation.

## EOSINOPHILS IN VASCULITIS

A 67-year-old man presented with persistent fever with mild constitutional symptoms. The symptoms were not relieved by antibiotics and headache with neck pain developed. A vascular lesion with beaded appearance was identified in the temporal area by PET-CT and a biopsy was performed. Intimal thickening with granulomatous inflammation and giant cell infiltration characteristic of giant cell arteritis were noted. Many eosinophils had infiltrated in the intima and media with degranulation (Fig. 5 A and B).

Several types of vasculitis affect the central nervous system. Vasculitis is characterized by inflammation and destruction of the blood vessel wall in the CNS,

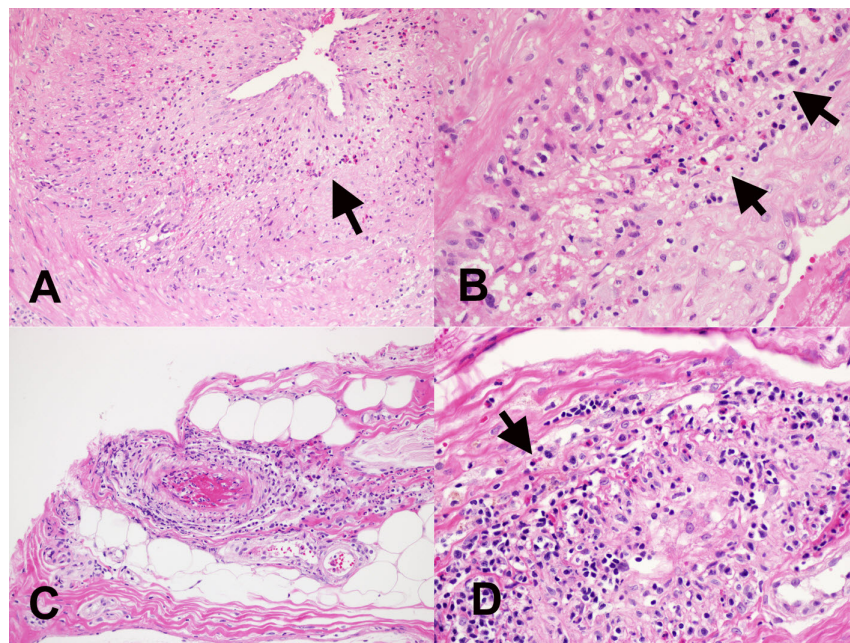


Fig. 5. The histologic findings of CNS vasculitis, Giant cell arteritis (A. H-E x 100 and B. H-E x 400) and Churg-Strauss vasculitis (C. H-E x 100 and D. H-E x 400). Eosinophilic infiltration is noted (arrows).

and can either be primary or secondary.<sup>19</sup>

Giant cell arteritis is a chronic inflammatory disorder of large- and medium-sized arteries involving mainly the temporal artery. The involvement of cranial arteries may cause headache, temporal swelling and tenderness as well as scalp necrosis, blindness and stroke in severe cases.<sup>20</sup> The main histopathologic findings consist of a chronic inflammatory reaction with lymphocytes, histiocytes and multinucleated giant cells. Neutrophil granulocytes are not part of the process, but it has been reported that a few eosinophils may be seen.<sup>20</sup>

Systemic vasculitis may involve the CNS. Among the different types, eosinophilic infiltration is typical in Churg–Strauss syndrome.<sup>21</sup> CNS involvement by Churg–Strauss syndrome was reported with features of necrotizing vasculitis with abundant eosinophils and extravascular eosinophilic granulomatous vasculitis, in 6–7% of patients.<sup>22,23</sup> (Fig. 5C and D) Microscopic polyangiitis is a systemic necrotizing vasculitis affecting small vessels with no or few immune deposits.<sup>24</sup> Dural involvement by microscopic polyangiitis has been reported in several case reports.<sup>25,26</sup> Diffuse infiltration by plasma cells and eosinophils was described.<sup>26</sup> One report described a tumor-like cerebral perivasculitis in a pediatric patient with systemic lupus erythematosus.<sup>27</sup> Brain biopsy revealed perivasculitis of the brain with marked perivascular infiltration of eosinophils, macrophages, and neutrophils.<sup>27</sup>

## **EOSINOPHILS IN LANGERHANS HISTIOCYTOSIS INVOLVING THE BRAIN**

Recently, the stereotactic biopsy has been an

essential diagnostic procedure for intracerebral masses. Due to the limitation of the amount of tissue acquired and fragmentation during the procedure, pathologists find that specimens often have a marked pinching artifact and hemorrhage, which makes the diagnosis complicated. The present case is a good example. Initial diagnosis was limited due to the pinching artifact and the degranulated eosinophilic granules, which might have provided a diagnostic clue for Langerhans histiocytosis, were it not recognized properly.

A 30-year-old man presented to the hospital with polyuria, sweating, and lethargy. He had no known medical history and there were no neurological abnormalities in the physical examination, but a decreased serum level of antidiuretic hormone was noted. Hyposexuality with abnormal testosterone level was also noted. Initially, magnetic resonance imaging (MRI) demonstrated abnormal thickening of the pituitary stalk which suggested non-specific inflammation, but this gradually progressed and eventually developed into a suprasellar solitary lesion (0.3 → 1.2 cm) beyond the optic chiasm. The biopsy revealed glial and fibrotic tissue showing inflammatory cell infiltrates with crushing artifact and was reported as non-diagnostic. With the tentative diagnosis of germinoma, the patient underwent 19.8 Gy trial of radiation therapy that failed. Follow-up imaging revealed an increased size of the mass and a second biopsy was performed. The second biopsy revealed abundant lymphoplasmic cells with fresh hemorrhage, findings suspicious for hypophysitis and lymphoma. A part of the biopsy showed a suspicious area where eosinophil degranulation mimicked the appearance of red blood cells; a few cells with folded nuclei were also observed (Fig. 6). These cells with

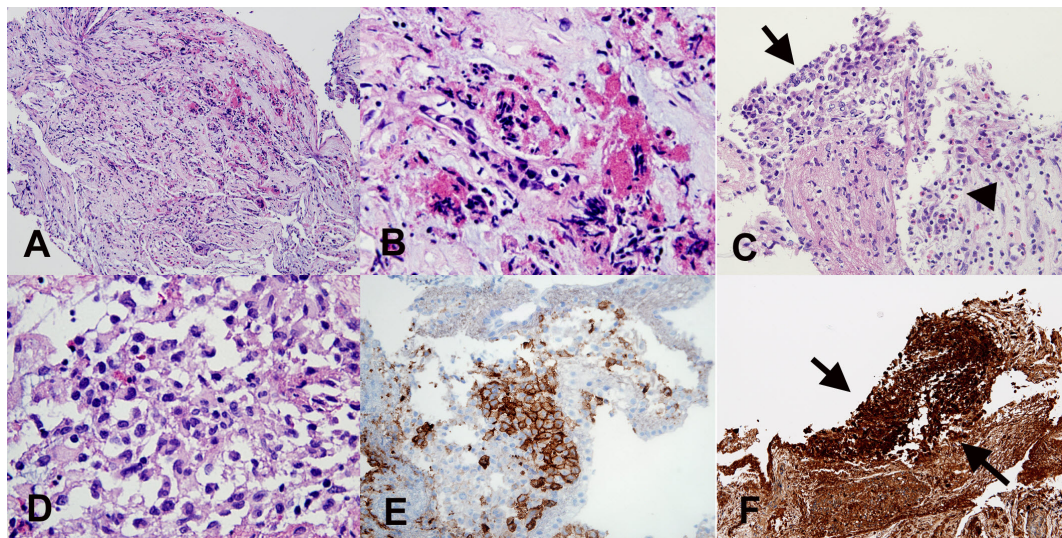


Fig. 6. The histologic findings of Langerhans cell histiocytosis with marked artifacts in CNS. Eosinophilic granules and inflammatory cells are seen in crushed focus (A. H-E x100 and B. H-E x 400). Aggregates of cells, which nuclei are eccentrically located and indented (arrow), mixed with eosinophilic granules (arrow head) are noted in rare area (C. H-E x 200 and D. H-E x 400). A cluster of large involuted nuclei show CD1a (E. CD1a x 200) and S-100 (F. S-100 x 100, arrows) immunohistochemical staining positivity.

involved nuclei had CD1a and S-100 immunopositivity. Upon review of the first biopsy, neither histologic nor immunohistochemical evidence of Langerhans cell histiocytosis were noted, but several scattered eosinophils were found. Langerhans cells often look like disrupted inflammatory cells, and the lakes of eosinophilic granules within eosinophils may be misidentified as erythrocytes. Thus identification of eosinophils and/or eosinophilic degranulation may provide a useful diagnostic clue, especially in a limited biopsy specimen.

## EOSINOPHILS IN GLIOBLASTOMA

Eosinophilic infiltration is also found in glioblastoma. We have seen several cases of glioblastoma showing eosinophilic infiltration. In many cases, it is concentrated in the peri-necrotic area, suggesting that this is part of the reparative process (Fig. 7A, B). Eosinophilic infiltration in the neoplastic lesion

has been reported in several human cancers including colonic adenocarcinoma,<sup>28</sup> cutaneous T cell lymphoma,<sup>29</sup> gastric cancer,<sup>30</sup> oral squamous cell carcinoma,<sup>31</sup> renal cell carcinoma<sup>32</sup> and malignant glioma.<sup>2</sup> In an in vivo murine model, the eosinophils seem to be recruited to the necrotic tissue, which is also a primary determinant of glioblastoma.<sup>33</sup> Eosinophils are an established effector cell in atopic disease and may therefore participate in the reported inverse associations between atopic disease (allergy, asthma, and eczema), and the risk of glioma, oral cancer, and gastrointestinal cancer.<sup>34</sup> Recently, Currant et al.<sup>2</sup> reviewed the role of eosinophils in glioblastoma tumorigenesis. They suggested that eosinophils may have roles in the initiation, promotion and progression of the disease. IL-4Ra-related response by IL-4 and IL-13 seems to enhance pro-eosinophilic chemokines and in certain cases, effective glioblastoma tumor eradication may occur in response to IL-4 and the concomitant recruitment of CD8+ T cells and eosino-

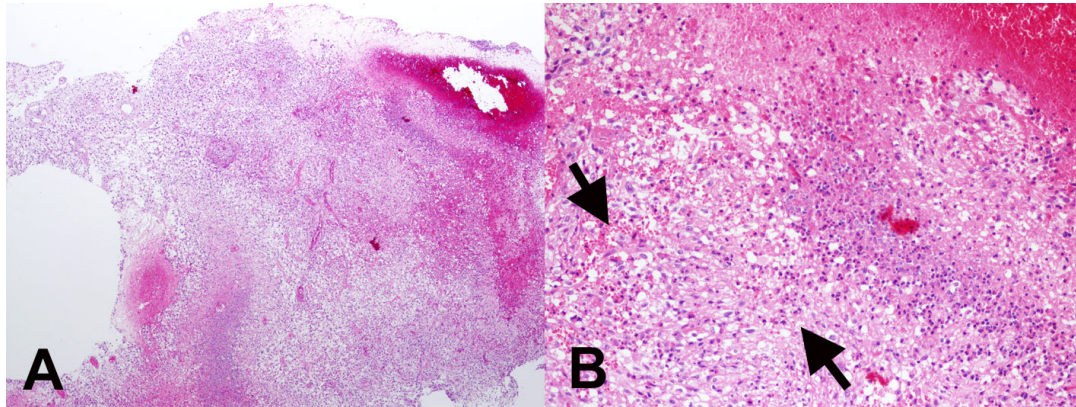


Fig. 7. Glioblastoma with eosinophils (A. H-E x40). Adjacent necrotic area, eosinophilic infiltration is noted (B. H-E x400, arrows).

phils.<sup>2</sup> Moreover, human astrocytes and glioblastoma tumor cells are known to produce GM-CSF,<sup>35,36</sup> which may enhance eosinophil-related oxidative stress. Platelet-derived growth factor (PDGF) and PDGF receptor are expressed in a subset of glioblastoma and this signaling pathway seems to be involved in the regulation of NF-kappa B activation and cell proliferation.<sup>37,38</sup> Eosinophils express PDGF receptor and may be activated by PDGF ligand, leading to activation with release of cytotoxic granules. This kind of response seems related to anti-tumor responses during tumor progression. Moreover, GM-CSF, known to be produced by glioblastoma, may activate eosinophils and in turn produce growth factors and matrix metalloproteinases in promoting tumorigenesis.<sup>36</sup> There is a possibility that the infiltration of eosinophils may reflect a condition that emerges in response to increased intracranial pressures or non-specific phenomenon related with the repair process. Further study is needed to elucidate the role of eosinophils in the pathogenesis of glioblastoma.

Due to morphologic and functional characteristics, the presence of eosinophils in certain lesions may provide a useful diagnostic clue if understood in the relevant clinical setting. Consideration of this finding

may facilitate the differential diagnosis of the lesion, especially in a small specimen such as a stereotactic biopsy.

## REFERENCES

1. Young B. *Wheater's functional histology : a text and colour atlas*. 5th ed. Edinburgh: Churchill Livingstone/Elsevier; 2006.
2. Curran CS, Bertics PJ. Eosinophils in glioblastoma biology. *J Neuroinflammation* 2012;9:11.
3. Seehusen DA, Reeves MM, Fomin DA. Cerebrospinal fluid analysis. *Am Fam Physician* 2003;68:1103-8.
4. Ramzy I. *Clinical cytopathology and aspiration biopsy : Fundamental principles and practice*. 2nd ed. New York: McGraw-Hill; 2001.
5. Luna LG. The quality control dilemma in Histotechnology: A possible answer. *Histologic* 1991;21:245-50.
6. Goffette S, Jeanjean AP, Duprez TP, Bigaignon G, Sindic CJ. Eosinophilic pleocytosis and myelitis related to *Toxocara canis* infection. *Eur J Neurol* 2000;7:703-6.
7. Harzheim M, Schlegel U, Urbach H, Klockgether T, Schmidt S. Discriminatory features of acute transverse myelitis: a retrospective analysis of 45 patients. *J Neurol Sci* 2004;217: 217-23.
8. Jeffery DR, Mandler RN, Davis LE. Transverse myelitis. Retrospective analysis of 33 cases, with differentiation of cases associated with multiple sclerosis and parainfectious events. *Arch Neurol* 1993;50:532-5.
9. Kawamura J, Kohri Y, Oka N. Eosinophilic meningoradiculo-

- myelitis caused by *Gnathostoma spinigerum*. A case report. *Arch Neurol* 1983;40:583-5.
10. Kerr DA, Ayetey H. Immunopathogenesis of acute transverse myelitis. *Curr Opin Neurol* 2002;15:339-47.
  11. Kikuchi H, Osoegawa M, Ochi H, Murai H, Horiuchi I, Takahashi H, et al. Spinal cord lesions of myelitis with hyperIgEemia and mite antigen specific IgE (atopic myelitis) manifest eosinophilic inflammation. *J Neurol Sci* 2001;183:73-8.
  12. Tsai CP, Yeh HH, Tsai JJ, Lin KP, Wu ZA. Transverse myelitis and polyneuropathy in idiopathic hypereosinophilic syndrome. *Muscle Nerve* 1993;16:112-3.
  13. Kira J, Yamasaki K, Kawano Y, Kobayashi T. Acute myelitis associated with hyperIgEemia and atopic dermatitis. *J Neurol Sci* 1997;148:199-203.
  14. Kira J, Kawano Y, Yamasaki K, Tobimatsu S. Acute myelitis with hyperIgEemia and mite antigen specific IgE: atopic myelitis. *J Neurol Neurosurg Psychiatry* 1998;64:676-9.
  15. Osoegawa M, Ochi H, Kikuchi H, Shirabe S, Nagashima T, Tsumoto T, et al. Eosinophilic myelitis associated with atopic diathesis: a combined neuroimaging and histopathological study. *Acta Neuropathol (Berl)* 2003;105:289-95.
  16. Osoegawa M, Ochi H, Minohara M, Murai H, Umehara F, Furuya H, et al. Myelitis with atopic diathesis: a nationwide survey of 79 cases in Japan. *J Neurol Sci* 2003;209:5-11.
  17. Lucchinetti CF, Mandler RN, McGavern D, Bruck W, Gleich G, Ransohoff RM, et al. A role for humoral mechanisms in the pathogenesis of Devic's neuromyelitis optica. *Brain* 2002;125:1450-61.
  18. Milici AJ, Carroll LA, Stukenbrok HA, Shay AK, Gladue RP, Showell HJ. Early eosinophil infiltration into the optic nerve of mice with experimental allergic encephalomyelitis. *Lab Invest* 1998;78:1239-44.
  19. Giannini C, Salvarani C, Hunder G, Brown RD. Primary central nervous system vasculitis: pathology and mechanisms. *Acta Neuropathol* 2012;123:759-72.
  20. Nordborg E, Nordborg C. Giant cell arteritis. In: Kalimo H, editor. *Pathology & Genetics Cerebrovascular Diseases*. Basel: International Society of Neuropathology; 2005. p.134-9.
  21. Bazile C, Keohane C, Gray F. Systemic Diseases and Drug-Induced Vasculitis. In: Kalimo H, editor. *Pathology & Genetics Cerebrovascular Diseases*. Basel: International Society of Neuropathology; 2005. p.151-62.
  22. Guillevin L, Cohen P, Gayraud M, Lhote F, Jarrousse B, Casassus P. Churg-Strauss syndrome. Clinical study and long-term follow-up of 96 patients. *Medicine* 1999;78:26-37.
  23. Na SJ, Lee KO, Ko JH. Eosinophilic vasculitis of the spinal cord associated with Churg-Strauss syndrome. *J Neurol Sci* 2010;295:107-9.
  24. Jennette JC, Falk RJ. Small-vessel vasculitis. *N Engl J Med* 1997;337:1512-23.
  25. Kono H, Inokuma S, Nakayama H, Yamazaki J. Pachymeningitis in microscopic polyangiitis (MPA): a case report and a review of central nervous system involvement in MPA. *Clin Exp Rheumatol* 2000;18:397-400.
  26. Furukawa Y, Matsumoto Y, Yamada M. Hypertrophic pachymeningitis as an initial and cardinal manifestation of microscopic polyangiitis. *Neurology* 2004;63:1722-4.
  27. Huang CH, Hung CH, Chu YT, Hua YM. Tumor-like cerebral perivasculitis in a pediatric patient with systemic lupus erythematosus. *Kaohsiung J Med Sci* 2008;24:218-22.
  28. Moezzi J, Gopalswamy N, Haas RJ Jr, Markert RJ, Suryaprasad S, Bhutani MS. Stromal eosinophilia in colonic epithelial neoplasms. *Am J Gastroenterol* 2000;95:520-3.
  29. Kural YB, Su O, Onsun N, Uras AR. Atopy, IgE and eosinophil cationic protein concentration, specific IgE positivity, eosinophil count in cutaneous T Cell lymphoma. *Int J Dermatol* 2010;49:390-5.
  30. Iwasaki K, Torisu M, Fujimura T. Malignant tumor and eosinophils. I. Prognostic significance in gastric cancer. *Cancer* 1986;58:1321-7.
  31. Dorta RG, Landman G, Kowalski LP, Lauris JR, Latorre MR, Oliveira DT. Tumour-associated tissue eosinophilia as a prognostic factor in oral squamous cell carcinomas. *Histopathology* 2002;41:152-7.
  32. Moroni M, Porta C, De Amici M, Quaglini S, Cattabiani MA, Buzio C. Eosinophils and C4 predict clinical failure of combination immunotherapy with very low dose subcutaneous interleukin-2 and interferon in renal cell carcinoma patients. *Haematologica* 2000;85:298-303.
  33. Cormier SA, Taranova AG, Bedient C, Nguyen T, Protheroe C, Pero R, et al. Pivotal Advance: eosinophil infiltration of solid tumors is an early and persistent inflammatory host response. *J Leukoc Biol* 2006;79:1131-9.
  34. Sherman PW, Holland E, Sherman JS. Allergies: their role in cancer prevention. *Q Rev Biol* 2008;83:339-62.
  35. Mueller MM, Herold-Mende CC, Riede D, Lange M, Steiner HH, Fusenig NE. Autocrine growth regulation by granulocyte colony-stimulating factor and granulocyte macrophage colony-stimulating factor in human gliomas with tumor progression.

- Am J Pathol 1999;155:1557-67.
36. Curran CS, Evans MD, Bertics PJ. GM-CSF production by glioblastoma cells has a functional role in eosinophil survival, activation, and growth factor production for enhanced tumor cell proliferation. *J Immunol* 2011;187:1254-63.
  37. Smith D, Shimamura T, Barbera S, Bejcek BE. NF-kappaB controls growth of glioblastomas/astrocytomas. *Mol Cell Biochem* 2008;307:141-7.
  38. Ranza E, Facoetti A, Morbini P, Benericetti E, Nano R. Exogenous platelet derived growth factor (PDGF) induces human astrocytoma cell line proliferation. *Anticancer Res* 2007;27:2161-6.

### **Peer Reviewers' Commentary**

Eosinophilic infiltration is also present in various human central nervous system (CNS) diseases such as parasitic infection, transverse myelitis, vasculitis, Langerhans cell histiocytosis, glioblastoma and etc... Due to the morphologic and functional characteristics, the presence of eosinophils in certain lesions may provide useful diagnostic clues in the right clinical setting. Consideration of this finding may facilitate the diagnosis of CNS pathologic lesions, especially in a small specimen such as a stereotactic biopsy. In this review, eosinophilia as well as the presence of eosinophils in the tissue specimen may provide surgical pathologists with a valuable clue to the diagnosis of a particular disease.

(정리: 편집위원회)