

## Clinical Article

# The Effect of Microvascular Decompression for Hemifacial Spasm Caused by Vertebrobasilar Dolichoectasia

Jeong-Han Kang, M.D.,<sup>1,2</sup> Dong-Wan Kang, M.D., Ph.D.,<sup>3</sup> Sang Sup Chung, M.D., Ph.D.,<sup>4</sup> Jin Woo Chang, M.D., Ph.D.<sup>1</sup>

*Department of Neurosurgery,<sup>1</sup> Severance Hospital, Brain Korea 21 Project for Medical Science, Brain Research Institute, Yonsei University College of Medicine, Seoul, Korea*

*Department of Neurosurgery,<sup>2</sup> Gandong Sacred Heart Hospital, Hallym University College of Medicine, Seoul, Korea*

*Department of Neurosurgery,<sup>3</sup> Pusan National University Hospital, Busan, Korea*

*Department of Neurosurgery,<sup>4</sup> Bundang CHA Hospital, CHA University, Seongnam, Korea*

**Objective :** Hemifacial spasm (HFS) caused by vertebrobasilar dolichoectasia (VBD) is very rare, and in these cases, it is difficult to decompress the nerve from its vascular compression. The objective of this study was to investigate the outcome of microvascular decompression (MVD) for HFS caused by VBD.

**Methods :** There were 10 patients of HFS caused by VBD at our hospital between September 1978 and September 2008. We evaluated magnetic resonance angiography (MRA) and time of flight magnetic resonance imaging (TOF MRI) findings using the criteria for VBD. We compared the clinical outcomes of MVD for the 10 patients with VBD with the overall outcomes of the total 2058 MVDs performed for HFS.

**Results :** The results of MVD for HFS caused by VBD were successful in 90.9% of cases. The postoperative complication rate in VBD was 45.5%. Offending vessels in patients with VBD were identified visually during surgery. Adverse effects after MVD were found in 4 patients. We found that the diameter of VBD was significantly greater in patients with complications than in those with no complications ( $p=0.028$ )

**Conclusion :** Our data shows that MVD may be a good treatment modality for HFS caused by VBD but care must be taken to avoid adverse effects from the procedure. It is important to detach the dolichoectatic artery from its surrounding structures sufficiently to allow it to be easily movable. In addition, attempts should be made to lessen the retraction of the cerebellum during release of the dolichoectatic artery.

**Key Words :** Microvascular decompression · Hemifacial spasm · Vertebrobasilar dolichoectasia.

## INTRODUCTION

Hemifacial spasm (HFS) is a hyperactive cranial nerve dysfunction syndrome characterized by unilateral involuntary contractions of muscles innervated by the affected facial nerve. Causes of HFS include blood vessel, tumor, and bony abnormality<sup>15</sup>. Since Campbell and Keedy<sup>2</sup> first described vascular arterial compression of the facial nerve among patients with HFS. The cause of this condition is thought to be mainly neurovascular compression of the facial nerve at its root exit zone (REZ) from the brainstem<sup>13</sup>. Therefore, microsurgical neurovascular decompression (MVD) is now widely performed as

the most logical and curative treatment of HFS.

In general, the offending vessels are the anterior inferior cerebellar artery (AICA), posterior inferior cerebellar artery (PICA), vertebral artery (VA), or branches of these main arteries encountered during MVD. HFS caused by vertebrobasilar dolichoectasia (VBD), however, is quite rare<sup>30</sup>. The offending in cases of VBD is difficult to move during MVD due to its character of enlargement and elongation. We have experienced several cases of MVD for HFS resulting from VBD. We compared outcomes of MVD for HFS caused by VBD with the outcomes of non-VBD cases, and analyzed the complication occurrence rate in MVD for HFS related with VBD.

• Received : December 29, 2011 • Revised : May 28, 2012 • Accepted : August 19, 2012

• Address for reprints : Jin Woo Chang, M.D., Ph.D.

Department of Neurosurgery, Severance Hospital, Brain Korea 21 Project for Medical Science, Brain Research Institute, Yonsei University College of Medicine, 50 Yonsei-ro, Seodaemun-gu, Seoul 120-752, Korea

Tel : +82-2-361-5624, Fax : +82-2-393-9979, E-mail : jchang@yuhs.ac

• This is an Open Access article distributed under the terms of the Creative Commons Attribution Non-Commercial License (<http://creativecommons.org/licenses/by-nc/3.0>) which permits unrestricted non-commercial use, distribution, and reproduction in any medium, provided the original work is properly cited.

## MATERIALS AND METHODS

### Definitions

VBD refers to enlargement and elongation of the vertebrobasilar artery. To diagnose VBD, we need criteria that specifically define enlargement and elongation of the vertebrobasilar artery. Smoker et al.<sup>28,29</sup> reviewed normal high-resolution computed tomographic (CT) scans of 123 patients and defined the diameter, the height of the bifurcation, and the transverse position of the normal basilar artery. According to Smoker's criteria, we use the term elongation if the basilar artery, at any point throughout its course, lies in a lateral position to the margin of the clivus or dorsum sellae (Position 2, 3) (Table 1) or if the artery bifurcation lies above the plane of the suprasellar cistern (Height 2, 3) (Table 2). Enlargement is diagnosed if the diameter of the basilar artery is greater than 4.5 mm. Giang et al.<sup>9</sup> reported that MRI diagnosed VBD as well as CT, and it was proved to be superior to CT in delineating the anatomical relationship of the vessels to the neural structures. Therefore, although Smoker et al. defined the normal basilar artery based on data from CT imaging, we measured elongation and en-

largement on time of flight magnetic resonance image (TOF MRI) and magnetic resonance angiography (MRA).

### Patient population

A total of 2,064 MVDs for HFS were performed at our institution between September 1978 and September 2008. In six patients, HFS was not resulting from a blood vessel, and these patients were excluded from the current study. Among the remaining 2058 cases with vascular compression, 2047 cases (99.5%) had non-VBD HFS, and 11 cases (0.5%) had HFS caused by VBD. One patient with HFS caused by VBD had bilateral HFS and underwent 2-stage MVD. The clinical outcomes and image findings of TOF MRI and MRA of these 11 cases were analyzed.

### TOF MRI and MRA evaluation

We retrospectively evaluated the available preoperative images from TOF MRI and MRA, which were performed with a 1.5-Tesla imaging system (Signa; GE Medical Systems, Milwaukee, WI, USA). Enlargement of the vertebrobasilar artery was measured on MRA by Picture Archiving Communication System (PACS; GE Medical Systems, Milwaukee, WI, USA) and diagnosed if the diameter of the basilar artery was greater than 4.5 mm. Elongation was evaluated on TOF MRI and diagnosed in the case of position 2 or 3 or height 2 or 3 (Table 1, 2).

### Surgical procedures

In all patients, exposure and dissection were performed using standard surgical techniques for microvascular decompression procedures with the lateral decubitus position through a lateral retrosigmoid suboccipital craniectomy<sup>14,19</sup>.

In patients with VBD, a wider retrosigmoid suboccipital craniectomy was done to reach at the sigmoid sinus. Dissection of the arachnoid membranes was carefully continued from the lower cranial nerves up to the petrosal vein to enhance the exposure and mobilization of the cerebellum. Release of the VBD artery (VA or BA) was meticulously obtained not only near the REZ but also from the proximal portion to the distal for as great a distance as possible. In this way, the VBD artery was made to move easily, to allow complete decompression of the nerve, and stretching of the seventh and eighth cranial nerves was lessened during the insertion of Teflon felt

**Table 1.** Criteria for assignment of basilar artery position

Position	Most lateral position identified throughout course of basilar artery
0	Midline throughout
1 (R or L)	Medial to lateral margin of clivus or dorsum sellae
2 (R or L)	Lateral to lateral margin of clivus or dorsum sellae
3 (R or L)	In cerebellopontine angle cistern

R : right, L : left

**Table 2.** Criteria for assignment of basilar artery height

Height	Plane of Basilar Bifurcation
0	At or below dorsum sellae
1	Within suprasellar cistern (one cut above dorsum)
2	At level of third ventricle floor (one cut above suprasellar cistern)
3	Indenting and elevating floor of third ventricle (two or more cuts above suprasellar cistern)

0.6 mm-thick, time of flight magnetic resonance image

**Table 3.** Clinical characteristics of 2058 cases with hemifacial spasm treated by microvascular decompression

	Non-VBD (n=2,047)	VBD (n=11)
Age (years)	49.4 (20-77)	55.6 (43-69)
Sex	Men	5 (45.5%)
	Women	6 (54.5%)
Symptom duration (years)	7 (1-40)	5 (1-20)
Postoperative follow-up (months)	17 (6-226)	21.5 (4-76)
Offending vessel	AICA	4 (36.3%)
	PICA	1 (9.1%)
	VA	1 (9.1%)
	Multiple	5 (45.5%)
	Venous	0

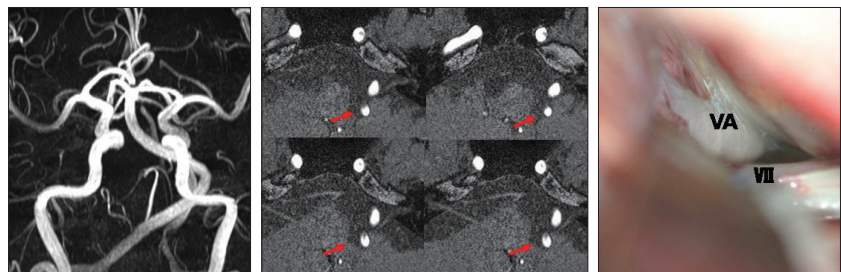
VD : vertebrobasilar dolichoectasia, AICA : anterior inferior cerebellar artery, PICA : posterior inferior cerebellar artery, VA : vertebral artery

**Table 4.** Summary of eleven cases of hemifacial spasm caused by vertebrobasilar dolichoectasia

Case no.	Age (y)/Sex	Symptom duration (y)	Symptom side	Intra-OP offender	TOF-MRI and MRA			Result	Complication
					Diameter (mm)	Height	Position		
1*	51/F	1	Left	VA, PICA	5.93	3	1	Excellent	FP, HI
2	48/M	2	Right	AICA (BA)	5.34	2	2	Excellent	FP
3*	57/F	2	Right	AICA	5.93	3	1	Excellent	
4	69/M	5	Left	Right VA	4.90	2	2	Good	P-FP
5	60/M	20	Left	AICA (VA)	4.91	3	1	Excellent	
6	43/M	2	Left	VA, PICA	4.95	2	2	Excellent	FP
7	56/F	4	Right	AICA (VA)*	4.62	0	2	Fair	
8	62/F	6	Left	VA, PICA	4.61	0	2	Excellent	
9	61/M	5	Left	PICA (VA)*	4.98	0	2	Excellent	
10	59/F	5	Left	VA, PICA	4.65	3	2	Excellent	
11	46/F	4	Left	VA, PICA	4.75	1	2	Excellent	

\*one patient who had bilateral HFS and underwent MVD twice. ( ) : over offender vessel, not direct contact. TOF-MRI : time of flight magnetic resonance image, VA : vertebral artery, PICA : posterior inferior cerebellar artery, AICA : anterior inferior cerebellar artery, BA : basilar artery, FP : facial palsy. P-FP : permanent facial palsy, HI : hearing impairment

and balls to reposition the offending vessels. After the vessel was freed, Teflon felt and balls were inserted in a step-by-step manner without retraction of the vessel. The first Teflon was placed between the vessel and the nerve beside the compression site and was then gently pushed along the nerve toward the compression site. As second Teflon was placed where the first was originally positioned, and this was repeated, until complete vascular decompression was achieved.



**Fig. 1.** Preoperative MRI and photograph taken during surgery of a patient with right VA offender. The patient was 69-year-old man with a left side facial spasm for 5 years. Preoperative MRI shows that right side VA compressed left facial nerve at the REZ (red arrows). Photograph was taken before neurovascular decompression was performed. Surgical outcome was ‘good’ but permanent facial palsy developed. VA basilar artery, VII facial nerve. VA : vertebral artery, REZ : root exit zone.

**Clinical assessment and follow-up review**

The clinical data and intra-operative findings of the selected patients were reviewed retrospectively. After MVD, the patients were classified into the following five grades, on the basis of the degree of HFS present : 1) “excellent” if no HFS was present; 2) “good” if the HFS was more than 90% resolved; 3) “fair” if the HFS was more than 50% resolved; 4) “poor” if the HFS was less than 50% resolved; and 5) “failure” for all remaining results. Outcomes of “excellent” and “good” were considered successful outcomes. Clinical outcomes were evaluated immediately after the surgery and at outpatient visits during the subsequent follow-up period.

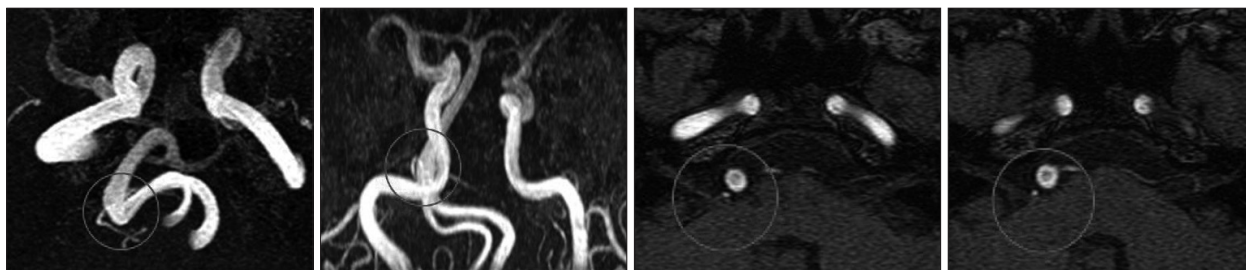
**Statistical analysis**

Comparisons between two groups (non-VBD vs. VBD) were tested for statistical significance with the Fisher exact test. The complication occurrences of VBD were assessed using the Mann-Whitney test. Probability values were 2-tailed, and values of  $p < 0.05$  were considered significant. Case no 3 (Table 4) was excluded from statistical analysis, because it did not involve a dolichoectatic artery. All data analyses were performed with PASW statistics version 18.0 (SPSS Inc., Somers, NY, USA).

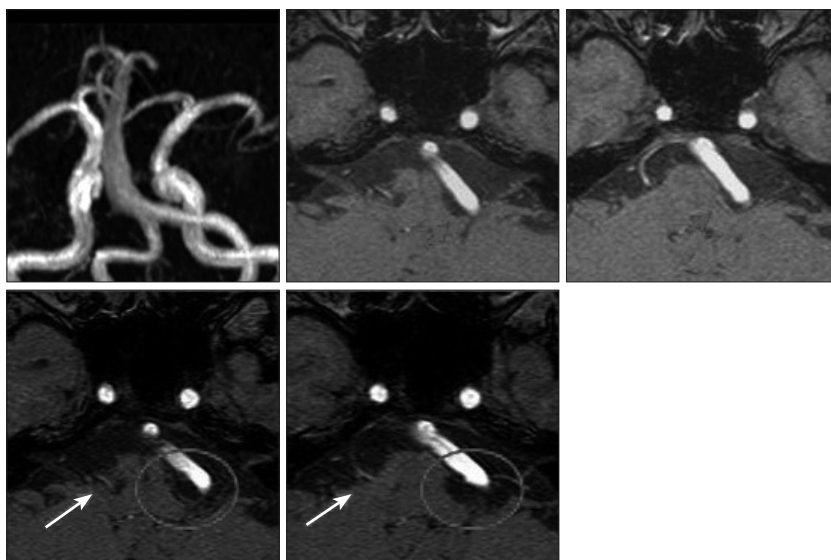
**RESULTS**

The clinical characteristics of 2,058 cases of HFS treated by MVD are summarized in Table 3. The diameter, height, and transverse position of the basilar arteries of the VBD cases are presented in Table 4. The mean diameter of the basilar arteries was 5.05 mm (range, 4.61-5.93 mm). Offending vessels identified visually during surgery were 4 AICA, 1 PICA, 1 VA, and 5 multiple artery. A patient with right offending VA (case no 4) (Fig. 1) had left-sided facial spasm. In all cases except one, the VA or basilar artery (BA, case no 2) (Fig. 2) affected neurovascular compression of the facial nerve directly or over the offending vessel. One case (case no 3) (Fig. 3) had only the AICA as the offending vessel, not related with VA or BA compression. This patient had bilateral HFS that required 2-stage MVD.

Levels of successful outcomes were 93.1% in non-VBD and 90.9% in VBD, a difference which was not statistically significant ( $p=0.779$ ) (Table 5). Postoperative complications related to facial nerve and cochlear nerve in non-VBD were noted in 24.7% (permanent in 2.4%) these complications included facial palsy in 18.5% (permanent in 0.9%) and hearing impairment in 6.1% (permanent in 1.5%). However, the postoperative complication



**Fig. 2.** Preoperative MRI of a patient with AICA offender and BA over AICA. The patient was 48-year-old man with right side facial spasm for 2 years. Preoperative MRI shows that AICA compressed facial nerve and BA is over AICA offender (circle) at the REZ. During MVD, we made an effort to make BA movable freely. After surgery, HFS completely resolved but transient facial palsy occurred. AICA : anterior inferior cerebellar artery, REZ : root exit zone, MVD : microsurgical neurovascular decompression, BA : basilar artery.



**Fig. 3.** Preoperative and postoperative MRI of a patient with bilateral HFS. The patient was 50s woman with bilateral HFS. Left side facial spasm resulting from VA and PICA occurred one year before first MVD. Preoperative MRI shows that dolichoectatic VA and PICA compressing left facial nerve at the REZ (short arrow). After MVD, left HFS completely resolved but transient facial palsy and hearing impairment occurred. Right side HFS occurred 4 years after left MVD. We obtained postoperative MRI showing that only AICA compressed facial nerve (long arrow) and that complete decompression of left facial nerve was done (circle). After right MVD, right HFS completely disappeared without any complication. In the right HFS, VBD did not affect the offender. HFS : hemifacial spasm, VA : vertebral artery, PICA : posterior inferior cerebellar artery, REZ : root exit zone, MVD : microsurgical neurovascular decompression, VBD : vertebrobasilar dolichoectasia.

**Table 5.** Surgical outcome and complications after microvascular decompression for hemifacial spasm in 2058 cases

		Non-VBD (n=2047)	VBD (n=11)	p value
Outcome	Successful	1905 (93.1%)	10 (90.9%)	0.779
	Excellent	1791 (87.5%)	9 (81.8%)	
	Good	114 (5.6%)	1 (9.1%)	
	Fair	88 (4.3%)	1 (9.1%)	
	Poor	25 (1.2%)	0	
	Failure	29 (1.4%)	0	
Complication	7th and 8th nerve	506 (24.7%)	5 (45.5%)	0.154
	Transient FP	361 (17.6%)	3 (27.2%)	
	Permanent FP	19 (0.9%)	1 (9.1%)	
	Transient HI	95 (4.6%)	1 (9.1%)	
	Permanent HI	31 (1.5%)	0	

VBD : vertebrobasilar dolichoectasia, FP : facial palsy, HI : hearing impairment

rate in VBD was 45.5%, greater than the rate of 24.7% in non-VBD. There was transient facial palsy in three cases (27.2%), transient hearing impairment in one case (9.1%), and one permanent case of facial palsy (9.1%). There was no statistical difference in the overall complication rate ( $p=0.154$ ).

There were 5 cases of complications in the group of patients with VBD. Table 6 shows the results of the analysis of complication occurrence in VBD. There was no statistically significant difference in age and sex ratio between the complication and no complication groups. Diameter of the VBD was significantly greater in the complication group than in the group with no complications ( $p=0.028$ ). However, there were no statistically significant differences in height and position of the VBD between the complication and no complication groups.

## DISCUSSION

VBD is a rare arteriopathy characterized by elongation and enlargement of the vertebrobasilar artery with subsequent thrombosis, micro-embolization, and brainstem compression, with or without aneurysm formation<sup>6,11,12,16,18,21,31,34,35</sup>. This arteriopathy is known to cause variable neurologic deficits, including combined brainstem and cranial nerve syndromes<sup>3,6,7,12,24,31</sup>, cervicomedullary junction compression<sup>12,16,18,20,31,33</sup> transient or permanent motor deficits<sup>12,16,20,21,23,35</sup>, cerebellar dysfunction<sup>16</sup>, central sleep apnea<sup>22</sup>, hydrocephalus, ischemic stroke<sup>33,35</sup>, and subarachnoid hemorrhage<sup>5,8,26</sup>. VBD is a potentially serious

condition that may cause severe disability due to ischemic or compressive dysfunction in the posterior fossa<sup>27,32</sup>. VBD itself may cause hemodynamic changes leading to thrombosis and microembolization<sup>32</sup>. Furthermore, manipulation of the dolichoectatic artery during surgical procedures may also result in these hemodynamic changes. Therefore, an effort should be made to minimize the manipulation of the dolichoectatic artery in order to prevent ischemic dysfunction in the posterior fossa. In the procedure described here, the VBD artery was released from the proximal

portion to the distal as far along its length as possible before decompression of the seventh nerve, and Teflon felt and balls were inserted in stepwise manner without retraction of the vessel. In our study, 10 patients had hemifacial spasm caused by VBD without any other neurologic deficits preoperatively, and fortunately, no ischemic dysfunction occurred following microsurgical neurovascular decompression.

Hemifacial spasm caused by VBD has been reported previously<sup>1,3,10,25,27,30</sup>. In these cases, vascular compression of the facial nerve at the root entry zone was considered the cause of HFS. There are also reported cases of HFS related with a dolichoectatic artery. Chakravarty<sup>4</sup>) reported HFS resulting from pontine compression by a large fusiform dolichoectatic basilar artery without any compression of the facial nerve at the REZ. In all our cases, we identified an offending artery compressing the facial nerve at the REZ. There was direct compression of the facial nerve by the VA in six cases, including right VA compression of the left facial nerve (Fig. 1), compression by the VA or BA (Fig. 2) over the offending vessel in four cases, and compression by the AICA alone, with no relation to a dolichoectatic artery (Fig. 3), in one case. One patient (case no 1 and 3) (Fig. 3) who had only the AICA offending vessel on the right side, underwent microsurgical neurovascular decompression for HFS in left side first. The left side offending vessels were the VA and PICA. Even though this patient had VBD, microsurgical neurovascular decompression for the right side was similar to other usual decompression procedure. A dolichoectatic artery as the offending vessel or over the offending vessel makes surgical procedures difficult to perform completely without any complications because of its character of enlargement and elongation.

The prevalence of VBD is 0.5% of all HFS patients in this study. Even though VBD is a very rare arteriopathy, there is the problem of selection and referral bias in these results. The male to female ratio in VBD is greater than in non-VBD (1 : 1.2 vs. 1 : 3). Multiple offending vessels are more frequent in VBD than in non-VBD (45.5% vs. 12.5%). In our study, a success rate of 90.9% was achieved in VBD, similar to the 93.2% success rate in non-VBD ( $p=0.779$ ). If the dolichoectatic artery is released

**Table 6.** Analysis of complication occurrence in microvascular decompression for hemifacial spasm related with vertebrasilar dolichoectasia

	Complication (n=5)	No complication (n=6)	p value
Age (yr)	52.4 (43-69)	57.8 (46-62)	0.271
Males (%)	60	33.4	0.399
Diameter (mm)	5.41 (4.90-5.93)	4.75 (4.61-4.98)	0.028
Height			0.182
0	0	3	
1	0	1	
2	3	0	
3	2	2	
Position			0.409
1	2	1	
2	3	5	

only near the REZ, it is difficult and dangerous to retract the dolichoectatic artery to directly insert Teflon felt and balls into the compression site because of the artery's character of enlargement and the ischemic attack risk. Successful neurovascular decompression could be performed without retraction of dolichoectatic artery with sufficient release of the artery and a step-by-step manner of insertion of the Teflon. It is thus a mandatory step in neurovascular decompression to release the dolichoectatic artery from surrounding structures enough to allow its easy movement, as in the procedure described here. Nevertheless, one patient in our study (case no 1) developed transient facial weakness and hearing impairment, two patients (case no 2, 6) developed transient facial weakness, and one (case no 4) developed permanent facial weakness. Although the difference was not statistically significant ( $p=0.154$ ), the postoperative complication rate (45.5%) in VBD was higher than that in non-VBD (24.7%). Excessive retraction of the cerebellar flocculus to obtain surgical visibility during release of the dolichoectatic artery from its surrounding structure might play a role in increasing the complication rate. We analyzed the occurrence of complications in VBD (Table 6). Our findings suggest that the degree of height and position of the VBD may not contribute to the occurrence of complications. Only increase of diameter of the VBD was significantly associated with the occurrence of complications ( $p=0.028$ ) in our study. This result shows that the enlargement character of the VBD may be meaningful in development of complications. In fact, increase of a dolichoectatic artery's diameter results in much more increase of volume of that artery. Therefore, much greater retraction of the cerebellum may be needed to obtain sufficient release of the artery. A wider craniectomy and dissection of the arachnoid membranes from the lower cranial nerves up to the petrosal vein to enhance the exposure and mobilization of the cerebellum, the procedures followed here, are helpful for lessening retraction of cerebellum during release of the dolichoectatic artery, but not enough to prevent complications. Recently, some authors have used an endoscope to assist in the decompression procedure of trigeminal neuralgia or HFS caused by an elongated, tortuous

or enlarged VA or BA<sup>17</sup>). The use of an endoscope is another method that may prevent complications through lessening retraction of the cerebellum. To prevent postoperative complications, minimal manipulation of the dolichoectatic artery and lessening retraction of the cerebellum should be achieved.

## CONCLUSION

In this study, there were no statistically significant difference in surgical outcomes of MVD between VBD and non-VBD. Therefore, we would recommend microsurgical neurovascular decompression as treatment for hemifacial spasm caused by VBD. To obtain good outcomes and to reduce postoperative complication, the dolichoectatic artery, from the proximal portion to the distal, must be made sufficiently free from its surrounding structures before neurovascular decompression without excessive retraction of the cerebellum.

### • Acknowledgements

This study was supported by the Industrial Source Technology Department Program (No. 10033812) of the Ministry of Knowledge Economy (MKE) of Korea.

### References

1. Arantes M, Garcia R, Pereira JR, Costa M : [Hemifacial spasms and vertebral dolichoectasias]. *Rev Neurol* 47 : 468-470, 2008
2. Campbell E, Keedy C : Hemifacial spasm; a note on the etiology in two cases. *J Neurosurg* 4 : 342-347, 1947
3. Carella A, Caruso G, Lamberti P : Hemifacial spasm due to elongation and ectasia of the distal segment of the vertebral artery. Report of two cases. *Neuroradiology* 6 : 233-236, 1973
4. Chakravarty A : Hemifacial spasm, glossodynia, and dolichoectasia of the basilar artery. *J Stroke Cerebrovasc Dis* 21 : 78-81, 2012
5. De Georgia M, Belden J, Pao L, Pessin M, Kwan E, Caplan L : Thrombus in vertebralbasilar dolichoectatic artery treated with intravenous urokinase. *Cerebrovasc Dis* 9 : 28-33, 1999
6. de Oliveira Rde M, Cardeal JO, Lima JG : [Basilar ectasia and stroke : clinical aspects of 21 cases]. *Arq Neuropsiquiatr* 55 : 558-562, 1997
7. Deeb ZL, Jannetta PJ, Rosenbaum AE, Kerber CW, Drayer BP : Tortuous vertebralbasilar arteries causing cranial nerve syndromes : screening by computed tomography. *J Comput Assist Tomogr* 3 : 774-778, 1979
8. Flemming KD, Josephs K, Wijdicks EF : Enlarging vertebralbasilar dolichoectasia with subarachnoid hemorrhage heralded by recurrent ischemia. Case illustration. *J Neurosurg* 92 : 504, 2000
9. Giang DW, Perlin SJ, Monajati A, Kido DJ, Hollander J : Vertebralbasilar dolichoectasia : assessment using MR. *Neuroradiology* 30 : 518-523, 1988
10. Han IB, Chang JH, Chang JW, Huh R, Chung SS : Unusual causes and presentations of hemifacial spasm. *Neurosurgery* 65 : 130-137; discussion 137, 2009
11. Himi T, Kataura A, Tokuda S, Sumi Y, Kamiyama K, Shitamichi M : Downbeat nystagmus with compression of the medulla oblongata by the dolichoectatic vertebral arteries. *Am J Otol* 16 : 377-381, 1995
12. Hongo K, Nakagawa H, Morota N, Isobe M : Vascular compression of the medulla oblongata by the vertebral artery : report of two cases. *Neurosurgery* 45 : 907-910, 1999
13. Ishikawa M, Ohira T, Namiki J, Kobayashi M, Takase M, Kawase T, et al. : Electrophysiological investigation of hemifacial spasm after microvascular decompression : F waves of the facial muscles, blink reflexes,

- and abnormal muscle responses. *J Neurosurg* 86 : 654-661, 1997
14. Jannetta PJ, Abbasy M, Maroon JC, Ramos FM, Albin MS : Etiology and definitive microsurgical treatment of hemifacial spasm. Operative techniques and results in 47 patients. *J Neurosurg* 47 : 321-328, 1977
15. Kim JB, Park BJ, Choi SK, Rhee BA, Lim YJ : Microvascular decompression for hemifacial spasm associated with vertebralbasilar artery. *J Korean Neurosurg Soc* 44 : 131-135, 2008
16. Kim P, Ishijima B, Takahashi H, Shimizu H, Yokochi M : Hemiparesis caused by vertebral artery compression of the medulla oblongata. Case report. *J Neurosurg* 62 : 425-429, 1985
17. Lin CF, Chen HH, Hernesniemi J, Lee CC, Liao CH, Chen SC, et al. : An easy adjustable method of ectatic vertebralbasilar artery transposition for microvascular decompression. *Clin Neurol Neurosurg* 114 : 951-956, 2012
18. Maruyama K, Tanaka M, Ikeda S, Tada T, Yanagisawa N : [A case report of quadriplegia due to compression of the medulla oblongata by the elongated left vertebral artery]. *Rinsho Shinkeigaku* 29 : 108-111, 1989
19. McLaughlin MR, Jannetta PJ, Clyde BL, Subach BR, Comey CH, Resnick DK : Microvascular decompression of cranial nerves : lessons learned after 4400 operations. *J Neurosurg* 90 : 1-8, 1999
20. Milandre L, Bonnefoi B, Pestre P, Pellissier JF, Grisoli F, Khalil R : [Vertebralbasilar arterial dolichoectasia. Complications and prognosis]. *Rev Neurol (Paris)* 147 : 714-722, 1991
21. Milandre L, Martini P, Perot S, Mercier C : Pure motor hemiparesis in a case of vertebralbasilar arterial ectasia. *Neuroradiology* 35 : 196-198, 1993
22. Miyazaki M, Hashimoto T, Sakurama N, Yoshimoto T, Tayama M, Kuroda Y : Central sleep apnea and arterial compression of the medulla. *Ann Neurol* 29 : 564-565, 1991
23. Moss MS, West RJ : Ectasia of the vertebral artery as a cause of isolated pyramidal tract signs : case report and a review of the literature. *Br J Neurosurg* 10 : 497-499, 1996
24. Nuti D, Passero S, Di Girolamo S : Bilateral vestibular loss in vertebralbasilar dolichoectasia. *J Vestib Res* 6 : 85-91, 1996
25. Papapetropoulos S, Argyriou AA, Guevara A, Sengun C, Mitsi G, Singer C : Hemifacial spasm and pontine compression caused by a giant vertebralbasilar dolichoectasia. *Cerebrovasc Dis* 27 : 413-414, 2009
26. Rabb CH, Barnwell SL : Catastrophic subarachnoid hemorrhage resulting from ruptured vertebralbasilar dolichoectasia : case report. *Neurosurgery* 42 : 379-382, 1998
27. Rahman EA, Trobe JD, Gebarski SS : Hemifacial spasm caused by vertebral artery dolichoectasia. *Am J Ophthalmol* 133 : 854-856, 2002
28. Smoker WR, Corbett JJ, Gentry LR, Keyes WD, Price MJ, McKusker S : High-resolution computed tomography of the basilar artery : 2. Vertebralbasilar dolichoectasia : clinical-pathologic correlation and review. *AJNR Am J Neuroradiol* 7 : 61-72, 1986
29. Smoker WR, Price MJ, Keyes WD, Corbett JJ, Gentry LR : High-resolution computed tomography of the basilar artery : 1. Normal size and position. *AJNR Am J Neuroradiol* 7 : 55-60, 1986
30. Titlić M, Vrebalov-Cindro V, Lahman-Dorić M, Buca A, Jukić I, Tonkić A : Hemifacial spasm in vertebralbasilar dolichoectasia. *Acta Neurol Belg* 106 : 23-25, 2006
31. Ubogu EE, Chase CM, Verrees MA, Metzger AK, Zaidat OO : Cervicomedullary junction compression caused by vertebral artery dolichoectasia and requiring surgical treatment. Case report. *J Neurosurg* 96 : 140-143, 2002
32. Ubogu EE, Zaidat OO : Vertebralbasilar dolichoectasia diagnosed by magnetic resonance angiography and risk of stroke and death : a cohort study. *J Neurol Neurosurg Psychiatry* 75 : 22-26, 2004
33. Vincentelli F, Caruso G, Rabehanta PB, Rey M : Surgical treatment of a rare congenital anomaly of the vertebral artery : case report and review of the literature. *Neurosurgery* 28 : 416-420, 1991
34. Wolfe T, Ubogu EE, Fernandes-Filho JA, Zaidat OO : Predictors of clin-

ical outcome and mortality in vertebrobasilar dolichoectasia diagnosed by magnetic resonance angiography. *J Stroke Cerebrovasc Dis* 17 : 388-393, 2008

35. Yu YL, Moseley IF, Pullicino P, McDonald WI : The clinical picture of ectasia of the intracerebral arteries. *J Neurol Neurosurg Psychiatry* 45 : 29-36, 1982