

# Effects of Nasopore Packing on Dacryocystorhinostomy

Sun Young Jang<sup>1</sup>, Kyou Ho Lee<sup>2</sup>, Sang Yeul Lee<sup>2</sup>, Jin Sook Yoon<sup>2</sup>

<sup>1</sup>Department of Ophthalmology, Soonchunhyang Bucheon Hospital, Soonchunhyang University College of Medicine, Bucheon, Korea

<sup>2</sup>Institute of Vision Research, Department of Ophthalmology, Yonsei University College of Medicine, Seoul, Korea

**Purpose:** To investigate the effects of placement of the absorbable packing material Nasopore at the anastomosis site of newly formed mucosal flaps on postoperative re-bleeding, discomfort, and on the success rate of dacryocystorhinostomy (DCR).

**Methods:** A review of the medical records of patients with primary acquired nasolacrimal duct obstruction that underwent external or endonasal DCR by a single surgeon was performed. The degree of re-bleeding, discomfort, and postoperative results, including anatomical success, functional success and postoperative nasal findings such as granulation, synechiae, and membrane formation were compared in patients whose anastomosis site was packed with either Nasopore or Merocele, a non-absorbable packing material.

**Results:** A total of 77 patients (101 eyes) were included. Of the 101 eyes, 30 were packed with Nasopore, while 71 were packed with Merocele. The Nasopore group showed significantly better results than the Merocele group in the degree of re-bleeding and the level of patient discomfort ( $p = 0.000, 0.039$ , respectively; Pearson's chi-square test), whereas there were no statistically significant differences between the two groups in postoperative anatomical and functional success ( $p > 0.05$ ).

**Conclusions:** Nasopore significantly reduced postoperative nasal re-bleeding and patient discomfort during the early post-surgical period, but failed to show an effect on the postoperative anatomical and functional success of DCR.

**Key Words:** Absorbable packing material, Dacryocystorhinostomy, Discomfort, Nasopore, Postoperative bleeding

Nasal packing after dacryocystorhinostomy (DCR) is an optional procedure to prevent nasal bleeding [1,2]. Although improvements in surgical technique have reduced the need for this practice, nasal packing is still needed more for Asians than for Caucasians due to anatomical differences. Compared to Caucasians, Asians have a thicker lacrimal bone, a thicker frontal process of the maxilla, and a narrower nasal passage [3-5]. In addition, the proportion of the maxilla to the lacrimal bone in the lacrimal sac fossa

is greater than in Caucasians [4]. Such anatomical differences make osteotomy more difficult and prone to nasal bleeding in Asians when performing DCR. Postoperative nasal bleeding is unpleasant for patients and can be severe in certain cases [2,6]. It can potentially affect the mucosal healing process and can cause fibrosis and induce scarring at the newly formed rhinostomy site, all of which could result in an impairment of ostial patency [7]. Therefore, the minimization of intra- and postoperative bleeding is important to consider in an attempt to achieve successful surgical results.

The effects of nasal packing are not limited to hemostasis, as it also directly affects wound healing [8-14]. In the field of endoscopic sinus surgery, a number of papers have investigated whether or not nasal packing, both in general and in regard to the type used, affected nasal mucosal re-epithelialization, fibrous tissue proliferation, granulation, and synechiae formation [8,11-13]. More recently, the ef-

Received: February 7, 2012 Accepted: June 27, 2012

Corresponding Author: Jin Sook Yoon, MD, PhD. Institute of Vision Research, Department of Ophthalmology, Yonsei University College of Medicine, #50 Yonsei-ro, Seodaemun-gu, Seoul 120-749, Korea. Tel: 82-2-2228-3570, Fax: 82-2-312-0541, E-mail: yoonjs@yuhs.ac

This study was presented as a scientific poster at the ASOPRS in Orlando, USA, on October 21-22, 2011.

© 2013 The Korean Ophthalmological Society

This is an Open Access article distributed under the terms of the Creative Commons Attribution Non-Commercial License (<http://creativecommons.org/licenses/by-nc/3.0/>) which permits unrestricted non-commercial use, distribution, and reproduction in any medium, provided the original work is properly cited.

fects of nasal packing materials after DCR have started to draw attention [10], but there are no well-established conclusions due to the scarcity of reports. Furthermore, the lack of standardization in the measurement of DCR surgical outcomes makes it difficult to compare and interpret the results of previous studies [15].

Packing materials are broadly divided into non-absorbable and absorbable materials. Non-absorbable materials include Vaseline gauze strips and MeroGel, which inhibit bleeding through a compression mechanism [8]. Absorbable materials such as Gelfoam [1,9] and MeroGel [10] have been reported to be successful as packing materials after DCR. Nasopore, a bioresorbable dressing for the nasal cavity, is composed of fully synthetic biodegradable, fragmentable foam that absorbs fluids while supporting and providing pressure against the surrounding tissue. As such, it could potentially prevent undesired postoperative adhesions [13].

To investigate the effects of postoperative packing with Nasopore, we placed Nasopore at the anastomosis site of newly formed anterior mucosal flaps. Patients who had their nasal cavities packed with MeroGel packing were recruited as a control group. MeroGel, due to its non-absorbable character, is supposed to be removed within 2 to 3 days after its application.

We investigated the degree of postoperative re-bleeding and the level of patient discomfort and compared the anatomical and functional success rate 3 months post-surgery between Nasopore and MeroGel. To our knowledge, this is the first report to investigate the effect of Nasopore on the surgical outcome of DCR.

## Materials and Methods

### Patients

A review of the medical records of patients with primary acquired nasolacrimal duct obstruction (NLDO) who underwent external DCR (Ex-DCR) or endonasal endoscopic DCR (EES-DCR) by a single surgeon (JSY) at Severance Hospital from January 2008 to December 2010 was retrospectively performed. Patients with secondary NLDO, such as that caused by trauma, tumor, or dacryocystitis, were excluded from the study. Patients with less than 3 months of follow-up were also excluded. Patient histories of hypertension, diabetes, the presence of distal canalicular stenosis, and aspirin use were investigated. If a patient was on blood thinners, they were discontinued around perioperative periods; for example, aspirin and non-steroidal anti-inflammatory drugs were discontinued at 1 week and Coumadin at 4 days.

In cases of Ex-DCR, the type of the newly formed anterior mucosal flap (e.g., anchoring between the lacrimal sac and the nasal mucosa or between the lacrimal sac and the

periosteum) was investigated. A narrow nasal cavity was defined preoperatively and during surgery by the presence of nasal septal hypertrophy or septal deviation that made it difficult to observe the DCR opening site above the neck of the middle turbinate. For each patient, Nasopore (lactide caprolactone co-polyesters; Polyganics, Rozenburglaan, Groningen, The Netherlands) and MeroGel (polyvinyl alcohol; Medtronic Xomed, Jacksonville, FL, USA) were randomly selected and applied. The surgeon preferred Ex-DCR for patients with a narrow nasal cavity or severe septal deviation, whereas EES-DCR was preferred for patients with more concerns about facial scarring.

Written informed consent was obtained from each patient. This research adhered to the tenets of the Declaration of Helsinki and was approved by the international review board at Severance Hospital of Yonsei University.

### Surgical technique

The surgery was performed under general anesthesia. In both Ex-DCR and EES-DCR, an infratrochlear block using 2% xylocaine (AstraZeneca, Wilmington, DE, USA) and preoperative packing of bismine-soaked gauze into the nasal cavity was performed. For Ex-DCR, 2% xylocaine was also injected along the skin incision marking for hemostasis. For EES-DCR, an additional injection of 2% xylocaine into the lateral nasal wall was performed.

Ex-DCR was performed in a standardized fashion [16]. The lacrimal sac and the nasal mucosa from the osteotomy margin were used to make an anterior flap. The posterior flap was not fashioned in all surgeries. After making a preplaced suture of nasal mucosa, bicanalicular silicone intubation was performed (Fig. 1A). Four centimeter pieces of Nasopore were soaked in a gentamycin solution, squeezed, cut into three pieces, and packed one by one at the anastomosis site as deep as the common canaliculi opening to maximize the pressure and tenting effect on the lacrimal sac (Fig. 1B). Then a preplaced suture of 6-0 Vicryl was passed through the other edge of the sac flap to complete the anterior flap (Fig. 1C). For patients in whom a nasal mucosal flap could not be made, the anterior edge of the lacrimal sac flap was sutured onto the periosteum of the osteotomy site lip. For patients to whom MeroGel was applied, MeroGel was cut into two pieces and placed into the entire nasal cavity after skin wound closure. Especially in patients with a narrow nasal cavity, the packing material maintained the nasal wound separated from the nasal septum (Fig. 1D).

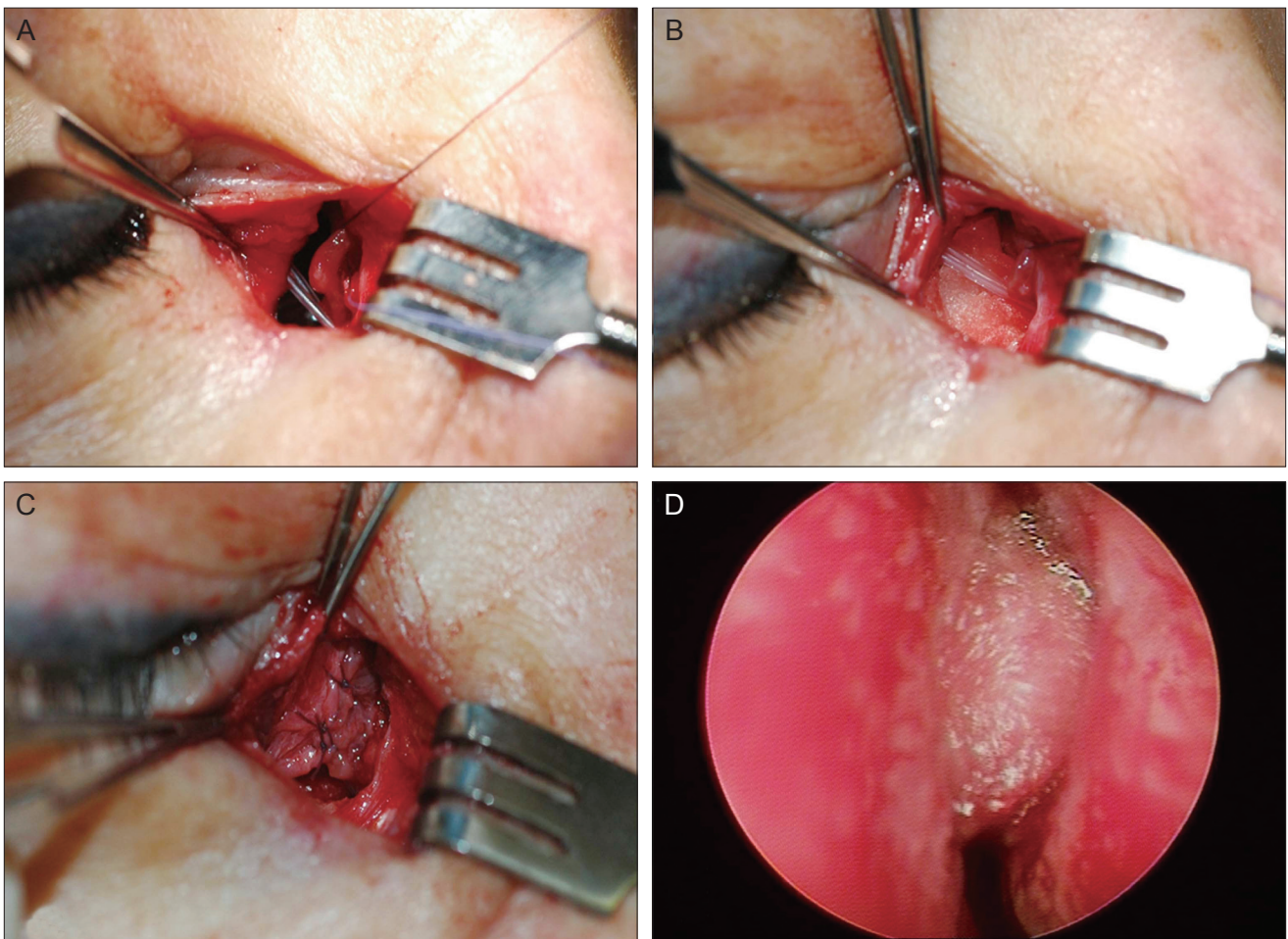
EES-DCR was also performed following standard methods [16]. The lacrimal sac was tented with a probe, incised with a sickle knife to make the posterior lacrimal sac, and flattened into the lateral nasal mucosal wall. Nasopore was packed in the same manner as in Ex-DCR at the anastomosis site.

Patients were instructed to instill topical antibiotics and steroid eye drops four times a day and to use a mometasone furoate nasal spray twice a day after the removal of packing. In patients with Nasopore packing, the packing was partially suctioned out at 1 week postoperatively, leaving a portion of the packing around the anastomosis site to be degraded naturally. The Merocel packing was removed 2 to 3 days after surgery. The follow-up visits were at 1, 2, 4, 8, and 12 weeks postoperatively. At every visit, nasal wounds were examined by endoscope and cleaned with suction and forceps. Whenever granuloma at the nasal wound was observed, it was removed and the wound was more closely examined within shorter follow-up periods. All the patients were instructed to use a steroid nasal spray and irrigate their nasal cavity using normal saline, postoperatively.

### Outcome measurement

The degree of nasal re-bleeding was assessed during postoperative week 1, meaning that all of the bleeding within a week of surgery as well as the bleeding associated with the removal of packing material was defined as re-bleeding. Bleeding was categorized into three grades: no bleeding event, re-bleeding occurred but stopped spontaneously within one hour, or re-bleeding occurred and re-packing was necessary to stop bleeding for a few hours. The degree of subjective discomfort for the 2 days during which packing materials were still inside the nasal wound was surveyed. The patients were asked to rate their discomfort degree as mild discomfort, moderate, or severe.

The postoperative success rate was evaluated 3 months after surgery. The success rate was assessed according to anatomical success and functional success separately (Table 1). Success was scored in a binary pattern. Anatomical



**Fig. 1.** Application of Nasopore. (A,B) The edge of the nasal mucosal flap is held by a pre-placed 6-0 Vicryl suture. (A) Photograph taken after bicanalicular silicone intubation. (B) Nasopore was placed at the anastomosis site before anchoring the anterior mucosal sacs during external dacryocystorhinostomy. Note the silicone tube. (C) Taken immediately after anchoring of the anterior mucosal flaps. (D) Photograph shows Nasopore widening the narrow nasal space between the septum and lateral nasal wall.

success was assessed with a lacrimal syringe test and with examination of the passage of fluorescein dye (F-dye) using a nasal endoscope. Results were categorized as either ‘well passed,’ ‘partially passed,’ or ‘not passed,’ which were recorded as success or fail, respectively. F-dye was instilled into the lower conjunctival sac, and the time until it was visible at the nasal ostium under endoscopic nasal exam was measured. The surgery was defined as a success if the dye was visible at the nasal ostium with an endoscope within 10 seconds, whereas the surgery was defined as a functional failure when the dye was not visible within 10 seconds. In addition, using a nasal endoscope, any granulations, synechiae, or membrane formations within 1 to 2 mm of the nasal ostium were identified.

Functional success was evaluated by subjective ocular symptoms. The degree of subjective epiphora was assessed by the Munk score [17]. A Munk score of 0 to 1 defined the surgery as a functional success, while a Munk score of 2 to 5 defined the surgery as a functional failure.

**Data analysis and statistics**

All statistical analysis was performed with the SPSS ver.

19.0 (SPSS Inc., Chicago, IL, USA), and a *p*-value of less than 0.05 was considered statistically significant. To compare the primary data between the two groups, we used the independent *t*-test and the Pearson’s chi-square test. For the comparison of the degree of postoperative re-bleeding and the level of patient discomfort, as well as the surgical success rates between groups, a Pearson’s chi-square and Fischer exact test were used.

**Results**

A total of 77 patients (101 eyes) were included in this study. Of the 101 eyes, 30 were packed with Nasopore, while 71 were packed with Meroceol. The demographics and clinical data of the patients are shown in Table 2. There were no statistically significant differences between the two groups in age, sex ratio, the ratio of right-eye surgery to left-eye surgery, the ratio of Ex-DCR to EES-DCR, and the cases with a narrow nasal cavity. However, there was a larger proportion of patients with preoperative canalicular stenosis in the Nasopore group than in Meroceol group (*p* = 0.042, Pearson’s chi-square test) (Table 2).

The packing material after DCR was associated with the

**Table 1.** Outcome measurements (anatomical and functional success) used in this study

	Success	Fail
Anatomical success		
Lacrimal system syringing	Well passed	Partially passed or not passed
Assessed by fluorescein dye	Visible within 10 sec	Invisible within 10 sec
Functional success		
Assessed by Munk score*	0, 1	2, 3, 4, 5

\*Munk score criteria was defined as follows: grade 0, no epiphora; grade 1, occasional epiphora requiring dabbling less than twice a day; grade 2, epiphora requiring dabbling 2 to 4 times daily; grade 3, epiphora requiring dabbling 5 to 10 times daily; grade 4, epiphora requiring dabbling more than 10 times per day; grade 5, constant tearing.

**Table 2.** Demographic and clinical data of subjects enrolled in this study

Primary data	Nasopore	Meroceol	<i>p</i> -value
No. of eyes (patients)	30 (21)	71 (56)	
Age (mean ± SD, range)	54.6 ± 15.9 (19-75)	58.0 ± 12.5 (19-79)	0.258
Gender (M / F)	5 / 25	15 / 56	0.786
Eye (OD / OS)	17 / 13	36 / 35	0.665
Op type (Ex / EES)	19 / 11	55 / 16	0.150
If Ex, flap type (SN / SP)	7 / 12	23 / 32	0.790
Narrow nasal space (Y / N)	8 / 22	24 / 47	0.640
Aspirin medication (Y / N)	8 / 22	23 / 48	0.642
HTN (Y / N)	6 / 24	25 / 46	0.160
DM (Y / N)	2 / 28	13 / 58	0.220
Canalicular stenosis (Y / N)	15 / 15	20 / 51	0.042*

Independent *t*-test for the comparison of age, otherwise Pearson’s chi-square and Fischer exact test were used.

Ex = external dacryocystorhinostomy; EES = endonasal endoscopic dacryocystorhinostomy; SN = lacrimal sac to nasal mucosa anchoring; SP = lacrimal sac to periosteum anchoring; HTN = hypertension; DM = diabetes mellitus.

\**p*-values less than 0.05 were considered statistically significant.

degree of re-bleeding and the level of patient discomfort. The nasopore group showed significantly better results than the Merocel group ( $p = 0.000, 0.039$ , respectively; Pearson's chi-square test) (Table 3 and Fig. 2). Accordingly, 93.3% of the patients with Nasopore showed no bleeding event during one week after surgery, whereas 42.3% of the patients with Merocel required nasal repacking to stop bleeding at the time of Merocel removal (Fig. 2). All of the re-bleeding events in patients with Merocel occurred at the time of packing removal. No patient with Nasopore described severe discomfort, whereas 16.9% of the patients with Merocel felt severe discomfort (Fig. 2). No differences were observed regarding the anatomical and functional success rate between the Nasopore and Merocel groups (all  $p > 0.05$ ) (Table 4).

Additionally, we did a sub-analysis by comparing parameters such as re-bleeding, discomfort, and surgical success rate of each packing material in groups categorized by two surgical types (Ex-DCR and EES-DCR). In both surgical groups, cases with Nasopore had significantly less re-bleeding than with Merocel ( $p < 0.001$ ). In cases using Nasopore, re-packing was done in 1 / 19 eyes (5.3%) in Ex-DCR and 0 / 11 eyes (0%) in EES-DCR, whereas in cases using Merocel, re-packing was done in 25 / 55 eyes (45.5%) in Ex-DCR and 5 / 16 eyes (31.3%) in EES-DCR. However, the degrees of discomfort, surgical success rate, or postoperative nasal findings were not different according to the packing materials in each surgical group (data not shown).

## Discussion

The most common causes of DCR failure are having a small bony ostium that is located improperly, scarring at the rhinostomy site, and ostial obstruction caused by granulation or fibrosis [7,9]. To ensure anatomical and functional success and in order to prevent the collapse of newly formed mucosal flaps and unwanted fibrotic closure, it is important to create a bony ostium of the proper size, reduce the intra- and postoperative bleeding, and to make the canalicular opening wider toward the nasal opening.

Several techniques for making a wider canalicular opening have been reported, including anchoring of the anterior lacrimal sac flap to the periosteum [18], lacrimal diaphragm and periosteum suturation [19], bicanalicular double silicone intubation [20], the sleeve technique (i.e., sustaining the sleeve at the opening site) [21], and the use of mitomycin C [22]. It is thought that anchoring the anterior flap to the periosteum and the sleeve technique might especially help prevent the newly formed anterior mucosal flap from collapsing because the sac flaps are physically tented [18,21]. We expected to achieve a similar mechanical tenting effect by placing the absorbable packing materials at the site of the newly-formed anastomosis before the suturing of the anterior flaps (Fig. 1).

Nasopore consists of a biologically inert foam and has a highly interconnected porous structure that is highly absorbent and can absorb up to 25 times its weight. It is believed to provide gentle compression and offer sufficient wound support during the critical healing period through the absorption of nasal fluids and blood [13]. Also, Naso-

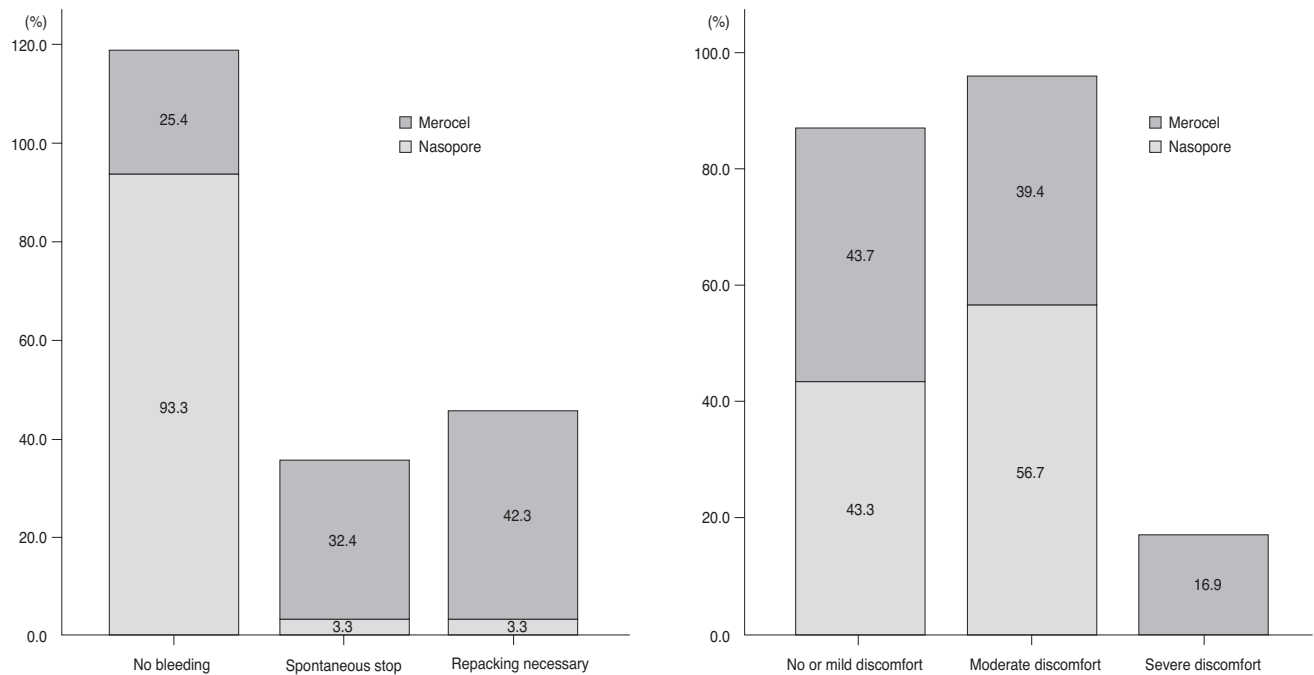
**Table 3.** Comparison of proportions of patients in terms of the degree of re-bleeding and the level of discomfort after dacryocystorhinostomy according to packing material, operative type, and other clinical characteristics

	Re-bleeding*			p-value	Discomfort†			p-value
	a	b	c		a	b	c	
Packing material								
Nasopore (30 eyes)	28 (93.3)	1 (3.3)	1 (3.3)	0.000‡	13 (43.3)	17 (56.7)	0 (0)	0.039‡
Merocel (71 eyes)	18 (25.4)	23 (32.4)	30 (42.3)		31 (43.7)	28 (39.4)	12 (16.9)	
Op type								
Ex-DCR (74)	33 (44.6)	15 (20.3)	26 (35.1)	0.196	27 (36.5)	37 (50)	10 (13.5)	0.060
EES-DCR (27)	13 (48.1)	9 (33.3)	5 (18.5)		17 (63.0)	8 (29.6)	2 (7.4)	
Narrow nasal space								
Yes (32)	12 (35.7)	6 (18.8)	14 (43.8)	0.152	9 (28.1)	19 (59.4)	4 (12.5)	0.087
No (69)	34 (49.3)	18 (26.1)	17 (24.6)		35 (50.7)	26 (37.7)	8 (11.6)	
Aspirin medication								
Yes (31)	14 (45.2)	11 (35.5)	6 (19.4)	0.107	16 (51.6)	11 (35.5)	4 (12.9)	0.465
No (70)	32 (45.7)	13 (18.6)	25 (35.7)		28 (40.0)	34 (48.6)	8 (11.4)	

Values are presented as number (%).

Ex-DCR = external dacryocystorhinostomy; EES-DCR = endonasal endoscopic dacryocystorhinostomy.

\*Re-bleeding grade: a, no bleeding event; b, re-bleeding occurred but stopped spontaneously within one hour; c, re-bleeding occurred and re-packing was necessary for a few hours; †Discomfort grade: a, no or mild discomfort; b, moderate; c, severe discomfort; ‡p-values less than 0.05 were considered significant. Pearson's chi-square and Fischer exact test were used.



**Fig. 2.** Proportions of the degree of re-bleeding and level of discomfort in patients who underwent dacryocystorhinostomy packed with Nasopore and Merocel.

**Table 4.** Comparison of anatomical and functional success between Nasopore and Merocel groups

Outcome	Nasopore (n = 30)	Merocel (n = 71)	p-value
<b>Anatomical success</b>			
Well passed-syringing	29 (96.7)	68 (95.8)	0.883
Assessed by fluorescein dye	28 (93.3)	64 (90.1)	0.607
<b>Functional success</b>			
Assessed by Munk score	28 (93.3)	60 (85.7)	0.283
<b>Postoperative nasal findings*</b>			
No granulation formation	23 (76.7)	55 (77.5)	0.930
No synechiae formation	27 (90)	66 (93.0)	0.615
No membrane formation	27 (90)	62 (87.3)	0.704
Revision not necessary	26 (86.7)	63 (88.7)	0.769

Values are presented as number (%).

p-values less than 0.05 were considered significantly. Pearson's chi-square and Fischer exact test.

\*Postoperative nasal findings were assessed using a nasal endoscope, and any granulation, synechiae, and membrane formation within 1 to 2 mm of the nasal ostium were identified.

pore can accelerate wound healing by providing a wet dressing environment. It can be more helpful for wound healing, especially in EES-DCR cases more so than in Ex-DCR cases. The former is associated with wound healing that takes about two or more weeks by secondary intension healing, whereas the latter is associated with primary intension healing [23]. Maintaining a large mucosal opening with Nasopore for approximately one week is expected to help prevent the adhesion of the anterior mucosal flaps by both a mechanical volume effect and the absorption of blood. Although we had hoped that this would lead to bet-

ter results in terms of ostial patency, the difference in surgical success between Nasopore and Merocel did not prove statistical significance in the present study. We believe that this is probably due to the high functional success rates of external DCR, which is greater than 90% in both groups, or due to a small sample size. In the present study, we did a sub-analysis by comparing parameters such as re-bleeding, discomfort, and surgical success rate of each packing material in groups categorized by two surgical types (Ex-DCR and EES-DCR). In both surgical groups, cases with Nasopore had significantly less re-bleeding than with Merocel.

However, the degree of discomfort, surgical success rate, and postoperative nasal findings did not differ according to the packing materials in each surgical group. Considering the results of combined Ex- and EES-DCR (101 eyes), which showed that Nasopore had significantly less discomfort than Meroceol ( $p = 0.039$ , Pearson's chi-square test), this is probably due to the decreased sample size resulting from sub-grouping.

In several previous reports on the effects of absorbable packing material on postoperative bleeding, discomfort and nasal wound healing showed contrary results. Berlucchi et al. [12] reported that absorbable packing material showed a lower proportion of nasal adhesion and improvement of endoscopic nasal findings such as re-epithelialization, granulation, and the appearance of mucosa of the nasal cavities after endoscopic sinus surgery, compared to non-absorbable packing material. However, Wang et al. [8] reported that Nasopore packing showed a trend toward causing granulation tissue formation during the early stages of wound healing and a higher incidence of major bleeding, which led the authors to reason that Nasopore provided less compression onto mucosa. In another report by Shoman et al. [13], there was no significant difference between Nasopore and Meroceol in regard to the risk of bleeding or patient discomfort, which contradicted our results. However, the Meroceol packing used in this study was placed in a vinyl glove finger, so we assume that use of a vinyl glove might reduce the potential damage to the nasal mucosa from the pressure of the packing or from the trauma of packing removal. In addition, these reports involved cases of endoscopic sinus surgery, and therefore it is difficult to compare the results from previous reports with our results.

There is a scarcity of reports involving cases of DCR. Wu et al. [10] reported that another absorbable pack, Mero-gel, an esterified derivative of hyaluronan, was associated with a larger number of healed ostium with a lining of intact epithelial mucosa, less formation of scarring, and a greater success rate of ostial patency, compared to those in the non-packed group after endoscopic DCR. In the present study, we compared the degree of postoperative re-bleeding, the level of patient discomfort, and the anatomical and functional success rate of external DCR between absorbable and non-absorbable packing materials. We did not find any excessive granulation tissue growth during the early stages of wound healing in the Nasopore group, and did not encounter postoperative major bleeding associated with Nasopore. Rather, we found more cases in the Meroceol group with discomfort and bleeding associated with the packing and its removal. We propose that there might be greater damage to the nasal mucosa during the removal of non-absorbable packing material, as the pressure of the packing is quite strong. Especially in patients with septal deviation or middle turbinate hypertrophy, the nasal mu-

cosa of the septum can be easily damaged during removal of the packing, and this unwanted damage can increase the risk of adhesion and fibrosis of the nasal ostium after DCR [7,10]. The removal and/or reinsertion of packing material may cause major pain or discomfort to patients, because the nasal cavity becomes much narrower than what it was during surgery, after the disappearance of vaso-constrictive effect of epinephrine.

In addition, Nasopore can separate the mucosal surfaces during the critical early post-surgical days when mucosal swelling is heightened. We believe that the use of Nasopore not only helped in the achievement of excellent early hemostasis, but also made endonasal wound care more comfortable by keeping the mucosal tissue separated, especially in patients with a narrow nasal cavity.

Although it is rare, the extrusion of silicone tubing may occur in the early postoperative period before complete absorption of the Nasopore material. However, we did not observe any case of prolapsed tubing in our cases. At week 1 postoperatively, the position of the silicone tube was confirmed while the external part of the material was partially suctioned.

In the present study, there was a larger portion of patients with preoperative canaliculus stenosis in the Nasopore group than in Meroceol group, partially due to a non-randomized, retrospective study design, and partially due to the small sample size of the Nasopore group. Further prospective randomized comparative study would be necessary.

In conclusion, although the anatomic and functional success rate of DCR was not affected by the packing material itself, an absorbable packing material such as Nasopore would be very helpful in postoperative hemostasis, endonasal wound care, and in reducing discomfort associated with nasal packing. Considering not only surgical success, but also postoperative pain and discomfort in DCR surgery, is important. Especially in cases with a narrow nasal cavity or in cases where intraoperative bleeding is difficult to control, such as the use of blood thinners or cases of thick maxillary bones, we believe the use of an absorbable packing would help elevate patient satisfaction after surgery.

## Conflict of Interest

No potential conflict of interest relevant to this article was reported.

## References

1. Anderson RL. Gelfoam packing after dacryocystorhinostomy. *Arch Ophthalmol* 1977;95:520.
2. Durrani OM, Fernando AI, Reuser TQ. Use of a novel topical hemostatic sealant in lacrimal surgery: a prospective, comparative study. *Ophthal Plast Reconstr Surg*

- 2007;23:25-7.
3. Carter SR, Gausas RE. Gender and racial variations of the lacrimal system. In: Cohen AJ, Mercandetti M, Brazzo BG, editors. *The lacrimal system: diagnosis, management, and surgery*. New York: Springer; 2006. p. 21.
  4. Woo KI, Maeng HS, Kim YD. Characteristics of intranasal structures for endonasal dacryocystorhinostomy in asians. *Am J Ophthalmol* 2011;152:491-8.e1.
  5. Tan TY, Lin M, Cheah FK, Koh DM. Distribution patterns of inflammatory sinonasal diseases. *Singapore Med J* 1998;39:59-63.
  6. Dailey RA, Chavez MR, Choi D. Use of a chitosan-based hemostatic dressing in dacryocystorhinostomy. *Ophthalm Plast Reconstr Surg* 2009;25:350-3.
  7. Konuk O, Kurtulmusoglu M, Knatova Z, Unal M. Unsuccessful lacrimal surgery: causative factors and results of surgical management in a tertiary referral center. *Ophthalmologica* 2010;224:361-6.
  8. Wang YP, Wang MC, Chen YC, et al. The effects of Vaseline gauze strip, Merocel, and Nasopore on the formation of synechiae and excessive granulation tissue in the middle meatus and the incidence of major postoperative bleeding after endoscopic sinus surgery. *J Chin Med Assoc* 2011;74:16-21.
  9. Basmak H, Cakli H, Sahin A, et al. Comparison of endocanalicular laser dacryocystorhinostomy with and without endonasal procedures. *Graefes Arch Clin Exp Ophthalmol* 2011;249:737-43.
  10. Wu W, Cannon PS, Yan W, et al. Effects of Merogel coverage on wound healing and ostial patency in endonasal endoscopic dacryocystorhinostomy for primary chronic dacryocystitis. *Eye (Lond)* 2011;25:746-53.
  11. Miller RS, Steward DL, Tami TA, et al. The clinical effects of hyaluronic acid ester nasal dressing (Merogel) on intranasal wound healing after functional endoscopic sinus surgery. *Otolaryngol Head Neck Surg* 2003;128:862-9.
  12. Berlucchi M, Castelnuovo P, Vincenzi A, et al. Endoscopic outcomes of resorbable nasal packing after functional endoscopic sinus surgery: a multicenter prospective randomized controlled study. *Eur Arch Otorhinolaryngol* 2009;266:839-45.
  13. Shoman N, Gheriani H, Flamer D, Javer A. Prospective, double-blind, randomized trial evaluating patient satisfaction, bleeding, and wound healing using biodegradable synthetic polyurethane foam (NasoPore) as a middle meatal spacer in functional endoscopic sinus surgery. *J Otolaryngol Head Neck Surg* 2009;38:112-8.
  14. Wormald PJ, Boustred RN, Le T, et al. A prospective single-blind randomized controlled study of use of hyaluronic acid nasal packs in patients after endoscopic sinus surgery. *Am J Rhinol* 2006;20:7-10.
  15. Ben Simon GJ, Joseph J, Lee S, et al. External versus endoscopic dacryocystorhinostomy for acquired nasolacrimal duct obstruction in a tertiary referral center. *Ophthalmology* 2005;112:1463-8.
  16. Dolman PJ. Comparison of external dacryocystorhinostomy with nonlaser endonasal dacryocystorhinostomy. *Ophthalmology* 2003;110:78-84.
  17. Munk PL, Lin DT, Morris DC. Epiphora: treatment by means of dacryocystoplasty with balloon dilation of the nasolacrimal drainage apparatus. *Radiology* 1990;177:687-90.
  18. Holt GR, Holt JE, Cortez EA. Dacryocystorhinostomy utilizing an anterior lacrimal sac flap to periosteum technique. *Otolaryngol Head Neck Surg* 1979;87:174-82.
  19. Ciftci F, Dinc UA, Ozturk V. The importance of lacrimal diaphragm and periosteum suturation in external dacryocystorhinostomy. *Ophthalm Plast Reconstr Surg* 2010;26:254-8.
  20. Hwang SW, Khwarg SI, Kim JH, et al. Bicanalicular double silicone intubation in external dacryocystorhinostomy and canaliculoplasty for distal canalicular obstruction. *Acta Ophthalmol* 2009;87:438-42.
  21. Jo YJ, Kim KN, Lee YH, et al. Sleeve technique to maintain a large mucosal ostium during endoscopic dacryocystorhinostomy. *Ophthalmic Surg Lasers Imaging* 2010;41:656-9.
  22. Deka A, Bhattacharjee K, Bhuyan SK, et al. Effect of mitomycin C on ostium in dacryocystorhinostomy. *Clin Experiment Ophthalmol* 2006;34:557-61.
  23. Olver JM. The success rates for endonasal dacryocystorhinostomy. *Br J Ophthalmol* 2003;87:1431.