

Analysis of Tumor Markers in Cytological Fluid Obtained From Computed Tomography–Guided Needle Aspiration Biopsies for the Diagnosis of Ground-Glass Opacity Pulmonary Lesions

Ga Ram Kim, MD¹; Jin Hur, MD, PhD¹; Hye-Jeong Lee, MD, PhD¹; Ji Eun Nam, MD¹;
Young Jin Kim, MD, PhD¹; Yoo Jin Hong, MD¹; Hyo Sup Shim, MD, PhD²; Hee Yeong Kim, MD¹;
Ji Won Lee, MD¹; and Byoung Wook Choi, MD, PhD¹

BACKGROUND: The purpose of this study was to assess whether analyses of tumor markers in cytological fluid can improve the performance of computed tomography (CT)-guided needle aspiration biopsy (NAB) for the diagnosis of ground-glass opacity (GGO) pulmonary lesions. **METHODS:** Forty-two patients were prospectively enrolled for CT-guided NAB. Levels of cytokeratin 19 fragments (CYFRA 21-1) and carcinoembryonic antigen (CEA) from serum and cytological fluid were measured. The cutoff values of 3.3 ng/mL for CYFRA 21-1 and 5.0 ng/mL for CEA (threshold A) or thresholds by adding 2 standard deviations to the mean levels of markers found in patients without malignancy (threshold B) were used to identify malignancy. The sensitivity and area under the curve (AUC) of NAB alone were compared with those of NAB combined with serum or cytological tumor markers. **RESULTS:** Among the 42 patients, 30 (71.4%) had malignant and 12 (28.6%) had benign lesions. For NAB alone, the sensitivity, specificity, and AUC for diagnosing GGO were 70.0%, 100%, and 0.850, respectively. The sensitivity and AUC increased significantly for NAB with cytological CYFRA 21-1 compared with NAB alone, using both thresholds (threshold A: 86.7%, $P = .026$ and $.933$, $P = .016$; threshold B: 93.3%, $P = .008$ and $.925$, $P = .046$). **CONCLUSIONS:** Cytological fluid measurements of CYFRA 21-1 can improve the diagnostic performance of CT-guided NAB for GGO pulmonary lesions. *Cancer (Cancer Cytopathol) 2013;121:214-22.* © 2012 American Cancer Society.

KEY WORDS: cytokeratin 19 fragments, CYFRA 21-1, carcinoembryonic antigen, cytological fluid, computed tomography-guided needle aspiration biopsy, ground-glass opacity.

Recently, the diagnosis and treatment of ground-glass opacity (GGO) lesions have become important issues, because subsolid nodules including GGO are now known to frequently represent the histologic spectrum of lung adenocarcinoma.¹ Although GGO had traditionally been regarded as areas of inflammation, hemorrhage, or fibrosis, GGO lesions appearing on computed tomography (CT) have been reported to comprise a wide range of diagnoses, from preinvasive lesions, such as atypical adenomatous hyperplasia or adenocarcinoma in situ, to invasive lesions, such as minimally invasive adenocarcinoma or invasive adenocarcinoma.²⁻⁷ Moreover, some reports have suggested that focal GGO lesions with solid components (mixed GGO) are significantly more likely to be associated with malignancy, especially with an invasive component.^{8,9}

Corresponding author: Jin Hur, MD, PhD, Department of Radiology, Severance Hospital, Yonsei University College of Medicine, 50 Yonsei-ro, Seodaemun-gu, Seoul 120-752, South Korea; Fax: (011) 82-2-393-3035; khuhz@yuhs.ac

¹Department of Radiology and Research Institute of Radiological Science, Yonsei University College of Medicine, Seoul, Korea; ²Department of Pathology, Yonsei University College of Medicine, Seoul, Korea

Received: July 8, 2012; **Revised:** August 9, 2012; **Accepted:** September 10, 2012

Published online December 5, 2012 in Wiley Online Library (wileyonlinelibrary.com)

DOI: 10.1002/cncy.21244, wileyonlinelibrary.com

Currently, CT-guided percutaneous needle aspiration biopsy (NAB) of the lung is the most commonly used method for the cytologic diagnosis of pulmonary lesions.³ However, the diagnostic yield of CT-guided NAB for GGO lesions was reported to be significantly lower than that of solid lesions, because of the low cellularity in GGO lesions.⁴ Concerning persistent GGO lesions, it remains uncertain whether further confirmation by repeat biopsy or surgical biopsy should be considered in cases of inconclusive or negative results by NAB.

Serum tumor markers have been extensively studied in lung cancer, but none are specific for detecting lung cancer.^{5,6} Among several possible types of samples for tumor marker analysis, cytological fluid (cell suspension of aspirates) obtained from NAB is obtained directly from tumor tissue and thus, candidate biomarkers may be present in high concentrations. We performed an initial study on cytological tumor markers which suggested that additional evaluation of the markers cytokeratin 19 fragments (CYFRA 21-1), carcinoembryonic antigen (CEA), and squamous cell carcinoma (SCC) antigen would be valuable in improving sensitivity in diagnosis of non-small cell lung cancer in patients undergoing NAB.¹⁰ Therefore, we hypothesized that cytological tumor marker analysis could also improve diagnostic performance of CT-guided NAB for GGO lesions. This study was conducted to prospectively assess whether analyses of the tumor markers CYFRA 21-1 and CEA in cytological fluid can improve the diagnostic performance of CT-guided NAB for GGO pulmonary lesions.

MATERIALS AND METHODS

Study Population

This single-center prospective study was approved by our institutional review board. Informed consent was obtained from all subjects prior to the procedure.

Patients in whom focal GGO was detected at initial CT scan were re-evaluated with a thin-section CT within a 3-month interval. From October 1, 2009, to May 31, 2010, 50 patients with persistent GGO lesions suspicious for malignancy on CT were prospectively enrolled in our study. GGO lesions were identified by the consensus of 2 experienced chest radiologists, using thin-section CT. GGO was defined as an area of increased attenuation without obscuration of the underlying vessels or bronchi.⁷

The inclusion criteria were as follows: lesions with a GGO component of more than 50%, patient age greater than 20 years, lesion size larger than 8 mm, and persistence or growth of the established lesion within a 3-month period.^{1,2,11,12} The exclusion criteria were indeterminate results (n = 4) or refusal to provide written informed consent (n = 4). A total of 42 patients (21 men and 21 women; mean age, 60.3 years; range, 37-79 years) with histologically- and/or cytologically-confirmed results were included in our final study population. Data including sex, age, size and location of the lesion, history, results of NAB and pathology, and laboratory data (serum and cytological fluid tumor markers for CYFRA 21-1 and CEA) were collected for each patient.

CT-Guided NAB and Tumor Marker Analysis

The study protocol, including the biopsy procedures and all equipment or experimental arrangements associated with CT-guided NABs and tumor marker analysis in blood or cytological fluid, was performed as described.¹⁰

The biopsy procedures were performed by 3 experienced chest radiologists who had 4, 6, and 10 years of experience performing thoracic biopsies, respectively. CT-guided NABs were performed using a 16-row multi-detector CT scanner (Somatom Sensation 16; Siemens Healthcare, Erlangen, Germany) equipped with CARE Vision software (Siemens). The exposure parameters were 120 kV, 30 mAs, and slice thickness of 6 mm. During each procedure, more than 2 aspiration specimens were obtained using 20- to 22-gauge Chiba needles connected to a 10-mL syringe without additional needle punctures. Part of each aspirate was placed onto glass slides and smeared for cytological examination and part of the material was prepared in a tube for processing as a cell block. All smears were immediately placed in 95% ethanol for Papanicolaou staining. Remaining aspirates (1 ≈ 2 mL) were rinsed with 1 mL of normal saline solution in a tube for the evaluation of cytological tumor markers.

In our institution, cytological results were evaluated and divided into the following diagnostic categories: “malignant,” “negative for malignancy,” and “nondiagnostic” (eg, cell paucity or samples with few atypical cells). A designation of “malignancy” was considered a positive result. A designation of “negative for malignancy” was considered a negative result. Nondiagnostic designations (n = 4)

were considered neither positive nor negative, and the results were excluded from our study.

Blood and cytological fluid were collected from each patient prior to therapy. Serum and cytological fluid supernatants were obtained by centrifugation at 2000g for 10 minutes and stored at -40°C prior to assays for tumor markers using commercial immunoassay kits. CYFRA 21-1 levels were measured using an electrochemiluminescent immunoassay (CYFRA 21-1; Roche Diagnostics, Germany) and CEA levels were measured using a chemiluminescence immunoassay (Centaur CEA; Bayer HealthCare, USA).¹⁰ Tumor markers in each cytological fluid sample were assayed twice, with the mean values used for analysis. Technicians performing the assays for both serum and cytological fluid were blinded to the final sample diagnoses.

In our study, we determined the cutoff values of the serum and cytological tumor markers using 2 criteria. Threshold A was defined as 3.3 ng/mL for CYFRA 21-1 and 5 ng/mL for CEA, which are the upper limits of normal serum values.^{13,14} Threshold B was calculated by adding 2 standard deviations to the mean levels of markers in patients without lung cancer and was defined as 5.27 ng/mL for serum CYFRA 21-1 (bCYFRA 21-1), 6.14 ng/mL for cytological CYFRA 21-1 (cCYFRA 21-1), 4.17 ng/mL for serum CEA (bCEA), and 0.31 ng/mL for cytological CEA (cCEA).^{15,16}

Histological Analysis

The cytological specimen from the NAB was stained by the Papanicolaou method after fixation in 95% ethanol. The tumor tissue sampled during the operation was imprinted on a glass slide. Tissue sections were processed for hematoxylin and eosin stains, and histochemical stains. Histologic classification was done according to the proposed International Association for the Study of Lung Cancer (IASLC)/American Thoracic Society (ATS)/European Respiratory Society (ERS) international multidisciplinary classification of lung adenocarcinoma. If there was a disagreement in the histopathological analysis, a consensus was achieved by a joint reading.

Statistical Analysis

A positive NAB result was considered a true-positive result if there was surgical confirmation and a false-positive result if no evidence of malignancy was found during

surgical resection in the absence of preoperative chemotherapy. Results were considered to be negative if no tumor was found in the surgical specimen or disappearance of the lesion was discovered on subsequent CT. If the level of either marker was higher than its threshold, the result was considered positive. Differences between the 2 groups (malignant and benign) were evaluated using the chi-square test or Fisher's exact test. Differences of serum and cytological tumor makers among the histological subgroups were evaluated using the 1-way analysis of variance or Kruskal-Wallis test. The sensitivity, specificity, accuracy, positive predictive value, and negative predictive value of NAB alone and NAB combined with serum or cytological tumor markers (CYFRA 21-1 and CEA) were calculated. When combining NAB with tumor marker evaluation, cases were considered positive if either NAB or a tumor marker were positive, and were considered negative if NAB and all tumor markers were negative. Comparisons were made using weighted least squares to determine the statistical significance of sensitivity and accuracy between NAB combined with tumor markers and NAB alone.¹⁷ To compare the performances of NAB alone and NAB combined with tumor markers, receiver operating characteristic (ROC) curves were constructed and the areas under the curve (AUC) were compared. Comparisons were made using the Delong method to determine the statistical significance of AUC.¹⁸ Statistical analyses were performed with SAS software, version 9.2 (SAS Institute, Cary, NC) and *P* values $< .05$ were considered statistically significant.

RESULTS

Our study included 42 of 50 initial patients. Among the 42 patients, 30 (71.4%) had malignant and 12 (28.6%) had benign pulmonary lesions. Baseline characteristics of the 42 pulmonary lesions in the malignant group, benign group, and the total population are summarized in Table 1. There were no significant differences between the 2 groups in any of the baseline characteristics including sex, age, lesion size, GGO component, lesion location, or past history ($P > .05$) (Table 1).

All of the 30 malignant lesions were confirmed by lobectomy. The histological types according to IASLC/ATS/ERS classification were as follows: 23 patients with invasive adenocarcinoma (lepidic predominant [n = 10], acinar predominant [n = 8], papillary predominant

TABLE 1. Demographic and Baseline Characteristics of 42 Pulmonary Lesions

Characteristic		All (n = 42)	Malignant (n = 30)	Benign (n = 12)	P
Sex					
Male		21 (50.0)	12 (40.0)	9 (75.0)	.088
Female		21 (50.0)	18 (60.0)	3 (25.0)	
Age, y ^a		60.3 ± 10.4	62.1 ± 9.9	21.6 ± 10.5	.087
Lesion size, mm ^a		20.3 ± 9.1	21.6 ± 8.8	17.9 ± 9.2	.159
Ground-glass opacity component ^b (%)	50%-90%	30 (71.4)	24 (80.0)	6 (50.0)	.069
	>90%	12 (28.6)	6 (20.0)	6 (50.0)	
Location ^b	Upper/middle lobe	32 (76.2)	23 (76.7)	9 (75.0)	1.000
	Lower lobe	10 (23.8)	7 (23.3)	3 (25.0)	
History	Smoking ^b	15 (35.7)	8 (26.7)	7 (58.3)	.078
	Hypertension ^b	13 (31.0)	10 (33.3)	3 (25.0)	.722
	Diabetes ^b	5 (11.9)	3 (10.0)	2 (16.7)	.613
	Pulmonary tuberculosis ^b	6 (14.3)	3 (10.0)	3 (25.0)	.329

^aValues in parentheses are percentages.

^bFisher's exact test.

Data are presented as mean ± standard deviation.

TABLE 2. Serum and Cytological Fluid Levels of CYFRA 21-1 and CEA in 42 Patients With Malignant and Benign Lesions

Tumor Marker	Malignant (n = 30)	Benign (n = 12)	P
Serum			
CYFRA 21-1 (ng/mL)	1.91 ± 0.81	2.29 ± 1.49	.290
CEA (ng/mL)	1.94 ± 1.42	1.79 ± 1.19	.742
Cytological fluid			
CYFRA 21-1 (ng/mL)	30.78 ± 52.63	2.73 ± 1.71	.007
CEA (ng/mL)	2.70 ± 6.58	0.18 ± 0.07	.194

Abbreviations: CEA, carcinoembryonic antigen; CYFRA 21-1, cytokeratin 19 fragments.

Data are presented as mean ± standard deviation.

[n = 5]), 4 patients with adenocarcinoma in situ [n = 4], and 3 patients with minimally invasive adenocarcinoma.¹⁹ Of the 30 malignant lesions, 9 were false-negatives on NAB (lepidic predominant adenocarcinoma [n = 6], adenocarcinoma in situ [n = 2], and minimally invasive adenocarcinoma [n = 1]). Serum tumor marker levels of these 9 false-negatives on NAB were lower than the cutoff value of serum according to threshold A or B. Of the 12 benign lesions, 6 were confirmed by surgery such as video-assisted thoracic surgery or wedge resection, and 6 were diagnosed as benign on the basis of subsequent CT examinations showing complete disappearance of the lesion (n = 5) or maintenance of regressed status for at least 2 years (n = 1).¹

The serum and cytological fluid concentrations of CYFRA 21-1 and CEA in patients with benign and malignant lesions are presented in Table 2. Serum tumor marker levels were not significantly different between the

malignant and benign groups ($P > .05$). However, cCYFRA 21-1 was significantly higher in the malignant group than in the benign group ($P = .007$). When we analyzed the serum and cytological fluid concentrations of CYFRA 21-1 and CEA according to histopathological subtypes, serum and cytological tumor markers were not significantly different among the histological subtypes ($P > .05$; Table 3).

Table 4 describes the sensitivity, specificity, accuracy, positive predictive value, and negative predictive value of NAB alone and NAB combined with serum or cytological tumor markers in the 42 patients. Using threshold A, neither the sensitivity nor the accuracy were significantly different between NAB combined with serum tumor markers and NAB alone (for 2 serum tumor markers, $P > .05$). However, the sensitivity and accuracy were significantly increased for NAB combined with cCYFRA 21-1 compared with NAB alone. Sensitivity increased from 70.0% with NAB alone to 86.7% when combined with cCYFRA 21-1 ($P = .026$), and accuracy increased from 78.6% to 90.5% ($P = .026$). However, sensitivity and accuracy were not significantly different between NAB combined with cCEA and NAB alone ($P = .084$ and $P = .084$, respectively; Table 4). Using threshold B, the sensitivity and accuracy were not significantly different between NAB combined with serum tumor markers and NAB alone (for 2 serum tumor markers, $P > .05$). However, the sensitivity increased significantly for NAB combined with cCYFRA 21-1 and cCEA compared with NAB alone (93.3% for cCYFRA 21-1 and 86.7% for cCEA: $P = .008$ and $P = .026$, respectively). Furthermore, the accuracy was significantly different

TABLE 3. Serum and Cytological Fluid Levels of CYFRA 21-1 and CEA According to Histopathological Subtypes

Tumor Marker	Invasive Adenocarcinoma (n = 23)	Minimally Invasive Adenocarcinoma (n = 3)	Adenocarcinoma In Situ (n = 4)	P
Serum (ng/mL)				
CYFRA 21-1	1.83 ± 0.82	2.41 ± 0.77	2.01 ± 0.81	.776
CEA	1.81 ± 1.19	1.96 ± 1.24	2.63 ± 2.68	.795
Cytological fluid (ng/mL)				
CYFRA 21-1	35.78 ± 59.23	14.51 ± 18.24	17.75 ± 13.61	.163
CEA	2.72 ± 7.38	2.78 ± 4.61	2.50 ± 2.47	.611

Tumor Marker	Lepidic Predominant (n = 10)	Acinar Predominant (n = 8)	Papillary Predominant (n = 5)	P
Serum (ng/mL)				
CYFRA 21-1	1.86 ± 0.61	1.56 ± 0.93	2.18 ± 1.05	.874
CEA	1.75 ± 1.41	1.68 ± 1.02	2.17 ± 1.12	.747
Cytological fluid (ng/mL)				
CYFRA 21-1	42.39 ± 63.18	16.54 ± 16.28	32.51 ± 43.45	.637
CEA	4.43 ± 11.07	2.84 ± 1.17	2.41 ± 2.27	.643

Abbreviations: CEA, carcinoembryonic antigen; CYFRA 21-1, cytokeratin 19 fragments. Data are presented as mean ± standard deviation.

TABLE 4. Comparison of the Diagnostic Performances of NAB alone and NAB Combined With Serum or Cytological Fluid Tumor Markers in 42 Patients

Diagnostic	Sensitivity	Specificity	Accuracy	PPV	NPV
NAB alone	70.0	100	78.6	100	57.1
NAB + serum tumor markers					
CYFRA 21-1					
Threshold A	70.0	83.3	73.8	91.3	52.6
Threshold B	70.0	91.7	76.2	95.5	55.0
CEA					
Threshold A	70.0	100	78.6	100	57.1
Threshold B	70.0	91.7	76.2	95.5	55.0
NAB + cytological fluid tumor markers					
CYFRA 21-1					
Threshold A	86.7	100	90.5	100	75.0
Threshold B	93.3	91.7	92.9	96.6	84.6
CEA					
Threshold A	80.0	100	85.7	100	66.7
Threshold B	86.7	91.7	88.1	96.3	73.3

Abbreviations: CEA, carcinoembryonic antigen; CYFRA 21-1, cytokeratin 19 fragments; NAB, needle aspiration biopsy; NPV, negative predictive value; PPV, positive predictive value. Values shown are percentages. Threshold A = Cutoff values of 3.3 ng/mL and 5 ng/mL for serum or cytological fluid CYFRA 21-1 and CEA, respectively; Threshold B = Threshold calculated by adding 2 standard deviations to the mean level found in patients without lung cancer.

between NAB combined with cCYFRA 21-1 and NAB alone ($P=.046$), but was not significantly different between NAB combined with cCEA and NAB alone ($P=.103$; Table 4).

For the diagnosis of malignancy using threshold A, the AUC of NAB combined with either serum tumor marker was not significantly larger than the AUC of NAB alone (0.767 for bCYFRA 21-1, and 0.850 for bCEA, both $P > .05$). The AUC of NAB with cCYFRA 21-1 was significantly larger than the AUC of NAB alone (0.933 for cCYFRA 21-1 versus 0.850; $P=.016$). However, the AUC of NAB with cCEA was not significantly larger than the AUC of NAB alone (0.900 versus 0.850; $P=.073$; Table 5). ROC curves of NAB alone and NAB combined with tumor markers, using threshold A, are shown in Figure 1. The AUC of NAB combined with either serum tumor marker was not significantly larger than the AUC of NAB alone for the diagnosis of malignancy, using threshold B (0.808 for bCYFRA 21-1, and 0.808 for bCEA, both $P > .05$). The AUC of NAB with cCYFRA 21-1 was significantly larger than the AUC of NAB alone (0.925 versus 0.850; $P=.046$), whereas the AUC of NAB with cCEA was not significantly larger than the AUC of NAB alone (0.892 versus 0.850; $P=.442$; Table 5). Figure 2 represents the ROC curves of NAB alone and NAB combined with tumor markers, using threshold B.

DISCUSSION

This study was designed to examine whether analyses of the tumor markers CYFRA 21-1 and CEA in cytological

fluid could improve the performance of CT-guided NAB in the diagnosis of persistent GGO pulmonary lesions. We found that CT-guided NAB with additional evaluation of CYFRA 21-1 can improve sensitivity and accuracy in the diagnosis of persistent GGO pulmonary lesions.

TABLE 5. Comparison of the Diagnostic Performance of NAB Alone and NAB With Serum or Cytological Fluid Tumor Markers in 42 Patients

Tumor Marker		AUC	P
NAB alone		0.850 (0.767-0.933)	
NAB + serum tumor marker			
CYFRA 21-1	Threshold A	0.767 (0.629-0.905)	.138
	Threshold B	0.808 (0.692-0.925)	.317
CEA	Threshold A	0.850 (0.767-0.933)	1.000
	Threshold B	0.808 (0.692-0.925)	.317
NAB + cytological fluid tumor marker			
CYFRA 21-1	Threshold A	0.933 (0.872-0.995)	.016
	Threshold B	0.925 (0.832-1.000)	.046
CEA	Threshold A	0.900 (0.827-0.973)	.073
	Threshold B	0.892 (0.789-0.994)	.442

Abbreviations: AUC, area under the curve; CEA, carcinoembryonic antigen; CYFRA 21-1, cytokeratin 19 fragments; NAB, needle aspiration biopsy. Threshold A = Cutoff values of 3.3 ng/mL and 5 ng/mL for serum or cytological fluid CYFRA 21-1 and CEA, respectively; Threshold B = Threshold calculated by adding 2 standard deviations to the mean level found in patients without lung cancer. Values in parentheses are 95% confidence intervals.

Early detection of small malignant pulmonary nodules is important because it can lead to early, potentially curative treatment.¹⁸ The improved detection of focal GGO lesions by advanced CT screening necessitates the definite diagnosis of GGO, although the diagnostic accuracy of CT-guided NAB for GGO lesions is not well established. Despite the relative safety and accuracy of CT-guided NAB for the diagnosis of lung lesions, nonspecific or false-negative results are common, with reported incidences ranging from 5.5% to 29%.^{3,20-22} Moreover, the diagnostic yield of CT-guided NAB for GGO lesions is significantly lower than that of solid lesions, especially for lesions with a GGO component > 90%.^{4,23} Shimizu et al⁴ reported that the diagnostic yield of CT-guided NAB was 51.2% for GGO lesions and 75.6% for solid lesions. Therefore, the proper clinical management of persistent GGO remains controversial, and patients with suspected malignancies but inconclusive results on initial lung biopsy often require additional transthoracic lung biopsy or surgical biopsy, including video-assisted thoracic surgery. We attempted to improve the diagnosis of GGO lesions by using cytological fluid instead of blood serum for tumor marker analysis. Although blood is useful for

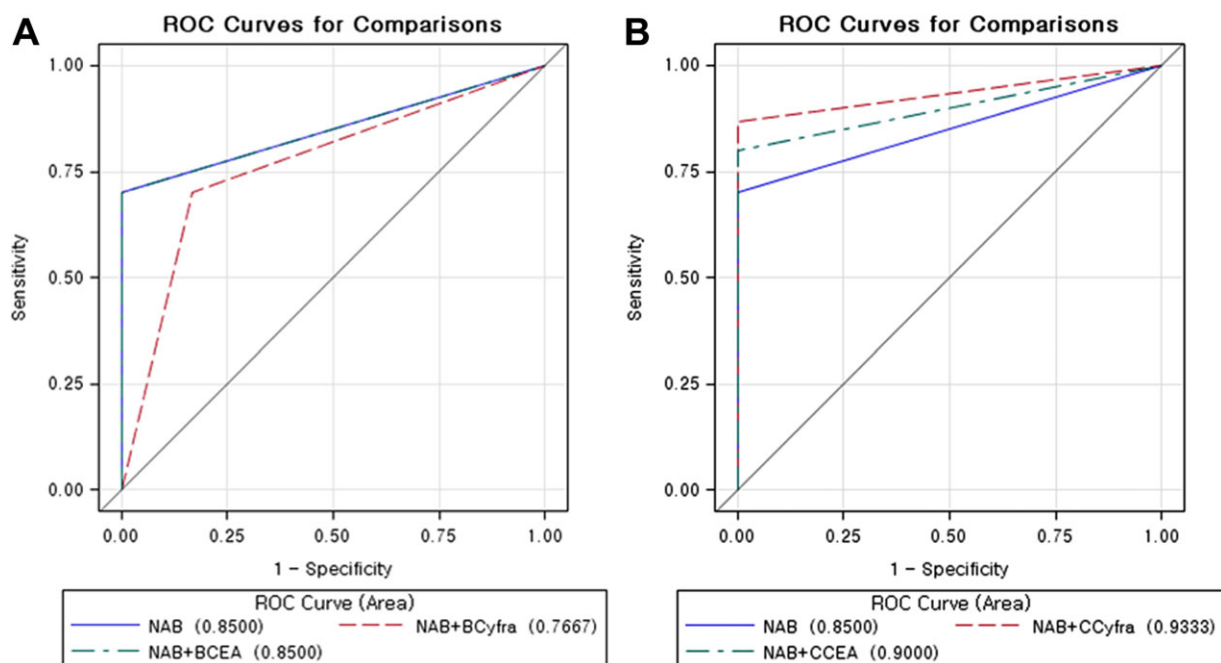


FIGURE 1. Receiver operating characteristic (ROC) curves of needle aspiration biopsy (NAB) alone and NAB with (A) serum or (B) cytological fluid tumor markers using threshold A with cutoff values of 3.3 ng/mL and 5 ng/mL for cytokeratin 19 fragments (CYFRA 21-1) and carcinoembryonic antigen (CEA) levels, respectively. The solid curve, dashed curve, and dot-and-dash curve represent NAB alone, NAB combined with CYFRA 21-1, and NAB combined with CEA, respectively.

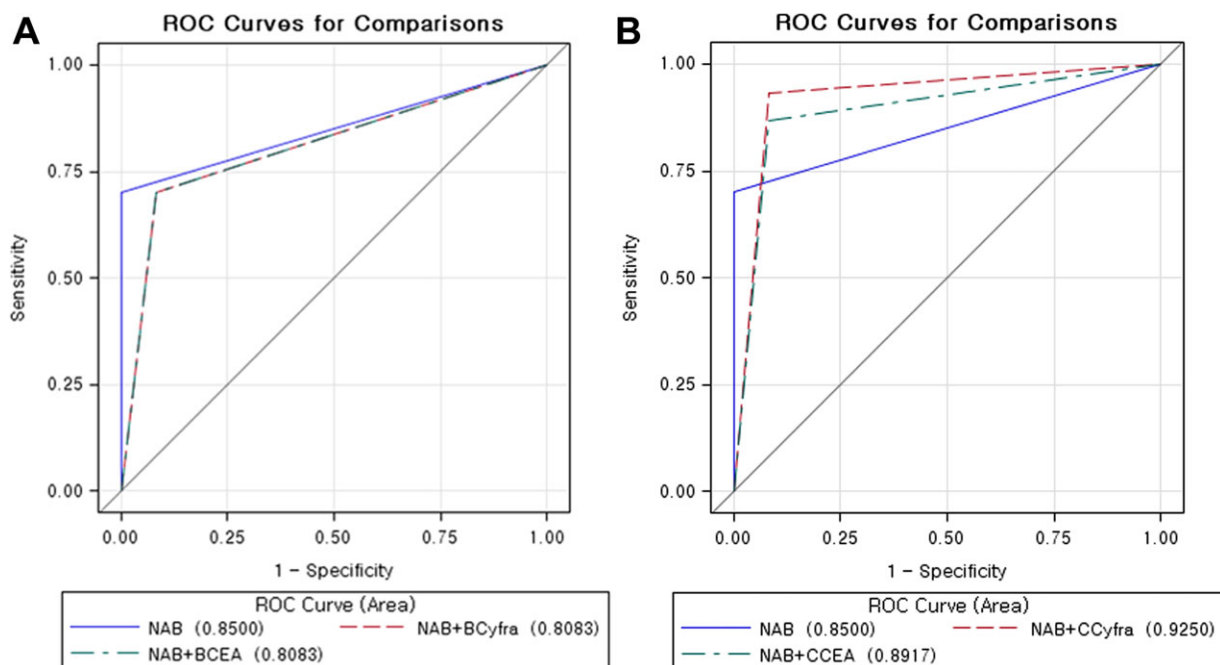


FIGURE 2. Receiver operating characteristic (ROC) curves of needle aspiration biopsy (NAB) alone and NAB with with (A) serum or (B) cytological fluid tumor markers using threshold B calculated by adding 2 standard deviations to the mean levels found in patients without lung cancer. Each solid curve, dashed curve, and dot-and-dash curve indicates NAB alone, NAB combined with cytokeratin 19 fragments (CYFRA 21-1), and NAB combined with carcinoembryonic antigen (CEA), respectively.

the analysis of serum biomarkers and contains a large proteome that reflects health status,²⁴⁻²⁷ one of the main drawbacks of using serum tumor markers is that these markers are typically found in high concentrations only near the tumor tissue or when the disease is at an advanced stage.^{11,12} Therefore, it remains very difficult to use serum marker assays to clinically detect lung tumors at early stages.^{25,28} Cytological fluid might be a more effective sample fluid than blood for the evaluation of tumor markers, because it is obtained directly from tumor tissue, and therefore could contain many biomarkers in high concentrations.²⁵ Recently, we reported that the sensitivity for diagnosing non-small cell lung cancer increased significantly for NAB combined with cytological tumor markers compared with NAB alone (100% for cCYFRA 21-1, 92.9% for cCEA, and 94.2% for cSCC; $P = .001$, $P = .025$, and $P = .014$, respectively), and the AUC of NAB with cCYFRA 21-1 was significantly larger than the AUC of NAB alone ($P = .001$).¹⁰

According to the results of this study, the additional evaluation of tumor markers in cytological fluid can improve the diagnostic performance of CT-guided NAB for GGO pulmonary lesions. Although sensitivity and ac-

curacy did not significantly differ between NAB combined with any serum tumor marker and NAB alone, the sensitivity and accuracy of diagnosis increased significantly for NAB combined with cCYFRA 21-1 compared with NAB alone. By calculating ROC curves, we observed that the AUC of NAB with cCYFRA 21-1 was significantly larger than that of NAB alone or NAB with serum tumor markers, indicating that this cytological tumor marker has additional value for the diagnosis of GGO pulmonary lesions. Our results revealed that cCYFRA 21-1 had better diagnostic performance than other tumor markers related to lung cancer, similar to findings of previous studies concerning diagnostic performance of serum tumors related to lung cancer.^{5,10,11,29}

Our study had a number of limitations. First, our sample size was relatively small, and we were therefore unable to verify that surgery should be performed in patients with elevated NAB tumor marker concentrations in the absence of malignant cells found by fine-needle aspiration cytology. Second, the benign and malignant pathologic results were not represented in equal numbers, because more than half of the confirmed cases were malignant. Therefore, the values of cytological tumor markers

shown in this study may be limited in malignant lesions. Third, whereas most lesions had histopathologically-confirmed diagnoses, 6 benign lesions required follow-up imaging studies and clinical examinations. Fourth, the results of this study may be influenced by the methods used to choose the cutoff points for cytological tumor markers. To the best of our knowledge, no other studies on the measurement of cytological tumor markers in patients with GGO pulmonary lesions have been published, and therefore, there are no established reference values for normal cytological fluid levels of various tumor markers. In our study, we used 2 sets of reference values for cytological fluid levels of tumor markers, including a threshold that was calculated by adding 2 standard deviations to the mean levels found in patients without lung cancer and another threshold that observed lower cutoff values of 3.3 ng/mL and 5 ng/mL for CYFRA 21-1 and CEA, respectively.

Measurement of the tumor marker CYFRA 21-1 in cytological fluid can improve the diagnostic performance of CT-guided NAB for persistent GGO pulmonary lesions. On the basis of our results, cytological fluid appears to be suitable for assessing the presence and concentrations of tumor markers that might be clinically helpful to make definite diagnoses of GGO lesions. The ability to make a definite diagnosis is particularly important, because although lung biopsy using needle aspiration can confirm the diagnosis of lung cancer, the diagnostic yield and sensitivity of NAB for GGO pulmonary lesions are significantly lower than for solid pulmonary nodules because of the lower cellularity of GGO lesions.^{4,23} Performing the extra step of tumor marker concentration measurement in aspirated cytological fluid takes additional time for analysis and increases cost for these assays. However, it does not require additional puncture and is relatively easy. Considering that the AUC of NAB with cCYFRA 21-1 was significantly larger than that of NAB alone or NAB with any serum tumor markers, the clinical benefit of adding cytological fluid analysis for diagnosing persistent GGO lesions is evident. Therefore, we believe that our results provide a rationale for the evaluation of tumor markers in cytological fluid that is complementary to conventional means of diagnosis of persistent GGO pulmonary lesions.

FUNDING SOURCES

This research was supported by the Basic Science Research Program through the National Research Foundation of Korea

(NRF) funded by the Ministry of Education, Science and Technology (2010-0009053).

CONFLICT OF INTEREST DISCLOSURE

The authors made no disclosure.

REFERENCES

1. Godoy MC, Naidich DP. Subsolid pulmonary nodules and the spectrum of peripheral adenocarcinomas of the lung: recommended interim guidelines for assessment and management. *Radiology*. 2009;253:606-622.
2. Goo JM, Park CM, Lee HJ. Ground-glass nodules on chest CT as imaging biomarkers in the management of lung adenocarcinoma. *AJR Am J Roentgenol*. 2011;196:533-543.
3. Larscheid RC, Thorpe PE, Scott WJ. Percutaneous transthoracic needle aspiration biopsy: a comprehensive review of its current role in the diagnosis and treatment of lung tumors. *Chest*. 1998;114:704-709.
4. Shimizu K, Ikeda N, Tsuboi M, Hirano T, Kato H. Percutaneous CT-guided fine needle aspiration for lung cancer smaller than 2 cm and revealed by ground-glass opacity at CT. *Lung Cancer*. 2006;51:173-179.
5. Molina R, Filella X, Augé JM, et al. Tumor markers (CEA, CA 125, CYFRA 21-1, SCC and NSE) in patients with non-small cell lung cancer as an aid in histological diagnosis and prognosis. Comparison with the main clinical and pathological prognostic factors. *Tumour Biol*. 2003;24:209-218.
6. Bréchet JM, Chevret S, Nataf J, et al. Diagnostic and prognostic value of Cyfra 21-1 compared with other tumour markers in patients with non-small cell lung cancer: a prospective study of 116 patients. *Eur J Cancer*. 1997;33:385-391.
7. Collins J, Stern EJ. Ground-glass opacity at CT: the ABCs. *AJR Am J Roentgenol*. 1997;169:355-367.
8. Kim HY, Shim YM, Lee KS, Han J, Yi CA, Kim YK. Persistent pulmonary nodular ground-glass opacity at thin-section CT: histopathologic comparisons. *Radiology*. 2007;245:267-275.
9. Nakata M, Saeki H, Takata I, et al. Focal ground-glass opacity detected by low-dose helical CT. *Chest*. 2002;121:1464-1467.
10. Hong YJ, Hur J, Lee HJ, et al. Analysis of tumor markers in the cytological fluid obtained from computed tomography-guided needle aspiration biopsy for the diagnosis of non-small cell lung cancer. *J Thorac Oncol*. 2011;6:1330-1335.
11. Plebani M, Basso D, Navaglia F, De Paoli M, Tommasini A, Cipriani A. Clinical evaluation of seven tumour markers in lung cancer diagnosis: can any combination improve the results? *Br J Cancer*. 1995;72:170-173.
12. Seemann MD, Beinert T, Fürst H, Fink U. An evaluation of the tumour markers, carcinoembryonic antigen (CEA), cytokeratin marker (CYFRA 21-1) and neuron-specific enolase (NSE) in the differentiation of malignant from benign solitary pulmonary lesions. *Lung Cancer*. 1999;26:149-155.
13. Molina R, Auge JM, Escudero JM, et al. Mucins CA 125, CA 19.9, CA 15.3 and TAG-72.3 as tumor markers in patients with lung cancer: comparison with CYFRA 21-1, CEA, SCC and NSE. *Tumour Biol*. 2008;29:371-380.
14. Wieskopf B, Demangeat C, Purohit A, et al. Cyfra 21-1 as a biologic marker of non-small cell lung cancer. Evaluation of sensitivity, specificity, and prognostic role. *Chest*. 1995;108:163-169.
15. Cignarelli M, Ambrosi A, Marino A, et al. Diagnostic utility of thyroglobulin detection in fine-needle aspiration of cervical cystic metastatic lymph nodes from papillary thyroid cancer with negative cytology. *Thyroid*. 2003;13:1163-1167.

16. Kim MJ, Park BW, Lim JB, et al. Axillary lymph node metastasis: CA-15-3 and carcinoembryonic antigen concentrations in fine-needle aspirates for preoperative diagnosis in patients with breast cancer. *Radiology*. 2010;254:691-697.
17. Kagohashi K, Satoh H, Ishikawa H, Ohtsuka M, Sekizawa K. A re-evaluation of squamous cell carcinoma antigen (SCC) as a serum marker for non-small cell lung cancer. *Med Oncol*. 2008;25:187-189.
18. Kothary N, Lock L, Sze DY, Hofmann LV. Computed tomography-guided percutaneous needle biopsy of pulmonary nodules: impact of nodule size on diagnostic accuracy. *Clin Lung Cancer*. 2009;10:360-363.
19. Travis WD, Brambilla E, Noguchi M, et al. International association for the study of lung cancer/american thoracic society/european respiratory society international multidisciplinary classification of lung adenocarcinoma. *J Thorac Oncol*. 2011;6:244-285.
20. Quint LE, Kretschmer M, Chang A, Nan B. CT-guided thoracic core biopsies: value of a negative result. *Cancer Imaging*. 2006;6:163-167.
21. Colquhoun SD, Rosenthal DL, Morton DL. Role of percutaneous fine-needle aspiration biopsy in suspected intrathoracic malignancy. *Ann Thorac Surg*. 1991;51:390-393.
22. Mitruka S, Landreneau RJ, Mack MJ, et al. Diagnosing the indeterminate pulmonary nodule: percutaneous biopsy versus thoracoscopy. *Surgery*. 1995;118:676-684.
23. Hur J, Lee HJ, Nam JE, et al. Diagnostic accuracy of CT fluoroscopy-guided needle aspiration biopsy of ground-glass opacity pulmonary lesions. *AJR Am J Roentgenol*. 2009;192:629-634.
24. Sung HJ, Cho JY. Biomarkers for the lung cancer diagnosis and their advances in proteomics. *BMB Rep*. 2008;41:615-625.
25. Cho JY, Sung HJ. Proteomic approaches in lung cancer biomarker development. *Expert Rev Proteomics*. 2009;6:27-42.
26. Hanash SM, Pitteri SJ, Faca VM. Mining the plasma proteome for cancer biomarkers. *Nature*. 2008;452:571-579.
27. Anderson NL, Anderson NG. The human plasma proteome: history, character, and diagnostic prospects. *Mol Cell Proteomics*. 2002;1:845-867.
28. Niklinski J, Furman M, Chyczewska E, Chyczewski L, Rogowski F, Laudanski J. Diagnostic and prognostic value of the new tumour marker CYFRA 21-1 in patients with squamous cell lung cancer. *Eur Respir J*. 1995;8:291-294.
29. Molina R, Agusti C, Mane JM, et al. CYFRA 21-1 in lung cancer: comparison with CEA, CA 125, SCC and NSE serum levels. *Int J Biol Markers*. 1994;9:96-101.