

# Clinical trial of platelet rich fibrin insertion for exposed dental pulp of second molar associated with impacted third molar: A pilot study

Yeeun Jo , Sanghuem Cho , Woong Nam 

Department of Oral and Maxillofacial Surgery, College of Dentistry, Yonsei University, Seoul, Korea

## ABSTRACT

**Purpose:** Root resorption of second molars (M2s) due to impacted third molars (M3s) can result in pulp exposure of second molars. Platelet rich fibrin (PRF) has recently been investigated because of its positive effect on tissue healing. This study aims to determine the clinical utility of applying PRF to pulp exposure site of second molars affected by impacted third molars using radiological and clinical examination.

**Materials and Methods:** Ten patients with exposed pulp of M2 by impacted M3 were evaluated clinically and radiographically before surgery. Extraction of M3 was performed and average follow up period was 8.3 months (ranged from 1 week to 40 months). Extraction was done using conventional method and PRF was applied to pulp exposure site. PRF was obtained by collecting the patient's blood and spinning it in a centrifuge at 1300 RPM for 15 minutes. After extraction of M3, clinical and radiographic exam was done regularly to evaluate dentin bridge formation, bony healing and viability of M2.

**Results:** In 6 of 10 patients who underwent regular follow-up, dentin bridge formation and bony healing were observed radiographically at the site of PRF application. All patients remained free of symptoms implying additional external root resorption or pulp necrosis.

**Conclusion:** This study shows that the application of PRF on M2 pulp exposure site associated with impacted M3 is effective in promoting healing. Although this study demonstrates beneficial effect of PRF, further controlled studies are warranted.. (*J Korean Dent Assoc* 2025; 63(9): 298-303)

Key words : Root Resorption; Molar, Third; Tooth, Impacted; Platelet Rich Fibrin

## Introduction

Pressure associated with impacted third molars (M3) occasionally result in external root resorption (ERR) of adjacent second molars (M2)<sup>1-3</sup>. The main etiologies of ERR is known as periodontal ligament injury<sup>4,5</sup>. ERR associated with mandibular M3 is reported with various incidence which ranges from 20.17 to 52.9%<sup>6-8</sup>. And ERR

associated with maxillary M3 is reported less frequent than in mandible<sup>6,9</sup>. Additionally, male, old age, depth and angle of impaction are known as risk factors for ERR<sup>2,3,6-10</sup>. Regarding the location of ERR, cervical ERR was prevalent in mandibular M2 and apical ERR was prominent in maxillary M2<sup>8</sup>.

Regarding severity of ERR, severe ERR involving root canal exposure was prevalent in middle and apical third of a M2 root<sup>10</sup>. Incidence of severe ERR has been reported 16.7% in maxilla and 23.9% in mandible<sup>11</sup>. Symptoms of ERR are known as severe pain, allodynia on temperature, mobility, apical periodontitis, alveolar bone resorption, and root fracture<sup>12,13</sup>. Despite majority of M2 with root

Received Jun 18, 2025; Revised Aug 26, 2025; Accepted Aug 27, 2025

\*Corresponding author: Dr. Woong Nam

Department of Oral and Maxillofacial Surgery, College of Dentistry, Yonsei University, 50-1 Yonsei-ro, Seodaemun-gu, Seoul 03722, Korea  
Tel: +82-2-2228-2971, E-mail: omsnam@yuhs.ac

ISSN: 0376-4672  
eISSN: 2713-7961

Copyright © 2025 by Korean Dental Association  
This article is an open access article distributed under the terms and conditions of the Creative Commons Attribution (CC BY-NC-ND) license  
(https://creativecommons.org/licenses/by-nc-nd/4.0/).

canal exposure are asymptomatic, about 10% of patients experienced mentioned discomfort<sup>13</sup>.

Even though affected M2 are able to be treated with root canal treatment or extraction, it will be possible to prevent of this problem at the time of extraction. Several materials such as Biodentine™ (Septodont Ltd, Saint Maur des Faussés, France), calcium hydroxide, mineral trioxide aggregate, IRoot™ BP (Innovative BioCeramix Inc, Vancouver, Canada) are reported effective for treatment of exposed pulp<sup>14</sup>. Despite their well-known efficacy, it might be difficult to apply exactly on exposed M2 root canal adjacent to M3 extraction socket and its effect on extraction socket is uncertain.

Several studies have demonstrated that growth factors such as transforming growth factor  $\beta$ s, bone morphogenetic proteins, insulin growth factor, platelet-derived growth factor and vascular endothelial growth factor are significant in dentin-pulp recovery<sup>15-17</sup>. And its clinical efficacy was shown in previous studies<sup>18,19</sup>. Additionally, growth factors can promote healing potency of extraction socket<sup>20</sup>. Platelet-rich fibrin (PRF) is a concentrate of fibrin, platelet and growth factors derived from patient's blood and is a well-established biomaterial for delivering such growth factors to injured sites. PRF is extensively utilized in dentistry including oral surgery, regenerative endodontic therapy and periodontal therapy<sup>21</sup>. As a result, the application of PRF to the exposed M2 root canal and the adjacent M3 extraction socket is expected to be beneficial. However, scientific evidence supporting the therapeutic role of PRF remains limited.

Therefore, the aim of this study was to prove benefits of PRF in treatment of M2 root canal exposure induced by impacted M3 with the radiographical and clinical investigation.

## Materials and Methods

This study was approved by the institutional review

board (IRB) of Yonsei university dental hospital (IRB No.2-2025-0302).

### Selection of patients

Ten patients who visited outpatient clinic of Department of Oral and Maxillofacial Surgery in Yonsei University Dental Hospital from April 2021 to April 2025 were selected. All included patients visited clinic for impaction or cystic lesion on M3 and ERR of all cases were verified on panoramic radiography or cone-beam computed tomography (CBCT). All patients exhibited ERR involving the dental pulp of M2 due to an adjacent impacted M3. The presence of ERR was determined when definitively destructive radiolucent pattern extended to root canal was observed on M2 root adjacent to M3 on panoramic radiography and CBCT. None of patients had systemic disease affecting ERR (Table1).

### Surgical procedure

Surgical extraction of M3 was performed by a single surgeon. After enucleation of any associated cysts and removal of granulation tissue, the operator clearly identi-

Table 1. Clinical characteristics of patients with external root resorption (ERR) of second molar (M2) associated with impacted third molar (M3)

Patient	ERR site	Age/sex	Medical history
1	#37, 47	31/F	None
2	#37	34/M	None
3	#37	24/M	None
4	#47	18/M	None
5	#27	30/F	Pyelonephritis history, anxiety disorder
6	#37	20/M	None
7	#47	23/M	None
8	#47	27/M	None
9	#17	57/F	Anxiety disorder
10	#27	26/F	None

fied exposed dental pulp. On pulp exposure site, platelet rich fibrin (PRF) was applied. PRF was obtained by centrifuging 20ml of the patient's venous blood at 1300 RPM in 15 minutes. PRF covered entire root surface of M2 and floor of M3 extraction socket. Above PRF, Ateloplug® (Hyundai Bioland, Cheongju, Korea) was packed in extraction socket for hemostasis and stable application of PRF. After that, operation site was sutured with single interrupted method. Dentigerous cysts were identified intraoperatively in 4 cases and in such cases, the size of cysts was similar to a crown of M3.

### Evaluation of efficacy of PRF

To assess dentin bridge formation and bone healing, clinicians evaluated radiolucent calcification around the ERR site of M2 and increased radiopacity around the extraction area on postoperative panoramic radiographs. Postoperative panoramic radiography was taken at round a week, 4 months and then every 6months thereafter. Average follow up period was 8.3 months ranged from 1 week to 40 months. Clinical signs of pulp necrosis and progression of ERR, including increased tooth mobility, pain, infection, or hypersensitivity, were also evaluated. No additional surgical damage was observed in any case.

### Results

In 6 of 10 patients, dentin bridge formation and bone healing at the PRF application site were visible on panoramic radiographs (Figs. 1 and 2), excluding 4 patients who returned only once within one month postoperatively. In Table 2, patients who presented radiographic improvement and patients who had uncertain radiographic results due to insufficient follow-up period were described. In addition to bony healing, dental pulp atrophy was detected in a case (Fig. 3). No additional ERR

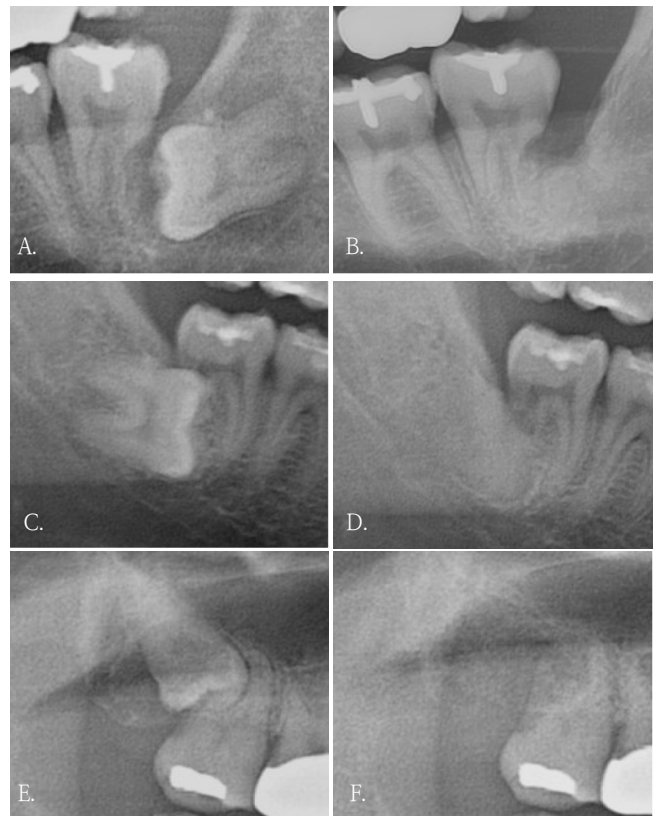


Fig. 1. Bony healing and dentin bridge formation is visible on post operative panoramic radiographies (B, D, and F) compared to preoperative panoramic radiographies (A, C, and E). A. Pre-operative panoramic radiograph of left lower third molar. B. Panoramic radiograph of left lower third molar after 11 months of surgery. C. Pre-operative panoramic radiograph of right lower third molar. D. Panoramic radiograph of right lower third molar after 14 months of surgery. E. Pre-operative panoramic radiograph of right upper third molar. F. Panoramic radiograph of right lower third molar after 11 months of surgery.

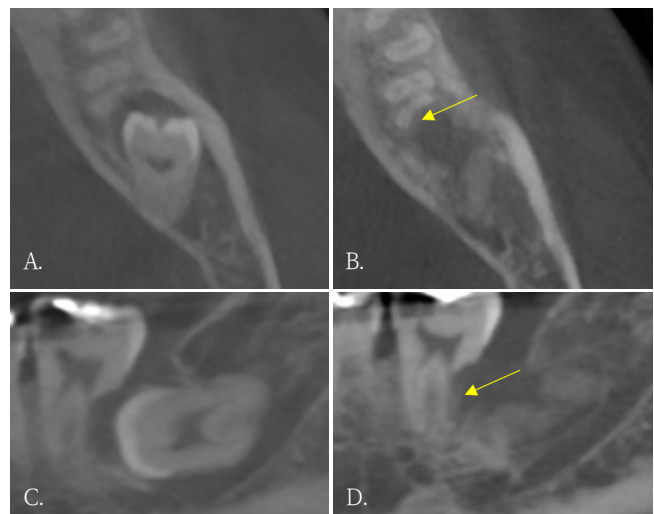


Fig. 2. Dentin formation (yellow arrows). A and C. Pre-operative cone-beam computed tomographic (CBCT) images. B and D. Post-operative CBCT after 6 months of surgery.

Table 2. Perioperative clinical findings, treatment details, and follow-up outcomes

Patient	Pre-operative symptom	Post-operative complication	Post-operative symptom	Intervention on second molar	Pathology	Bony healing or dentin formation	Duration of follow-up
1	-	infection	-	-	Dentigerous cyst	Present	4 months
2	pain	-	-	-	Dentigerous cyst	Present	3 years 4 months
3	-	-	-	-	Dentigerous cyst	Uncertain	1 month
4	-	-	-	-	-	Present	10 months
5	pain	-	-	-	-	Uncertain	1 weeks
6	-	-	-	-	-	Uncertain	2 weeks
7	-	-	-	-	-	Present	14 months
8	-	-	-	-	-	Present	4 months
9	-	-	-	-	Dentigerous cyst	Present	9 months
10	-	-	-	-	-	Uncertain	2 weeks

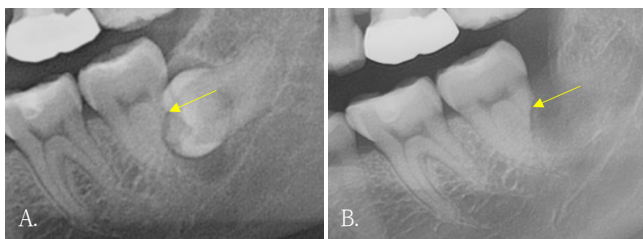


Fig. 3. Pulpal atrophy with apex closure is visible on postoperative panoramic radiography (yellow arrows). A. Pre-operative panoramic radiography. B. Panoramic radiography after 4 months of surgery.

was observed in any patients. Only one patient had pre-operative and postoperative CBCT, and dentin formation and bony healing was seen on CBCT 6 months after surgery.

None of the patients reported symptoms such as increased mobility, pain and hypersensitivity on first follow up visit. And all patients did not undergo extraction or endodontic treatment on affected M2. One patient developed a postoperative infection, which was successfully managed with cephalosporin and ibuprofen medication for a week (Table 2).

## Discussion

Since its introduction in dentistry by Choukroun et al., PRF has been widely investigated in various fields such as oral and maxillofacial surgery, periodontology and implantology<sup>22-24</sup>. Because of its cost-effectiveness, ease of preparation and excellent biocompatibility, PRF is suitable for a wide range of clinical application<sup>25</sup>. This pilot study explores clinical possibility of PRF on ERR site of M2 associated with impacted M3 and it makes clear distinction from previous studies which reported application of PRF on bone regeneration of extraction socket or pulp capping<sup>19,20</sup>. Despite the difference in application site, this study also demonstrated positive clinical results. The results of this study can serve as reliable evidence for more active utilization of PRF on ERR site of M2 associated with M3 and for conducting further related research.

The results of this study imply positive effect of PRF on ERR site of M2 associated with impacted M3. However, to verify clinical efficacy of PRF more accurately, this study needs further refinement. First, the period of radiograph-

ical evaluation needs to be standardized. In this study, the follow-up periods for radiographic evaluation varied among patients, and 4 patients lacked adequate follow up to detect meaningful changes. Further studies should include patients with long-term, standardized follow-up. Second, the modality of radiographic exam needs to be improved. CBCT is known to provide higher resolution and accuracy than panoramic radiography<sup>26,27</sup>. But not all the patients underwent postoperative CBCT. Eventually, the clinician determined favorable healing only with panoramic radiography and symptoms. To more precisely evaluate radiographic change, further studies need to contain preoperative and regular postoperative CBCT. Third, a control group or comparative study design is needed to accurately evaluate the effect of PRF. Comparable materials for further studies may include collagen plug, growth factors, newly introduced scaffolds or stem cells derived from various part of body. Lastly, method to evaluate the viability of M2s needs to be quantified. In this study, only qualitative evaluation was used to evaluate viability of M2s. Methods including the electric pulp test (EPT), regular quantitative recording of mobility and hypersensitivity are required in further studies.

Although most M2s with ERR heal asymptotically, complications such as pain, residual root fracture, alodynia may occur in some of M2. Furthermore, Qu et al.<sup>13</sup> demonstrated that older age increases the risk of such complications. According to the “Dental Outpatient Visit Trends” report published by the Health Insurance Review and Assessment Service (HIRA) in 2023, the age of patients visiting dental clinics is showing an increasing trend, possibility of harmful symptoms on ERR site associated with M3 also may increase. The efforts to improve healing of ERR site of M2 associated with impacted M3 will prevent requirement for unnecessary root canal treatment or extraction. The results of this pilot study and further studies based on this study may provide a reliable solution.

In conclusion, 6 patients who had sufficient follow

up duration showed radiographic improvements, such as dentin bridge formation and bony healing, were observed in all 6 patients within follow-up period. No patients demonstrated clinical symptoms requiring further intervention. These findings suggest that PRF may enhance the healing potency of ERR site of M2 associated with impacted M3.

## References

1. Wang HY. Root resorption associated with impacted maxillary third molar. *Oral Surg Oral Med Oral Pathol* 1992; 73: 765-6.
2. Yamaoka M, Furusawa K, Ikeda M, Hasegawa T. Root resorption of mandibular second molar teeth associated with the presence of the third molars. *Aust Dent J* 1999; 44: 112-6.
3. Nemcovsky CE, Tal H, Pitaru S. Effect of non-erupted third molars on roots of approximal teeth. A radiographic, clinical and histologic study. *J Oral Pathol Med* 1997; 26: 464-9.
4. Gunraj MN. Dental root resorption. *Oral Surg Oral Med Oral Pathol Oral Radiol Endod* 1999; 88: 647-53.
5. Ne RF, Witherspoon DE, Gutmann JL. Tooth resorption. *Quintessence Int* 1999; 30: 9-25.
6. Tassoker M. What are the risk factors for external root resorption of second molars associated with impacted third molars? A cone-beam computed tomography study. *J Oral Maxillofac Surg* 2019; 77: 11-7.
7. Wang D, He X, Wang Y, Li Z, Zhu Y, Sun C, et al., External root resorption of the second molar associated with mesially and horizontally impacted mandibular third molar: evidence from cone beam computed tomography. *Clin Oral Investig* 2017; 21: 1335-42.
8. Li D, Tao Y, Cui M, Zhang W, Zhang X, Hu X. External root resorption in maxillary and mandibular second molars associated with impacted third molars: a cone-beam computed tomographic study. *Clin Oral Investig* 2019; 23: 4195-203.
9. Ma Y, Mu D, Li X. Risk factors for root resorption of second molars with impacted third molars: a meta-analysis of CBCT

- studies. *Acta Odontol Scand* 2023; 81: 18-28.
10. Lacerda-Santos JT, Granja GL, Bento PM, Araújo-Filho JC, Melo DP, Santos JA. Prevalence of second molar external root resorption caused by mandibular third molars: a CBCT study. *Gen Dent* 2023; 71: 58-63.
  11. Sakhdari S, Farahani S, Asnaashari E, Marjani S. Frequency and severity of second molar external root resorption due to the adjacent third molar and related factors: a cone-beam computed tomography study. *Front Dent* 2021; 18: 36.
  12. Nayak MT, Nayak A. External inflammatory root resorption in mandibular first molar: a case report. *Malays J Med Sci* 2015; 22: 63-6.
  13. Qu T, Lai Y, Luo Y, Pan W, Liu C, Cao Y, et al. Prognosis of second molars with external root resorption caused by adjacent embedded third molars. *J Endod* 2022; 48: 1113-20.
  14. Matoug-Elwerfelli M, ElSheshtawy AS, Duggal M, Tong HJ, Nazzal H. Vital pulp treatment for traumatized permanent teeth: a systematic review. *Int Endod J* 2022; 55: 613-29.
  15. Smith AJ. Vitality of the dentin-pulp complex in health and disease: growth factors as key mediators. *J Dent Educ* 2003; 67: 678-89.
  16. Zhang M, Jiang F, Zhang X, Wang S, Jin Y, Zhang W, et al. The effects of platelet-derived growth factor-bb on human dental pulp stem cells mediated dentin-pulp complex regeneration. *Stem Cells Transl Med* 2017; 6: 2126-34.
  17. Xu F, Qiao L, Zhao Y, Chen W, Hong S, Pan J, et al. The potential application of concentrated growth factor in pulp regeneration: an in vitro and in vivo study. *Stem Cell Res Ther* 2019; 10: 134.
  18. Yadav RK, Jasrasaria N, Tiwari R, Verma UP. Outcomes of vital pulp therapy using various pulp capping agents. *J Conserv Dent Endod* 2025; 28: 138-43.
  19. Kirilova JN, Kosturkov D. Direct pulp capping with advanced platelet-rich fibrin: a report of two cases. *Medicina (Kaunas)* 2023; 59: 225.
  20. Srinivas B, Das P, Rana MM, Qureshi AQ, Vaidya KC, Ahmed Raziuddin SJ. Wound healing and bone regeneration in postextraction sockets with and without platelet-rich fibrin. *Ann Maxillofac Surg* 2018; 8: 28-34.
  21. Goswami P, Chaudhary V, Arya A, Verma R, Vijayakumar G, Bhavani M. Platelet-rich fibrin (PRF) and its application in dentistry: a literature review. *J Pharm Bioallied Sci* 2024; 16(Suppl 1): S5-7.
  22. Miron RJ, Zucchelli G, Pikos MA, Salama M, Lee S, Guillemette V, et al., Use of platelet-rich fibrin in regenerative dentistry: a systematic review. *Clin Oral Investig* 2017; 21: 1913-27.
  23. Choukroun J, Adda F, Schoeffler C, Vervelle A. Une opportunité en para-implantologie: Le PRF. *Implantodontie* 2000; 42: 55-62.
  24. Fan Y, Perez K, Dym H. Clinical uses of platelet-rich fibrin in oral and maxillofacial surgery. *Dent Clin North Am* 2020; 64: 291-303.
  25. Barone S, Bennardo F, Salviati M, Antonelli A, Giudice A. Evaluation of the usefulness of platelet-rich fibrin (PRF) in mandibular third molar surgery with 3D facial swelling analysis: a split-mouth randomized clinical trial. *Head Face Med* 2025; 21: 8.
  26. Huang FM, Yang SF, Zhao JH, Chang YC. Platelet-rich fibrin increases proliferation and differentiation of human dental pulp cells. *J Endod* 2010; 36: 1628-32.
  27. Holiel AA, Mahmoud EM, Abdel-Fattah WM. Tomographic evaluation of direct pulp capping using a novel injectable treated dentin matrix hydrogel: a 2-year randomized controlled clinical trial. *Clin Oral Investig* 2021; 25: 4621-34.