



OPEN ACCESS

Subdural hygroma as a rare complication after revision spine surgery

Yung Park,¹ Chang-Min Lee,^{1,2} Joong-Won Ha,¹ Jae-Won Shin^{1,2}

¹Department of Orthopedic Surgery, National Health Insurance Service Ilsan Hospital, Goyang, Korea (the Republic of)
²Department of Orthopedic Surgery, Yonsei University College of Medicine, Seodaemun-gu, Seoul, Korea (the Republic of)

Correspondence to
Jae-Won Shin;
jaewuni@nhimc.or.kr

Accepted 5 January 2023

SUMMARY

Spinal fusion surgery is the most commonly performed orthopaedic surgical procedure. However, subdural hygroma occurrence is a very rare complication after revision spinal fusion surgery. Here, we report a case of revision lumbar fusion surgery at the L3–4 level. The patient developed acute conus medullaris syndrome at 10 days postoperatively. MRI showed a subdural, extra-arachnoid area fluid collection following the T12–L2, cephalad to the area of revision spinal fusion. When patients have a decreased motor grade, difficulty in voiding urine and neurological abnormalities after lumbar spine surgery, conus medullaris syndrome with a possible occurrence of subdural hygroma should be considered. In this situation, immediate imaging investigations and emergency surgery might be necessary to reduce the pressure on the spinal cord.

BACKGROUND

Spinal subdural hygroma (SSH) refers to excess fluid retention in the subdural space along the spine. SSH must be differentially diagnosed from a subdural haematoma, empyema and lipoma. This differentiation can be made using MRI, mainly owing to differences in the parts involved in these complications. Cystic lesions are located in the epi-arachnoid or subdural spaces. The physiology behind cerebrospinal fluid (CSF) accumulation within the subdural space is hypothesised to result from tears in the arachnoid membrane. Although SSH is possible, it is a rare complication of cranial and spinal surgeries. Some cases of SSH have been reported following spinal decompression surgery. In the most cases, a pinhole leak in the arachnoid membrane caused SSH.^{1,2}

This case report describes a postoperative complication, especially the case of a patient with conus medullaris syndrome with SSH developed proximal to the area of spinal fusion. Contrary to previously reported cases, SSH occurred very late in our case, at 10 days postoperatively.

CASE PRESENTATION

This retrospective review was conducted with the approval of the corresponding institutional review board of our hospital. A woman in her 70s with chronic kidney disease, diabetes mellitus and hypertension underwent laminectomy and discectomy at L4–5–S1 and posterior lumbar interbody fusion at L4–5–S1 2 years previously. At 1 year and 6 months after the first surgery, she visited the outpatient

clinic for aggravated back pain and radiculopathy. Radiography and MRI findings revealed an L3 spinal compression fracture, severe central canal stenosis and right foraminal stenosis at L3–4, and bilateral pedicle screw loosening at L4 (figure 1A). Therefore, we performed revisional surgery. L3–4 posterior decompression and posterolateral fusion, as well as posterior instrumentation, were performed at L2–3–4.

Postoperatively, the patient underwent prolonged periods of bed rest, and her general weakness was severe. On postoperative day 8, the patient started walking. At 10 days after the revision surgery, the patient had decreased right lower extremity motor and sensory scores. Urinary retention and sacral hypoesthesia were observed.

INVESTIGATIONS

MRI performed immediately after the patient-reported symptoms revealed a newly developed subdural fluid collection extending between T12–L1–L2, located on the right side of the canal, compressing the spinal cord (figure 1B).

TREATMENT

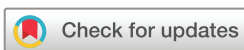The patient's right lower extremity motor function deteriorated further as time passed. Therefore, we decided to perform emergency surgical exploration with posterior decompression by T12–L1–L2 laminectomy and epi-arachnoid fluid evacuation. After making a 5 mm incision in the dural sac, a yellowish fluid was drained. After fully draining this yellowish fluid, the dural sac was successfully repaired. After surgery, although the right motor grade slowly recovered, urinary retention persisted.

OUTCOME AND FOLLOW-UP

MRI performed at 2 weeks after the final surgery revealed complete removal of subdural fluid accumulation at the L1–2 level and resolved moderate spinal cord compression (figure 1C). At 4 weeks postoperatively, the patient's motor grade was restored to grade 4. The patient's sensory grade almost recovered to a normal level.

DISCUSSION

Subdural hygroma is a very rare but well-known complication of revision spinal surgery, spinal anaesthesia or Chiari malformation surgery,^{1,2} such as foramen magnum decompression.^{3–5} Development of neurological symptoms after spinal fusion surgery due to CSF collection is rare and difficult to diagnose.^{3,6} A subdural hygroma is a CSF collection



© BMJ Publishing Group Limited 2023. Re-use permitted under CC BY-NC. No commercial re-use. See rights and permissions. Published by BMJ.

To cite: Park Y, Lee C-M, Ha J-W, et al. *BMJ Case Rep* 2023;**16**:e253760. doi:10.1136/bcr-2022-253760

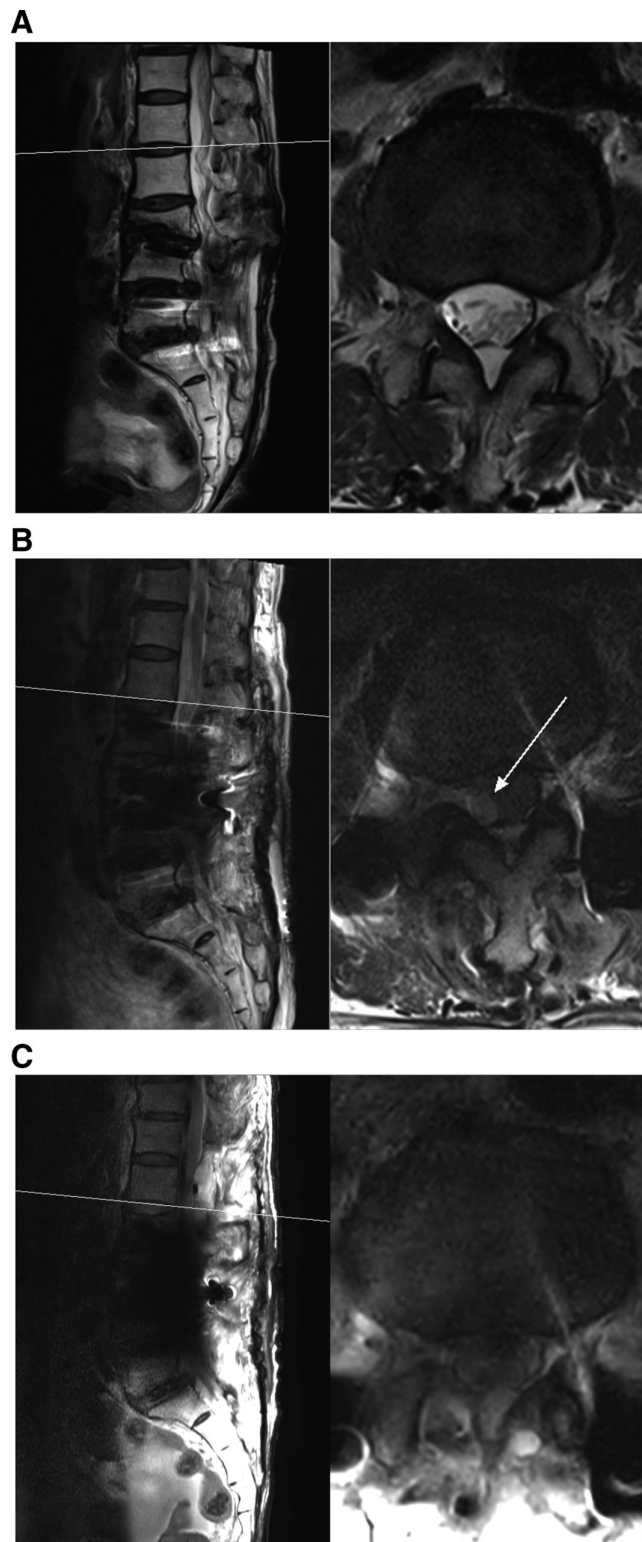


Figure 1 (A) Sagittal and axial T2-weighted MRI obtained preoperatively, 6 months after a previous laminectomy and discectomy at L4–5 and posterior lumbar interbody fusion at L4–5–S1. There were no signs of fluid collection. (B) Sagittal and axial T2 MRI obtained 10 days after the development of conus medullaris syndrome. The image reveals newly developed subdural complicated fluid collection (arrow) through the T12–L1–L2 level, which seems to cause moderate conus medullaris compromise. (C) Sagittal and axial T2 MRI obtained after hygroma evacuation. The previous fluid collection is resolved.

between the dura mater and the arachnoid membrane. In the most previous cases, incidental durotomy could occur during decompressive surgery, resulting in CSF leakage.^{7 8} Without evidence of durotomy, CSF collection can be accompanied by a pinhole injury to the arachnoid membrane, and a one-way slit valve may develop, causing CSF collection in the subdural space.⁹

In this case, SSH occurred following revision fusion surgery. In most previous cases, SSH occurred 2–5 days postoperatively. This can be related to the starting point of ambulation. However, in this case, SSH occurred at 10 days postoperatively, which was different from other reported cases. The exact cause of this delay is unknown.^{4 5} However, ambulation was delayed owing to the patient's poor post-operative condition and remarkable medical history. The symptoms developed at 2 days after ambulation, and the onset of SSH might have been related to the initiation of ambulation and movement of fluids in the epiarachnoid space. There were no events, such as dura tears, during the operation. Nevertheless, as this was a revision fusion surgery, the risk of dura injury was higher. Generally, the fluid collection was caused by a pinhole injury to the arachnoid membrane resulting in a spread of fluid in the subdural and epiarachnoid space, which might have been caused by the movement of the collected fluid in the subdural space after ambulation.^{7 8}

In cases where the motor grade decreased a few days after surgery, the cause of the haematoma was considered first, and MRI scanning was urgently performed after a physical examination. It should be noted that SSH could also cause spinal cord or root compression after spinal fusion surgery. Therefore, it is necessary to note that rapid MRI and treatment could affect a patient's long-term outcomes.^{10–12} In previous studies, the cause of SSH was only a hypothesis, and no clear cause was ever revealed. To prevent SSH after revision spinal fusion surgery, more researches on the causative factors are needed.

SSH should be considered one of the causes of motor weakness after revision lumbar fusion surgery. Early diagnosis and decompression surgery may help achieve recovery.

Learning points

- ▶ Subdural hygroma is a rare complication after revision spinal fusion surgery.
- ▶ When delayed motor weakness is evoked after revision spinal fusion surgery, a subdural hygroma may be the cause.
- ▶ To make a differential diagnosis of subdural hygroma from other problems, detailed history taking, physical examination and performing MRI are essential.
- ▶ When subdural hygroma is diagnosed, it is important to treat it with surgery quickly to achieve recovery.

Contributors J-WS: conceptualisation, project administration, investigation, methodology, resource, software. C-ML: data curation, writing-original draft, formal analysis, visualisation. J-WH: Supervision. YP: writing-reviewing and editing, funding acquisition, validation.

Funding The authors have not declared a specific grant for this research from any funding agency in the public, commercial or not-for-profit sectors.

Competing interests None declared.

Patient consent for publication Consent obtained directly from patient(s).

Provenance and peer review Not commissioned; externally peer reviewed.

Open access This is an open access article distributed in accordance with the Creative Commons Attribution Non Commercial (CC BY-NC 4.0) license, which

permits others to distribute, remix, adapt, build upon this work non-commercially, and license their derivative works on different terms, provided the original work is properly cited and the use is non-commercial. See: <http://creativecommons.org/licenses/by-nc/4.0/>.

Case reports provide a valuable learning resource for the scientific community and can indicate areas of interest for future research. They should not be used in isolation to guide treatment choices or public health policy.

REFERENCES

- Vien C, Marovic P, Ingram B. Epidural anesthesia complicated by subdural hygromas and a subdural hematoma. *Case Rep Anesthesiol* 2016;2016:5789504.
- Lai YC, Chia YY, Lien WH. Reversal of progressive conscious disturbance with epidural blood patch for cerebrospinal fluid leakage at C2 level. *Pain Physician* 2017;20:E465–8.
- Marshman LAG, Benjamin JC, Chawda SJ, et al. Acute obstructive hydrocephalus associated with infratentorial subdural hygromas complicating Chiari malformation type I decompression. Report of two cases and literature review. *J Neurosurg* 2005;103:752–5.
- Zakaria R, Kandasamy J, Khan Y, et al. Raised intracranial pressure and hydrocephalus following hindbrain decompression for Chiari I malformation: a case series and review of the literature. *Br J Neurosurg* 2012;26:476–81.
- Suzuki F, Kitagawa T, Takagi K, et al. Subacute subdural hygroma and presyrinx formation after foramen magnum decompression with duraplasty for Chiari type 1 malformation. *Neural Med Chir (Tokyo)* 2011;51:389–93.
- Ranjan A, Cast IP. Symptomatic subdural hygroma as a complication of foramen magnum decompression for hindbrain herniation (Arnold-Chiari deformity). *Br J Neurosurg* 1996;10:301–3.
- Herren C, Sobottke R, Mannion AF, et al. Incidental durotomy in decompression for lumbar spinal stenosis: incidence, risk factors and effect on outcomes in the spine tango registry. *Eur Spine J* 2017;26:2483–95.
- Papavero L, Engler N, Kothe R. Incidental durotomy in spine surgery: first aid in ten steps. *Eur Spine J* 2015;24:2077–84.
- Nentwig MJ, Whitaker CM, Yang SY. Spinal subdural hygroma as a post-operative complication in revision spine fusion: a case report. *J Surg Case Rep* 2019;2019:rjz305.
- Elder BD, Ishida W, Goodwin RC, et al. Iatrogenic spinal subdural extra-arachnoid hygroma following uncomplicated lumbar decompression. *Cureus* 2017;9:e1171.
- Kaliya-Perumal A-K, Lu M-L, Kao F-C, et al. Delayed extensive lumbar sub-dural effusion following discectomy-clinical imaging and case report. *Biomedicine (Taipei)* 2017;7:6:..
- Yi CK, Biega TJ, Burgos RM. Spontaneous resolution of idiopathic lumbar subdural hygroma on CT myelography and lumbar spine MRI. *BMJ Case Rep* 2014;2014:bcr2014206223.

Copyright 2023 BMJ Publishing Group. All rights reserved. For permission to reuse any of this content visit <https://www.bmj.com/company/products-services/rights-and-licensing/permissions/>
BMJ Case Report Fellows may re-use this article for personal use and teaching without any further permission.

Become a Fellow of BMJ Case Reports today and you can:

- ▶ Submit as many cases as you like
- ▶ Enjoy fast sympathetic peer review and rapid publication of accepted articles
- ▶ Access all the published articles
- ▶ Re-use any of the published material for personal use and teaching without further permission

Customer Service

If you have any further queries about your subscription, please contact our customer services team on +44 (0) 207111 1105 or via email at support@bmj.com.

Visit casereports.bmj.com for more articles like this and to become a Fellow