JCN Open Access ORIGINAL ARTICLE

pISSN 1738-6586 / eISSN 2005-5013 / J Clin Neurol 2023;19(5):460-468 / https://doi.org/10.3988/jcn.2022.0374

Clinical and Radiological Features of Korean Patients With Anti-HMGCR Myopathy

Eun Kyoung Oh[a*], Seung-Ah Lee[b*] Hyun Joon Lee[a], Yoon Jin Cha[c] Sungjun Kim[d], Hyung-Soo Lee[e] Bum Chun Suh[f], Ha Young Shin[g] Seung Woo Kim[g], Byeol-A Yoon[h] Seong-il Oh[i], Yoo Hwan Kim[j] Joong-Yang Cho[k], Jeong Hee Cho[l] Ki-Han Kwon[m], Young-Chul Choi[a,n] Hyung Jun Park[a,n]

Departments of [a]Neurology, [c]Pathology, and [d]Radiology, Gangnam Severance Hospital, Yonsei University College of Medicine, Seoul, Korea
[b]Department of Neurology, Mokdong Hospital, Ewha Womans University School of Medicine, Seoul, Korea
[e]Department of Neurology, Korea University Ansan Hospital, Ansan, Korea
[f]Department of Neurology, Kangbuk Samsung Hospital, Sungkyunkwan University School of Medicine, Seoul, Korea
[g]Department of Neurology, Severance Hospital, Yonsei University College of Medicine, Seoul, Korea
[h]Department of Neurology, Peripheral Neuropathy Research Center, College of Medicine, Dong-A University, Busan, Korea
[i]Department of Neurology, Busan Paik Hospital, Inje University College of Medicine, Busan, Korea
[j]Department of Neurology, Hallym University Sacred Heart Hospital, Hallym University College of Medicine, Anyang, Korea
[k]Department of Neurology, Ilsan Paik Hospital, Inje University College of Medicine, Goyang, Korea
[l]Department of Neurology, National Health Insurance Service Ilsan Hospital, Goyang, Korea
[m]Department of Neurology, Dongtan Sacred Heart Hospital, Hallym University College of Medicine, Hwaseong, Korea
[n]Rehabilitation Institute of Neuromuscular Disease, Gangnam Severance Hospital, Yonsei University College of Medicine, Seoul, Korea

Received September 29, 2022
Revised November 10, 2022
Accepted November 10, 2022

Correspondence
Hyung Jun Park, MD, PhD
Department of Neurology, Gangnam Severance Hospital, Yonsei University College of Medicine, 211 Eonju-ro, Gangnam-gu, Seoul 06273, Korea
Tel +82-2-2019-3329
Fax +82-2-3462-5904
E-mail hjpark316@yuhs.ac

*These authors contributed equally to this work.

Background and Purpose To understand the characteristics of Korean patients with anti-3-hydroxy-3-methylglutaryl-coenxyme A reductase (HMGCR) myopathy, we measured anti-HMGCR antibodies and analyzed the clinical, radiological, and pathological features of patients with anti-HMGCR myopathy.

Methods We measured titers of anti-HMGCR antibodies in the sera of 99 patients with inflammatory myopathy, 36 patients with genetic myopathy, and 63 healthy subjects using an enzyme-linked immunosorbent assay. We tested 16 myositis-specific autoantibodies (MSAs) in all patients with anti-HMGCR myopathy.

Results Positivity for the anti-HMGCR antibody was observed in 17 (4 males and 13 females) of 99 patients with inflammatory myopathy. The median age at symptom onset was 60 years. Ten (59%) of the patients with anti-HMGCR positivity had taken statins. The titer of anti-HMGCR antibodies was significantly higher in the statin-naïve group (median=230 U/mL, interquartile range=170−443 U/mL) than in the statin-exposed group (median=178 U/mL, interquartile range=105−210 U/mL, p=0.045). The most common symptom was proximal muscle weakness in 15 patients (88%), followed by myalgia in 9 (53%), neck weakness in 4 (24%), dysphagia in 3 (18%), and skin lesions in 2 (12%). The median titer of anti-HMGCR antibody was 202 U/mL. We found eight different MSAs in nine (53%) patients. The median disease duration from symptom onset to diagnosis was significantly shorter in the MSA-positive group than in the MSA-negative group (p=0.027).

Conclusions Our study was the first to measure anti-HMGCR antibodies in inflammatory myopathy. It has provided new findings, including the suggestion of the coexistence of other MSAs in Korean patients.

Keywords myositis; necrotizing myopathy; autoantibodies; HMGCR; enzyme-linked immunosorbent assay.

INTRODUCTION

Immune-mediated necrotizing myopathy (IMNM) is a subgroup of inflammatory myopathy characterized by subacute proximal weakness and prominent myofiber necrosis with minimal inflammatory cell infiltrate in muscle biopsies. Autoantibodies are useful immunological biomarkers for providing various types of information, including clinical and histopathological features, therapeutic responses, and prognosis predictions. Two autoantibodies have been found to be associated with IMNM: those against the signal recognition particle (SRP) and the 3-hydroxy-3-methylglutaryl-coenxyme A reductase (HMGCR).[1,2] Anti-HMGCR antibody was first identified in 2010.[1]

HMGCR is located at the endoplasmic reticulum membrane and is a key enzyme in the cholesterol biosynthesis pathway.[3] The identification of this antibody has attracted consid-

erable attention because of its possible association with statins. Statins are structural analogues of HMGCR and competitively inhibit it. Statins are one of the most frequently prescribed drugs and are taken by more than an estimated 30 million Americans. Anti-HMGCR myopathy was first identified in patients with statin exposure,[1,4] but subsequent studies found that statin exposure in anti-HMGCR myopathy is highly variable and is particularly low in Asia.[5-7] The pathogenic mechanism of anti-HMGCR myopathy is presumed to involve the genetic susceptibility of patients and environmental factors such as statin exposure.[8] However, its exact pathogenic mechanism is unknown. There have only been two previous case reports of Korean patients with anti-HMGCR myopathy.[9,10] We therefore measured anti-HMGCR antibodies and analyzed clinical, radiological, and pathological features in these patients to understand their characteristics.

METHODS

Patient selection

We reviewed the medical records of patients with myopathy who were referred to Gangnam Severance Hospital between January 2002 and March 2022. We then selected 99 patients with inflammatory myopathy, comprising 82 with polymyositis, 9 with dermatomyositis, and 8 with inclusion-body myositis. We also selected 63 healthy subjects and 36 patients with genetic myopathy. The most common genetic myopathy subgroup was limb-girdle muscular dystrophy in 11 patients, followed by congenital myopathy in 6, distal myopathy in 4, facioscapulohumeral muscular dystrophy type I in 3, Becker muscular dystrophy in 3, myotonic dystrophy in 3, mitochondrial myopathy in 3, and metabolic myopathy in 3.

This study was approved by the Institutional Review Board of Gangnam Severance Hospital, Korea (IRB No. 3-2020-0251). Written informed consent was obtained from all patients in accordance with the approved protocol. The study was also conducted in accordance with the Declaration of Helsinki for medical research involving human subjects.

Phenotype assessment

Clinical, laboratory, and pathological data were obtained retrospectively by reviewing medical records. Clinical information included assessments of the age at symptom onset, disease duration, muscle impairments, dysphagia, myalgia, skin lesions, interstitial lung disease, cancers, and treatment regimens. Laboratory analyses included the serum creatine kinase (CK) level. Physical disability was evaluated using the seven-level modified Rankin Scale (mRS) score as follows: 0, no symptoms; 1, symptoms but no disability in daily function; 2, slight disability with inability to carry out previous activities, but can function without assistance; 3, moderate disability requiring some help but able to walk without assistance; 4, moderately severe with inability to walk without assistance and the need of assistance for bodily care; 5, severe disability, bedridden and requiring constant nursing care; and 6, dead.[11]

Patients were considered to have inflammatory myopathy if they met the 2017 European League Against Rheumatism/American College of Rheumatology (EULAR/ACR) criteria for inflammatory myopathies in adults.[12] According to this classification, 99 inflammatory myopathies were classified, with 30 (30%) in the definite inflammatory myopathy group and 69 (70%) in the probable inflammatory myopathy group. Muscle biopsies were performed on 60 (60%) patients. Further subclassification of inclusion-body myositis was followed by the development of classification trees using the 2017 EULAR/ACR classification criteria.[12]

Anti-HMGCR enzyme-linked immunosorbent assay

Anti-HMGCR antibodies were measured in the sera of 99 patients with inflammatory myopathy, 36 patients with genetic myopathy, and 63 healthy subjects. Enzyme-linked immunosorbent assay (ELISA) plates coated with recombinant HMGCR were incubated using diluted serum. The assay was performed according to the standard protocol from the manufacturer of the QUANTA Lite assay (Inova Diagnostics, San Diego, CA, USA).[13] The cutoff level for positivity was 20 U/mL.

Line-blot immunoassay for 16 myositis-specific autoantibodies

We tested 16 myositis-specific autoantibodies (MSAs) in all of the patients with anti-HMGCR myopathy against the following antigens: Mi-2α, Mi-2β, TIF1γ, MDA5, NXP2, SAE1, Ku, PM-Scl100, PM-Scl75, Jo-1, SRP, PL-7, PL-12, EJ, OJ, and Ro-52. These antibodies were tested using the EUROLINE Autoimmune Inflammatory Myopathies 16 Ag (EUROIMMUN, Lübeck, Germany) line-blot immunoassay according to the standard protocol. EUROIMMUN recommends interpreting results based on signal intensity. Signal intensities exceeding 25 on the EUROLine Scan flatbed scanner generated medium-to-strong bands and were considered positive results for the antibodies. Results are expressed as + for medium, ++ for strong, and +++ for very strong bands, with intensity bands determined in comparison with the control band.

Histological examinations

Muscle biopsy was performed on ten patients (P1, P2, P3, P4, P5, P6, P7, P8, P12, and P14). All histological and histochemical staining procedures were performed on frozen materials. Sections were cut in a cryostat at -23°C to -25°C. Briefly, 10-μm-thick sections were prepared for histochemistry analysis. All

available slides were stained with hematoxylin and eosin, modified Gomori trichrome, and nicotinamide adenine dinucleotide−tetrazolium reductase, and they were then evaluated by a pathologist.

Lower-limb magnetic resonance imaging

Seven patients (P2, P4, P5, P6, P7, P10, and P16) underwent lower-limb magnetic resonance imaging (MRI) of the pelvis, thigh, and calf muscles using one of the following three MRI machines: two 1.5T systems (MAGNETOM Vision or MAGNETOM Avanto, Siemens, Erlangen, Germany) and one 3T system (MAGNETOM Vida, Siemens). The imaging was performed on the axial (field of view [FOV]=24−32 cm, slice thickness=10 mm, and slice gap=0.5−1.0 mm) and coronal (FOV=38−40 cm, slice thickness=4−5 mm, and slice gap=0.5−1.0 mm) planes. The protocol used for all patients comprised T1-weighted spin-echo (SE) (repetition time [TR]=570−650 ms, echo time [TE]=14−20 ms, and 12 metrics) and short tau inversion recovery (STIR)-weighted SE (TR=3,090−4,900 ms, TE=85−99 ms, and 12 matrices). The degree of fatty replacement was evaluated according to the Mercuri scale: grade 0, normal appearance; grade 1, traces of increased signal intensity; grade 2, increased signal intensity with confluence in less than 50% of the muscle; grade 3, increased signal intensity in more than 50% of the muscle; and grade 4, increased signal intensity over the entire muscle.[14,15]

Statistical analysis

Fisher's exact test was used to compare discrete variables. The Mann-Whitney test was used to compare the age at symptom onset, disease duration, serum CK level, and titer of serum anti-HMGCR antibodies. The correlations between titers of anti-HMGCR antibodies and serum CK levels were investigated using Spearman's correlation analysis. We compared the mRS scores and the titers of anti-HMGCR antibody between pre- and posttreatment using the Wilcoxon signed-rank test. Differences were considered significant at $p \leq 0.05$. All statistical analyses were performed using R software (version 4.2.0, www.r-project.org).

RESULTS

Anti-HMGCR ELISA

Fig. 1 presents the anti-HMGCR antibody values. Anti-HMGCR antibody positivity was observed in 17 of 99 (17%) the patients with inflammatory myopathy. The prevalence of anti-HMGCR antibodies was highest in patients with polymyositis (15/82, 18%), followed by in those with dermatomyositis (2/9, 22%). Anti-HMGCR antibodies were negative in all patients with inclusion-body myositis (0/8) and in 36 patients with genetic myopathy. The titer of anti-HMGCR antibodies was elevated in 3 of 63 healthy subjects (22, 25, and 28 U/mL). However, the titer of anti-HMGCR antibodies was lower in healthy subjects than in patients with inflammatory myopathy (median=202 U/mL, interquartile range=162.5−235.5 U/mL). Three healthy subjects took no statins, had no muscle weakness, and had normal serum CK levels.

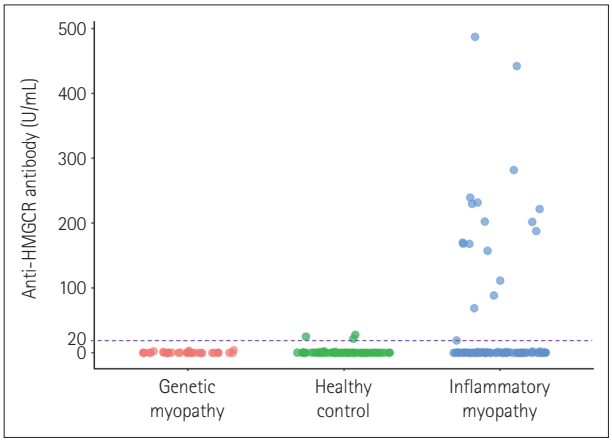

Fig. 1. HMGCR ELISA. Antibodies reactive with recombinant HMGCR protein in ELISA in the sera of patients with inflammatory myopathy and genetic myopathy, and healthy controls. The cutoff level for positivity is indicated by the broken line (20 U/mL). ELISA, enzyme-linked immunosorbent assay; HMGCR, anti-3-hydroxy-3-methylglutaryl-coenxyme A reductase.

Clinical features of patients with anti-HMGCR myopathy

Table 1 lists the clinical and pathological features of 17 patients (4 males and 13 females). The median age at symptom onset was 60 years (interquartile range=49−73 years). The median duration from symptom onset to diagnosis was 8 months (interquartile range=4−9 months). One patient (P8) had lung squamous cell carcinoma, while no patient had concomitant interstitial lung disease. The most common symptoms were proximal muscle weakness in 15 patients (88%), myalgia in 9 (53%), neck weakness in 4 (24%), dysphagia in 3 (18%), and skin lesions in 2 (12%). The median serum CK level was 7,482 IU/l (interquartile range=4,179.5−11,533.5 IU/l). The median titer of anti-HMGCR antibody was 202 U/mL (interquartile range=162.5−235.5 IU/l). The titer of anti-HMGCR was significantly associated with serum CK levels in 17 patients (r=0.606, p=0.010).

Ten (59%) patients had taken statins: eight had taken atorvastatin and two had taken rosuvastatin. The median duration of treatment with statin was 3.5 years (interquartile range=2.25−7.25 years). We compared the clinical characteristics between the statin-exposed (n=0) and statin-naïve (n=7) groups (Supplementary Table 1 in the online-only Data Supplement).

Table 1. Clinical presentation, laboratory parameters, management, and outcome of patients with anti-HMGCR myopathy (n=17)

Patient	P1	P2	P3	P4	P5	P6	P7	P8	P9	P10	P11	P12	P13	P14	P15	P16	P17
Age at onset, years	59	73	55	63	44	73	50	73	60	49	49	65	42	79	63	26	75
Sex	F	F	M	F	M	F	F	M	F	F	F	F	F	M	F	F	F
Duration, months	24	6	9	9	9	9	109	1	4	4	8	8	5	4	4	108	1
Statin exposure	-	A	A	A	A	-	-	-	R	-	A	A	-	A	R	-	A
Associated cancer	-	-	-	-	-	-	-	Lung	-	-	-	-	-	-	-	-	-
Physical exam																	
Proximal weakness	+	+	+	+	+	+	+	+	-	+	+	+	+	+	+	+	-
Neck weakness	+	+	-	+	+	-	-	-	-	-	-	-	-	-	-	-	-
Dysphagia	-	+	-	-	+	-	-	-	-	-	-	-	-	-	+	-	-
Myalgia	-	+	+	-	-	+	-	-	+	+	+	-	+	+	-	-	+
Skin lesion	-	-	-	-	+	-	-	-	-	+	-	-	-	-	-	-	-
ILD	-	-	-	-	-	-	-	-	-	-	-	-	-	-	-	-	-
CK, IU/l	6,017	7,482	11,716	11,188	33,410	12,138	8,415	13,580	1,200	2,232	5,097	4,494	10,655	11,351	3,464	5,614	3,865
Anti-HMGCR Ab, U/mL	282	232	239	188	202	443	222	230	111	168	68	157	457	168	88	170	202
MSAs*	-	Mi2b (+)	-	MDA5 (+)	-	-	-	Ro52 (+)	-	-	NXP2 (++)	Ro52 (+)	Ro52 (++), OJ (+)	SAE1 (++)	PL-7 (+)	-	PM75 (+)
Treatment regimen	GC, AZA	GC, MTX, IVIG	GC, AZA	GC, MTX, IVIG	GC, AZA	GC	GC, AZA, MTX, IVIG	GC, IVIG, RTM	None	GC	GC, MTX	GC, AZA	GC, TAC, MTX	GC	GC, MTX,	GC, MTX, IVIG	None
Muscle biopsy																	
Necrosis fibers	Many	Some	Many	Many	Some	Many	Few	Many	N/A	N/A	N/A	Some	N/A	Many	N/A	N/A	N/A
Regenerating fibers	Many	Some	Some	Some	Some	Many	Few	Many	N/A	N/A	N/A	Some	N/A	Some	N/A	N/A	N/A
Inflammatory cell infiltrates	-	-	-	-	-	-	-	Few	N/A	N/A	N/A	-	N/A	Few	N/A	N/A	N/A

*MSA grading: +, medium band; ++, strong band; +++, very strong band.
A, atorvastatin; AZA, azathioprine; CK, creatine kinase; F, female; GC, glucocorticoid; HMGCR, 3-hydroxy-3-methylglutaryl-coenxyme A reductase; ILD, interstitial lung disease; IVIG, immunoglobulin; M, male; MSA, myositis-specific autoantibody; MTX, methotrexate; N/A, not available; R, rosuvastatin; RTM, rituximab; TAC, tacrolimus.

The titer of anti-HMGCR antibodies was significantly higher in the statin-naïve group (median=230 U/mL, interquartile range=170−443 U/mL vs. median=178 U/mL, interquartile range=105−210 U/mL; p=0.045). However, there were no significant differences in sex, age at symptom onset, disease duration, and serum CK levels between the groups.

We found eight MSAs among nine (53%) patients: autoantibodies against Ro52 in three, and those against Mi2b, MDA5, NXP2, OJ, PL-7, PM75, and SAE1 in one each (Table 1). We compared the clinical characteristics of the MSA-positive (n=9) and MSA-negative (n=8) groups (Supplementary Table 2 in the online-only Data Supplement). The median duration from symptom onset to diagnosis was significantly shorter in the MSA-positive group (5 months, interquartile range=3−8 months vs. 9 months, interquartile range=5−87 months; p=0.027). The median age at symptom onset tended to be higher in the MSA-positive group (65 years, interquartile range=56−74 years vs. 53 years, interquartile range=45−60 years; p=0.0596). However, there were no differences in sex, stain exposure status, serum CK levels, or the presence of anti-HMGCR antibodies between the two groups.

Two patients (P7 and P16) with anti-HMGCR myopathy were initially misdiagnosed with muscular dystrophy, which delayed the appropriate diagnosis. Patient P7 was initially suspected of polymyositis and treated accordingly. However, steroid therapy did not improve muscle weakness and a biopsy revealed few necrotic fibers and increased endomysial fibrosis without inflammatory cell infiltrates (Fig. 2A-C). Thereafter she was misdiagnosed with muscular dystrophy and did not receive immunotherapy. After 109 months from symptom onset, we suspected that she had IMNM because steroid use did not improve the muscle strength but decreased the serum CK level. Patient P16 complained of slowly progressive muscle weakness at 26 years old. Her condition was initially mistaken for muscular dystrophy due to its early onset and slowly progressing weakness. She was referred to our clinic and was diagnosed with IMNM at 108 months after symptom onset.

The treatment regimens undergone by 17 patients were analyzed. In two patients (P9 and P17), myalgia was resolved and the serum CK level normalized after discontinuation of the statin alone. High-dose intravenous methylprednisolone pulse therapy and subsequently varying regimens of other immunosuppressive agents were initially administered to 15 (88%) patients. These regimens included methotrexate in seven patients (41%), azathioprine in five (29%), intravenous immunoglobulin in five (29%), tacrolimus in one (6%), and rituximab in one (6%). Seven patients (P1, P2, P3, P4, P5, P7, and P10) were followed up for 32, 24, 21, 27, 106, 24, and 20 months, respectively. The mRS scores and titer of an-

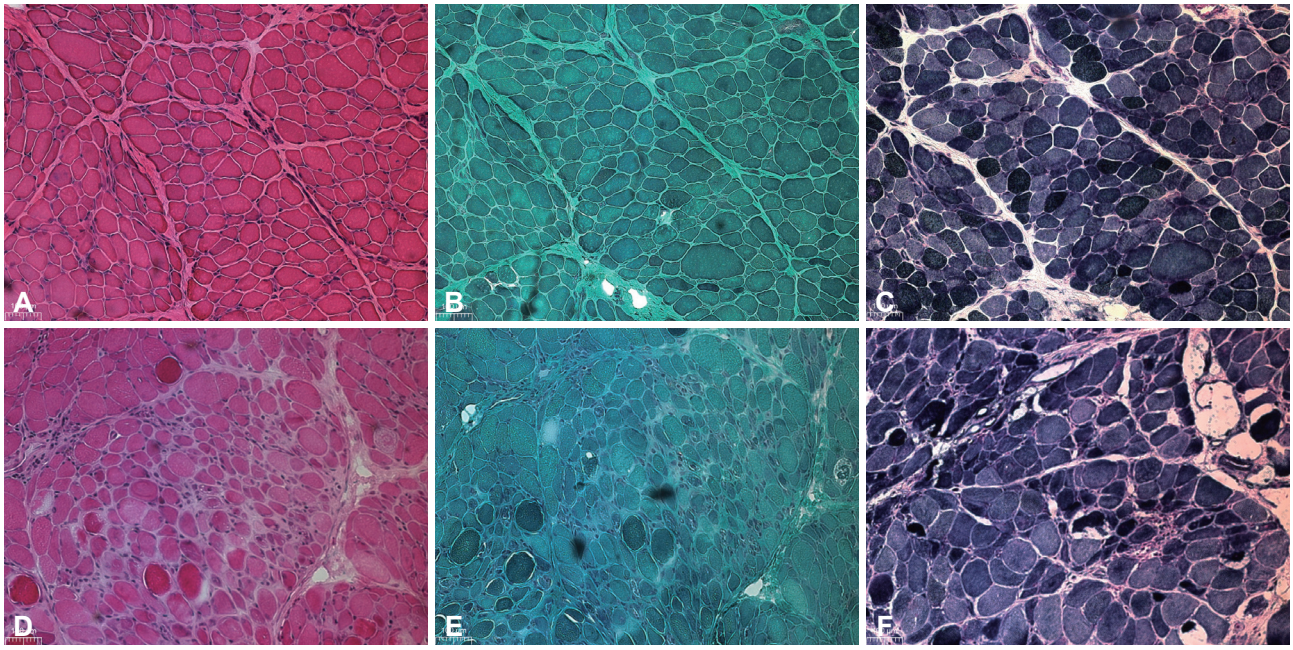

Fig. 2. Pathology of muscle fibers in patients with anti-HMGCR myopathy in patients P7 (A-C) and P6 (D-E). A-F: There were still myopathic changes in patient P7, but endomysial fibrosis was more prominent (A, H&E stain; B, modified GT). Intermyofibrillar network disorganization was only subtle for staining with NADH-TR (C). Variable muscle fiber sizes with degenerating and regenerating changes were present in patient P6 (D, H&E). There was no accumulation of nemaline rods, mitochondria (ragged red fibers), or vacuoles (E, GT). There was marked disorganization of intermyofibrillar networks (F, NADH-TR). Magnification: ×200. GT, Gomori trichrome; H&E, hematoxylin and eosin; HMGCR, anti-3-hydroxy-3-methylglutaryl-coenxyme A reductase; NADH-TR, nicotinamide adenine dinucleotide–tetrazolium reductase.

ti-HMGCR antibodies of these patients were compared between before and after treatment. The mRS score was significantly lower after treatment (median=1, interquartile range=0−2 vs. median=3, interquartile range=2−3; p=0.026) (Fig. 3A). The posttreatment anti-HMGCR antibody titer was also significantly lower after treatment (median=161, interquartile range=79−184 vs. median=232, interquartile range=202−252; p=0.018) (Fig. 3B). These changes were observed in both statin-exposed (P2, P3, P4, and P5) and statin-naïve (P1, P7, and P10) patients (Fig. 3).

Histological examinations

Necrotic and regenerative fibers were observed using microscopy in all cases. The number of degenerative muscle fibers varied. Rare necrotic fibers with increased endomysial fibrosis were observed in patient P7 (Fig. 2A-C), and patient P6 had many necrotic and regenerating fibers (Fig. 2D and E) with and without some inflammatory cell infiltrations. Few inflammatory cell infiltrates were observed in two patients (P8 and P14).

Lower-limb magnetic resonance imaging

T1-weighted MRI scans of lower-limb muscles indicated predominant fatty replacements in the thigh muscles, especially in the gluteus maximus, adductor magnus, adductor brevis, semimembranosus, long head of the biceps femoris, and semitendinosus muscles (Fig. 4). Those fatty replacements were not related to age at symptom onset or disease severity, but they were correlated with the duration between symptom onset and diagnosis. Severe fat replacement was observed in two patients (P7 and P16) in whom treatment was initiated 100 months after symptom onset (Figs. 4 and 5A-H). Obvious asymmetric fatty replacement was only observed in patient P5 (Fig. 4). STIR signal increases were patchy and asymmetric in all patients (Fig. 5I-P).

DISCUSSION

This study measured anti-HMGCR antibodies in 198 Korean subjects: 99 patients with inflammatory myopathy, 36 patients with genetic myopathy, and 63 healthy subjects. We found that 17 of 99 (17%) patients with inflammatory myopathy were positive for anti-HMGCR antibodies.

We confirmed that the clinical features of Korean patients with anti-HMGCR myopathy included subacute progressive proximal muscle weakness and greatly elevated serum CK levels. As in previous reports, the patients were predominantly female.[1,16-18] One patient (6%) had cancer. This was also consistent with previous studies, in which patients with anti-HMGCR myopathy demonstrated an increased risk of cancer, but this risk was not as substantial as with other inflammatory myopathies, especially dermatomyositis.[19,20] Two patients presented slowly progressing limb-girdle muscle weakness, which was also found in previous studies.[21,22] This suggests that the anti-HMGCR antibody test is necessary not only for patients with inflammatory myopathies but also for those with muscular dystrophy. Statin-naïve patients with anti-HMGCR myopathy accounted for 41% of the sample. This was consistent with the proportions of statin-naïve patients found in previous studies (15%−63%).[4,16,17,23,24] The anti-HMCR antibody titer was significantly associated with the serum CK level in Korean patients, which was consistent with previous results.[25,26]

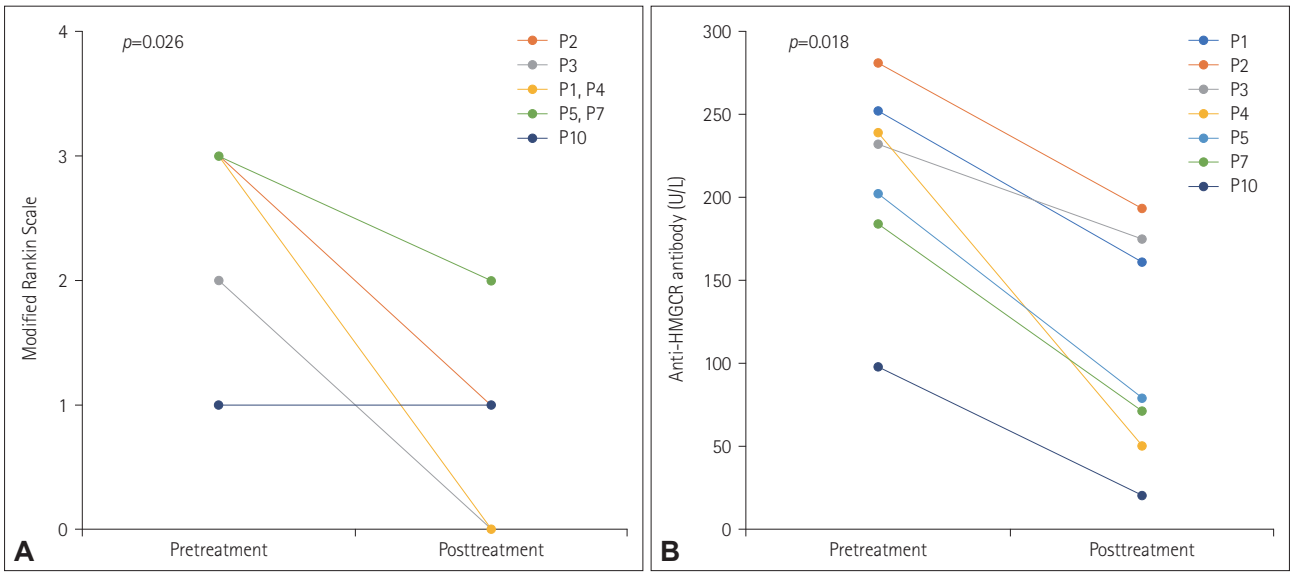

Fig. 3. Treatment effects in seven patients (P1, P2, P3, P4, P5, P7, and P10). A and B: Serial changes in the modified Rankin Scale score (A) and titer of anti-HMGCR antibody (B) between pre- and posttreatment. HMGCR, anti-3-hydroxy-3-methylglutaryl-coenxyme A reductase.

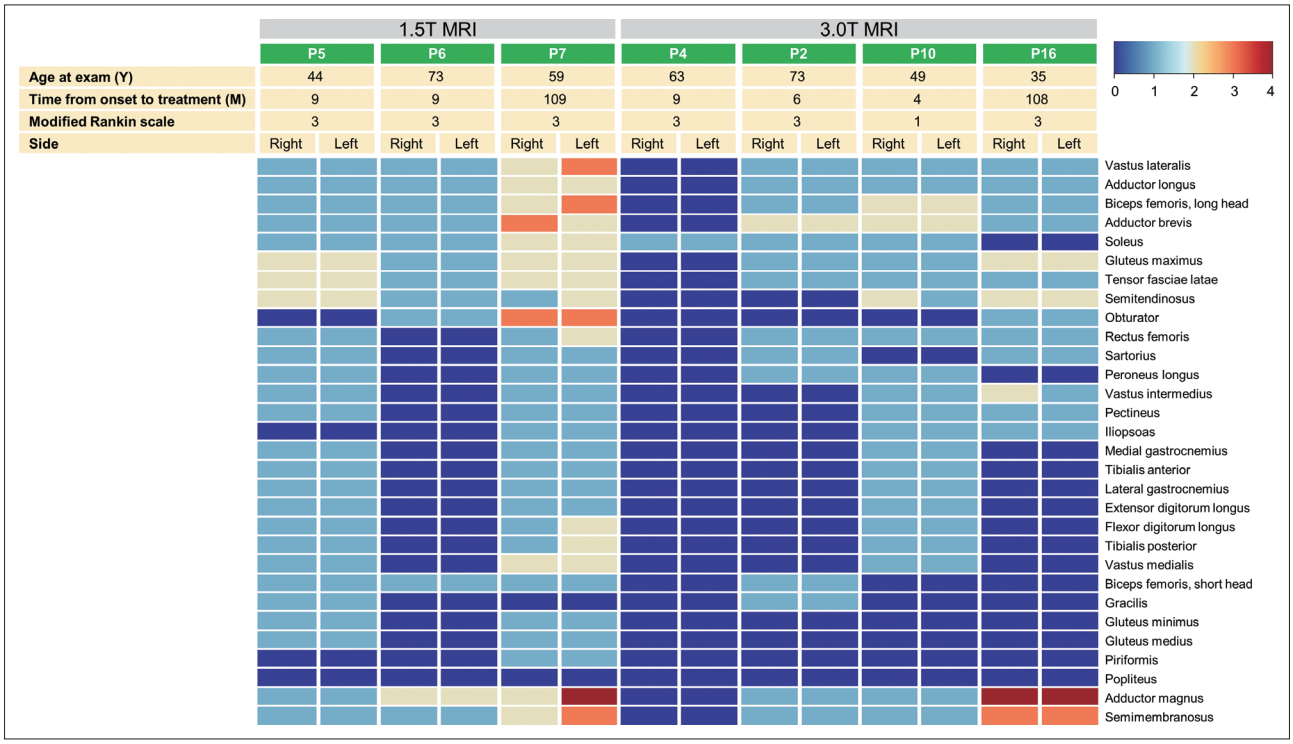

Fig. 4. Distribution of fatty replacement observed in T1-weighted images in the lower-limb muscles of patients with anti-HMGCR myopathy. The heatmap presents the Mercuri scale scores of the studied lower-limb muscles: grade 0, normal appearance; grade 1, traces of increased signal intensity; grade 2, increased signal intensity with confluence in less than 50% of the muscle; grade 3, increased signal intensity in more than 50% of the muscle; and grade 4, increased signal intensity over the entire muscle. HMGCR, 3-hydroxy-3-methylglutaryl-coenxyme A reductase; MRI, magnetic resonance imaging.

Our study produced three unique clinical findings in Korean patients with anti-HMGCR myopathy. First, half of the patients had various MSAs, most commonly anti-Ro52 antibodies. The MSA-positive group was older and their disease progressed faster than in the MSA-negative group. Two previous studies found that patients with anti-HMGCR myopathy had few or no other MSAs.[6,27] However, those studies included few patients with anti-HMGCR myopathy (n=6 and n=11).[6,27] One of those studies used a line-blot assay, while the method was not specified for the other. Second, the titer of anti-HMGCR antibody was significantly higher in statin-naïve than in statin-exposed patients. This finding was the opposite of that in a previous study.[28] The reason for this finding remains unclear. However, differences in the titer of anti-HMGCR antibody may be due to age differences rather than the statin exposure status. One large-scale study demonstrated that a lower age predicted more-severe disease regardless of the statin exposure status, and that muscle strength was inversely associated with the titer of anti-HMGCR antibody.[26] Although the difference was not significant in our study, statin-naïve patients tended to be younger. Third, the level of anti-HMGCR antibody was significantly lower at posttreatment than at pretreatment in both statin-exposed and -naïve patients. However, a previous study only found decreased anti-HMGCR antibodies after immunotherapy in statin-exposed patients.[25] These results were insufficient to suggest a definite clinical relevance because of the small sample and inconsistency with previous results, highlighting the need for further large-scale studies.

Necrotic and regenerative fibers with minimal inflammatory cell infiltrates were found in all patients. These findings were consistent with the pathological findings of previous studies.[17,29,30] Lower-limb MRI indicated fatty replacement in the hamstrings and adductors with patchy and asymmetric edema. Severe fatty replacement was only found in patients who received immunotherapy after a long delay. These radiological findings were compatible with previous results.[21,30]

Our study had several limitations. The main one was its retrospective nature based on medical records. Second, the sample was too small to characterize the clinical presentation of Korean patients with anti-HMGCR myopathy. Further prospective studies are therefore needed to confirm our results. Third, we could not confirm the results of line-blot immunoassay for 16 MSAs using the ELISA or cell-based assay. The line-blot assay obtains false-positive results about 13% of the time, and so further testing is needed.[31]

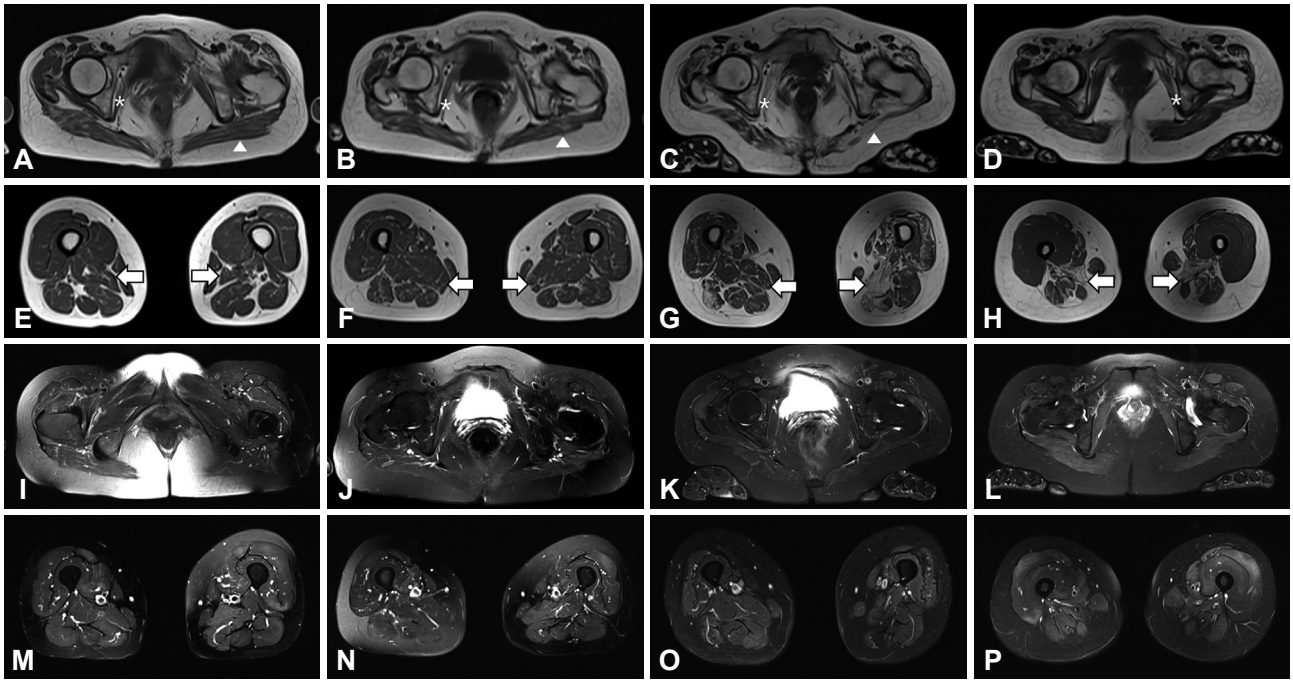

Fig. 5. Lower-limb muscle MRI of two patients with anti-HMGCR myopathy: patients P7 (A-C, E-G, I-K, and M-O) and P16 (D, H, L, and P). A-P: Two patients were misdiagnosed as having muscular dystrophy due to slowly progressing muscle weakness and did not receive appropriate treatment for nearly 9 years after symptom onset. MRI was performed at 40 months (A, E, I, and M), 54 months (B, F, J, and N), and 109 months (C, G, K, and O) after symptom onset in patient P7 (A-C). At the hip level, T1-weighted images indicated predominant fatty replacement of the obturator (asterisk, A-D) and gluteus maximus (arrowhead, A-C) muscles over time. At the thigh level, T1-weighted images indicated asymmetric fatty replacement of adductors (arrows, E-G), long head of the biceps femoris, and semimembranosus muscles over time. T1-weighted images also presented predominant fatty replacement of adductors in P16 (arrows, H). Short tau inversion recovery signal increases were patchy and asymmetric (I-P). MRI, magnetic resonance imaging.

In summary, Korean patients with anti-HMGCR myopathy had subacute, progressive, proximal muscle weakness, and highly elevated serum CK levels. This study has also revealed unique clinical findings in Korean patients: the frequent coexistence of other MSAs, high titer of anti-HMGCR antibodies in statin-naïve patients, and decreased anti-HMGCR antibodies after immunotherapy in both statin-exposed and -naïve groups.

In conclusion, this study was the first to measure anti-HMGCR antibodies in Korean patients with inflammatory myopathy and to analyze the clinical, pathological, and radiological features of patients with anti-HMGCR myopathy. We found typical clinical features of anti-HMGCR myopathy and have produced novel findings including the coexistence of other MSAs in Korean patients.

Supplementary Materials

The online-only Data Supplement is available with this article at https://doi.org/10.3988/jcn.2022.0374.

Availability of Data and Material

The datasets analyzed during the current study are available from the corresponding author on reasonable request.

ORCID iDs

Eun Kyoung Oh	https://orcid.org/0000-0002-4661-5209
Seung-Ah Lee	https://orcid.org/0000-0002-0727-638X
Hyun Joon Lee	https://orcid.org/0000-0001-6295-182X
Yoon Jin Cha	https://orcid.org/0000-0002-5967-4064
Sungjun Kim	https://orcid.org/0000-0002-7876-7901
Hyung-Soo Lee	https://orcid.org/0000-0001-6810-9369
Bum Chun Suh	https://orcid.org/0000-0002-3947-5615
Ha Young Shin	https://orcid.org/0000-0002-4408-8265
Seung Woo Kim	https://orcid.org/0000-0002-5621-0811
Byeol-A Yoon	https://orcid.org/0000-0002-4350-3551
Seong-il Oh	https://orcid.org/0000-0002-8067-2135
Yoo Hwan Kim	https://orcid.org/0000-0002-9532-5769
Joong-Yang Cho	https://orcid.org/0000-0002-5916-3846
Jeong Hee Cho	https://orcid.org/0000-0003-2190-2292
Ki-Han Kwon	https://orcid.org/0000-0001-6399-2236
Young-Chul Choi	https://orcid.org/0000-0001-5525-6861
Hyung Jun Park	https://orcid.org/0000-0003-4165-8901

Author Contributions

Conceptualization: Young-Chul Choi, Hyung Jun Park. Data curation: Hyun Joon Lee, Yoon Jin Cha, Sungjun Kim, Hyung-Soo Lee, Bum Chun Suh, Ha Young Shin, Seung Woo Kim, Byeol-A Yoon, Seong-il Oh, Yoo Hwan Kim, Joong-Yang Cho, Jeong Hee Cho, Ki-Han Kwon, Young-Chul Choi. Formal analysis: Eun Kyoung Oh, Seung-Ah Lee, Hyun Joon Lee, Yoon Jin Cha, Sungjun Kim, Bum Chun Suh, Hyung Jun Park. Writing—original draft: Eun Kyoung Oh, Seung-Ah Lee, Hyung Jun Park. Writing—review & editing: Young-Chul Choi.

Conflicts of Interest

The authors have no potential conflicts of interest to disclose.

Funding Statement

The authors would like to thank the patients for their help with this work. This research was supported by the Basic Science Research Program through the National Research Foundation of Korea (NRF) funded by the Ministry of Education (grand number: 2020R1I1A1A01068066).

REFERENCES

1. Christopher-Stine L, Casciola-Rosen LA, Hong G, Chung T, Corse AM, Mammen AL. A novel autoantibody recognizing 200-kd and 100-kd proteins is associated with an immune-mediated necrotizing myopathy. *Arthritis Rheum* 2010;62:2757-2766.
2. Targoff IN, Johnson AE, Miller FW. Antibody to signal recognition particle in polymyositis. *Arthritis Rheum* 1990;33:1361-1370.
3. van der Most PJ, Dolga AM, Nijholt IM, Luiten PG, Eisel UL. Statins: mechanisms of neuroprotection. *Prog Neurobiol* 2009;88:64-75.
4. Mammen AL, Chung T, Christopher-Stine L, Rosen P, Rosen A, Doering KR, et al. Autoantibodies against 3-hydroxy-3-methylglutaryl-coenzyme A reductase in patients with statin-associated autoimmune myopathy. *Arthritis Rheum* 2011;63:713-721.
5. Limaye V, Bundell C, Hollingsworth P, Rojana-Udomsart A, Mastaglia F, Blumbergs P, et al. Clinical and genetic associations of autoantibodies to 3-hydroxy-3-methyl-glutaryl-coenzyme a reductase in patients with immune-mediated myositis and necrotizing myopathy. *Muscle Nerve* 2015;52:196-203.
6. Klein M, Mann H, Pleštilová L, Zámečník J, Betteridge Z, McHugh N, et al. Increasing incidence of immune-mediated necrotizing myopathy: single-centre experience. *Rheumatology (Oxford)* 2015;54:2010-2014.
7. Watanabe Y, Uruha A, Suzuki S, Nakahara J, Hamanaka K, Takayama K, et al. Clinical features and prognosis in anti-SRP and anti-HMGCR necrotising myopathy. *J Neurol Neurosurg Psychiatry* 2016;87:1038-1044.
8. Mammen AL. Statin-associated autoimmune myopathy. *N Engl J Med* 2016;374:664-669.
9. Lee J, Kim E, Kim N, Park HJ, Kim YH. Statin-induced immune-mediated necrotizing myopathy with anti-HMGCR antibody. *Korean J Neuromuscul Disord* 2021;13:64-66.
10. Yung Y, Kim BY, Oh K, Cho JY. Statin-naïve paraneoplastic anti-HMGCR myopathy. *Korean J Neuromuscul Disord* 2021;13:15-19.
11. Rankin J. Cerebral vascular accidents in patients over the age of 60. II. Prognosis. *Scott Med J* 1957;2:200-215.
12. Lundberg IE, Tjärnlund A, Bottai M, Werth VP, Pilkington C, Visser M, et al. 2017 European League Against Rheumatism/American College of Rheumatology classification criteria for adult and juvenile idiopathic inflammatory myopathies and their major subgroups. *Ann Rheum Dis* 2017;76:1955-1964.
13. Musset L, Miyara M, Benveniste O, Charuel JL, Shikhman A, Boyer O, et al. Analysis of autoantibodies to 3-hydroxy-3-methylglutaryl-coenzyme A reductase using different technologies. *J Immunol Res* 2014;2014:405956.
14. Fischer D, Clemen CS, Olivé M, Ferrer I, Goudeau B, Roth U, et al. Different early pathogenesis in myotilinopathy compared to primary desminopathy. *Neuromuscul Disord* 2006;16:361-367.
15. Jungbluth H, Davis MR, Müller C, Counsell S, Allsop J, Chattopadhyay A, et al. Magnetic resonance imaging of muscle in congenital myopathies associated with RYR1 mutations. *Neuromuscul Disord* 2004;14:785-790.
16. Allenbach Y, Drouot L, Rigolet A, Charuel JL, Jouen F, Romero NB, et al. Anti-HMGCR autoantibodies in European patients with autoimmune necrotizing myopathies: inconstant exposure to statin. *Medicine (Baltimore)* 2014;93:150-157.
17. Watanabe Y, Suzuki S, Nishimura H, Murata KY, Kurashige T, Ikawa M, et al. Statins and myotoxic effects associated with anti-3-hydroxy-3-methylglutaryl-coenzyme A reductase autoantibodies: an observational study in Japan. *Medicine (Baltimore)* 2015;94:e416.
18. Alshehri A, Choksi R, Bucelli R, Pestronk A. Myopathy with anti-HMGCR antibodies: perimysium and myofiber pathology. *Neurol Neuroimmunol Neuroinflamm* 2015;2:e214.
19. Kadoya M, Hida A, Hashimoto Maeda M, Taira K, Ikenaga C, Uchio N, et al. Cancer association as a risk factor for anti-HMGCR antibody-positive myopathy. *Neurol Neuroimmunol Neuroinflamm* 2016;3:e290.
20. Allenbach Y, Keraen J, Bouvier AM, Jooste V, Champtiaux N, Hervier B, et al. High risk of cancer in autoimmune necrotizing myopathies: usefulness of myositis specific antibody. *Brain* 2016;139(Pt 8):2131-2135.
21. Mohassel P, Landon-Cardinal O, Foley AR, Donkervoort S, Pak KS, Wahl C, et al. Anti-HMGCR myopathy may resemble limb-girdle muscular dystrophy. *Neurol Neuroimmunol Neuroinflamm* 2019;6:e523.
22. Idiculla PS, Govindarajan R. Anti-HMGCR myopathy mimicking limb-girdle muscular dystrophy and the response to Rituximab. *Clin Neurol Neurosurg* 2020;194:105871.
23. Drouot L, Allenbach Y, Jouen F, Charuel JL, Martinet J, Meyer A, et al. Exploring necrotizing autoimmune myopathies with a novel immunoassay for anti-3-hydroxy-3-methyl-glutaryl-CoA reductase autoantibodies. *Arthritis Res Ther* 2014;16:R39.
24. Szczesny P, Barsotti S, Nennesmo I, Danielsson O, Dastmalchi M. Screening for anti-HMGCR antibodies in a large single myositis center reveals infrequent exposure to statins and diversiform presentation of the disease. *Front Immunol* 2022;13:866701.
25. Werner JL, Christopher-Stine L, Ghazarian SR, Pak KS, Kus JE, Daya NR, et al. Antibody levels correlate with creatine kinase levels and strength in anti-3-hydroxy-3-methylglutaryl-coenzyme A reductase-associated autoimmune myopathy. *Arthritis Rheum* 2012;64:4087-4093.
26. Tiniakou E, Pinal-Fernandez I, Lloyd TE, Albayda J, Paik J, Werner JL, et al. More severe disease and slower recovery in younger patients with anti-3-hydroxy-3-methylglutaryl-coenzyme A reductase-associated autoimmune myopathy. *Rheumatology (Oxford)* 2017;56:787-794.
27. Ramanathan S, Langguth D, Hardy TA, Garg N, Bundell C, Rojana-Udomsart A, et al. Clinical course and treatment of anti-HMGCR antibody-associated necrotizing autoimmune myopathy. *Neurol Neuroimmunol Neuroinflamm* 2015;2:e96.
28. Musset L, Allenbach Y, Benveniste O, Boyer O, Bossuyt X, Bentow C, et al. Anti-HMGCR antibodies as a biomarker for immune-mediated necrotizing myopathies: a history of statins and experience from a large international multi-center study. *Autoimmun Rev* 2016;15:983-993.
29. Ashton C, Junckerstorff R, Bundell C, Hollingsworth P, Needham M. Treatment and outcomes in necrotising autoimmune myopathy: an Australian perspective. *Neuromuscul Disord* 2016;26:734-740.
30. Liang WC, Uruha A, Suzuki S, Murakami N, Takeshita E, Chen WZ, et al. Pediatric necrotizing myopathy associated with anti-3-hydroxy-3-methylglutaryl-coenzyme A reductase antibodies. *Rheumatology (Oxford)* 2017;56:287-293.
31. Tansley SL, Li D, Betteridge ZE, McHugh NJ. The reliability of immunoassays to detect autoantibodies in patients with myositis is dependent on autoantibody specificity. *Rheumatology (Oxford)* 2020;59:2109-2114.