Received: 3 October 2023 | Accepted: 21 October 2023
DOI: 10.1111/srt.13517

RESEARCH LETTER

WILEY

Ultrasonographic observations of the paradoxical mentalis bulging in regard to botulinum neurotoxin injection for mentalis muscle

Dear Editor

Botulinum neurotoxin (BoNT) is administered into the mentalis muscle to alleviate or forestall the development of a cobblestone chin. Nevertheless, there has been inadequate elucidation of the anatomical factors related to this technique, even though there is potential for undesirable repercussions. The process of pinpointing the mentalis muscle with BoNT can lead to issues like uneven drooping of the lower lip and impaired mouth opening as well as paradoxical mentalis bulging, which can have significant implications for patients.[1–3]

The dispersion of BoNT generally doesn't frequently impact adjacent muscles like the orbicularis oris and depressor labii inferioris muscles. Nevertheless, injecting BoNT into the upper and lateral parts of the mentalis muscle, while effective on the chin, could potentially influence muscles such as the orbicularis oculi and depressor labii inferioris. The spread of BoNT to these muscles could result in uneven alterations in lower facial expressions. Hence, the diffusion of BoNT should be approached cautiously when performing injection procedures. Additionally, inadequate spread of the BoNT within the mentalis muscle can also result in adverse effects. It's not uncommon to observe instances where the mentalis muscle becomes more prominently hyperactivated following the administration of BoNT.

Yu et al. documented a case where a patient underwent BoNT injection into the mentalis muscle, resulting in unexpected swelling.[4] The researchers suggest that complete penetration of the muscle thickness by BoNT injection could lead to this unusual swelling.[4] In situations of pronounced mentalis muscle overactivity, an injection strategy based on anatomical considerations is necessary to avert lopsided paralysis and the development of paradoxical mentalis bulging.[4] The occurrence of paradoxical mentalis bulging arises from uneven distribution of BoNT during injection.[4]

From June 2021 to April 2023, among 120 patients who received BoNT injections in the mentalis muscle, one individual experienced paradoxical mentalis bulging, and an ultrasound examination was conducted on this patient. This patient, a 26-year-old female, received a total of 8 units of BoNT according to Yi's guidelines and presented with side effects, necessitating a follow-up visit 3 days after the injection. Upon reviewing the patient's history, it was discovered that she had received approximately 2 cc of hyaluronic filler in the mentalis muscle about 2 years prior (Figure 1A). While visually assessing the photographs, it was observed that the previously bumpy "cobblestone" contour had diminished, but a rounded shape could be seen when she moved her lips (Figure 1B). Ultrasound examination revealed the absence of movement in the superficial belly and the presence of hypercontraction in the deep belly. Furthermore, non-active hyaluronic acid filler granulomas have been observed situated between these two muscle bellies (Figure 2). In this case, relief was achieved after additional deep injections with 4 units of BoNT.

Anatomically, when a superficial injection is performed, excessive activity in the deep belly seems to be emphasized. Particularly, in cases where fillers have been used, it is suspected that preventing the spreading of the mentalis muscle as a result of the filler might be considered.[5] Typically, fillers are placed in the space between the left and right bellies of the mentalis muscle, and their introduction can elongate the length of the chin, thereby inhibiting the diffusion of BoNT (Figure 3).

Yi et al. established a protocol for injecting toxin into the mentalis muscle, diluting it with 2.5 mL of normal saline to achieve a concentration of 4 U/0.1 mL.[1] Using larger dilution volumes is linked to enhanced diffusion into the surrounding tissue. In their approach, a deep injection of 3 U per side is administered at each point situated 0.5 cm lateral to the pogonion. Additionally, a superficial injection of 1 U per side is performed at the same injection site. When injecting BoNT on the upper and lateral areas, potential effects on the orbicularis oris and depressor labii inferioris muscles should be considered, as this might lead to uneven changes in the expression of the lower lip or result in mouth dysfunction along with lower lip drooping. It is advised to choose intramuscular or subdermal injections based on the desired depth of injection.

The mentalis muscle encompasses a deep muscle belly, and the space between the periosteum and mentalis muscle measures 1.1 mm. Once the needle touches the mandibular bone, a slight retraction is recommended prior to injecting 3 U of BoNT for deep injection. Following the deep injection and needle retraction, an additional subdermal injection of 1 U is suggested.

In their research, Quezada-Gaón and colleagues[6] employed ultrasonography to guide the injection of hyaluronidase, which they deemed an efficacious approach for substantially diminishing the size of

Kyu-Ho Yi and Soo-Bin Kim contributed equally as first authors.

FIGURE 1 A patient's photograph before the procedure with no muscle contraction (A), followed by an image taken after the administration of botulinum neurotoxin injection after 2 days with mentalis muscle contraction, demonstrating paradoxical mentalis bulging (B).

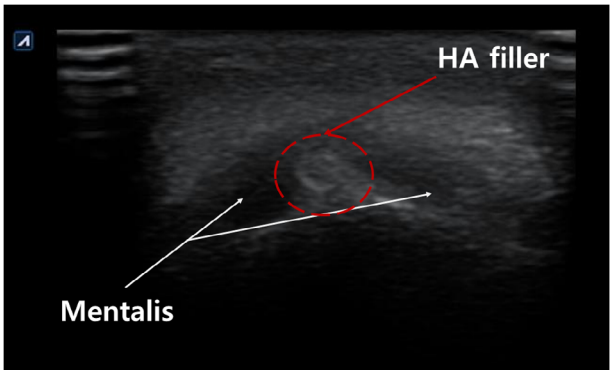

FIGURE 2 The ultrasonographic observation of the paradoxical masseteric bulging. Hypercontraction of the deep part of the mentalis muscle tends to contract more strongly when the botulinum neurotoxin has not been adequately dispersed. Additionally, inactive granulomas of the hyaluronic acid filler were observed between both sides of the muscle belly.

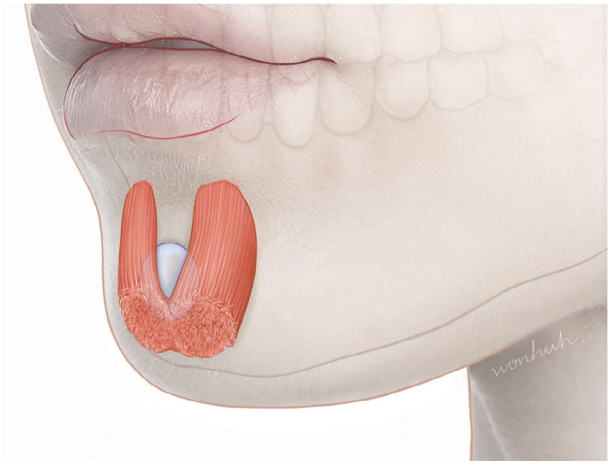

FIGURE 3 Schematic image of the mentalis muscle with chin augmentation using hyaluronic acid filler.

nodules resulting from hyaluronic acid injections. Ultrasound serves as a non-invasive and valuable instrument for pinpointing the precise sites of cosmetic filler placements, ensuring a secure process and facilitating treatment monitoring. The encapsulation of hyaluronic acid fillers by non-inflammatory cells, referred to as non-inflammatory granuloma, can lead to prolonged effects.[7,8] The presence of fillers in mobile areas around anatomical structures complicates the challenge of achieving precise targeting and dissolution. Despite claims of successful filler dissolution, instances where fillers persist without dissolving are fairly common. Moreover, allergic reactions are a common side effect associated with the use of hyaluronidase. Typically, these allergic reactions to hyaluronidase are localized, although systemic reactions may occur in rare cases. As most allergic responses to hyaluronidase present as immediate hypersensitivity reactions, it is advisable to administer the smallest possible amount.[9,10] here is a threshold for allergic reactions, representing the minimum amount required to trigger such a response. Consequently, administering a minimal injection may prevent allergic reactions from occurring.[11] In this instance, we did not utilize hyaluronidase for the dissolution of the hyaluronic acid filler; nevertheless, the subsequent course of action would involve dissolving the hyaluronic acid filler through an ultrasonography-guided injection.

In summary, when performing filler injections for the purpose of achieving mental elongation, it is plausible that some parts of the muscle itself may undergo elongation. However, the administration of BoNT might pose a hurdle in paralyzing the deep belly of the mentalis muscle. Therefore, in the case of the mentalis muscle, it is imperative to opt for deep injection to prevent potential side effects.

Furthermore, the recent ultrasound examination underscores the significance of ensuring adequate delivery of BoNT to the deep belly for cases involving chin filler augmentation. This insight emphasizes the importance of precise injection to achieve effective results.

ACKNOWLEDGMENTS

This study was conducted in compliance with the principles set forth in the Declaration of Helsinki. Consent was received from the families of the deceased patients before beginning the dissections. There is no financial disclosure to report. This study was supported by the Yonsei University College of Dentistry Fund (No. 6-2023-0002).

CONFLICT OF INTEREST STATEMENT

I acknowledge that I have considered the conflict of interest statement included in the "Author Guidelines." I hereby certify that, to the best of my knowledge, that no aspect of my current personal or professional

situation might reasonably be expected to significantly affect my views on the subject I am presenting.

DATA AVAILABILITY STATEMENT

The data that support the findings of this study are available from the corresponding author upon reasonable request.

Kyu-Ho Yi[1,2]
Soo-Bin Kim[2]
Hee-Jin Kim[2]

[1]*Maylin Clinic (Apgujeong), Seoul, South Korea*
[2]*Division in Anatomy and Developmental Biology, Department of Oral Biology, Human Identification Research Institute, BK21 FOUR Project, Yonsei University College of Dentistry, Seoul, Republic of Korea*

Correspondence
Hee-Jin Kim, Division in Anatomy & Developmental Biology, Department of Oral Biology, Yonsei University College of Dentistry, 50–1 Yonsei-ro, Seodaemun-gu, Seoul 03722, Republic of Korea.
Email: hjk776@yuhs.ac

REFERENCES

1. Yi KH, Lee JH, Hu HW, et al. Novel anatomical guidelines for botulinum neurotoxin injection in the mentalis muscle: a review. *Anat Cell Biol*. 2023;56(3):293-298.
2. Le Louarn C. Botulinum toxin A and facial lines: the variable concentration. *Aesthetic Plast Surg*. 2001;25(2):73-84.
3. Klein AW. Contraindications and complications with the use of botulinum toxin. *Clin Dermatol*. 2004;22(1):66-75.
4. Yu N, Liu Y, Chen C, Dong R, Yang E, Wang X. Paradoxical bulging of mentalis after botulinum toxin type A injection. *J Cosmet Dermatol*. 2020;19(6):1290-1293.
5. Jabbour S, Kechichian E, Awaida C, Nasr M. Updates in the Treatment of the lower face and neck with botulinum toxin injections. *Aesthet Surg J*. 2019;39(4):NP93-NP94.
6. Quezada-Gaon N, Wortsman X. Ultrasound-guided hyaluronidase injection in cosmetic complications. *J Eur Acad Dermatol Venereol*. 2016;30(10):e39-e40.
7. Trinh LN, McGuigan KC, Gupta A. Delayed granulomas as a complication secondary to lip augmentation with dermal fillers: a systematic review. *Surg J (N Y)*. 2022;8(1):e69-e79.
8. Shah KK, Pritt BS, Alexander MP. Histopathologic review of granulomatous inflammation. *J Clin Tuberc Other Mycobact Dis*. 2017;7:1-12.
9. Jung H. Hyaluronidase: an overview of its properties, applications, and side effects. *Arch Plast Surg*. 2020;47(4):297-300.
10. Guliyeva G, Huayllani MT, Kraft C, Lehrman C, Kraft MT. Allergic complications of hyaluronidase injection: risk factors, treatment strategies, and recommendations for management. *Aesthetic Plast Surg*. 2023 May 5. Online ahead of print. doi:10.1007/s00266-023-03348-5
11. Fierro V, Marzano V, Monaci L, et al. Threshold of reactivity and tolerance to precautionary allergen-labelled biscuits of baked milk- and egg-allergic children. *Nutrients*. 2021;13(12):4540.