Multi-variable analysis for recurrent risk of odontogenic keratocyst

ARi Lee

The Graduate School

Yonsei University

Department of Dentistry

Multi-variable analysis for recurrent risk of odontogenic keratocyst

Directed by Professor Chena Lee, D.D.S., Ph.D.

The Doctoral Dissertation submitted to the Department of Dentistry, and the Graduate School of Yonsei University in partial fulfillment of the requirements for the degree of Doctor of Philosophy in Dental Science

ARi Lee

February 2023

This certifies that the Doctoral Dissertation of
A Ri Lee is approved.

Thesis Supervisor: **Prof. Sang-Sun Han**

Thesis Committee Member: **Prof. Kug-Jin Jeon**

Thesis Committee Member: **Prof. Chena Lee**

Thesis Committee Member: **Prof. Yoon Joo Choi**

Thesis Committee Member: **Prof. Hak-Sun Kim**

The Graduate School
Yonsei University
February 2023

감사의 글

학위 논문의 감사의 글을 작성하는 날이 저에게도 찾아올지 몰랐습니다. 길다면 긴 4 년의 학위 과정 동안 한계에 부딪혀 좌절하는 순간도 있었지만, 행복한 순간이 더 많았던 것 같습니다. 행복한 대학원 생활을 할 수 있도록 함께해주신 분들께 이 글을 통해 감사한 마음을 조금이라도 전하고자 합니다.

먼저, 천천히 성장하는 저를 믿어주시고 늘 언제나 아낌없는 칭찬으로 용기를 북돋아 주신 이채나 교수님께 무한한 감사 인사를 드립니다. 학문과 연구뿐만 아니라 인생의 스승으로서 넘어지면 일어나는 방법도 배울 수 있었던 것 같습니다. 교수님께서 주신 가르침 잊지 않고 부끄럽지 않은 제자가 되겠습니다. 끊임 없는 관심과 애정으로 격려 해주신 한상선 교수님. 아무것도 모르던 저를 뽑아 주시고, 저에게 가장 좋은 길이 무엇인지 끊임없이 생각해주셔서 감사합니다. 만나 뵐 때마다 연구원들의 안부와 걱정을 해주시는 따듯한 전국진 교수님, 바쁘신 와중에도 부족한 저의 논문을 통찰력 있는 피드백과 질문으로 논문의 완성도를 올려주신 최윤주 교수님, 해낼 수 없다고 생각할 때 할 수 있다는 응원과 관심 보내주신 김학선 교수님. 학위 과정 동안 교수님들 덕분에 성장 할 수 있었던 것 같습니다. 감사드립니다.

연구실 생활 중 좌절할 때마다 지혜로운 조언과 함께 막히는 연구 고민까지 함께 해주셨던 영현 선생님. 선생님 덕분에 무사히 졸업할 수 있었습니다. 수 많은 질문에 하나하나 자세히 답변해주며, 연구 고민까지 함께 해준 따뜻한 은규샘, 동생이지만 배울 점 많고 속 깊은 한승샘, 언제나 밝고 긍정적인 기운으로 연구실을 환하게 해준 휘샘. 모든 것이 낯설고 어려울 때 작은 것 하나까지 도와주며 함께해준 그리운 은주샘. 함께여서 행복했고 보람찬 연구실 생활이었습니다. 모두 감사드립니다.

어떤 도전에도 무한한 신뢰와 지원으로 든든하게 곁을 지켜준 존경하는 엄마. 저도 엄마처럼 열심히 최선을 다해 살아가겠습니다. 엄마 딸로 태어나서 행복합니다. 사랑하고 감사드립니다. 그리고 누나 대신 맏이 역할 해주는 든든한 내 동생 철재에게도 고맙다는 말 전하고 싶습니다. 첫째 손녀 걱정에 매일 기도해주시는 할머니. 늘 감사드리고 앞으론 제 용돈 받으시며 오래오래 사세요! 그리고 최근 들어 문득문득 생각나는 할아버지, 너무 그립고 보고싶습니다. 무뚝뚝한 조카에게 늘 언제나 베풀어주는 고마운 정희이모, 이모부, 가빈이, 학위과정 중 만나는 것만으로도 힐링 메이트가 되어주었던 아낌없이 주는 나무 경희언니, 정아, 연락 없는 친구에게 먼저 연락해주고 자랑스럽다고 말 해주는 고마운 친구 미정, 소현, 승연 모두 고마워!! 너희가 주는 믿음과 관심 덕분에 앞으로 더 나아갈 수 있었어.

마지막으로 저를 도와주시고 응원해주신 미처 언급하지 못한 모든 분들께 감사의 인사 드립니다. 저에겐 대학원 생활은 행복하고 즐거웠던 선물이었고, 좋은 분들과 함께 하는 것은 참 행복한 일임을 깨닫는 시간이었습니다. 앞으로 배움을 잊지 않고, 받은 것을 나누는 사람이 되겠습니다.

2022 12 월 저자 씀.

TABLE OF CONTENTS

LIST OF TABLES

LIST OF FIGURES

Abstract

Multi-variable analysis for recurrent risk of odontogenic keratocyst

ARi Lee

Department of Dentistry
The Graduate School, Yonsei University

(Directed by Professor Chena Lee, D.D.S., PhD.)

Purpose: The aims of this study was to investigate prognostic factors affecting the recurrence of odontogenic keratocyst (OKC) through clinical and radiologic feature analysis, and to propose the most effective post-operative imaging interval to detect the recurrence of the lesion.

Methods: The patients who were histopathologically diagnosed as OKC (n=506) after the surgery at Yonsei University Dental Hospital were investigated. For the included patients, the 16 clinico-radiologic features (5 clinical features, 11 radiologic features) were analyzed. The clinical features included patient age, sex, pre-surgical imaging modality, clinical preliminary diagnosis and treatment method. Radiologic features were the periphery and shape, internal structure, and influence on surrounding structure of the lesion. The cox proportional hazards model was used to establish prognostic factors of recurrence. The

appropriate follow-up period was determined by comparing the survival rates of recurred and non-recurred lesions based on the Kaplan-Meier curve and the log-rank test.

Results: In total, 267 out of 506 patients were included for this study. The overall recurrence rate was 25.47% with an average follow-up period of 4.36 years. The pre-surgical imaging modality, periphery and shape (size, appearance, location), and internal structure (septa) were identified as the factors related to recurrence in univariable cox regression analysis. When multiple regression was performed, the size and septa were the significant factor for the recurrent. The lesions smaller than the average size showed 1.92 times high recurrence rate over the lesion of larger size than the average. The lesion with septa showed 5.61 times high risk of recurrence compare to the lesion without septa. The recurrence rate was drastically increased during 3 to 7 years after the surgery when septa were present.

Conclusions: In this study, among the clinical features and radiologic features of OKC, the features related to recurrence were identified. Among radiologic features, lesions with septa show a high recurrence rate, and in this case, close follow-up is required between 3 and 7 years after surgery.

Keywords: Odontogenic keratocyst, Recurrence, Prognostic factor, Risk factor, Cox proportional hazards model

Multi-variable analysis for recurrent risk of odontogenic keratocyst

ARi Lee

Department of Dentistry
The Graduate School, Yonsei University

(Directed by Professor Chena Lee, D.D.S., PhD.)

I. INTRODUCTION

Predicting the prognosis of a lesion is used in clinical decision making process such as information-based treatment direction and follow-up planning[1,2]. When predicting the prognosis of these lesions, a risk prediction model that suggests the possibility of recurrence based on established risk factors is being used[3-5]. However, in order for a prediction model to have clinical utility, prognostic factors must be reliable and generalizable. As such, it is very important to establish prognostic factors related to the recurrence of the lesion. However, it is difficult to set up an accurate prognostic factors because there are many factors that cause recurrence, such as age, sex, histologic characteristics, lesion type, and treatment method. In particular, in the case of odontogenic keratocyst (OKC), which has high recurrence among OKC, the etiologic factors of recurrence are still ambiguous, so the

characteristics that can clearly prove the possibility of recurrence have not yet been established.

OKC are account for 10-20% of all odontogenic cysts and are the third common cyst in the head and neck[6,7]. It tends to be aggressive and infiltrating into surrounding tissues, has great growth potential, and has unique histological characteristics. The recurrence rate is reported to vary from 7.4 to 58.3%[8-13], and this wide range is thought to be due to the fact that the study included various follow-up periods, small sample size, surgical methods, and nevoid basal cell carcinoma syndrome (NBCCS). There are several hypotheses about the frequent recurrence of OKC, but the cause that can accurately prove the recurrence is still being debated. Most of the studies were analyzed focusing on treatment methods[14-17]. Recently, as factors related to the recurrence of OKC, clinical factors such as the size and location of the lesion or the presence of dental lamina remnants as well as satellite cysts, which are histopathologically characteristics, have been studied[10,13,18-20]. In some studies, radiological features such as cortical perforation and tooth inclusion within lesion have been studied for the relationship with recurrence, and it has been identified as a prognostic factor of recurrence[13-19]. This may suggest that other radiological features are also associated with recurrence.

OKC have various radiological characteristics on radiologic images[10,21,22]. Radiographically, it is a unilocular lesion, but has septa of internal, shows a scallop or round appearance, grows along the jaw, and appears radiopaque by the keratin present inside[10,21,22]. In addition, some cases show aggressive behavior such as cortical bone perforation and

tooth resorption[22,23]. Imaging is a routinely used non-invasive diagnostic test that can be confirmed prior to treatment and can be obtained more easily than histological examination, so it is being used as useful information for lesion evaluation. However, few studies have established prognostic factors based on detailed radiologic features. Therefore, in this study, clinical factors and various radiologic features were analyzed to identify important factors affecting recurrence of OKC.

Although OKC has a high recurrence rate is known as a lesion requiring long-term follow-up, it is difficult to predict the prognosis at the time of primary diagnosis. If prognostic factors can be identified and high-risk groups with the possibility of recurrence can be identified, an appropriate treatment direction can be established, and recurrence can be detected early through an appropriate follow-up plan. On the other hand, in the low-risk group with a low probability of recurrence, unnecessary procedures can be reduced. Therefore, this study aims to establish recurrence factors that affects the recurrence of OKC through clinical and radiologic factors analysis, and to propose an effective imaging period for recognizing recurrence.

Ⅱ. MATERIALS AND METHODS

This study was approved by the Institutional Review Board (IRB) of Yonsei Dental Hospital (No.2-2022-0056) and performed in accordance with relevant guidelines and ethical regulations. The IRB of Yonsei Dental Hospital granted a waiver of informed consent form due to the retrospective nature of this study.

1. Study population

From January 2005 to December 2019, 506 patients who were histopathologically diagnosed with OKC after post-operative at Yonsei University Dental Hospital were extracted. The exclusion criteria are as follows; i) patients diagnosed with nevoid basal cell carcinoma syndrome (NBCCS) by genetic study, ii) recurrent patient who has been diagnosed with OKC in another hospital and cannot confirm the initial record of the lesion after surgery, iii) patients whose recurrence lesions is not OKC, iv) patients with a follow-up of less than 6 months after treatment. The overall flowchart of the patient selection criteria is shown in Figure 1.

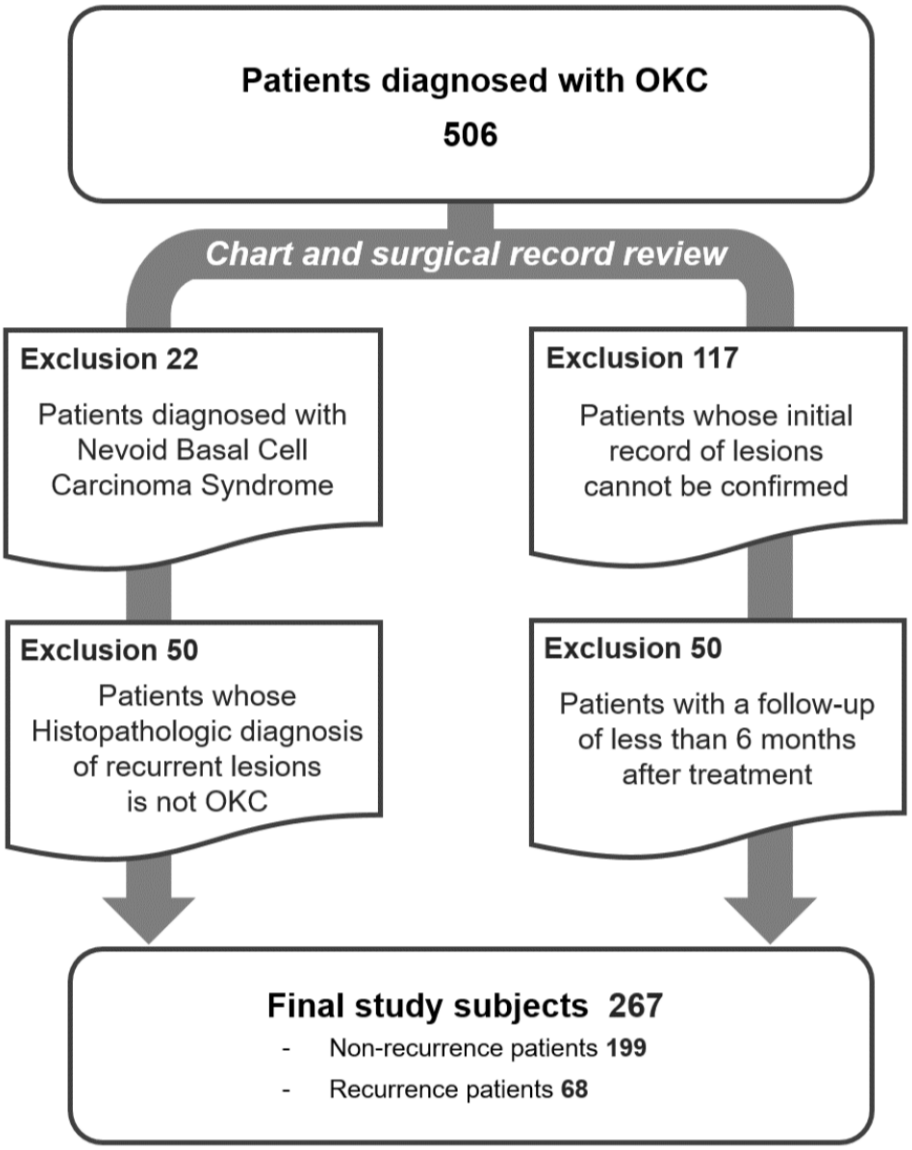

Figure 1. Flowchart of patient selection criteria. *OKC, odontogenic keratocyst*

2. Data collection and analysis

Only patients whose recurrent lesions were histopathologically diagnosed as OKC were included. We retrospectively reviewed the records of 267 patients with continuous follow-up. The recurrence status was divided into recurrence and non-recurrence. For recurrence patients, the recurrence time was defined as the time from completion of initial treatment to recurrence. In case non-recurrence patients, during the follow-up period, the recurrence time was defined until the last hospital visit. In the case of patients who recurrence more than twice, calculation was based on the time of the first recurrence.

2.1 Investigation of clinico-radiologic features

All feasible variables expected to be related with the prognosis were collected and to be used for analysis. Variables were grossly categorized into clinical and radiologic factors. All factors were presented in Table 1.

Table 1. Clinico-radiologic features investigated.

Clinical Features
Clinical information
· Age group (under 10s, 20s, 30s, 40s, 50s, over 60s)
· Sex (Male, Female)
Surgical information
· Pre-surgical imaging (MDCT, CBCT)
· Preliminary clinical diagnosis (Odontogenic keratocysts, Cyst, Tumor)
· Treatment method (Enucleation, Enucleation with decompression, Resection)
Radiologic Features
Periphery and shape
· Size (Small; <average size of overall lesions, Large; ≥average size of overall lesions)
· Appearance (Round, Scallop)
· Location (Ant Mx, Post Mx, Ant-post Mx, Ant Mn, Post Mn, Ant-post Mn)
Internal structure
· Septa (Absence, Presence)
· Keratin-like material (Absence, Presence)
· CT value (HU)
Surrounding structure
· Tooth resorption (Absence, Presence)
· Tooth displacement (Absence, Presence)
· Tooth inclusion within lesion (Absence, Presence)
· Cortical bone expansion (Absence, Presence),
· Cortical bone perforation (Absence, Presence)

MDCT, multidetector computed tomography; CBCT, cone-beam computed tomography; ant, anterior; post, posterior; Mx, maxilla; Mn, mandible

2.1.1 Clinical features

Clinical features were investigated through chart and surgical record review and classified into patient information and surgical information. Patient information included a) age and b) sex. The age groups were divided into under 10s, 20s, 30s, 40s, 50s, and over 60s. Sex group were divided as male and female.

Surgical information was investigated as pre-surgical imaging modality for treatment planning, preliminary clinical diagnosis, and treatment method. For the radiologic examination, the prescription of the three-dimensional (3D) image, a) multidetector computed tomography (MDCT) or b) cone-beam computed tomography (CBCT) taken for the surgical planning was confirmed. The preliminary clinical diagnosis before surgery was classified into a) odontogenic keratocyst, b) cyst, and c) benign tumor. Any type of cyst other than OKC, such as aneurysm bone cyst, dentigerous cyst, periodontal cyst, radicular cyst, residual cyst, and simple bone cyst, were included in the cyst. All tumor, including ameloblastoma, fall into tumor category. The treatment methods were a) enucleation, b) enucleation with decompression, and c) resection.

2.1.2 Radiologic features

The radiologic features were identified in CT images by consensus of 1 radiologist and 1 post-graduate student for the following aspects; periphery and shape, internal structure, and influence on surrounding structure. For periphery and shape, a) size, b) appearance and c) location of the lesion were investigated. To estimate the size of the lesion, axial view showing the largest area of the lesion were selected. Then, the diameters of the lesion along the arch axis (mesial-to-distal) and arch width (bucco-lingual) were measured using digital caliper of PACS viewer (Tae-Young soft, Gyeonggi-do, Republic of Korea). The lesion area was obtained by calculating the size of each measured lesion. The lesion size was divided into small and large groups based on the average value of total lesion areas. The appearance of lesion was evaluated as round or scallop by. The appearance of lesion was evaluated as round or scallop by viewing all cross-sections of the CT image.

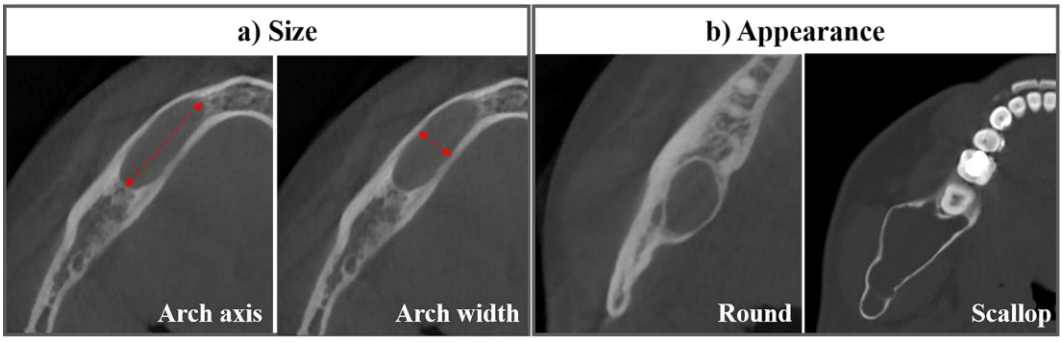

Figure 2. The radiologic features of periphery and shape in computed tomographic image. a) size measurement of the lesion in arch axis and width, b) appearance of the lesion as round or scallop.

An example image of the size and appearance of lesion is in Figure 2. The location of lesion was divided into the following 6 regions; anterior, posterior, and anteroposterior of maxilla; anterior, posterior, anteroposterior of mandible.

For the internal structure, a) presence of septa, b) presence of keratin-like material and c) CT value were investigated (Figure 3). For both septa and keratin-like material, all axial sections of image were reviewed and classified as presence or absence. The CT value was acquired only when the choice of pre-surgical imaging was MDCT. The measured area of the CT value was measured by the red dotted line in Figure 3c. The value was obtained from the same image where the size of the lesion was measured.

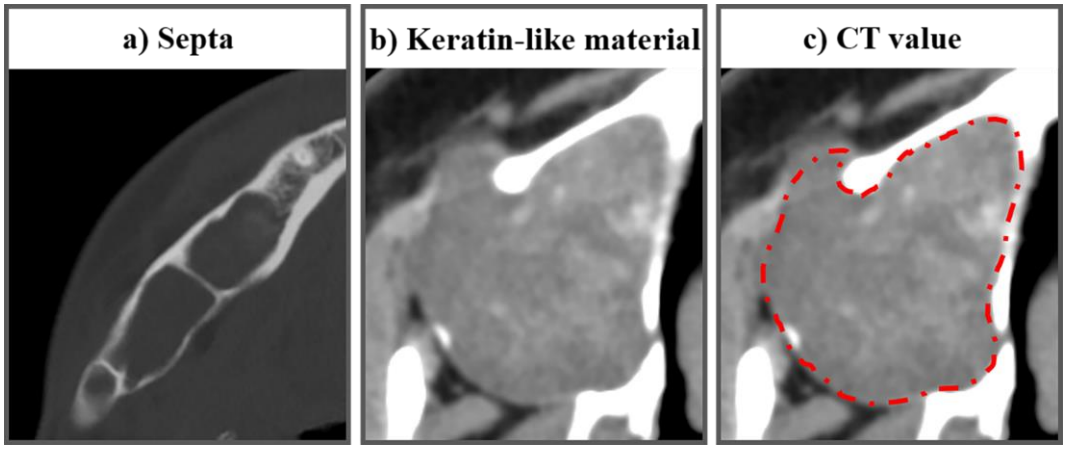

Figure 3. The radiologic features of internal structure in CT image. The representative image of a) presence of septa, b) presence of keratin-like material. c) CT value measurement in Hounsfield Unit. The red dotted line represents the area where the CT value was measured.

The influence of surrounding structures was as followed; a) tooth resorption, b) tooth displacement, c) tooth inclusion within by the lesion, d) cortical bone expansion and e) cortical bone perforation (Figure 4). The tooth resorption and displacement were all defined as presence or absence. The tooth inclusion within the lesion was determined as presence when the lesion completely encasing the tooth. For cortical bone expansion, it was determined as presence when if there was either buccal, lingual or both sides of cortical bone expansion. The cortical bone perforation was also determined as any part of cortical perforation was observed, it was indicated as present.

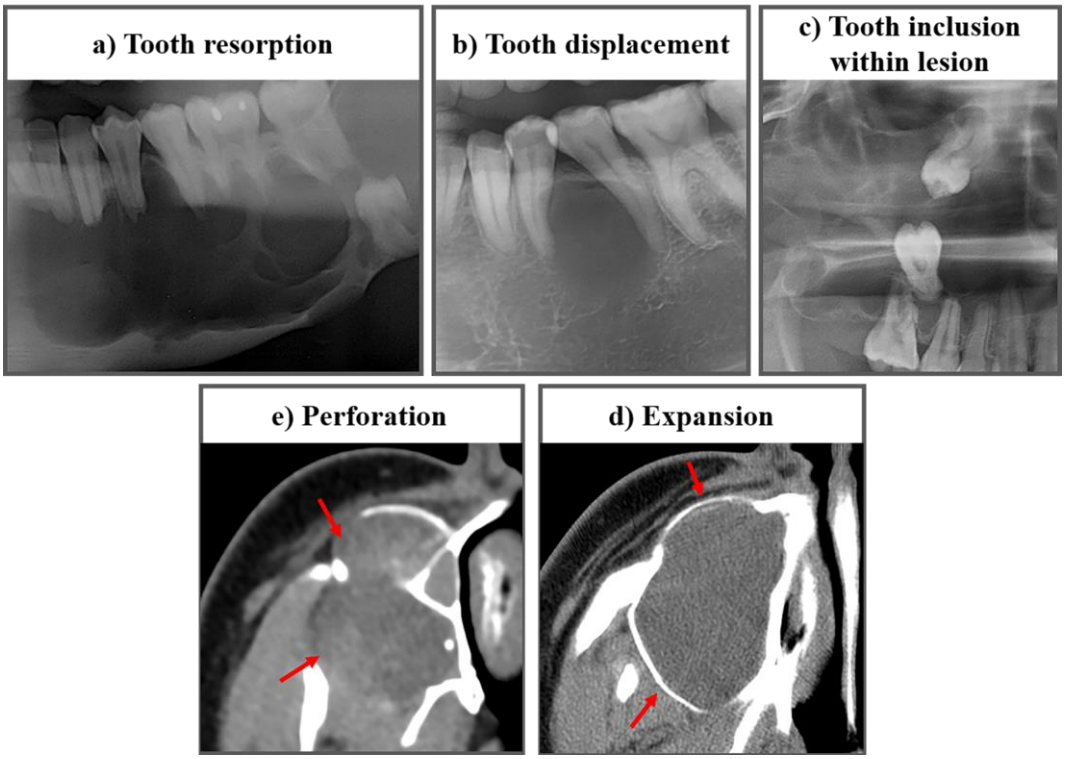

Figure 4. The influence of surrounding structures. a) tooth resorption, b) tooth displacement, c) tooth inclusion within lesion, d) expansion, e) perforation. Rad arrows to the expansion, and perforation portions.

3. Statistical analysis

A cox proportional hazards model was performed to determine the prognostic factors associated with recurrence. In addition, the probability of recurrence according to the prognostic factors was confirmed through the relative hazards ratio (HR). The HR is the risk of recurrence in the presence of prognostic factor compared to the absence of the factor. If HR is greater than 1.0, the risk of recurrence of the lesion with the prognostic factors is increased, while if HR is less than 1.0, the risk is decreased.

In the univariable analysis, the unadjusted HR ratio is presented without correction of the interaction effects of each factor. In the multivariate analysis, the adjusted HR is suggested, which can identify the intrinsic influence of each factor that have corrected the mutual influence of each other. The statistical analysis methods used in the study is described in Figure 5.

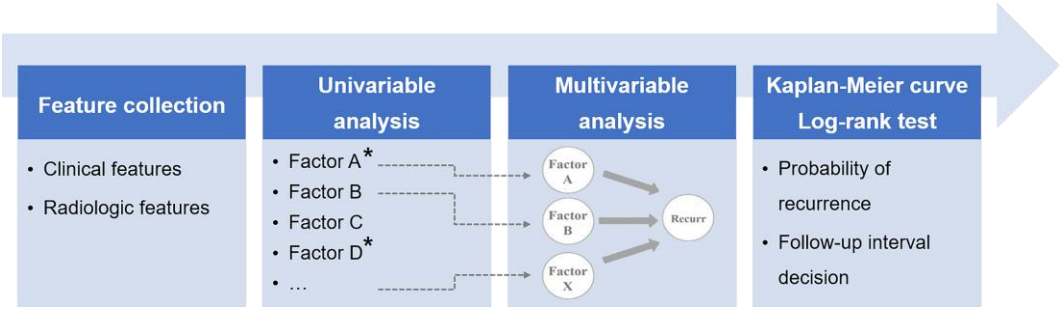

Figure 5. Statistical flow for identifying the prognostic factor and assess recurrent rate according to the factor.

3.1 Prognostic factor determination and risk assessment

The univariable cox regression analysis was performed to identify important factors for the recurrence. For this step, the significance level was set as p-value<0.1, because the commonly used significance level (p-value < 0.05) may cause omission of factors which are clinically important. For this reason, the significance level was set less strictly at p-value < 0.1.

After selection of significant factors from the univariable cox regression, multiple cox regression was conducted since recurrence is caused by several correlated factors. With the multiple cox regression analysis, models are estimated according to the number and combination of factor, and the variable selection proceeds by adding or removing factors. For this study, the final multiple cox regression model was constructed using backward elimination, which is a method of sequentially removing factors with high significance probability. The significance level of the multiple cox regression model was set as p-value < 0.05.

The cox proportional hazards model constructs the model as the HR in the absence of prognostic factors and the HR in the presence of prognostic factors. It is assumed that this HR is always constant with respect to time, called the 'proportionality assumption.' The cox proportional hazard model is established only when the proportionality assumption is satisfied. In this study, the observed-expected plot and the Schoenfeld residuals plot were performed to prove the proportionality assumption of the established cox proportional hazards model.

3.2 Recurrent rate assessment

Using the Kaplan-Meier curve and log-rank test, the difference in recurrence rate according to the significant prognostic factors was confirmed, and the recurrence period is presented by identifying the time when the most recurrence occurs according to each factor. Statistical analyses were conducted in R Studio (version 4.2.1, R Foundation for Statistical Computing, Vienna, Austria).

Ⅲ. RESULTS

1. General information

A total of 267 patients were analyzed; 199 non-recurrence patients (74.53%), and 68 recurrence patients (25.47%). The average patient follow-up period was 4.36 years (range: 0.58-17.75 years). The patients with recurrence more than twice is 15. There were 14 patients who relapsed 2 times, and 1 patient had recurrence of 3 times. Recurrence occurred in 32 patients (11.9%) within 5 years, in 28 patients (10.4%) within 10 years, and in 8 patients (2.9%) within 15 years.

The average age of patients was 32.25 years and the range was 7 to 86 years. The OKC patients was the highest in the 20s group. The OKC occurred in 133 males (49.81%) and 134 females (50.19%) (Figure 6).

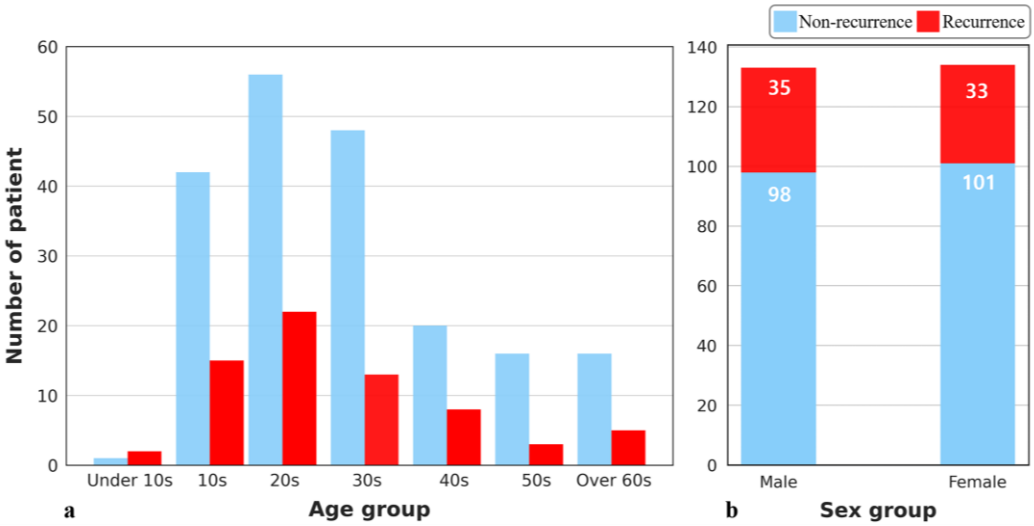

Figure 6. General information of patient information.

For pre-surgical imaging modality, 45 CBCT (16.85%) and 222 MDCT (83.15%) images were obtained. The preliminary clinical diagnosis was confirmed in the order of OKC (n=179, 67.04%), cyst (n=77, 28.84%), and tumor (n=11, 4.12%). The treatment methods were performed in the order of enucleation (n=166, 62.17%), enucleation with decompression (n=95, 35.58%), and resection (n=6, 2.25%). General information on surgical information for non- recurrence and recurrence patients is presented in Table 2.

Table 2. General information according to pre-surgical imaging, preliminary clinical diagnosis and treatment method.

Surgical information, N (%)		**Non-recurrence**	**Recurrence**	**Total**
Pre-surgical imaging	MDCT	165 (74.32)	57 (25.68)	222 (100)
	CBCT	34 (75.56)	11 (24.44)	45 (100)
Preliminary clinical diagnosis	OKC	128 (71.51)	51 (28.49)	179 (100)
	Cyst	62 (80.52)	15 (19.48)	77 (100)
	Tumor	9 (81.82)	2 (18.18)	11 (100)
Treatment method	Enucleation	128 (77.11)	38 (22.89)	166 (100)
	Enucleation with decompression	65 (68.42)	30 (31.58)	95 (100)
	Resection	6 (100)	0 (0.00)	6 (100)

MDCT, multidetector computed tomography; CBCT, cone-beam computed tomography; OKC, odontogenic Keratocyst

The average size measured in 3D images of all patients 511.06 mm^2 (range: 68.31-6272.15 mm^2). The non- recurrence patients were 531.45 mm^2 (range: 68.31-6272.15 mm^2), and recurrence patients were 452.18 (range: 106.86-1881.60 mm^2). The categorized size was described in the Table3. The appearance of the lesion was more round (n=194, 72.66%) than scallop (n=73, 27.34%).

Table 3. General information about the size and appearance of the periphery and shape.

Radiologic features, N (%)		**Non-recurrence**	**Recurrence**	**Total**
Size	Small	130 (72.63)	49 (27.37)	179 (100)
	Large	69 (78.41)	19 (21.59)	88 (100)
Appearance	Round	155 (79.90)	39 (20.10)	194 (100)
	Scallop	44 (60.27)	29 (39.73)	73 (100)

For location of lesion, mandible posterior (n=166, 62.17%), maxilla posterior (n=64, 23.97%), mandible anteroposterior (n=16, 5.99%), mandible anterior (n=8, 3.00%), maxilla anterior (n=7, 2.62%), maxilla anteroposterior (n=6, 2.25%) was the most common (Figure 7).

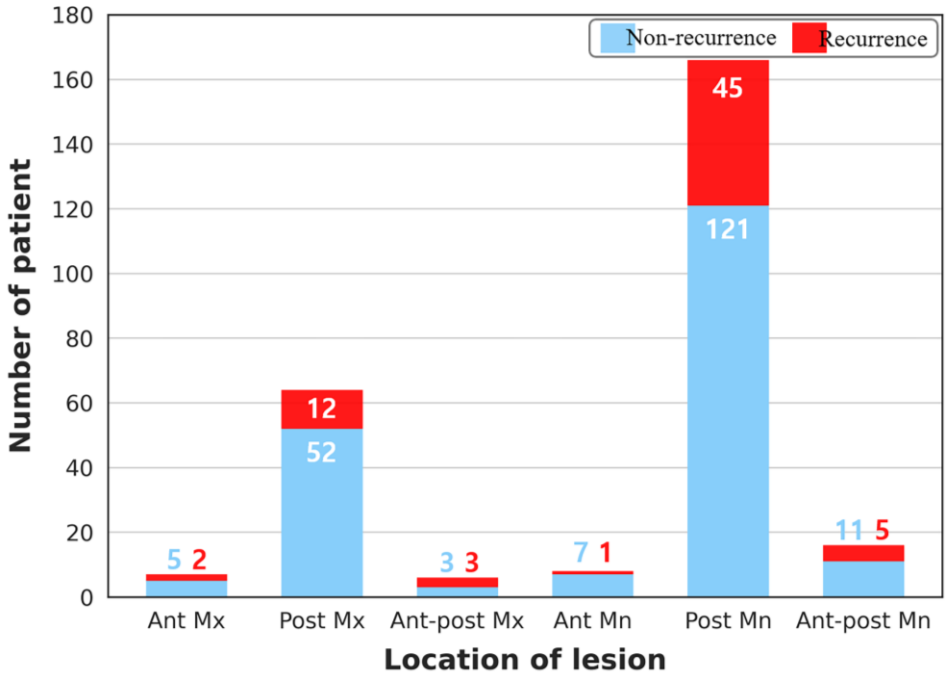

Figure 7. Incident of odontogenic keratocyst according to the location. *ant, anterior; post, posterior; Mx, maxilla; Mn, mandible*

The septa were absence (n=243, 91.01%) more frequently than presence (n=24, 8.99%). In the case of keratin-like material, there were more cases with keratin-like material inside the lesion (n=139, 66.19%) than that without keratin-like material (n=71, 33.81%). The details of septa and keratin-like material are summarized in the Table 4. The average CT value measured in 210 MDCTs was 37.03HU (range: 0.754-149.698HU) (Table 5). The 57 patients with difficulties in evaluating keratin-like material and measuring CT value were excluded.

Table 4. General information about the septa and keratin-like material of the internal structure.

Radiologic features, N (%)		**Non-recurrence**	**Recurrence**	**Total**
Septa	Absence	188 (77.37)	55 (26.63)	243 (100)
	Presence	11 (45.83)	13 (54.17)	24 (100)
Keratin-like material (n=210)	Absence	107 (76.98)	32 (23.02)	139 (100)
	Presence	48 (67.61)	23 (32.39)	71 (100)

Table 5. The CT value of the lesion measured in the 3D image (n=210).

CT value (HU)	**Non-recurrence**	**Recurrence**	**Total**
Average value	36.83	37.60	37.03
Minimum-maximum value	2.92-149.70	0.75-80.28	0.75-149.70

There were more teeth that were resorption (n=256, 95.88%) than those that had not resorption (n=11, 4.12%). Also, there were more teeth that were not displacement (n=190, 71.16%) than those that tooth displacement (n=77, 28.84%). There was more without teeth inside the lesion (n=170, 63.67%) than with teeth inside the lesion (n=97, 36.33%). There were more cases without expansion (n=165, 61.80%) than with expansion (n=102, 38.20%) of the lesion. There were more cases without perforation (n=249, 93.26%) than perforation (n=18, 6.74%) of the cortical bone surrounding the lesion. The characteristics of the surrounding structure of the lesion are listed in Table 6.

Table 6. General information according to the surrounding structure of radiologic features.

Radiologic features, N (%)		**Non-recurrence**	**Recurrence**	**Total**
Tooth resorption	Absence	191 (74.61)	65 (25.39)	256 (100)
	Presence	8 (72.73)	3 (27.27)	11 (100)
Tooth displacement	Absence	144 (75.79)	46 (24.21)	190 (100)
	Presence	55 (71.43)	22 (28.57)	77 (100)
Tooth inclusion within lesion	Absence	123 (72.35)	47 (27.65)	170 (100)
	Presence	76 (78.35)	21 (21.65)	97 (100)
Cortical bone expansion	Absence	120 (72.73)	45 (27.27)	165 (100)
	Presence	79 (77.45)	23 (22.55)	102 (100)
Cortical bone perforation	Absence	187 (75.10)	62 (24.90)	249 (100)
	Presence	12 (66.67)	6 (33.33)	18 (100)

2. Prognostic factor determination and risk assessment

2.1 Prognostic factor selection

As a result of univariable analysis, the factors significantly influencing recurrence were pre-surgical imaging, size, appearance, location, and septa. On pre-surgical imaging, the risk of recurrence was 1.82 times (p=0.072) higher in CBCT than in MDCT, and 0.56 times (p=0.037) lower in lesion size large. The risk of recurrence was 1.58 times (p=0.065) higher when the appearance of the lesion was scallop compared to the round. The HR of lesion location; Ant Mx 10.20 (p=0.003), Post Mx 0.64 (p=0.172), Ant-post Mx 1.00 (p=0.996), Ant Mn 1.97 (p=0.057), Ant-post 0.89 (p=0.809). The risk of recurrence was 5.14 times (p=0.000) higher when septa is presence rather than absence. The results of univariable analysis of all factors are presented in Table 7.

Table 7. Results of univariable cox regression analysis.

Prognostic factors		Unadjusted HR (95% CI)	P-value
Clinical feature - Clinical information			
Age group	Under 10s	Ref	
	10s	0.88 (0.20-3.89)	0.870
	20s	0.84 (0.20-3.62)	0.820
	30s	0.95 (0.21-4.22)	0.940
	40s	0.89 (0.19-4.23)	0.880
	50s	0.41 (0.07-2.51)	0.340
	Over 60s	0.88 (0.17-4.57)	0.880
Sex	Male	Ref	
	Female	0.81 (0.49-1.32)	0.387
Clinical feature - Surgical information			
Pre-surgical imaging	MDCT	Ref	
	CBCT	1.82 (0.95-3.50)	**0.072***
Preliminary clinical diagnosis	OKC	Ref	
	Cyst	1.07 (0.60-1.91)	0.810
	Tumor	0.54 (0.13-2.23)	0.400
Treatment method	Enucleation	Ref	
	Enucleation with decompression	1.49 (0.92-2.43)	0.110
	Resection	0.00 (0.00-0.00)	1.000
Radiologic feature - Periphery and shape			
Size (mm^2)	Small	Ref	
	Large	0.56 (0.32-0.96)	**0.037***
Appearance	Round	Ref	
	Scallop	1.58 (0.97-2.57)	**0.065***
Location	Post Mn	Ref	
	Ant Mx	10.20 (0.98-2.19)	**0.003***
	Post Mx	0.64 (1.56-0.34)	0.172
	Ant-post Mx	1.00 (1.00-0.30)	0.996
	Ant Mn	1.97 (0.51-0.27)	0.507
	Ant-post Mn	0.89 (1.12-0.35)	0.809

Radiologic feature - Internal structure			
Septa	Absence	Ref	
	Presence	5.14 (2.67-9.88)	**0.000***
Keratin-like material	Absence	Ref	
	Presence	1.29 (0.75-2.23)	0.360
CT value (HU)		1.00 (0.99-1.01)	0.960
Radiologic feature – Surrounding structure			
Tooth resorption	Absence	Ref	
	Presence	1.11 (0.35-3.56)	0.858
Tooth displacement	Absence	Ref	
	Presence	1.02 (0.61-1.71)	0.941
Tooth inclusion within lesion	Absence	Ref	
	Presence	1.45 (0.86-2.46)	0.167
Cortical bone expansion	Absence	Ref	
	Presence	0.90 (0.54-1.49)	0.684
Cortical bone perforation	Absence	Ref	
	Presence	1.29 (0.56-3.01)	0.549

*Statistically significant difference at $p < 0.1$.

HR, relative hazards ratio; CI, confidence interval; MDCT, multidetector computed tomography; CBCT, cone-beam computed tomography; OKC, odontogenic Keratocyst; Ant, anterior; Post, posterior; Mx, maxilla; Mn, mandible

2.2 Determination of factors and risk assessment

Multivariable analysis was performed with 5 important factors in univariable analysis, and the final model using backward elimination included the size and septa factors. The final multiple cox regression model was statistically significant with a *p*-value of 0.038. When the size of the lesion was large, the adjusted HR was 0.52 (*p*=0.020) indicating recurrence risk of small lesion is 1.92 times higher than large lesion. The risk of recurrence was 5.61 times higher when the septa was present than when it was not present. The final multiple cox regression model results are presented in Figure 8.

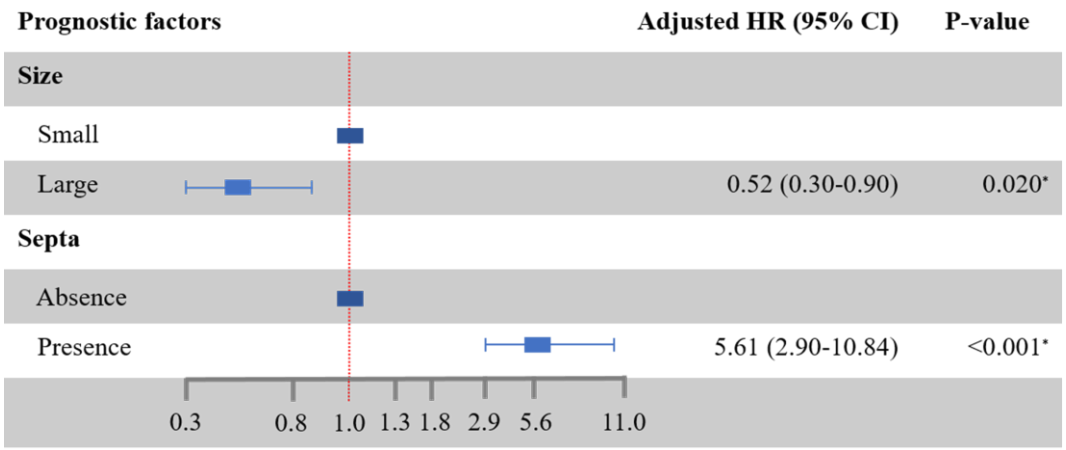

Figure 8. Results of multiple cox regression analysis. If it is greater than the 1.0 (rad dotted line), the risk of recurrence increases, and less than 1.0, the risk decreases.

*Statistically significant difference at $p < 0.05$. *HR, relative hazards ratio; CI, confidence interval*

2.3 Proportional hazard assumption

In the observed-expected plot, it was confirmed that the proportional hazard assumption was satisfied as the observed line follows the expected lines with high similarity (Figure 9). Therefore, as there is no noticeable difference between the observed and expected lines, the proportional hazards assumption was satisfied. The proportional hazard assumption was also confirmed to be satisfied as a result of the Schoenfeld residuals plot showing the proportionality assumption is satisfied with p-value>0.05. In the plot, the assumptions were satisfied with a p-value of 0.24 for size and 0.13 for septa factors. Therefore, the final cox proportional hazards model used in this study can be used.

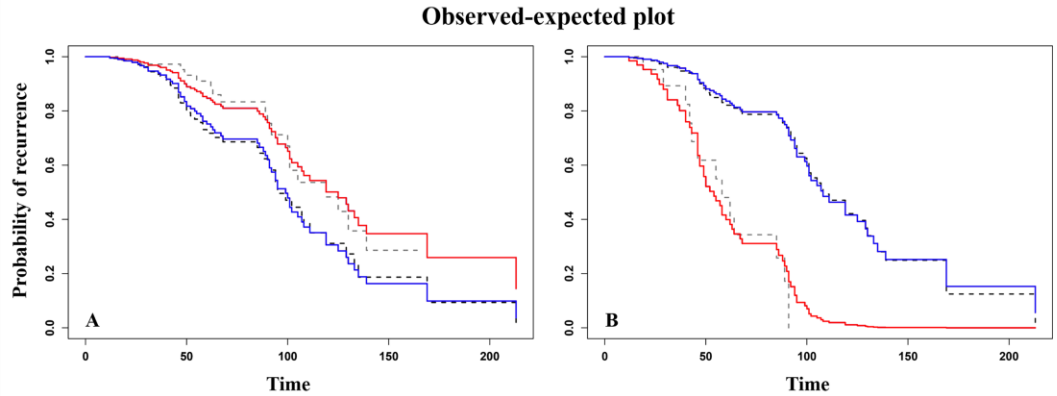

Figure 9. Observed-expected plot of the prognostic factor is confirmed the satisfaction of the proportional hazard assumption. The expected line (color) is described as similar to the overserved line (black dotted). (A) The plot related to size factor (B) The plot related to septa factor. *Blue line; small, absence of septa. Red line; large, presence of septa.*

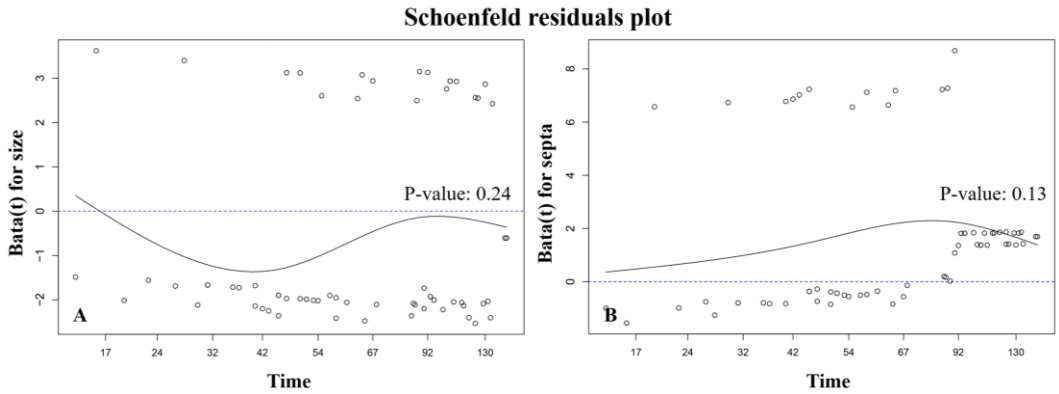

Figure 10. Schoenfeld residuals plot of the prognostic factor shows the proportional hazard assumption is satisfied (p >0.05). (A) The plot of size factor, (B) The plot of septa factor.

3. Recurrent rate assessment

The Kaplan-Meier curve was derived to analyze the effect on the probability of recurrence according to the identified prognostic factors size and septa (Figure 11,12). Large size of lesion showed low recurrence compared to the small size lesion and the difference was a statistically significant the log-rank test result (p=0.046). When the recurrence rate drops below 50%; 8 years for small lesion and 10 years for large lesion after the surgery as shown in Figure 11.

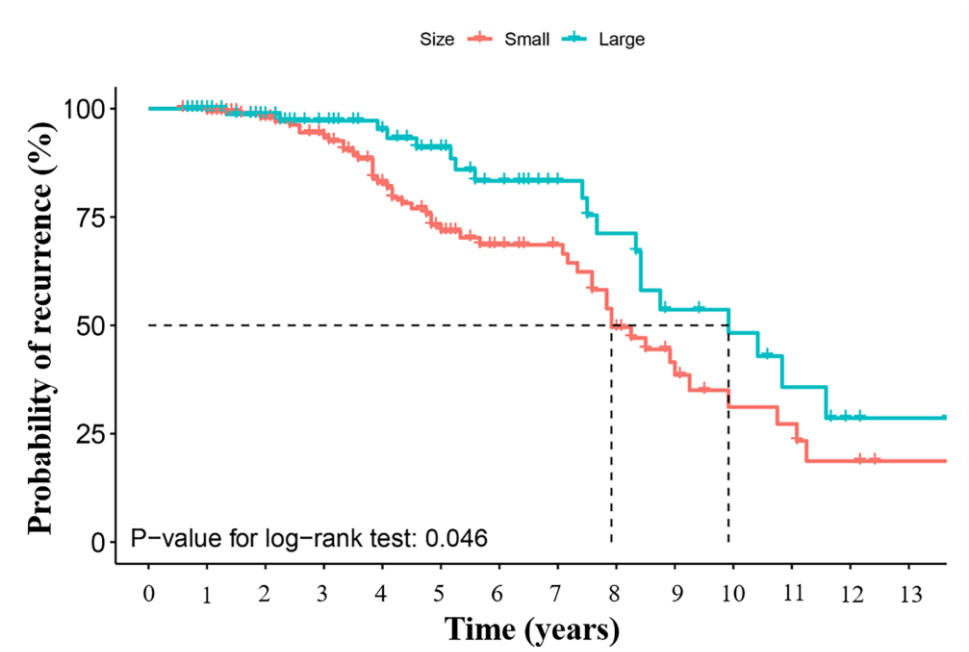

Figure 11. Kaplan-Meier curve and log-rank test of size factor shows the cumulative risk of the lesion is significantly higher in small lesion compared to the large lesion. The recurrence occurs with shorter interval after the surgery in small lesion compared to the large lesion with statistical difference ($p < 0.05$). The dotted line indicates the time point when the recurrence rate is 50%.

In the case of the septa factor, it was confirmed that the probability of recurrence was higher when septa was present than absent, and the difference was statistically significant (p<0.001). It was found that the risk of recurrence increased sharply with time when septa was present than absent (Figure 12). The recurrence rate dropped to 50% at 5 years in presence of septa and 9 years in absence of septa.

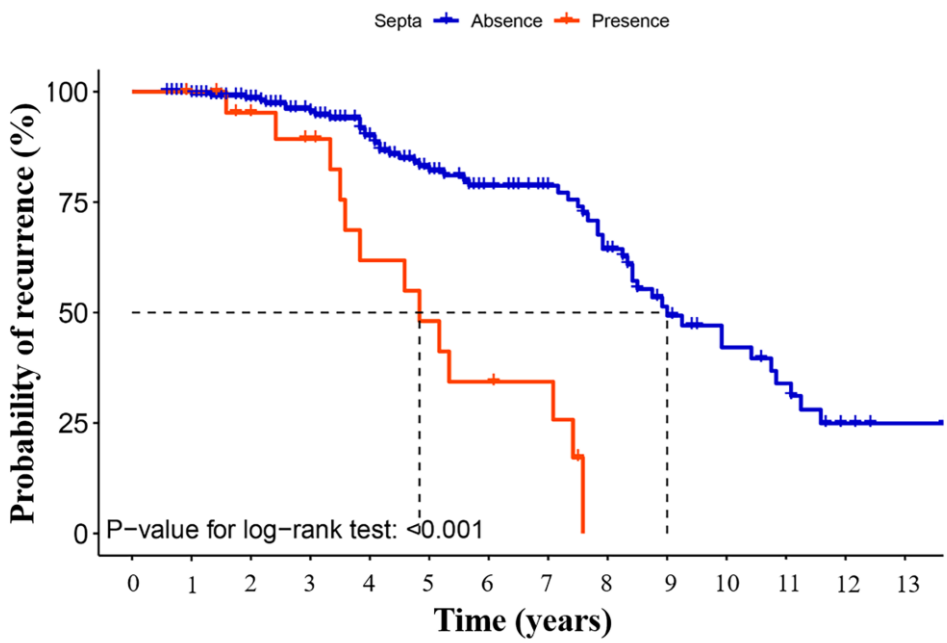

Figure 12. Kaplan-Meier curve and log-rank test of septa factor shows the cumulative risk according to the present (blue line) or absent (red line) of septa. The recurrence occurs more quickly after the surgery when septa is present than absent and the difference is significant ($p < 0.05$). For the lesion with septa shows drastic drops of curve during 3 to 7 years indicating high frequency of recurrence. The dotted line indicates the time point when the recurrence rate is 50%.

Ⅳ. DISCUSSION

OKC is a relatively common cystic lesion with high recurrence in maxillofacial region [6,7]. Although many researchers tried to elucidate definitive recurrence factor, there has been no study yet to confirm the prognostic factor for recurrence clearly[3-15]. Also, the study about the detailed radiologic feature associated with the OKC recurrence was scarce. This study has significant meaning that the various radiologic features were investigated to find prognostic factor of OKC recurrence. In addition, this study suggests an appropriate follow-up interval by analyzing the probability of recurrence with the prognostic factors. It is significant that this study provided analytical evidence for the follow-up interval, which has been determined by clinician's experience previously.

The recurrence rate of OKC has been reported as widely varied from 7.4 to 58.3% [8-13]. The current study showed recurrence rate of 25.47% during an average follow-up period of 52.28 months. The previous study conducted on the largest sample number (n=351) also reported similar values of recurrence rate, 19.47%[13]. The current study was also based on the large sample size (n=565) comparable to the previous study, thus, it would be considered to present sufficient reliability for the recurrence study.

The meaningful result of the current study was that the lesion with septa showed significantly higher (5.62 times) recurrence rate compared to that without septa. As far as we know, the study about presence of septa of the OKC was first studied as a prognostic factor in this study. Yet, a few previous studies mentioned locularity of the lesion either

unilocular or multilocular, which can be considered as similar factor as septa in this study[7,8,13,14]. Their studies were consistent with the current study as they reported the multilocular lesion showed high recurrence rate compared to the unilocular lesion. In this study, authors found that most of the lesion showing multilocular pattern in panoramic radiography were actually unilocular with open septation in CT image. Thus, we considered it would be more precise to define such feature as presence of septa, rather than multilocular. As such, it can be confirmed that the more irregular the internal structure of the lesion, the higher the risk of recurrence.

One of the other prognostic factors shown in this study was size of the lesion. There were many researches on the lesion size and recurrent rate[7,8,13,14]. However, the result was different from the current study. In previous studies, the larger the lesion, the higher the risk of recurrence[7,8,13,14]. In the current study, large sized lesion showed 0.52 times lower recurrence rate compared to the small sized lesion. This was probably due to the different measurement method and imaging modality according to the individual study design. All previous studies were measured the lesion based on panoramic images[7,8,13,14]. Also, some of them measured only the major axis of the lesion[7,13]. Considering magnification and distortion of the panoramic radiography, the precise lesion size cannot be obtained. Meanwhile, the size measurement of the current study cannot be assumed as highly precise although it was measured in 3D image, since the size was measured by multiplying axis and width in one slice of the image. Thus, further study using sophisticated size measurement system should be conducted to result this controversial result. Based on the

result of the present study only, the size cannot be considered as definitive prognostic factor.

When the interactions among individual features was not adjusted, the univariate analysis, the modality of the pre-surgical imaging and the location of the lesion were also found to be factors related to recurrence. One of them, the pre-surgical imaging factor, showed that the probability of recurrence was higher when using CBCT than MDCT during the diagnosing lesions. This can be explained as the clinician may tend to choose MDCT over CBCT when the lesion shows more complex internal structures presenting aggressive impression. The complex internal structure, the presence of septa was shown to be correlated with high recurrence rate, as described above. It can be assumed that appearance, specifically scalloping shape, also closely related with presence of septa within the lesion. In the current study, the risk of recurrence was 1.58 times higher in the scallop than in the round. The lesion with septa has tendency to show scalloping border shape rather than simple round border. As a recurrence factor, the factor according to the border shape was also studied in advance. For the location of the lesion, several previous literatures reported that it is significant factor related with recurrence of OKC[3,11]. In previous studies, it was mentioned that deep area within the maxillofacial bone are closely related to the probability of recurrence due to difficult surgical approach due to imperfect resection of the root and the presence of the in posterior mandible[24]. In the current study, the anterior maxilla was the significant factor with 10.2 times high recurrence risk compared to the posterior mandible, where OKC mostly occur. The anterior maxilla is an area that is easily accessible during the surgery, which is contrary to the previous literature that recurrence would be

related with the areas that are difficult to access. This is probably because extremely small samples of anterior maxilla case were included in the current study. It is thought that the location was not included in the final prognostic factor through multivariate analysis because of the bias caused by the non-uniform sample distribution.

This study showed that when lesion shows septa, which is the definitive factor of high recurrence, the probability of recurrence changed drastically between 3 and 7 years after the surgery. Although the last recurrent lesion was presented at 8 years after the surgery in the lesion with septa, in terms of the overall recurrent lesions, recurrent occurred even after 10 years of follow-up in 8 patients (11.76%). This was consistent with the previous study that reported recurrence of OKC within 5-7 years after the surgery, and the recurrent also occurred after 10 years8,14. This suggests that follow-up should be conducted with a focus on 5-7 years after treatment, specifically when the primary lesion had septa within it. Also, check-up examination would be required with wide interval after the 10 years post-operatively.

The limitation of this study is that it is conducted in a single-center, so it is difficult to generalize. However, since it was performed at a single-center, standardized follow-up in relation to surgical methods and pre-surgical imaging test was possible, so consistent data could be obtained when collecting radiographic features. Moreover, compared to previous studies, it is a study conducted over a long period of time with a relatively large number of patients, and it can be helpful as prognostic factors that can be referenced when setting up a treatment method and follow-up plan for OKC.

V. CONCLUSION

During the maximum period of 18 years of follow-up in this study, the recurrence of the OKC was shown in 25.47% of the total subjects of 267 cases. When the interactions of individual factors were not adjusted, the following features were shown to influence for the recurrence of OKC; the modality of pre-srugical imaging, the lesion size, the location, the appearance and the septa wihtin the lesion. Among them, as the interaction between factors were adjusted, the size of the lesion and the septation were finally determined as the prognostic factor influencing the OKC recurrence. Careful radiologic analysis is required during the treament planning stage since both prognositc factors can be confirmed thorugh the CT examination. In specific, presence of septation within the lesion should be evaluated precisely as the recurrence rate was about 5.6 times higher when the lesion shows septa. The recurrence rate increases significantly during 3-7 years after surgery. Therefore, follow-up evaluation should be more focused on within 7 years from the initial treatment.

REFERENCES

1. Chung, Sae Rom, et al. "Prognostic factors predicting recurrence in invasive breast cancer: An analysis of radiological and clinicopathological factors." Asian journal of surgery 42.5 (2019): 613-620.

2. Senkus, E., et al. "Primary breast cancer: ESMO Clinical Practice Guidelines for diagnosis, treatment and follow-up." Annals of oncology 26 (2015): v8-v30.

3. Mao, Shuqi, et al. "Development of nomogram models of inflammatory markers based on clinical database to predict prognosis for hepatocellular carcinoma after surgical resection." BMC cancer 22.1 (2022): 1-14.

4. Talebi, Atefeh, et al. "Development of web-based dynamic nomogram to predict survival in patients with gastric cancer: a population-based study." Scientific Reports 12.1 (2022): 1-9.

5. Moreno, Lucas, et al. "A nomogram of clinical and biologic factors to predict survival in children newly diagnosed with high-risk neuroblastoma: An International Neuroblastoma Risk Group project." Pediatric Blood & Cancer 68.3 (2021): e28794.

6. El-Naggar, Adel K., John KC Chan, and Jennifer R. Grandis. WHO classification of head and neck tumours. (2017).

7. Aquilanti, L., et al. "Non-neoplastic jaw cysts: a 30-year epidemiological s tudy of 2150 cases in the Italian population." British Journal of Oral and Maxillofacial Surgery 59.2 (2021): 168-173.

8. Myoung, Hoon, et al. "Odontogenic keratocyst: review of 256 cases for re currence and clinicopathologic parameters." Oral Surgery, Oral Medicine, O ral Pathology, Oral Radiology, and Endodontology 91.3 (2001): 328-333.

9. Chirapathomsakul, Duangrudee, Panunn Sastravaha, and Pornchai Jansisyan ont. "A review of odontogenic keratocysts and the behavior of recurrences. " Oral surgery, oral medicine, oral pathology, oral radiology, and endodont ology 101.1 (2006): 5-9.

10. Kuroyanagi, Norio, et al. "Prognostic factors for keratocystic odontogenic t umor (odontogenic keratocyst): analysis of clinico-pathologic and immunoh istochemical findings in cysts treated by enucleation." Journal of oral patho logy & medicine 38.4 (2009): 386-392.

11. Zhao, Y., Liu, B., Cheng, G., Wang, S. P., & Wang, Y. N. (2012). Recurr ent keratocystic odontogenic tumours: report of 19 cases. Dentomaxillofacia l Radiology, 41(2), 96-102.

12. Tabrizi, Reza, et al. "Correlation of radiographic features and treatments w ith the frequency of recurrence in odontogenic keratocysts of the mandible. " Journal of Craniofacial Surgery 25.5 (2014): e413-e417.

13. Fidele, Nyimi-Bushabu, et al. "Recurrence of odontogenic keratocysts and possible prognostic factors: Review of 455 patients." Medicina oral, patologia oral y cirugia bucal 244 (2019): e491.

14. Stoelinga, Paul JW. "Long-term follow-up on keratocysts treated according to a defined protocol." International journal of oral and maxillofacial surgery 30.1 (2001): 14-25.

15. Zhao, Yi-Fang, Jin-Xiong Wei, and Shi-Ping Wang. "Treatment of odontogenic keratocysts: a follow-up of 255 Chinese patients." Oral Surgery, Oral Medicine, Oral Pathology, Oral Radiology, and Endodontology 94.2 (2002): 151-156.

16. Habibi, Ataollah, et al. "Keratocystic odontogenic tumor: a 10-year retrospective study of 83 cases in an Iranian population." Journal of oral science 49.3 (2007): 229-235.

17. Kaczmarzyk, T., I. Mojsa, and J. Stypulkowska. "A systematic review of the recurrence rate for keratocystic odontogenic tumour in relation to treatment modalities." International journal of oral and maxillofacial surgery 41.6 (2012): 756-767.

18. Yagyuu, Takahiro, et al. "Recurrence of keratocystic odontogenic tumor: clinicopathological features and immunohistochemical study of the Hedgehog signaling pathway." Pathobiology 75.3 (2008): 171-176.

19. Kaczmarzyk, Tomasz, et al. "Investigation of clinicopathological parameters and expression of COX-2, bcl-2, PCNA, and p53 in primary and recurrent sporadic odontogenic keratocysts." Clinical oral investigations 22.9 (2018): 3097-3106.

20. de França, Glória Maria, et al. "Recurrence-free survival and prognostic factors of odontogenic keratocyst: a single-center retrospective cohort." European Archives of Oto-Rhino-Laryngology 278.4 (2021): 1223-1231.

21. Ferreira Junior, O., J. H. Damante, and J. R. P. Lauris. "Simple bone cyst versus odontogenic keratocyst: differential diagnosis by digitized panoramic radiography." Dentomaxillofacial Radiology 33.6 (2004): 373-378.

22. Kitisubkanchana, Jira, et al. "Odontogenic keratocyst and ameloblastoma: radiographic evaluation." Oral radiology 37.1 (2021): 55-65.

23. Philipsen, H. P. "Keratocystic odontogenic tumour." World health Organization classification of tumours, pathology and genetics of tumours of the head and neck (2005): 306-307.

24. Jung, H. D., Lim, J. H., Kim, H. J., et al. "Appropriate follow-up period for odontogenic keratocyst: a retrospective study." Maxillofacial plastic and reconstructive surgery 43.1 (2021): 1-6.

Abstract (in Korean)

다변수 분석을 통한 치성각화낭종의 재발위험 예측 연구

< 지도교수 이 채 나 >

연세대학교 대학원 치의학과

이 아 리

연구목적: 본 연구의 목적은 임상적, 영상적 요인 분석을 통해 치성각화낭종의 재발에 영향을 미치는 재발 예측 인자를 확립하고, 재발 확인에 효과적인 영상 추적 검사 주기를 제안하고자 한다.

연구대상 및 방법: 연세대 치과병원에서 수술 후 치성각화낭종으로 진단된 총 506명의 환자를 분석하였다. 포함된 환자들의 기록에서 총 16개의 임상-방사선학적 특징(임상적 특징 5개, 방사선학적 특징 11개)를 분석하였다. 임상적 특징은 나이, 성별, 술전 진단영상의 종류, 술전 임상진단명의 기록을 수집

하였으며, 방사선학적 특징으로 경계와 형태, 내부구조, 주변구조물에 대한 영향을 삼차원 영상에서 분석하였다. 재발 예측 인자를 확립하기 위하여 콕스비례위험모형을 사용하였다. 카플란 마이어 곡선과 로그 순위법을 통해 재발 환자와 비재발환자의 시간에 따른 생존율 비교 및 추적검사주기를 제시하였다.

연구결과: 총 506명의 환자 중 267명의 대상자가 선별되었으며, 평균 4.36년의 추적관찰기간 동안 25.47% 의 재발률이 확인되었다. 재발과 독립적으로 관련된 인자는 수술 전 영상 종류, 병소의 크기, 형태, 위치 및 격벽의 유무로 확인되었다. 각각의 변수들의 영향을 고려한 분석을 통해 최종적으로 병소의 크기와 격벽이 재발과 유의하게 관련이 있는 것으로 나타났다. 병소의 크기가 평균보다 큰 경우를 기준으로 하였을 때, 작은 경우 1.92 배 높은 재발률을 보였으며, 병소 내부에 격벽이 존재하는 경우, 그렇지 않은 경우에 비해 5.61 배 높은 재발 위험율을 보였다. 병소 내의 격벽이 존재 하는 경우, 수술 후 3-7년 동안 상당수의 재발 병소가 집중적으로 발생함을 보였다.

결론: 본 연구를 통해 치성각화낭종의 발견 시 임상적, 방사선학적 특성 중 방사선학적 특성에서 재발과 관련된 특성을 확인하였다. 방사선학적 특성 중 격벽이 있는 병소의 경우 높은 재발률을 보이며, 이 경우 수술 후 3년에서 7년사이에 면밀한 추적검사가 요구 된다.

핵심어: 치성각화낭종, 재발, 예후 관련 인자, 위험 인자, 콕스 비례위험모형