



## 군발두통의 임상 양상으로 나타난 해면정맥동혈전정맥염

주하람 정다은<sup>a</sup> 성민수 최병주 최윤정 주민경<sup>a</sup>

연세대학교 의과대학 강남세브란스병원 신경과, 연세대학교 의과대학 세브란스병원 신경과<sup>a</sup>

### Cavernous Sinus Thrombophlebitis Presenting as Cluster-like Headache

Haram Joo, MD, Da Eun Jung, MD<sup>a</sup>, Min Soo Sung, MD, Byung Joo Choi, MD, Yunjung Choi, MD, Min Kyung Chu, MD<sup>a</sup>

Department of Neurology, Gangnam Severance Hospital, Yonsei University College of Medicine, Seoul, Korea

Department of Neurology, Severance Hospital, Yonsei University College of Medicine, Seoul, Korea<sup>a</sup>

J Korean Neurol Assoc 41(3):237-239, 2023

**Key Words:** Cavernous sinus thrombosis, Cluster headache

#### Address for correspondence

Min Kyung Chu, MD  
Department of Neurology, Severance Hospital, Yonsei University College of Medicine, 50-1 Yonsei-ro, Seodaemun-gu, Seoul 03722, Korea  
Tel: +82-2-2228-1600  
Fax: +82-2-393-0705  
E-mail: chumk@yuhs.ac

**Received** February 8, 2023

**Revised** April 14, 2023

**Accepted** April 14, 2023

Cluster headache (CH) is a primary headache disorder which typically presents as periodic recurrent unilateral severe headache attacks accompanying autonomic symptoms.<sup>1</sup> Nevertheless, various conditions can mimic symptoms of CH and present as cluster-like headache. Here, we present a case of cavernous sinus thrombophlebitis presenting as cluster-like headache.

### CASE

A 48-year-old Korean man presented to emergency room with recurrent severe left-sided headache attacks involving the orbit and periorbital areas accompanied by abnormal lacrimation which started 2 days prior to the visit. He was an otherwise healthy individual with no previous medical history except occasional migraine attacks and dental caries and took no medications for the migraine attacks. His headache attacks, with a numeric rating scale (NRS) of 8-9, occurred once or twice a day and each attack lasted for an hour. Between headache attacks, patient did not report any headache. During his emergency room visit, brain computed tomography and ophthalmologic examination revealed normal findings. He was treated with intravenous (IV) analgesics at

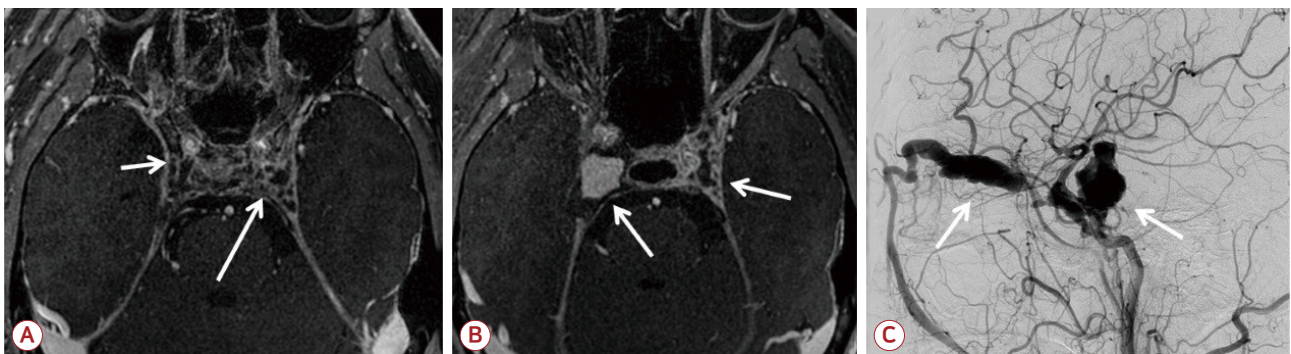
the outpatient clinic, the patient complained of an aggravation of the same left-sided headache attacks with NRS of 5, accompanied by abnormal lacrimation, involving the orbital and periorbital regions.

He was diagnosed as having CH, fulfilling the criteria for CH according to the 3rd edition of the International Classification of Headache Disorder, and was admitted to our neurology service for pain and medication control and to evaluate for possible secondary causes of headache. On admission, his contrast-enhanced brain magnetic resonance imaging (MRI) and cerebrospinal fluid examination showed no abnormal findings (Fig. A). He was prescribed oral prednisolone 60 mg/day, verapamil 320 mg/day, and valproate 500 mg/day as preventive treatment for the headache, and oral zolmitriptan 2.5 mg for acute treatment of CH. After starting the medications, the headache attacks slowly abated with shorter duration of headaches from 1 hour to 10 minutes, and a reduced NRS of 1-2 during attacks. He was discharged 4 days after admission.

A week from discharge, he was readmitted for worsened left-sided headache with an NRS of 10. On the day of admission, his headache responded well (with NRS 6) to nasal oxygen 10 L/min. On the 3rd day, contrast-enhanced brain MRI revealed a left cavernous sinus thrombophlebitis and empirical antibiotic treatment was started promptly: ceftriaxone (4 g/day), vancomycin (2 g/day), and metronidazole (1.5 g/day). On the 4th day, while the patient's left sided headache slowly showed reduction in pain intensity (NRS 3) in response to intravenous antibiotics, he started complaining of a new-onset right-sided headache (NRS 6) accompanied by a right third nerve palsy including anisocoria (6 mm/3 mm) and right ptosis. To prevent neurologic deterioration, methylprednisolone (1 g/day) pulse treatment was started.

On the 14th day of admission, follow-up contrast-enhanced brain MRI revealed progression of bilateral thrombophlebitis, right side internal carotid arteritis and carotid-cavernous fistula (Fig. B).

On the 17th day of admission, the patient expired



**Figure.** Contrast-enhanced magnetic resonance imaging and digital subtraction angiography on the 3rd and 12th day of admission. (A) Axial T1-weighted magnetic resonance imaging with gadolinium contrast enhancement revealing filling defects in both (worse on the left compared to the right) cavernous sinuses with thrombus formation indicative of cavernous sinus thrombophlebitis (white arrows) (3rd day of admission). (B) On the 12th day of admission, left-sided cavernous thrombophlebitis showed slight improvement (left white arrow) while right-sided cavernous thrombophlebitis had aggravated to form a giant pseudoaneurysm and dilation and diffuse enlargement of superior ophthalmic vein (right white arrow). (C) Digital subtraction angiography of the right internal carotid artery on the 12th day of admission revealed a giant pseudo-aneurysm with distal ICA narrowing (right white arrow). Additionally, a newly seen direct right carotid cavernous fistula formation is noted with venous reflux to superior ophthalmic vein (left white arrow). ICA; internal carotid artery.

from subarachnoid hemorrhage that was caused by an internal carotid artery rupture (Fig. C).

## CONCLUSION

Isolated headache can be the only clinical symptom of a cavernous sinus thrombophlebitis.<sup>2</sup> Previously reported cases of cavernous sinus thrombophlebitis were accompanied by intracranial hemorrhages (25%), non-hemorrhagic infarcts (27%), hydrocephalus (3%), mass effect (13%), midline shift (6%), and vasogenic or diffuse cerebral edema (9%).<sup>3</sup> While intracranial hemorrhages, mass effect or diffuse cerebral edema could be the cause of an acute progressively worsening headache, it is important to recognize that cavernous sinus thrombophlebitis can present as cluster-like headache with a normal neurological examination and a normal non-contrast brain computed tomography.<sup>2</sup> Regarding the use of contrast-enhanced MRI for first-onset cluster headache evaluation, American College of Radiology appropriateness criteria recommends that contrast-enhanced MRI be performed at follow-up if the patient does

not respond adequately to medication.<sup>4</sup> Regardless of the response to the initial treatment of CH, an initial neuroimaging protocol of brain MRI with contrast-enhanced imaging should strongly be recommended. In cases with worsened headaches after conventional first-line headache medications have been tried, a follow-up repeat high-resolution imaging should be considered to search for secondary causes of headache such as cavernous sinus thrombophlebitis so that life-threatening complications can be prevented.

## REFERENCES

1. Voiticovschi-Iosob C, Allena M, De Cillis I, Nappi G, Sjaastad O, Antonaci F. Diagnostic and therapeutic errors in cluster headache: a hospital-based study. *J Headache Pain* 2014;15:56.
2. Cumurciuc R, Crassard I, Sarov M, Valade D, Bousser MG. Headache as the only neurological sign of cerebral venous thrombosis: a series of 17 cases. *J Neurol Neurosurg Psychiatry* 2005;76:1084-1087.
3. Wasay M, Kojan S, Dai AI, Bobustuc G, Sheikh Z. Headache in cerebral venous thrombosis: incidence, pattern and location in 200 consecutive patients. *J Headache Pain* 2010;11:137-139.
4. American College of Radiology. ACR Appropriateness Criteria® Headache [online] [cited 2023 Jun 14]. Available from: <https://acsearch.acr.org/docs/69482/Narrative/>.