


Immediate postoperative lumbar spine magnetic resonance imaging

Correlation with postoperative pain in lumbar microdiscectomy

Sung Hyun Noh, MD^{a,b}, Eveline Ndraha, MD, PhD^c, Dong Ah Shin, MD, PhD^{b,c}, Pyung Goo Cho, MD, PhD^a, Keung Nyun Kim, MD, PhD^{b,c}, Sang Hyun Kim, MD, PhD^{a,*} 

Abstract

Magnetic resonance imaging (MRI) has been extensively used in the management of patients with a herniated lumbar disc. Nevertheless, immediate postoperative MRI has not become a standard procedure, with limited research suggesting that the findings are often similar to preoperative MRI in both symptomatic and asymptomatic patients. This study aimed to determine the benefits of immediate postoperative MRI in patients with or without postoperative symptoms and its correlation with these symptoms. A total of 172 patients who underwent lumbar spine microdiscectomy at our institution between 2014 and 2021 were included. Patients who had previous spinal surgery and lumbar fusion were excluded. Patient data were collected from medical records. MRI was performed 3 days after surgery and assessed by 2 neurosurgeons to minimize bias. Immediate postoperative MRI results showed dural sac compression or foraminal stenosis in 29 patients (16.86%), of which 10 had postoperative pain and 19 were pain free. Among the 143 patients (83.14%) without these findings on MR imaging, 38 had postoperative pain. Immediate postoperative MRI did not correlate with postoperative pain ($P = .421/.357$). Intraoperative bleeding and the Charlson comorbidity index (CCI) showed significant correlations with postoperative pain ($P = .018$ and $.002$, respectively). In a multivariate analysis, intraoperative blood loss and CCI independently correlated with postoperative pain ($P = .001$ and $.001$, respectively). Based on our findings, intraoperative blood loss and CCI appear to be the factors that may predict the persistence of postoperative pain, despite normal findings on MRI.

Abbreviations: CCI = Charlson comorbidity index, LDH = lumbar disc herniation, MRI = magnetic resonance imaging, VAS = visual analog scale.

Keywords: discectomy, intervertebral disc displacement, MRI, postoperative pain

1. Introduction

Lumbar disc herniation (LDH) is a common disorder among adults, with a reported lifetime occurrence as high as 40%. Compelling evidence has shown that the incidence of LDH increases with age, particularly in males.^[1–3] The highest prevalence is seen among people aged 30–50 years with a male to female ratio of 2:1.^[4] The majority of lumbar herniation cases occur at the L4-L5 and L5-S1 intervertebral disc levels.^[5]

Magnetic resonance imaging (MRI) has been extensively used for the diagnosis and evaluation of patients with herniated lumbar discs; it is the modality of choice for the assessment of discectomies. Determining the amount of time elapsed after surgery is particularly important, since findings in the immediate postoperative period need to be evaluated with caution.^[6,7]

Currently, immediate postoperative MRI is not considered to be the standard evaluation approach in many spine centers based on research stating that immediate postoperative MRI results are often similar to those of preoperative MRI in symptomatic and asymptomatic patients.^[8] Boos et al reported that MRI cannot provide a causal explanation for postoperative pain, as a majority of asymptomatic patients (63%) had findings comparable with those in symptomatic patients.^[9] There is no debate on whether to perform MRI in patients with new neurological symptoms, postoperatively. Mattew et al presented their findings from a group of patients who underwent immediate postoperative MRI of the lumbar spine for failure of symptom resolution or new compressive symptoms. This study showed that early MRI is of significant clinical value when managing the complicated postoperative lumbar spine. Early MRI has also been shown to correlate with surgical findings

The authors have no funding and conflicts of interest to disclose.

The datasets generated during and/or analyzed during the current study are available from the corresponding author on reasonable request.

^a Department of Neurosurgery, Ajou University School of Medicine, Suwon, Republic of Korea, ^b Department of Neurosurgery, Yonsei University College of Medicine, Seoul, Republic of Korea, ^c Department of Neurosurgery, Spine and Spinal Cord Institute, Severance Hospital, Yonsei University College of Medicine, Seoul, Republic of Korea.

*Correspondence: Sang Hyun Kim, Department of Neurosurgery, Ajou University Hospital, Ajou University School of Medicine, Suwon 164, Republic of Korea (e-mail: shkim709@aumc.ac.kr).

Copyright © 2022 the Author(s). Published by Wolters Kluwer Health, Inc. This is an open-access article distributed under the terms of the Creative Commons Attribution-Non Commercial License 4.0 (CCBY-NC), where it is permissible to download, share, remix, transform, and buildup the work provided it is properly cited. The work cannot be used commercially without permission from the journal.

How to cite this article: Noh SH, Ndraha E, Shin DA, Cho PG, Kim KN, Kim SH. Immediate postoperative lumbar spine magnetic resonance imaging. Correlation with postoperative pain in lumbar microdiscectomy. *Medicine* 2022;101:43(e31287).

Received: 8 April 2022 / Received in final form: 17 September 2022 / Accepted: 20 September 2022

<http://dx.doi.org/10.1097/MD.00000000000031287>

and strongly predict appropriate management and outcomes in these patients.^[8]

This study aimed to determine the benefits of immediate postoperative MRI in patients with or without postoperative symptoms, its contribution to surgical outcomes, and its correlation with postoperative symptoms and their management.

2. Material and Methods

2.1. Patients

This is a retrospective study of patients who underwent surgery at our institute between January 2014 and December 2021 (Fig. 1). We reviewed patient data from medical and surgical records, along with postoperative follow-up records from the out-patient department. This study was approved by the Institutional Review Board of our hospital. The inclusion criteria included the following: patients who underwent lumbar spine microdiscectomy for LDH; MRI evaluation 3 days after surgery; and a follow-up period >24 months. The exclusion criteria were as follows: patients who had previous spinal surgery;

patients who underwent lumbar spine fusion due to lumbar herniated discs; a follow-up period of <24 months; complications such as dura tear during surgery; and the presence of a disease at a level other than the surgical site.

2.2. Radiological evaluation

Immediate postoperative MRI was performed on the third postoperative day after lumbar spine microdiscectomy. The MRI examination included sagittal T1 and T2 and axial T1 and T2 studies. The findings were noted by a neuroradiologist and confirmed by 2 neurosurgery spine consultants (SHN, SHK) to minimize bias. We divided the patients based on their MRI findings into 2 groups. A patient group was labeled MRI positive if the postoperative MRI showed compression of the dural sac >50% or foraminal stenosis >50%, compared with the opposite side and adjacent levels (Fig. 2). The other group was referred to as MRI negative (Fig. 3).

2.3. Clinical outcome assessment

Clinical data were retrieved from patients' medical records, including indications and type of surgery, postoperative clinical condition (symptoms and signs which correlated with lumbar microdiscectomy surgery), indications for the postoperative MRI, and the MRI report. We also assessed patient pain intensity during follow-up, that is, 24 months after surgery. The visual analog scale (VAS) score was checked preoperatively, on postoperative day 3, and at the latest follow-up. Patients were categorized as symptom positive if they had back and radiating leg pain, postoperatively (VAS score >3) or symptom negative, if there was no or mild pain (pain score 0–3). Comorbidities were assessed using the modified Charlson Comorbidity Index (CCI) presented by Quan et al.^[10]

2.4. Operative technique

All patients were operated on, under general anesthesia, in the prone position. A dorsal midline incision was made after the surgical site was confirmed by radiography. The subcutaneous fat layer and fascia were excised and the muscles were detached

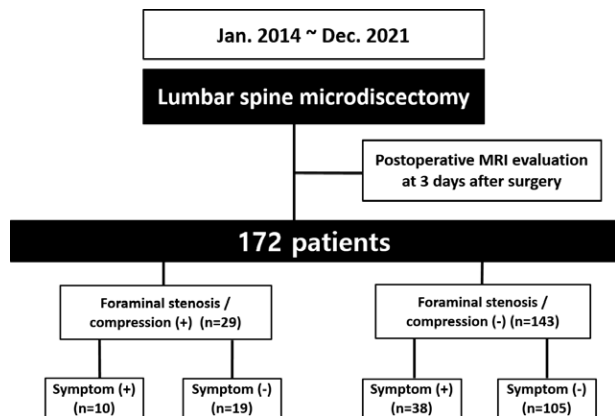


Figure 1. Schematic diagram showing the findings on immediate, postoperative MRI and number of patients with postoperative pain symptoms in the MRI positive and negative groups. MRI = magnetic resonance imaging.

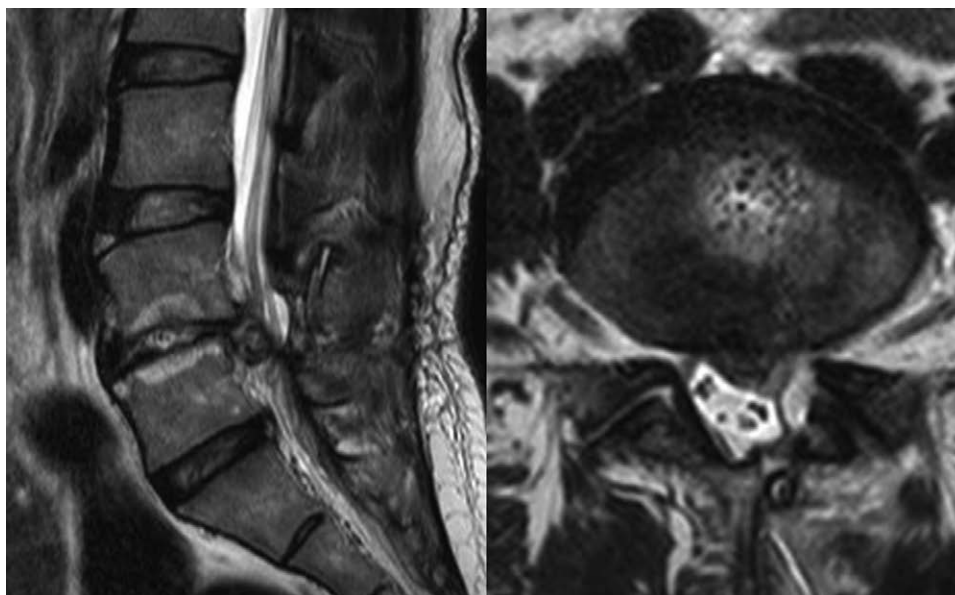


Figure 2. MRI positive case. Immediate, postoperative MRI in a patient who underwent partial hemilaminectomy and discectomy for a herniated lumbar disc showed that a disc left in the 4 to 5 lumbar spine on the MRI caused symptoms. MRI = magnetic resonance imaging.

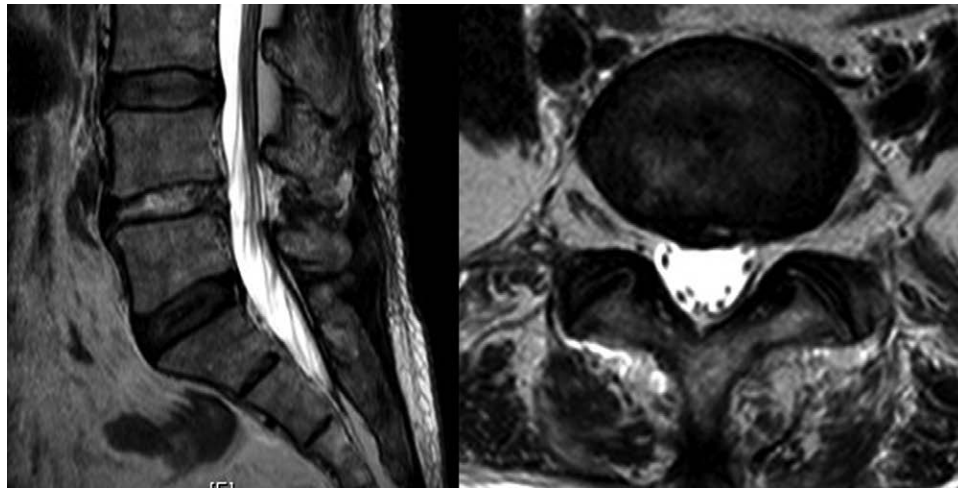


Figure 3. MRI negative case. A patient with a herniated lumbar disc underwent partial hemilaminectomy and discectomy. Upon immediate, postoperative MRI, there were no abnormal findings to explain his symptoms. MRI = magnetic resonance imaging.

from the lamina. A high-speed electric drill was used to perform a partial hemilaminectomy. When the dura was visible, the ruptured particles were removed by pulling the root with a root retractor. After confirming that the root was not pressed, saline irrigation was performed, followed by wound closure. All patients were able to sit and walk on the first postoperative day. Clinical and radiologic outcomes were noted by an independent observer for 3 days, postoperatively.

2.5. Statistical analysis

Our results are presented as mean ± standard deviation or counts, as indicated. We used the Chi-square test to test our hypothesis that postoperative MRI findings correlate with postoperative pain. We used the independent *t* test and the Chi-square test to test each variable to determine which one of the variables correlated with postoperative pain. Finally, we used the multiple regression test to determine which variables affected the postoperative pain independently. A *P* value < .05 was considered statistically significant. All statistical analyses were performed using IBM SPSS® Statistics version 23.0 (SPSS, Inc., Chicago, IL) and SAS version 9.2 (SAS, Cary, NC).

3. Results

3.1. Patient demographics

A total of 172 patients underwent primary lumbar spine microdiscectomy procedures at our institution. The demographic data are presented in Table 1. The study included 87 women (51%) and 85 men (49%), with ages ranging from 16 to 80 years old (mean age = 52.82 ± 16.93 years old). The mean postoperative follow-up duration was 25.7 ± 10.5 months (range 28–58 months). Herniation at the L4-5 level amounted to 51% (88/172) of the cases followed by the L5-S1 level (59 patients, 34%).

3.2. Comparative data between MRI positive and negative groups (Table 2)

Data on age, sex, intraoperative blood loss, operative time, duration of hospitalization, back-VAS, leg-VAS, ODI, and CCI of the 2 groups are shown in Table 2. Intraoperative bleeding and CCI were significantly different between the patients with positive and negative MRI scans. All clinical parameters improved

at follow-up (*P* < .0001). Between the MRI positive and negative groups, there were no significant differences in clinical outcomes. In the MRI positive group, 2 out of 10 symptomatic patients underwent reoperation, and the remaining 8 underwent conservative treatment, as did 19 asymptomatic patients in this group. In the MRI negative group, 38 patients with symptoms were treated conservatively in the pain clinic and showed gradual improvement in their symptoms; 105 asymptomatic patients in this group received conservative treatment.

3.3. MRI positive and symptom positive cases

Only 2 patients from the MRI positive group with positive clinical symptoms required revision surgery. The first patient had left leg pain (radicular pain). MRI performed 3 days postoperatively revealed hypointensity on T1 and T2-weighted images in the L4-5 level, suggesting a residual disc herniation with left foraminal stenosis at L4-5. This patient underwent revision surgery for removal of the residual herniated disc and root decompression. The second patient’s postoperative MRI showed a mixed density on T1 and T2 with left L5-S1

Table 1

Patient demographics.

Category	Number
Sex	
Male	85 (49%)
Female	87 (51%)
Mean age, yr	52.82 ± 16.93
BMI, kg/m ²	24.93 ± 3.76
Smoking	
Yes	30
No	142
DM	
Yes	22
No	150
Operation level	
L1/2	5 (3%)
L2/3	8 (5%)
L3/4	12 (7%)
L4/5	88 (51%)
L5/S1	59 (34%)

BMI = body mass index, DM = diabetes mellitus.

Downloaded from http://journals.lww.com/md-journal by BMDMSEPHKav12Eoum1QIN4a+kLHEZgbsIH04XMI0hCy WCX1AWWYQpIIOHHD33D00dRy7VVFAC3VCA/OAVDDa8KKGKv07my+78= on 03/18/2024

Table 2

Comparative data between MRI (+) and (–) group.

	MRI (+) (n = 29)		MRI (–) (n = 143)		P value
	Symptom (+) (n = 10)	Symptom (–) (n = 19)	Symptom (+) (n = 38)	Symptom (–) (n = 105)	
Age	53.40 ± 9.31	51.31 ± 15.56	47.97 ± 18.97	49.84 ± 17.16	.485
Sex					
Male	5	13	18	49	
Female	5	6	20	56	.574
Intraoperative blood loss (mL)	120.29 ± 99.54	87.57 ± 71.16	86.84 ± 40.28	73.44 ± 50.12	.018*
Operation time (min)	95.43 ± 34.64	82.84 ± 31.21	98.47 ± 23.37	73.90 ± 18.62	.052
Duration of hospitalization (d)	5.20 ± 3.64	5.53 ± 4.74	6.26 ± 7.91	5.28 ± 5.62	.673
Back VAS					
Preoperation	8.2 ± 0.45	8.3 ± 0.15	8.1 ± 0.27	8.2 ± 0.47	.316
Postoperation	3.1 ± 0.26**	2.7 ± 0.16**	3.9 ± 0.02**	2.8 ± 0.12**	.421
Last follow-up	1.9 ± 0.96**	1.7 ± 0.18**	1.2 ± 0.25**	1.7 ± 0.45**	.401
Leg VAS					
Preoperation	7.9 ± 0.23	8.1 ± 0.23	8.1 ± 0.72	8.4 ± 0.71	.217
Postoperation	3.7 ± 0.19**	2.7 ± 0.19**	3.6 ± 0.55**	2.6 ± 0.35**	.357
Last follow-up	1.5 ± 0.56**	1.2 ± 0.56**	1.4 ± 0.92**	1.3 ± 0.95**	.124
ODI					
Preoperation	35.7 ± 2.14	36.7 ± 1.89	34.7 ± 2.55	36.7 ± 3.45	.348
Postoperation	23.2 ± 1.77**	21.1 ± 1.97**	24.5 ± 1.76**	23.6 ± 2.56**	.248
Last follow-up	11.5 ± 1.46**	12.5 ± 1.36**	12.6 ± 1.31**	12.7 ± 1.25**	.478
CCI					
0	4	12	12	63	
1–2	6	7	26	42	.002*

CCI = Charlson comorbidity index, VAS = visual analogue scale.

*P < .05 comparing between MRI (+) and MRI (–).

**P < .05 compared with the preoperative value.

foraminal stenosis, suggesting a hematoma after surgery. The patient had left leg numbness and tingling. Revision surgery was performed to remove the hematoma. In the other 8 patients with positive symptoms, the pain gradually decreased with conservative treatment.

3.4. Multivariate analysis of the significant factors on postoperative pain (Table 3)

Significant factors that may potentially influence postoperative pain were analyzed using a logistic regression test; the outcomes are shown in Table 3. As influencing factors of postoperative pain, intraoperative blood loss and CCI were found to be statistically significant (P = .001 and .001, respectively).

4. Discussion

The benefit of routine, early, postoperative MRI after discectomy is still debated because literature shows that images of

the lumbosacral spine in the immediate postoperative period (the first 6–8 postsurgical weeks) must be interpreted with caution. Normal postoperative changes occur within the bones, as well as the soft tissues, and vary depending on the type and extent of surgery and the time since the operation^[11]; these can appear quite similar to the preoperative disc herniation.^[12] We performed this study to determine the benefits of routine, immediate, postoperative MRI, which was performed in patients with or without postoperative symptoms, and its correlation with postoperative symptoms and their management.

Our study showed that early postoperative MRI findings did not correlate with immediate postoperative pain (P = .421/.357). This finding is similar to some previous studies which state that immediate postoperative MRI is often similar to pre-operative MRI in symptomatic and asymptomatic patients. Matthew Crocker et al suggests that early MRI has great clinical value when managing the complicated postoperative lumbar spine, typically correlates with surgical findings, and strongly predicts appropriate management and favorable outcomes.^[8] In the immediate postoperative period, images show increased soft-tissue within the anterior epidural space accompanied by an indistinct annular margin due to tissue disruption, edema, and hemorrhage that are quite similar to and may mimic the preoperative disc herniation.^[12] The imaging must be interpreted in conjunction with the patient’s clinical state. The study by Matthew Crocker et al suggested that postoperative MRI, which is reserved for patients with ongoing, worsening, or new symptoms attributable to neural compression, was valuable in deciding whether to re-operate or manage the patient conservatively.^[8]

Our results demonstrate that patients with normal postoperative MRI findings can suffer from significant postoperative pain, which may become persistent, in several cases. Most cases of failed surgery were related to clinical versus technical issues. The surgery is a technical success, as the underlying

Table 3

Multivariate analysis of the significant factors on postoperative pain.

Factor	Odds ratio	95% CI	P value
Sex	0.978	0.658–1.453	.911
Age	1.191	0.814–1.742	.3672
Intraoperative blood loss	1.906	1.446–2.525	.001*
Operation time	1.365	0.702–2.654	.3594
Duration of hospitalization	1.023	0.673–1.554	.9164
CCI	1.352	1.124–1.72	.001*

CCI = Charlson comorbidity index.

*Statistically significant.

Downloaded from http://journals.lww.com/md-journal by BNDM5ePHKav1zEoum1QIN4a+kLHEZgbsIH04XMI0hCy WCX1AWWYQpIIQIHID33D00dFy7TVSF4C3VC4/OAVpDDa8KKGKv0Vmy+78= on 03/18/2024

pathophysiology has been corrected, but the patient continues to have pain despite such correction. The individual variability in pain has long been recognized, and pain is a multidimensional phenomenon that is largely subjective in nature. Although many studies report the benefits of spinal surgery, many patients who have undergone it report unsatisfactory results.^[13] In literature, the failure rates of spinal surgery vary among different studies ranging from 10% to 40%.^[14] This is often caused by surgical complications such as disc space infection, dural tear, or pseudomeningocele which are not seen on the immediate postoperative MRI.

Operative bleeding had a statistically significant correlation with postoperative pain ($P = .018$). It was previously mentioned in the literature that persistent pain after spinal surgery could be also caused by operative bleeding (hematoma).^[15] Andrew Bokov et al showed that one of the reasons for pain syndromes after surgical nerve root decompression is tissue damage (including hematoma) during the intervention.^[16] Although using a microscope and a good hemostat can minimize tissue damage during microdiscectomy, a considerable rate of radicular pain associated with fibrosis in the epidural space has been reported after open surgery.^[16] A high amount of bleeding will increase the risk of fibrosis in the epidural space during the healing process. This study suggested that the spine surgeon should opt for less invasive interventions in order to diminish the rate of pain syndromes associated with tissue damage.^[16]

Andrew Bokov et al also showed that the persistent pain syndrome is related to the naturally determined disease development such as facet joint pain, stenosis, and segment instability.^[16] This study reports that the overall prevalence of facet joint pain was 31%, with a 95% CI of 28% to 33%; the rate of this source of pain after lumbar surgery was 16%, with a 95% CI of 9% to 23%. A higher frequency of facet joint pain was expected in the group treated with microdiscectomy due to a more significant loss of disc height, yet there was no relationship between the pain source and the type of surgery. This is the result of altered biomechanics after spinal surgery. The other causes of persistent pain after surgery includes spondylolisthesis, nerve damage due to nerve root retraction, direct damage or arachnoiditis, and myofascial pain caused by altered biomechanics, muscular atrophy or weakness. Myofascial pain is known to be caused by multiple factors. The results of different studies have supported the hypothesis that myofascial pain may contribute to failed back surgery syndrome.^[17]

CCI also showed a correlation with postoperative pain ($P = .002$). These patients have complex multidisciplinary needs and in order to be successfully treated, they would need more than a single specialty modality of care.^[14] The development of postoperative pain to chronic pain is influenced by physical, psychological, and social factors. In the case of spinal surgery, Block and colleagues suggested that psychological factors have an even greater impact on outcomes than medical factors. Patients with a hyporeactive hypothalamic–pituitary–adrenal axis are at an increased risk for poor outcomes after disc surgery.^[15]

An analysis of all variables that may be affecting postoperative pain in patients with positive and negative MRI results, using a multivariate regression test, revealed that intraoperative bleeding and CCI independently affect postoperative pain ($P = .001$ and $.001$, respectively). As mentioned above, there was a risk of tissue and nerve damage due to nerve root retraction during the operation, which causes postoperative pain.^[16] It is known that manipulation or traction during surgery can result in more intraoperative bleeding and a higher the risk of tissue and nerve damage.

5. Limitations

The limitations of this study include postoperative MRI assessments based only on the presence of dural compression

and foraminal stenosis, not including other parameters such as the dorsal root ganglion position, disc height, contour, and signal intensity and variation in patients during the follow-up period. And comparison should have been made between symptomatic and asymptomatic patients with similar MRI findings. And type of disc, the number of surgeons involved in surgery, preoperative conditions, and differences in preoperative MRI findings are not considered. And postoperative residual discs indicate insufficient preoperative planning. This is a hindrance to real results. The subjective nature of patients' pain complaints is also a limitation of this study.

6. Conclusion

Routine, immediate, postoperative MRI for all patients, with or without symptoms, after microdiscectomy did not represent the actual condition of the patient. Intraoperative bleeding and CCI correlated with postoperative pain and may be the factors that affect persistent postoperative pain, even when the MRI revealed no significant abnormality.

Acknowledgments

All authors made substantive intellectual contributions to this study to qualify as authors. Noh and, SH Kim contributed to study design, acquisition of data, analysis of data, and interpretation of results. Ndraha, Shin, Cho, KN Kim contributed to discuss the article. All authors read and approved the final manuscript.

Author contributions

Conceptualization: Sung Hyun Noh.

Data curation: Sung Hyun Noh.

Formal analysis: Sung Hyun Noh.

Investigation: Sung Hyun Noh.

Methodology: Sung Hyun Noh.

Project administration: Sung Hyun Noh.

Resources: Sung Hyun Noh.

Software: Sung Hyun Noh.

Supervision: Eveline Ndraha, Dong Ah Shin, Pyung Goo Cho, Keung Nyun Kim, Sang Hyun Kim.

Validation: Sung Hyun Noh.

Visualization: Sung Hyun Noh.

Writing – original draft: Sung Hyun Noh.

Writing – review & editing: Sung Hyun Noh.

References

- [1] Kim DK, Oh CH, Lee MS, et al. Prevalence of lumbar disc herniation in adolescent males in Seoul, Korea: prevalence of adolescent LDH in Seoul, Korea. *Korean J Spine*. 2011;8:261–6.
- [2] Ma D, Liang Y, Wang D, et al. Trend of the incidence of lumbar disc herniation: decreasing with aging in the elderly. *Clin Interv Aging*. 2013;8:1047–50.
- [3] Urban JPG, Roberts S. Degeneration of the intervertebral disc. *Arthritis Res Ther*. 2003;5:120–30.
- [4] Jordan J, Konstantinou K, O'Dowd J. Herniated lumbar disc. *BMJ Clin Evid*. 2011;2011:1118.
- [5] Lurie JD, Facett SC, Hanscom B, et al. Lumbar discectomy outcomes vary by herniation level in the spine patient outcomes research trial. *J Bone Joint Surg Am*. 2008;90:1811–9.
- [6] Herrera Herrera I, Moreno de la Presa R, González Gutiérrez R, et al. Evaluation of the postoperative lumbar spine. *Radiologia*. 2013;55:12–23.
- [7] Milette PC. Classification, diagnostic imaging, and imaging characterization of a lumbar herniated disk. *Radiol Clin North Am*. 2000;38:1267–92.

- [8] Crocker M, Jones TL, Rich P, et al. The clinical value of early postoperative MRI after lumbar spine surgery. *Br J Neurosurg.* 2010;24:46–50.
- [9] Boos N, Rieder R, Schade V, et al. 1995 Volvo Award in Clinical Sciences. The diagnostic accuracy of magnetic resonance imaging, work perception, and psychosocial factors in identifying symptomatic disc herniations. *Spine (Phila Pa 1976).* 1995;20:2613–25.
- [10] Charlson ME, Pompei P, Ales KL, et al. A new method of classifying prognostic comorbidity in longitudinal studies: development and validation. *J Chron Dis.* 1987;40:373–83.
- [11] Van Goethem JW, Parizel PM, Jinkins JR. Review article: MRI of the postoperative lumbar spine. *Neuroradiology.* 2002;44:723–39.
- [12] Babar S, Saifuddin A. MRI of the post-discectomy lumbar spine. *Clin Radiol.* 2002;57:969–81.
- [13] Epker J, Block AR. Psychological screening before spine surgery: avoiding failed surgery syndrome. *Psychol Inj Law.* 2014;7:317–24.
- [14] Thomson S. Failed back surgery syndrome—definition, epidemiology and demographics. *Br J Pain.* 2013;7:56–9.
- [15] Hinrichs-Rocker A, Schulz K, Järvinen I, et al. Psychosocial predictors and correlates for chronic post-surgical pain (CPSP)—a systematic review. *Eur J Pain.* 2009;13:719–30.
- [16] Bokov A, Isrelov A, Skorodumov A, et al. An analysis of reasons for failed back surgery syndrome and partial results after different types of surgical lumbar nerve root decompression. *Pain Phys.* 2011;14:545–57.
- [17] Turner JA, Ersek M, Herron L, et al. Patient outcomes after lumbar spinal fusions. *J Am Med Assoc.* 1992;268:907–11.