

## RESEARCH

# Prognostic factors to predict the efficacy of surgical interventions against brain metastasis secondary to thyroid cancer

Jihwan Yoo<sup>1,2,\*</sup>, Hee Jun Kim<sup>3,\*</sup>, Seok Mo Kim<sup>4</sup> and Hun Ho Park<sup>ID1</sup><sup>1</sup>Department of Neurosurgery, Brain Tumor Center, Gangnam Severance Hospital, Seoul, Republic of Korea<sup>2</sup>College of Medicine, Yonsei University, Seoul, Republic of Korea<sup>3</sup>Department of Surgery, CHA Ilsan Medical Center, Cha University School of Medicine, Goyang-si, Republic of Korea<sup>4</sup>Department of Surgery, Thyroid Cancer Center, Gangnam Severance Hospital, Institute of Refractory Thyroid Cancer, Yonsei University College of Medicine, Seoul, Republic of KoreaCorrespondence should be addressed to S M Kim or H H Park: [SEOKMOKIM@yuhs.ac](mailto:SEOKMOKIM@yuhs.ac) or [nshhp@yuhs.ac](mailto:nshhp@yuhs.ac)

\*J Yoo and H J Kim contributed equally to this work)

## Abstract

**Introduction:** Brain metastasis in differentiated thyroid cancer (DTC) is rare (frequency < 1%) and has a poor prognosis. Treatment strategies for brain metastasis are not well established.

**Objectives:** We conducted a retrospective analysis to identify predictive factors for patient outcomes and verify surgical indications for patients with brain metastasis and DTC.

**Methods:** The study included 34 patients with pathologically confirmed DTC with brain metastasis from March 2008 to November 2020. The associations between overall survival (OS) and clinical factors were evaluated. Cox regression analysis was used to determine the relationship between clinical factors and OS. To assess the survival benefit of craniotomy, Kaplan–Meier survival analysis was performed for each variable whose statistical significance was determined by Cox regression analysis.

**Results:** The median OS of the entire patient sample was 11.4 months. Survival was affected by the presence of lung metastasis ( $P = 0.033$ ) and the number of brain metastases ( $n > 3$ ) ( $P = 0.039$ ). Only the subgroup with the number of brain metastases  $\leq 3$  showed statistical significance in the subgroup analysis of survival benefit following craniotomy ( $P = 0.048$ ).

**Conclusions:** The number of brain metastases and the existence of lung metastasis were regarded more essential than other clinical factors in patients with DTC in this study. Furthermore, craniotomies indicated a survival benefit only when the number of brain metastases was  $\leq 3$ . This finding could be beneficial in determining surgical indications in thyroid cancer with brain metastasis.

## Key Words

- ▶ differentiated thyroid carcinoma
- ▶ brain metastasis
- ▶ craniotomy
- ▶ prognosis
- ▶ surgical indication

## Introduction

Patients with differentiated thyroid cancer (DTC) generally have a good prognosis, even in cases of stage IV disease. The 10-year disease-specific survival rate is 82.6%, which is longer than that among patients with other carcinoma types (1). However, 0.15–1.3% of patients with thyroid cancer develop brain metastasis with a median survival

time of 4–33 months (2, 3, 4, 5, 6). The treatment options for such patients include surgical resection, stereotactic radiosurgery, and radiotherapy (7).

Surgical resection has been reported as an independent factor associated with better outcomes (8). The major goals of craniotomy for brain metastasis are tumor debulking,

minimizing the vasogenic edema, relieving neurological symptoms, securing local control of lesions, and improving patient survival (OS) (9, 10, 11). Level 1 evidence suggests that patients with a single brain metastasis have improved outcomes with combined surgical resection and whole-brain radiation therapy (12). However, in practice, treatment modalities are often determined by the patient's clinical situation.

Circumstances among patients with thyroid cancer brain metastasis (TCBM) can differ widely and have unanticipated effects on treatment. This lack of understanding impedes the determination of an optimal therapeutic strategy for patients with TCBM, particularly for craniotomy. This retrospective cross-sectional study aimed to assess prognostic factors in patients with TCBM and to identify the factors that influence the selection of suitable patients for craniotomy.

## Materials and methods

### Patients

We included patients in whom DTC with brain metastasis was diagnosed from March 2008 to November 2020 at our institute. Patients with medullary or anaplastic thyroid cancer were excluded from the study. Primary DTC was pathologically confirmed in all study participants. Brain metastasis was evaluated in patients with newly developed neurologic symptoms and diagnostically confirmed through MRI. Data on the following clinical factors were collected: age, sex, time interval between diagnosis of thyroid cancer and brain metastasis, Eastern Cognitive Oncology Group (ECOG) performance score (13), treatment (radioactive iodine (RAI) therapy, tyrosine kinase inhibitor (TKI), or radiotherapy), coexisting distant metastases and their location, and radiologic characteristics of brain metastasis observed on brain MRI (maximum diameter, multiplicity, intratumoral hemorrhage, and number of brain metastases).

Progressive thyroid cancer was preferentially treated with RAI therapy; TKIs, including sorafenib or lenvatinib, were administered when the cumulative RAI dose exceeded 600 mCi. Following the confirmation of brain metastasis, a craniotomy was performed in the following situations: (i) single metastasis with lesion size >1 cm; (ii) multiple metastases with lesion >3 cm in size; or (iii) multiple metastases with severe cerebral edema, or intratumoral hemorrhage, causing neurologic deterioration (14). Adjuvant systemic chemotherapy including TKI and

radiotherapy was considered, and treatment was decided based on each patient's clinical status. The OS was measured from the time when brain metastasis was diagnosed.

### Statistical analyses

Age, ECOG performance status, and number of brain metastases were converted into categorical variables to facilitate clinical applications, as described in a previous study (15). A Cox regression model was created to implement univariate and multivariate analyses. Univariate Cox regression analysis was performed to identify statistically significant variables associated with patient survival. These significant variables were analyzed using a multivariate Cox regression analysis. Kaplan–Meier (K–M) survival analysis was performed to verify the statistically significant findings from the univariate and multivariate regression analyses. Finally, a total of four subgroups were created according to the number of brain metastases and coexisting lung metastasis. The survival benefit was assessed using K–M survival analysis in each subgroup based on whether craniotomy was performed. *P* value of <0.05 was considered statistically significant. All statistical analyses were conducted using R Statistical Software version 4.1.0 (R Foundation for Statistical Computing, Vienna, Austria).

## Results

### Patient demographics

The demographic characteristics of the study population are summarized in Table 1. A total of 34 patients (23 women) were included in the study. The median age at which brain metastasis was detected was 69.1 (range, 39.9–84.6) years. The median interval from initial thyroid cancer diagnosis to discovery of brain metastasis was 121.7 (range, 2.3–381.7) months. Prior to brain metastasis, 13 patients (38.2%) received TKI (sorafenib or lenvatinib), whereas no patients underwent conventional cytotoxic chemotherapy. At the time of brain metastasis, metastases to other organs were detected in 27 patients (79.4%); of these, 25 (73.5%) exhibited lung metastasis, while 16 (47.1%) patients showed bone metastasis and 1 (2.9%) showed liver metastasis. The most common site of brain metastasis was the frontal lobe (19, 55.9%), followed by the cerebellum (11, 32.4%) and temporal lobe (10, 29.4%). The median size of the brain metastasis was 17.8 (range, 2.9–92.1) mm. At the time of brain metastasis diagnosis, 23 patients (65.7%) had more

**Table 1** Patient demographics.

Characteristics	(n = 34)
Age at diagnosis of BM, years, median (range)	69.1 (39.9–84.6)
Time from diagnosis of TC to BM, months, median (range)	121.7 (2.3–381.7)
Sex, female, n (%)	23 (67.6)
Overall survival, months, median (range)	11.4 (6.8–42.5)
Histology, n (%)	
Papillary	30 (88.2)
Follicular	4 (11.8)
Location, n (%)	
Frontal	19 (55.9)
Temporal	10 (29.4)
Parietal	8 (23.5)
Occipital	4 (11.8)
Cerebellum	11 (32.4)
Leptomeningeal seeding	3 (8.8)
Others	3 (8.8)
Tyrosine kinase inhibitor before BM, n (%)	13 (38.2)
Conventional cytotoxic agents before BM, n (%)	0 (0.0)
RAI therapy before BM, n (%)	31 (91.2)
Distant metastasis at BM diagnosis, n (%)	27 (79.4)
Lung	25 (73.5)
Liver	1 (2.9)
Bone	16 (47.1)
BM multiplicity, n (%)	23 (67.6)
Maximum size of BM, mm, median (range)	17.8 (2.9–92.1)
Intratumoral hemorrhage at BM, n (%)	8 (23.5)
Craniotomy for BM, n (%)	12 (35.3)
Radiotherapy for BM, n (%)	18 (52.9)
Chemotherapy for BM (conventional or TKI), n (%)	13 (38.2)

BM, brain metastases; RAI, radioactive iodine; TC, thyroid cancer.

than 1 intracranial metastasis. Intratumoral hemorrhage was observed in 8 patients (23.5%).

### Clinical factors affecting survival

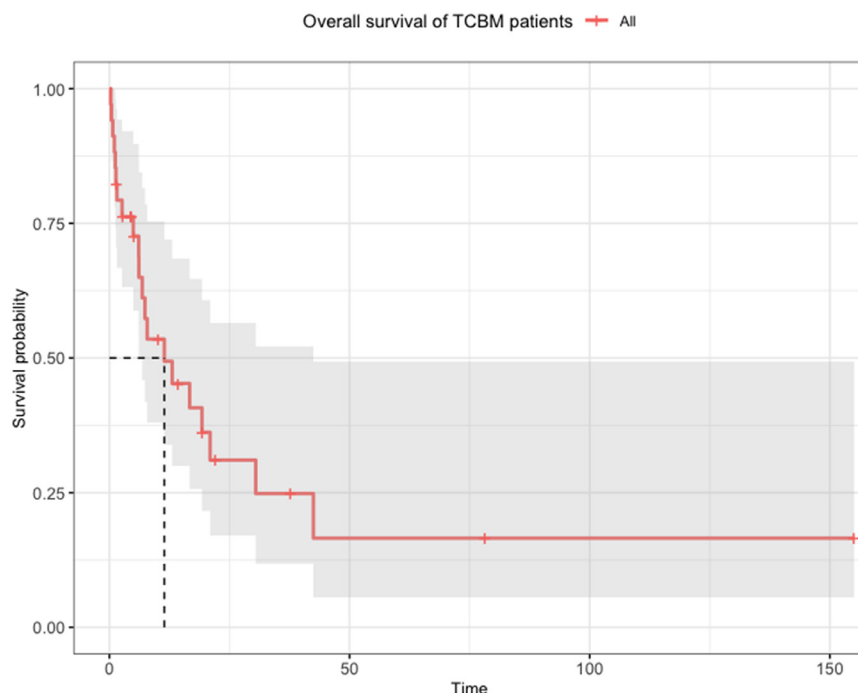
The median OS was 11.4 (range, 0.3–155.1) months (Fig. 1). Only coexistence of lung metastasis ( $P = 0.002$ ) and number of brain metastases ( $n > 3$ ) ( $P = 0.025$ ) showed statistically significant values on the univariate Cox regression analysis (Table 2). Age, ECOG, and coexisting distant metastasis have been reported to be significant factors affecting the patient OS but showed no significant relationships in the context of this study (15). Only the coexisting lung metastasis showed significant differences in survival among distant metastases. Pathologic subtypes (papillary vs non-papillary) and radiologic factors, such as intratumoral hemorrhage or the diameter of the brain metastasis, had no effect on survival among the variables studied. The two significant factors identified in univariate Cox regression analysis, coexisting lung metastasis and the number of brain metastases, were used in multivariate Cox regression analysis. Statistical significance was observed in both coexisting lung metastasis and the number of

brain metastases ( $n > 3$ ), as in multivariate Cox regression analysis. The hazard ratio for OS for each factor is as follows: coexisting lung metastasis, 3.861 (1.118–13.338,  $P = 0.033$ ) and number of brain metastases ( $n > 3$ ), 2.743 (1.055–7.134,  $P = 0.039$ ).

The coexisting lung metastasis, number of brain metastases, and craniotomy were also observed to have statistically significant effects on OS in K–M survival analysis (Fig. 2). Patients with coexisting lung metastasis had a median survival of 6.8 months, compared to 42.5 months for those without lung metastasis ( $P = 0.015$ ). Patients with more than three brain metastases had a median survival of 6.1 month, whereas those with three or fewer brain metastases had a median survival of 21.0 month ( $P = 0.020$ ). Patients who underwent craniotomies had a median survival time of 30.5 months, while those who did not undergo a craniotomy had a median survival time of 6.8 months ( $P = 0.035$ ).

### Craniotomy

A craniotomy was performed in 12 patients with single ( $n = 7$ ) and multiple ( $n = 5$ ) brain lesions (Table 3). Only



**Figure 1**  
Overall survival plot for all 34 patients with thyroid cancer with brain metastasis. Median overall survival, 11.4 months; range, 0.8–155.1 months.

in the subgroup that included patients with the number of brain metastases  $\leq 3$ , craniotomy showed a statistically significant survival benefit ( $P=0.048$ ) (Fig. 3A). In this subgroup, patients who underwent craniotomy had a median survival of 42.47 months, and those who did not undergo craniotomy had a median survival of 6.83 months. No other subgroups suggested any significant benefits from the craniotomy (Fig. 3B, C and D). In the subgroup of patients with brain metastases  $> 3$ , the patients who underwent craniotomy showed a median survival of 6.8 months, which was more disadvantageous than the median survival of 7.03 months in patients who did not undergo craniotomy ( $P=0.95$ ).

## Discussion and conclusion

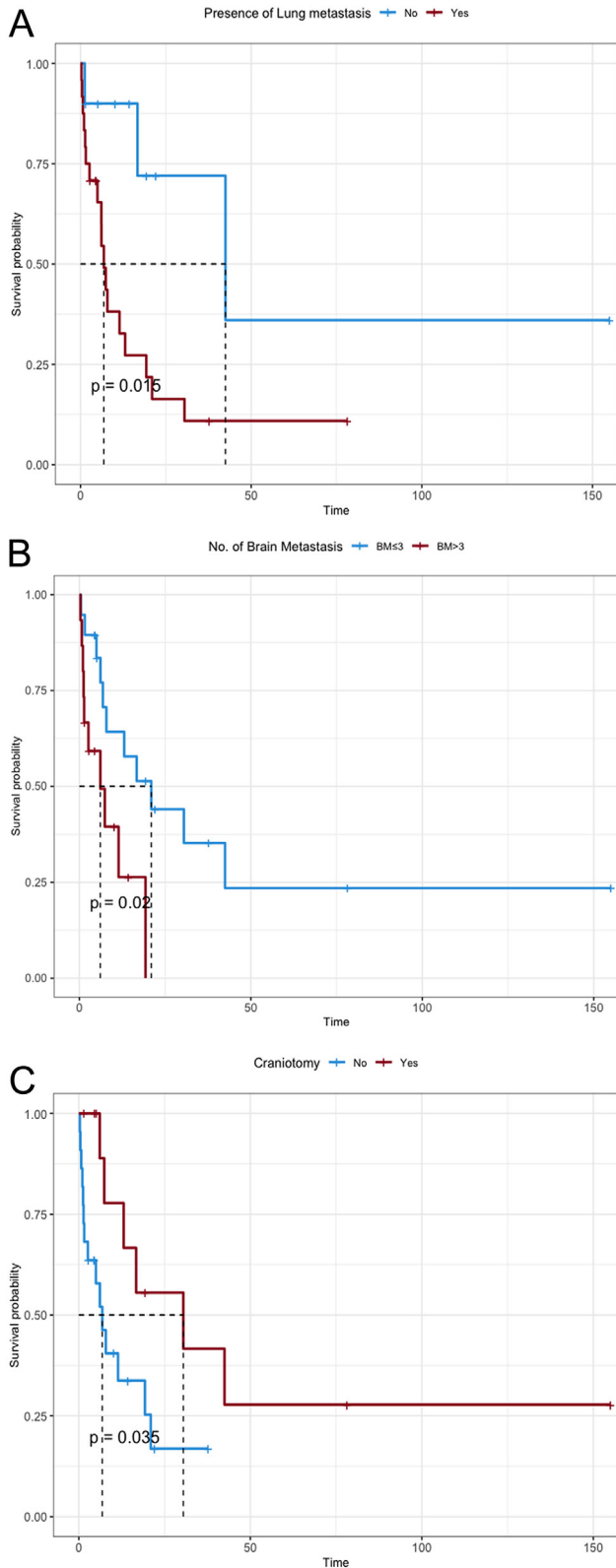
In this retrospective study, we evaluated the risk factors for TCBM diagnosed in 34 patients from 2008 to 2020 and subsequently analyzed the data of 12 patients who underwent craniotomy. The median OS was 11.4 months, and the statistically significant variables in the Cox regression analysis were the coexisting lung metastasis and the number of brain metastases. However, age and ECOG score, which were reported as risk factors in a previous study, did not exhibit statistical significance in this study (15). Furthermore, when the K–M survival analysis was used to perform subgroup analysis for two variables that were

**Table 2** Univariate and multivariate Cox regression analyses for each variable.

Factors	Univariate analysis		Multivariate analysis	
	(P value)	Hazard ratio (95% CI)	(P value)	Hazard ratio (95% CI)
Sex (male)	0.304	1.596 (0.655–3.891)		
Age > 60 years	0.621	0.802 (0.336–1.919)		
ECOG score >2	0.338	1.651 (0.592–4.604)		
Pathology (non-papillary)	0.310	1.908 (0.548–6.641)		
Prior chemotherapy	0.262	1.756 (0.656–4.7)		
Prior RAI therapy	0.963	0.965 (0.216–4.307)		
Coexisting lung metastasis	0.002 <sup>a</sup>	4.119 (1.196–14.18)	0.033 <sup>a</sup>	3.861 (1.118–13.338)
Coexisting distant metastasis	0.149	2.927 (0.680–12.6)		
Number of BM ( $n > 3$ )	0.025 <sup>a</sup>	3.007 (1.146–7.891)	0.039 <sup>a</sup>	2.743 (1.055–7.134)
Maximum diameter of BM > 3 cm	0.656	0.755 (0.218–2.603)		
Intratumoral hemorrhage	0.232	1.799 (0.687–4.713)		

<sup>a</sup> $P < 0.05$ .

BM, brain metastases; ECOG, European Clinical Oncology Group; RAI, radioactive iodine.



**Figure 2**  
Kaplan-Meier curves by each variable. Statistical significance is exhibited in cases with presence of lung metastasis ( $P = 0.015$ , A), the number of brain metastases ( $n > 3$ ,  $P = 0.02$ , B), and craniotomy ( $P = 0.035$ , C).

meaningfully identified through Cox regression analysis, only patients with brain metastases  $\leq 3$  demonstrated a clear survival benefit from craniotomy.

There have been various efforts to evaluate the prognosis of brain metastasis. In 1997, Gaspar *et al.* conducted a recursive partitioning analysis (RPA) of the radiation therapy oncology group (RTOG) studies by analyzing the data of 1200 patients (16). The analysis showed that Karnofsky performance status score, primary site status, age, and status of metastases to other organs were factors that significantly impacted prognostic outcomes in patients with brain metastasis; this was the basis for categorizing patients into classes I, II, and III, with median survival values of 7.1, 4.2, and 2.3 months, respectively (16). In 2012, inheriting previous RPA analysis, a graded prognostic assessment (GPA) system was published by analyzing 1960 patients included in the RTOG database (five randomized RTOG studies: protocol 7916, 8528, 8905, 9104, and 9508) (17). According to the GPA system, patients were classified into four classes based on age, performance status, the number of brain metastases, and extracranial metastases; the OS was as follows: GPA 0–1, 2.6 months; GPA 1.5–2.5, 3.8 months; GPA 3, 6.9 months; and GPA 3.5–4, 11.0 months. Recently, a prognostic prediction system for cancers, including lung cancer, melanoma, breast cancer, renal cell carcinoma, and gastrointestinal cancer, was reported based on diagnosis-specific GPA indices (18), which was later refined according to biomolecular subtypes for some carcinomas (1, 19, 20). However, these recent changes have not been applied for the prognosis of patients with thyroid cancer. This is probably due to the rarity of brain metastasis in thyroid cancer, which makes analysis difficult.

Although there is clear level 1 evidence indicating radiation therapy after surgical resection for well-controlled primary cancer with a single metastatic brain lesion, it is rare to encounter such an ideal situation in clinical practice (12). The efficacy of surgical treatment in this situation has not yet been objectively proven beneficial to the patient. Bindal *et al.* demonstrated a statistically significant survival benefit when all tumors were surgically removed in multiple brain metastases, compared to those with residual tumors and a similar median survival to patients with a single metastasis (21). Neurosurgical interventions are advantageous because they can provide immediate results in cases of mass effects, edema, and hemorrhagic presentation (9). In addition, removal of the tumor through craniotomy has the effect of cytoreduction, which allows for a rapid tapering of steroids and less intensive follow-up (14).

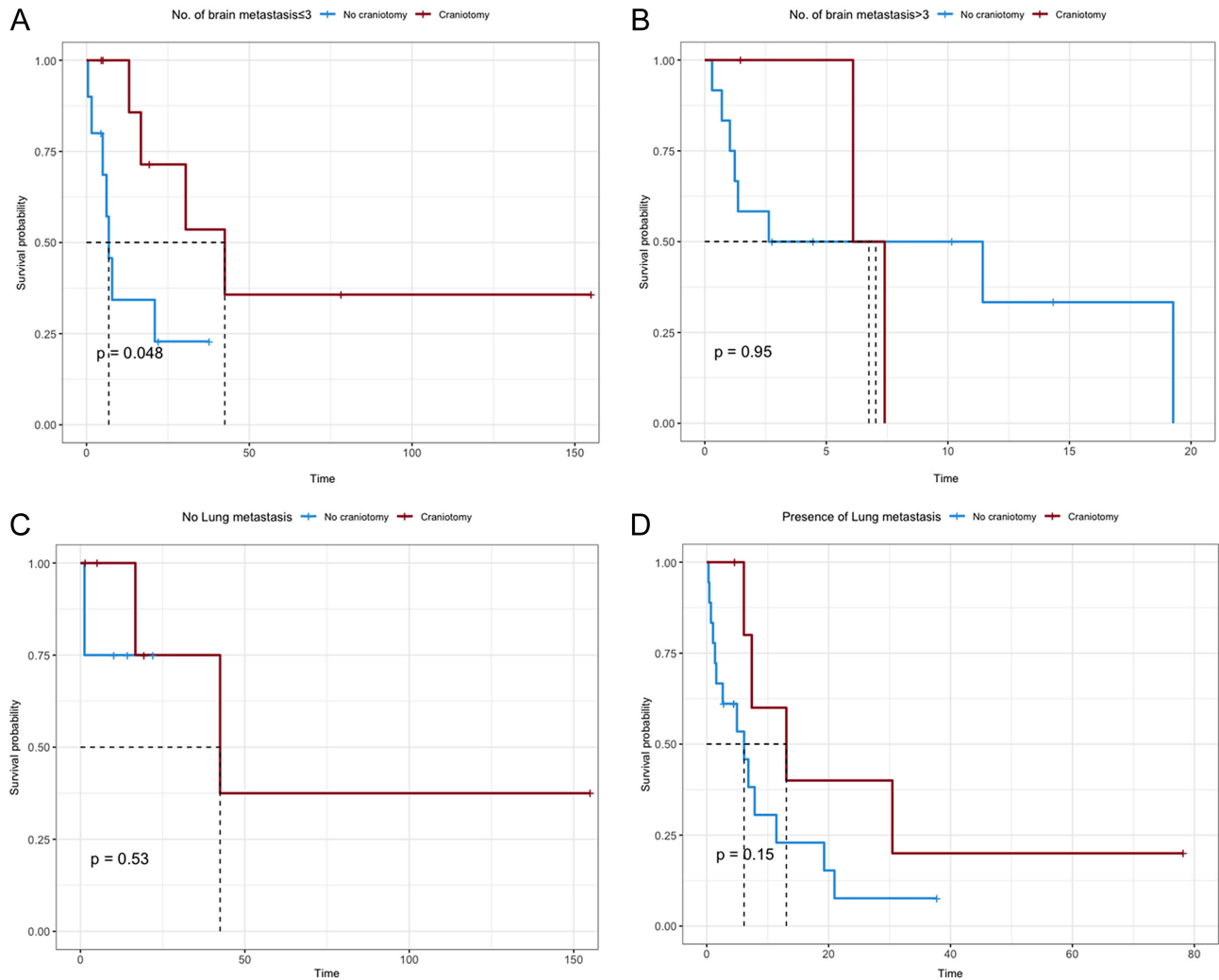
**Table 3** Characteristics of patients who underwent craniotomy.

Patient number	Histology	Chief complaint	Coexisting metastatic lesion	Number of BM	Size	Tumor bleeding	EOR	Blood loss	Operative time	Adjuvant therapy	Current status	Overall survival
1	Papillary	Incidental finding	None	1	53.57	0	GTR	2400	180	None	AWD	155.1
2	Follicular	Headache	Bone	3	92.05	0	STR	1500	238	WBRT+TKI	AWD	19.4
3	Papillary	Memory impairment	Lung	4	22.39	0	GTR	200	97	WBRT	DOD	7.4
4	Papillary	Left-sided weakness	None	3	27.51	0	GTR	1150	291	None	DOD	16.7
5	Papillary	Sensory aphasia	Lung	1	2.87	0	GTR	60	157	WBRT	AWD	75.5
6	Papillary	Headache	Lung	1	36.23	0	PR	1200	N/A	WBRT+TKI	AWD	4.6
7	Papillary	Right-sided weakness	Lung	1	5.5	1	GTR	1300	525	WBRT+TKI	DOD	30.5
8	Papillary	Gait disturbance	None	4	41.1	0	GTR	1000	322	WBRT	AWD	1.5
9	Papillary	Right-sided weakness	Lung	1	17.31	0	GTR	500	235	WBRT	DOD	13.1
10	Papillary	Left-sided weakness	Lung	12	22.99	1	GTR	850	291	None	DOD	6.1
11	Follicular	Incidental finding	Bone	1	29.92	0	GTR	250	177	TKI	DOD	42.5
12	Papillary	Seizure	None	1	23.56	0	GTR	100	150	WBRT+TKI	AWD	3.0

AWD, alive with the disease; BM, brain metastasis; DOD, died due to the disease; EOR, extent of resection; GTR, gross total resection; PR, partial resection; STR, subtotal resection; TKI, tyrosine kinase inhibitor; WBRT, whole brain radiation therapy.

Data on the efficacy of targeted agents in brain metastasis of DTC are limited. In two phase III trials (DECISION and SELECT) in RAI-refractory thyroid cancer, sorafenib and lenvatinib have been widely used, showing a clear increase in progression-free survival (22, 23). However, given the rarity of brain metastasis due to DTC, it is unlikely that a prospective study will be conducted, and a few retrospective studies have been published. Shen *et al.* reported a case of clinical and radiological improvement in a patient with brain metastases from follicular thyroid cancer following treatment with Sorafenib (24). In a study involving 24 patients with brain metastasis from DTC, Gomes-Lima *et al.* found that the TKI agent significantly increased survival in 12 patients (25). Recently, the effect of selective kinase inhibitors on diverse DTC targets has been reported (26). Variable percentages of DTC patients (2–25%) have been reported to have neurotrophic tropomyosin receptor kinase (NTRK) fusions (27). In a pooled analysis of 1/2 clinical trials, 79% of 24 patients with DTC bearing an NTRK fusion who received larotrectinib demonstrated an objective response (28). Pitoia reported a complete response to larotrectinib in a patient with RAI refractory DTC who had a rapid progression on TKI therapy and the disappearance of multiple brain metastases (29). Additionally, it is known that 5–25% of DTCs contain RET rearrangements (26). In the open-label, phase 1/2 clinical trial, 20 RET-fusion-positive thyroid cancer patients were included, showing an overall response rate (ORR) of 89% (30). Wirth *et al.* reported a comparable response rate in a selpercatinib study, with an ORR of 79% in the subgroup of patients with RET-positive thyroid cancer (31). In studies on selpercatinib for lung cancer, intracranial efficacy has been illustrated, but efficacy for thyroid cancer has not yet been reported (32). The intracranial efficacy of novel therapeutics is thought to be decisive in determining surgical indications in the future.

This study has several limitations. First, the sample size was small because it consisted of only TCBM patients treated at a single institution. Particularly, the analysis performed in the subgroup that underwent craniotomy should be interpreted with caution, as only 12 patients were included. However, given the rarity of TCBM, it is difficult to obtain sufficient subjects to demonstrate the effectiveness of craniotomy. Therefore, it is believed that there will be a small but clear significance in providing information to clinicians considering craniotomy. Secondly, our results are different from those reported previously. While age and performance status have been reported to affect patient outcomes, we found that these factors did not have a significant effect on our study population (15). Further



**Figure 3**

Survival benefit from craniotomy in each subgroup. (A) When the number of brain metastases (BM) was three or less, craniotomy provided a statistically significant survival benefit ( $P = 0.048$ ). (B) In the presence of more than three BMs, craniotomy showed no survival benefit ( $P = 0.95$ ). (C) In the absence of lung metastasis, craniotomy did not reach statistical significance ( $P = 0.53$ ). (D) Craniotomy did not reach statistical significance in the presence of lung metastasis ( $P = 0.15$ ).

integrative research using a larger study population and a more comprehensive study design, such as meta-analysis, would help validate these findings.

In conclusion, while patients with thyroid cancer have a good prognosis, those with TCBM have a poor prognosis with a short survival period. According to the study findings, the factors affecting prognostic outcomes are not directly analogous to the existing GPA system and coexisting lung metastasis, and the number of brain metastases is thought to be important for patient survival. Furthermore, the number of brain metastases is important in determining craniotomy candidacy and is regarded as the prime clinical factor in determining the therapeutic strategy.

**Declaration of interest**

The authors declare that there is no conflict of interest that could be perceived as prejudicing the impartiality of the research reported.

**Funding**

This work did not receive any specific grant from any funding agency in the public, commercial, or not-for-profit sector.

**Statement of ethics**

*Study approval statement:* All procedures performed in this study involving human participants complied with the ethical standards of the institutional and/or national research committee and with the 1964 Helsinki Declaration and its later amendments or comparable ethical standards. The study was approved by the Institutional Review Board (3-2021-0185) of the Gangnam Severance Hospital. *Consent to participate statement:* The requirement for

informed consent was waived because patient records were anonymized and de-identified before analysis.

#### Data availability statement

All data supporting the conclusions of this article are available from the corresponding authors upon reasonable request.

#### Author contribution statement

Jihwan Yoo: drafting, formal analysis, and submission of the article; Hee Jun Kim: data curation and formal analysis; Seok Mo Kim: methodology and supervision; Hun Ho Park: supervision, review, and concept. J Yoo and H J Kim contributed equally to this work as first authors. S M Kim and H H Park are co-corresponding authors.

#### Acknowledgement

The authors would like to thank Editage ([www.editage.co.kr](http://www.editage.co.kr)) for English language editing.

## References

- 1 Tam S, Boonsripitayanon M, Amit M, Fellman BM, Li Y, Busaidy NL, Cabanilas ME, Dadu R, Sherman S, Waguespack SG, et al. Survival in differentiated thyroid cancer: comparing the AJCC cancer staging seventh and eighth editions. *Thyroid* 2018 **28** 1301–1310. (<https://doi.org/10.1089/thy.2017.0572>)
- 2 Parker LN, Wu SY, Kim DD, Kollin J & Prasasvinichai S. Recurrence of papillary thyroid-carcinoma presenting as a focal neurologic deficit. *Archives of Internal Medicine* 1986 **146** 1985–1987. (<https://doi.org/10.1001/archinte.1986.00360220145025>)
- 3 Hjiyiannakis P, Jefferies S & Harmer CL. Brain metastases in patients with differentiated thyroid carcinoma. *Clinical Oncology* 1996 **8** 327–330. ([https://doi.org/10.1016/s0936-6555\(05\)80722-8](https://doi.org/10.1016/s0936-6555(05)80722-8))
- 4 Blankenship DR, Chin E & Terris DJ. Contemporary management of thyroid cancer. *American Journal of Otolaryngology* 2005 **26** 249–260. (<https://doi.org/10.1016/j.amjoto.2005.01.019>)
- 5 Kim IY, Kondziolka D, Niranjan A, Flickinger JC & Lunsford LD. Gamma knife radiosurgery for metastatic brain tumors from thyroid cancer. *Journal of Neuro-Oncology* 2009 **93** 355–359. (<https://doi.org/10.1007/s11060-008-9783-2>)
- 6 de Figueiredo BH, Godbert Y, Soubeyran I, Carrat X, Lagarde P, Cazeau AL, Italiano A, Sargos P, Kantor G, Loiseau H, et al. Brain metastases from thyroid carcinoma: a retrospective study of 21 patients. *Thyroid* 2014 **24** 270–276. (<https://doi.org/10.1089/thy.2013.0061>)
- 7 Bernad DM, Sperduto PW, Souhami L, Jensen AW & Roberge D. Stereotactic radiosurgery in the management of brain metastases from primary thyroid cancers. *Journal of Neuro-Oncology* 2010 **98** 249–252. (<https://doi.org/10.1007/s11060-010-0175-z>)
- 8 Chiu AC, Delpassand ES & Sherman SI. Prognosis and treatment of brain metastases in thyroid carcinoma. *Journal of Clinical Endocrinology and Metabolism* 1997 **82** 3637–3642. (<https://doi.org/10.1210/jcem.82.11.4386>)
- 9 Mut M. Surgical treatment of brain metastasis: a review. *Clinical Neurology and Neurosurgery* 2012 **114** 1–8. (<https://doi.org/10.1016/j.clineuro.2011.10.013>)
- 10 Hatiboglu MA, Wildrick DM & Sawaya R. The role of surgical resection in patients with brain metastases. *Ecancermedicalscience* 2013 **7** 308. (<https://doi.org/10.3332/ecancer.2013.308>)
- 11 Yaeger KA & Nair MN. Surgery for brain metastases. *Surgical Neurology International* 2013 **4** (Supplement 4) S203–S208. (<https://doi.org/10.4103/2152-7806.111297>)
- 12 Patchell RA, Tibbs PA, Walsh JW, Dempsey RJ, Maruyama Y, Kryscio RJ, Markesbery WR, Macdonald JS & Young B. A randomized trial of surgery in the treatment of single metastases to the brain. *New England Journal of Medicine* 1990 **322** 494–500. (<https://doi.org/10.1056/NEJM199002223220802>)
- 13 Oken MM, Creech RH, Tormey DC, Horton J, Davis TE, McFadden ET & Carbone PP. Toxicity and response criteria of the Eastern Cooperative Oncology Group. *American Journal of Clinical Oncology* 1982 **5** 649–655. (<https://doi.org/10.1097/00000421-198212000-00014>)
- 14 Suh JH. Stereotactic radiosurgery for the management of brain metastases. *New England Journal of Medicine* 2010 **362** 1119–1127. (<https://doi.org/10.1056/NEJMct0806951>)
- 15 Choi J, Kim JW, Keum YS & Lee IJ. The largest known survival analysis of patients with brain metastasis from thyroid cancer based on prognostic groups. *PLoS ONE* 2016 **11** e0154739. (<https://doi.org/10.1371/journal.pone.0154739>)
- 16 Gaspar L, Scott C, Rotman M, Asbell S, Phillips T, Wasserman T, McKenna WG & Byhardt R. Recursive partitioning analysis (RPA) of prognostic factors in three Radiation Therapy Oncology Group (RTOG) brain metastases trials. *International Journal of Radiation Oncology, Biology, Physics* 1997 **37** 745–751. ([https://doi.org/10.1016/s0360-3016\(96\)00619-0](https://doi.org/10.1016/s0360-3016(96)00619-0))
- 17 Sperduto PW, Berkey B, Gaspar LE, Mehta M & Curran W. A new prognostic index and comparison to three other indices for patients with brain metastases: an analysis of 1,960 patients in the RTOG database. *International Journal of Radiation Oncology, Biology, Physics* 2008 **70** 510–514. (<https://doi.org/10.1016/j.ijrobp.2007.06.074>)
- 18 Sperduto PW, Kased N, Roberge D, Xu Z, Shanley R, Luo X, Sneed PK, Chao ST, Weil RJ, Suh J, et al. Summary report on the graded prognostic assessment: an accurate and facile diagnosis-specific tool to estimate survival for patients with brain metastases. *Journal of Clinical Oncology* 2012 **30** 419–425. (<https://doi.org/10.1200/JCO.2011.38.0527>)
- 19 Sperduto PW, Xu Z, Sneed P, Luo X, Roberge D, Bhatt AK, Jensen AW, Shih HA, Kirkpatrick J & Gagar LE. A graded prognostic assessment (GPA) for women with breast cancer and brain metastases. *Journal of Clinical Oncology* 2010 **28** 1028–1028. ([https://doi.org/10.1200/jco.2010.28.15\\_suppl.1028](https://doi.org/10.1200/jco.2010.28.15_suppl.1028))
- 20 Sperduto PW, Jiang W, Brown PD, Braunstein S, Sneed P, Wattson DA, Shih HA, Bangdiwala A, Shanley R, Lockney NA, et al. Estimating survival in melanoma patients with brain metastases: an update of the graded prognostic assessment for melanoma using molecular markers (melanoma-molGPA). *International Journal of Radiation Oncology, Biology, Physics* 2017 **99** 812–816. (<https://doi.org/10.1016/j.ijrobp.2017.06.2454>)
- 21 Bindal RK, Sawaya R, Leavens ME & Lee JJ. Surgical treatment of multiple brain metastases. *Journal of Neurosurgery* 1993 **79** 210–216. (<https://doi.org/10.3171/jns.1993.79.2.0210>)
- 22 Brose MS, Nutting CM, Jarzab B, Elisei R, Siena S, Bastholt L, de la Fouchardiere C, Pacini F, Paschke R, Shong YK, et al. Sorafenib in radioactive iodine-refractory, locally advanced or metastatic differentiated thyroid cancer: a randomised, double-blind, phase 3 trial. *Lancet* 2014 **384** 319–328. ([https://doi.org/10.1016/S0140-6736\(14\)60421-9](https://doi.org/10.1016/S0140-6736(14)60421-9))
- 23 Schlumberger M, Tahara M, Wirth LJ, Robinson B, Brose MS, Elisei R, Habra MA, Newbold K, Shah MH, Hoff AO, et al. Lenvatinib versus placebo in radioiodine-refractory thyroid cancer. *New England Journal of Medicine* 2015 **372** 621–630. (<https://doi.org/10.1056/NEJMoa1406470>)
- 24 Shen Y, Ruan M, Luo Q, Yu Y, Lu H, Zhu R & Chen L. Brain metastasis from follicular thyroid carcinoma: treatment with sorafenib. *Thyroid* 2012 **22** 856–860. (<https://doi.org/10.1089/thy.2011.0419>)



- 25 Gomes-Lima CJ, Wu D, Rao SN, Pudukollu S, Hritani R, Zeymo A, Deeb H, Mete M, Aulisi EF, Van Nostrand D, *et al.* Brain metastases from differentiated thyroid carcinoma: prevalence, current therapies, and outcomes. *Journal of the Endocrine Society* 2019 **3** 359–371. (<https://doi.org/10.1210/js.2018-00241>)
- 26 Pitoia F, Jerkovich F, Trimboli P & Smulever A. New approaches for patients with advanced radioiodine-refractory thyroid cancer. *World Journal of Clinical Oncology* 2022 **13** 9–27. (<https://doi.org/10.5306/wjco.v13.i1.9>)
- 27 Chen Y & Chi P. Basket trial of TRK inhibitors demonstrates efficacy in TRK fusion-positive cancers. *Journal of Hematology and Oncology* 2018 **11** 78. (<https://doi.org/10.1186/s13045-018-0622-4>)
- 28 Hong DS, DuBois SG, Kummar S, Farago AF, Albert CM, Rohrberg KS, van Tilburg CM, Nagasubramanian R, Berlin JD, Federman N, *et al.* Larotrectinib in patients with TRK fusion-positive solid tumours: a pooled analysis of three phase 1/2 clinical trials. *Lancet: Oncology* 2020 **21** 531–540. ([https://doi.org/10.1016/S1470-2045\(19\)30856-3](https://doi.org/10.1016/S1470-2045(19)30856-3))
- 29 Pitoia F. Complete response to larotrectinib treatment in a patient with papillary thyroid cancer harboring an ETV6-NTRK3 gene fusion. *Clinical Case Reports* 2021 **9** 1905–1912. (<https://doi.org/10.1002/ccr3.3900>)
- 30 Subbiah V, Hu MI, Wirth LJ, Schuler M, Mansfield AS, Curigliano G, Brose MS, Zhu VW, Leboulleux S, Bowles DW, *et al.* Pralsetinib for patients with advanced or metastatic RET-altered thyroid cancer (ARROW): a multi-cohort, open-label, registrational, phase 1/2 study. *Lancet: Diabetes and Endocrinology* 2021 **9** 491–501. ([https://doi.org/10.1016/S2213-8587\(21\)00120-0](https://doi.org/10.1016/S2213-8587(21)00120-0))
- 31 Wirth LJ, Sherman E, Robinson B, Solomon B, Kang H, Lorch J, Worden F, Brose M, Patel J, Leboulleux S, *et al.* Efficacy of selpercatinib in RET-altered thyroid cancers. *New England Journal of Medicine* 2020 **383** 825–835. (<https://doi.org/10.1056/NEJMoa2005651>)
- 32 Subbiah V, Gainor JF, Oxnard GR, Tan DSW, Owen DH, Cho BC, Loong HH, McCoach CE, Weiss J, Kim YJ, *et al.* Intracranial efficacy of selpercatinib in RET fusion-positive non-small cell lung cancers on the LIBRETTO-001 trial. *Clinical Cancer Research* 2021 **27** 4160–4167. (<https://doi.org/10.1158/1078-0432.CCR-21-0800>)

Received in final form 18 June 2022

Accepted 29 June 2022

Accepted Manuscript published online 29 June 2022