



심장 내 이물질로 인한 반복적인 뇌경색 발생에 관한 증례

연세대학교 의과대학 내과학교실 심장내과

유지웅 · 김중선 · 서지원

Percutaneous Treatment of Recurrent Stroke Caused by a Cardiac Foreign Body: A Case Report

JiWung Ryu, Jung-Sun Kim, and Jiwon Seo

Division of Cardiology, Department of Internal Medicine, Yonsei University College of Medicine, Seoul, Korea

We present a case of recurrent ischemic stroke in a 68-year-old man with a linear foreign body in the right atrium and ventricle and a patent foramen ovale (PFO). The patient developed atrial fibrillation despite taking warfarin at a therapeutic dose and had a third acute stroke. We planned left atrial appendage (LAA) occlusion via the PFO, followed by PFO closure and foreign body removal. The percutaneous LAA occlusion and PFO closure were successful. However, it was difficult to remove the radiolucent foreign body. We inserted an Omni™ catheter via the right jugular vein to contact the foreign body in the right atrium directly, grasped its distal end with a snare, and successfully extracted it. The patient was followed-up in the outpatient clinic and had no recurrent stroke. (Korean J Med 2022;97:323-327)

Keywords: Foreign body; Atrial appendage; Foramen ovale, patent; Cerebral infarction

INTRODUCTION

Stroke is a leading cause of morbidity and mortality in the general population. The different structures of the heart, including the interatrial septum and left atrial appendage (LAA), are sites of ischemic stroke or cardioembolism [1]. Although rare, foreign bodies can reach the heart and cause serious complications, including embolic cerebral infarction. They can be removed surgically

or percutaneously or managed conservatively [2]. Here, we report a case of recurrent acute stroke in a patient with atrial fibrillation (AF), a patent foramen ovale (PFO), and a foreign body in the right heart chambers.

CASE REPORT

A 68-year-old man was admitted to Neurology Clinic at Severance

Received: 2022. 2. 10

Revised: 2022. 4. 4

Accepted: 2022. 4. 18

Correspondence to Jiwon Seo, M.D.

Division of Cardiology, Department of Internal Medicine, Severance Cardiovascular Hospital, Yonsei University College of Medicine, 50-1 Yonsei-ro, Seodaemun-gu, Seoul 03722, Korea

Tel: +82-2-2228-8464, Fax: +82-2-2227-7742, E-mail: eprangiana@yuhs.ac

Copyright © 2022 The Korean Association of Internal Medicine

This is an Open Access article distributed under the terms of the Creative Commons Attribution Non-Commercial License (<http://creativecommons.org/licenses/by-nc/3.0/>) which permits unrestricted noncommercial use, distribution, and reproduction in any medium, provided the original work is properly cited.

Hospital because of recurrent stroke. His medical history included hypertension, type 2 diabetes mellitus, and hyperthyroidism. He had undergone a partial gastrectomy for peptic ulcer perforation approximately 30 years previously. One day before admission, he had developed sudden dysarthria and right-sided weakness. He was diagnosed with acute left middle cerebral artery infarction based on magnetic resonance imaging of the brain (Fig. 1A) and referred to the cardiology department for evaluation of the cardiac embolic source of the acute stroke.

Transesophageal echocardiography (TEE) revealed linear echogenic material measuring approximately 9.2 cm and spanning from the right ventricular apex to the interatrial septum in the right

atrium (Fig. 1B). No spontaneous echo contrast or thrombus was observed in the left atrium or LAA. However, a left-to-right shunt via the PFO with no high-risk features was detected (slit length, 8 mm; slit diameter, 1.6 mm). TEE revealed an LAA ostial diameter of 18 mm, a maximum landing zone width of 15 mm, and a depth of 25 mm. He developed mild tricuspid regurgitation, without pulmonary hypertension or other relevant features. These findings were confirmed by thoracic computed tomography (Fig. 1C).

Suspecting cardioembolic infarction without hemorrhagic transformation, we started anticoagulant therapy. However, despite administering warfarin at a therapeutic dose, the patient experienced a third acute stroke. In addition, while the patient was hospitalized

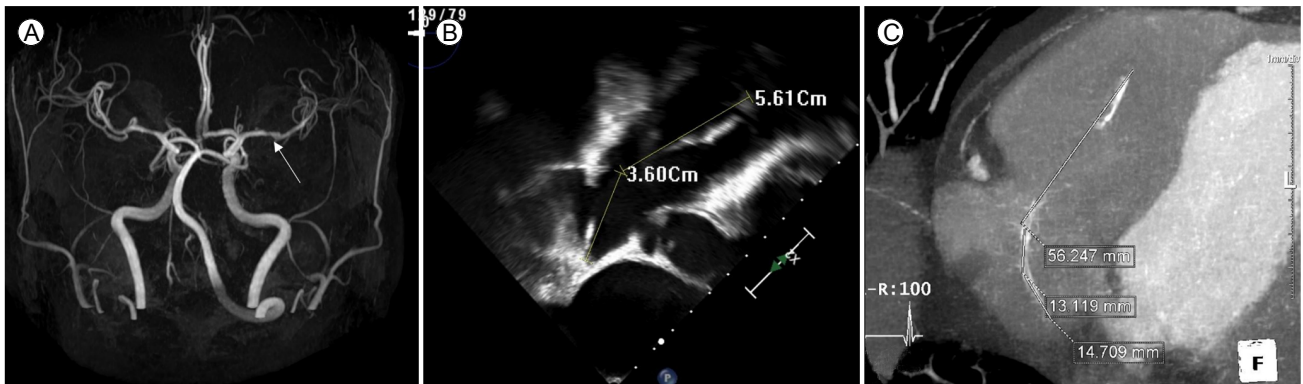


Figure 1. (A) Magnetic resonance imaging of the brain shows acute left middle cerebral artery infarction (white arrow). (B) Transesophageal echocardiograph shows linear echogenic material measuring approximately 9.2 cm. (C) Thoracic computed tomography shows the curvilinear foreign body in the right atrium and ventricle.

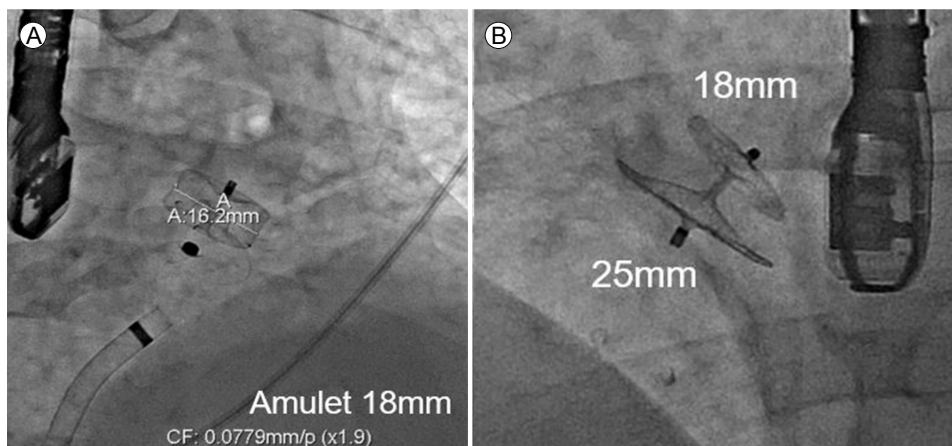


Figure 2. (A) The left atrial appendage (AMPLATZER™ Amulet 18 mm) and (B) patent foramen ovale (AMPLATZER™ PFO Occluder 25/18 mm) occlusion devices are successfully deployed.

to evaluate the cardiac embolic source, an electrocardiogram showed paroxysmal AF (CHA2DS2-VASc: 5). We discussed the case at a brain-heart team meeting with a neurologist, interventional cardiologist, imaging cardiologist, and radiologist. We decided to perform surgical or percutaneous closure of the PFO and simultaneous LAA occlusion and foreign body removal. When this decision was communicated to the patient and his family, they strongly preferred the percutaneous procedures. Therefore, the patient was transferred to the cardiology department for interventional treatment.

First, LAA occlusion was performed via the right femoral vein

using TEE and fluoroscopic guidance under general anesthesia. A transseptal approach was used via the PFO with an 8.5 Fr Swartz trans-septal catheter and a dilator. After placing the catheter in the LAA, contrast was injected via the sheath to demonstrate the anatomy and size of the LAA. An amulet device (AMPLATZER™ amulet 18 mm, Abbott, Minneapolis, MN, USA) was deployed, and a stable position was confirmed angiographically by the tug test, while TEE showed no leakage (Fig. 2A). Then the catheter was replaced with a 13 Fr AMPLATZER TorqVue delivery sheath (St. Jude Medical, Plymouth, MN, USA), and the PFO occlusion device (AMPLATZER™ PFO Occluder 25/18 mm, Abbott) was

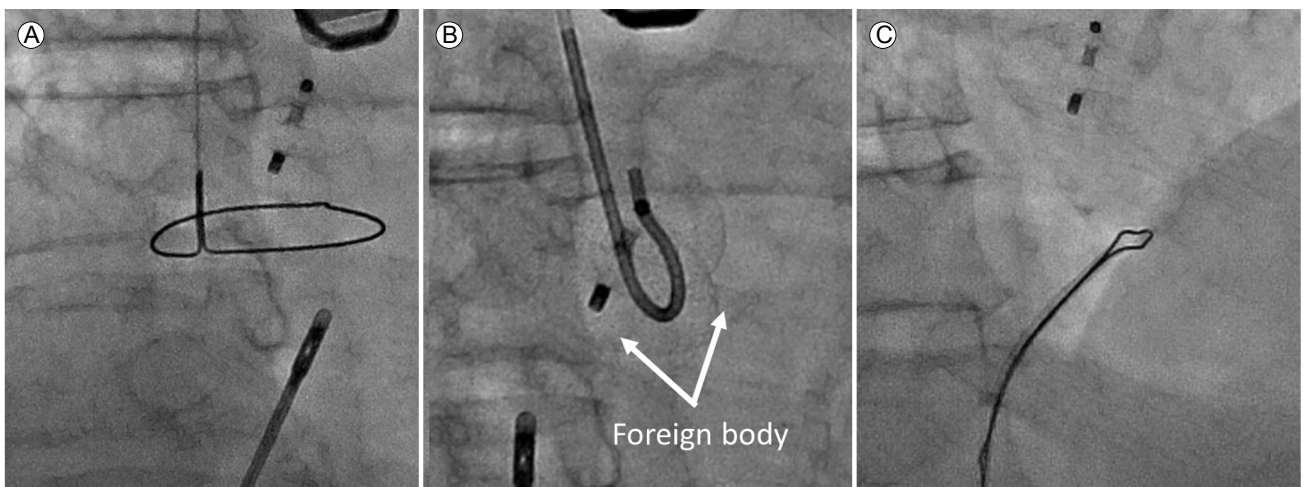


Figure 3. (A) A forceps-assisted device usually used for cardiac biopsies was used. The fluoroscopy image shows the Omni™ catheter with the right jugular vein approach and (B) grasping and (C) extracting the distal end of the foreign body with a snare.

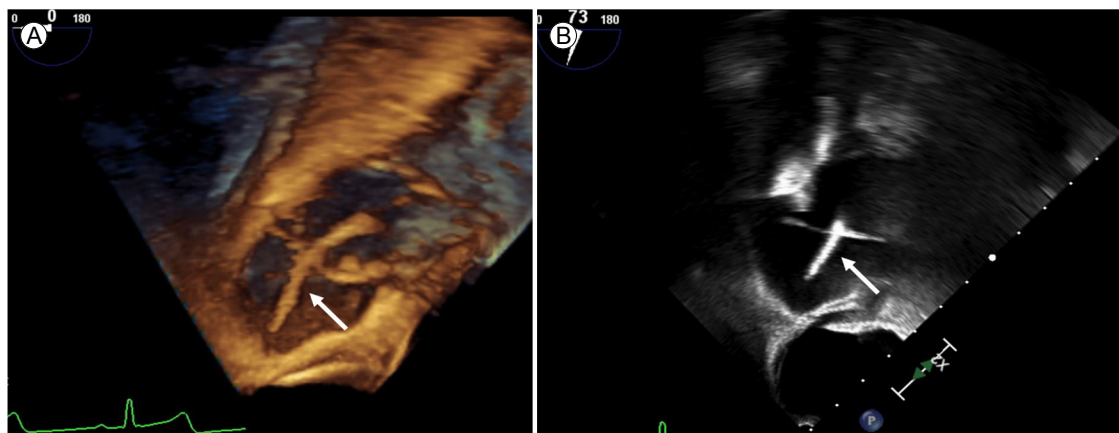


Figure 4. (A) Three- and (B) two-dimensional transesophageal echocardiographs show a foreign body in the right cardiac chambers (arrows).

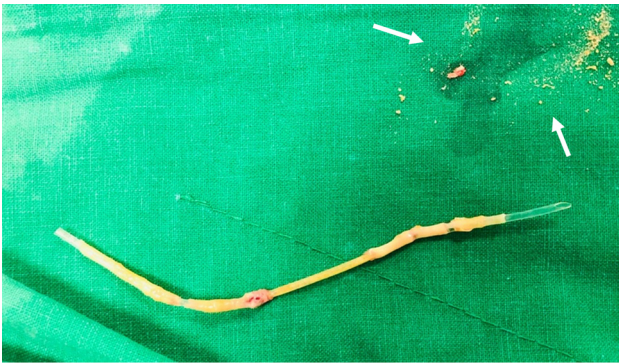

Figure 5. The foreign body appears to be the tip of a rubber-encased intravenous line. The white arrows show that the emboli may have originated from the foreign body.

deployed successfully (Fig. 2B). Stability and complete occlusion were confirmed by an intraprocedural TEE. Finally, we attempted to capture the distal end of the foreign body using a snare, although it could not be clearly visualized under fluoroscopy. Initially, a forceps-assisted device was used; however, despite several attempts, the distal end of the foreign body could not be grasped (Fig. 3A, B). Subsequently, we decided to use an Omni™ catheter via the right jugular vein. On opening the Omni™ catheter with wire advancement, we captured and retrieved the middle portion of the foreign body (Fig. 3C). The foreign body in the right cardiac chamber was repositioned using 3D TEE (Fig. 4). The multipurpose catheter was re-released using a 30 mm snare and recaptured at a distal end. The piece was straightened and easily extracted from the femoral vein sheath along with the foreign body, which appeared to be the tip of a rubber-enclosed intravenous line (Fig. 5) with several, tiny, easily broken particles. The procedure was terminated without complications.

DISCUSSION

Up to 58% of patients with cryptogenic stroke have a right-to-left cardiac shunt or PFO [3,4]. Although the cause of recurrent acute stroke was unclear in our case, it may have resulted from embolization of particles from the foreign body via the PFO. Another potential cause was AF because the patient had a high CHA2DS2-VASc score, which implies an increased risk for stroke [4]. When the patient had a third stroke, the prognosis was poor.

Therefore, we attempted to eliminate the possible causes of stroke. We decided to perform LAA occlusion via the PFO, followed by PFO closure and foreign body removal. The patient had an anatomy that allowed LAA occlusion via the PFO [5].

The unique feature of this case was the difficulty of catheter withdrawal, in the initial approach, from the right cardiac chambers because the foreign body was not visualized in fluoroscopy. The foreign body was removed successfully using an Omni™ catheter, which allowed slight pull-back of the foreign body with subsequent distal-end exposure and the final retrieval using the snaring technique [6]. Antecedent piece repositioning using the Omni™ catheter before snaring, particularly when the tip of the foreign body is not free, has been described with a high technical success rate [6]. The foreign body could be easily pulled back with the Omni™ catheter, and its distal end could be turned sufficiently to be snared in a second maneuver.

In conclusion, we report a rare case of recurrent stroke caused by a right-chamber foreign body. We successfully retrieved the foreign body percutaneously and occluded the LAA and PFO.

중심 단어: 이물질; 심방귀; 타원공; 뇌경색증

CONFLICTS OF INTEREST

No potential conflict of interest relevant to this article was reported.

FUNDING

None.

AUTHOR CONTRIBUTIONS

J.R. and J.S. drafted the manuscript and designed the figures. J.K. provided critical feedback.

ACKNOWLEDGMENTS

None.

REFERENCES

1. Freixa X, Arzamendi D, Tzikas A, et al. Cardiac procedures to prevent stroke: patent foramen ovale closure/left atrial appendage occlusion. *Can J Cardiol* 2014;30:87-95.
2. Leitman M, Vered Z. Foreign bodies in the heart. *Echocardiography* 2015;32:365-371.
3. McMahon NE, Bangee M, Benedetto V, et al. Etiologic workup in cases of cryptogenic stroke: a systematic review of international clinical practice guidelines. *Stroke* 2020;51:1419-1427.
4. Gladstone DJ, Spring M, Dorian P, et al. Atrial fibrillation in patients with cryptogenic stroke. *N Engl J Med* 2014;370:2467-2477.
5. Tzikas A, Papadopoulos K, Konstantinou D, Ntaios G, Arampatzis C. Left atrial appendage occlusion through a patent foramen ovale: should we or rather not? *Hellenic J Cardiol* 2020;61:442-443.
6. Ho CL, Chou CM, Chang TK, Jan SL, Lin MC, Fu YC. Dislodgment of port-a-cath catheters in children. *Pediatr Neonatol* 2008;49:179-182.