



Axial Length as a Risk Factor for Steroid-Induced Ocular Hypertension

Wungrak Choi, Jung Dong Kim, Hyoung Won Bae, Chan Yun Kim, Gong Je Seong, and Min Kim

Institute of Vision Research, Department of Ophthalmology, Yonsei University College of Medicine, Seoul, Korea.

Purpose: In this study, we aimed to assess whether axial length (AXL) is a true risk factor for steroid-induced ocular hypertension (OHT). We hypothesized that the proportion of patients with steroid-induced OHT among individuals who have received intravitreal dexamethasone (DEX) injections would differ according to the AXL of their eyes.

Materials and Methods: A single-center, cross-sectional, case-control study was conducted on 467 eyes that underwent DEX implant injection owing to various retinal diseases. Intraocular pressure (IOP) was measured before the injection and 1 week and 1, 2, 3, 6, and 12 months after the injection. Enrolled patients were divided into OHT and normal IOP groups. Univariable logistic regression analysis was used to calculate odds ratios of steroid-induced OHT with significant variables being analyzed using a multi-variable model.

Results: A longer AXL was identified as a risk factor for steroid-induced OHT via both univariable and multivariable analyses, with an odds ratio of 1.216 [95% confidence interval (CI): 1.004–1.472, $p=0.0452$]. The optimal cut-off value for AXL in terms of steroid-induced OHT was 23.585 mm, with an odds ratio of 2.355 (95% CI: 1.429–3.882, $p=0.0008$).

Conclusion: Our findings indicate that a long AXL is a risk factor for steroid-induced OHT. Further, clinicians should be aware of steroid-induced OHT when treating patients with high myopia with steroids.

Key Words: Dexamethasone, intraocular pressure, myopia, axial length, ocular hypertension

INTRODUCTION

Although ophthalmologists commonly encounter patients with steroid-induced ocular hypertension (OHT), the risk factors for this condition remain unclear.¹ As avoiding steroid usage among high-risk patients is an optimal way of preventing steroid-induced OHT, there is a clinical need to determine such risk factors. High myopia is one such possible risk factor,² although

evidence in support thereof is limited. To our knowledge, very few studies have been conducted to assess the association between axial length (AXL) and steroid-induced OHT.

The first study on myopia and steroid-induced OHT was conducted in 1966.² Therein, 17 patients with high myopia received 0.1% dexamethasone (DEX) eye drops for 6 weeks.² Patients with high myopia exhibited a higher risk of developing steroid-induced OHT than other patients.² Accordingly, most ophthalmologists accept high myopia as a risk factor for steroid-induced OHT. However, that study had a small sample, and although high myopia was defined as a myopic refractive error >5.0 , the exact AXL was not reported. These findings have not been confirmed in larger studies to date. In a recent study, a short AXL (<23.00 mm) was a risk factor for steroid-induced OHT.³ Given the need to confirm these findings, we conducted the present study to verify whether short and long AXLs are risk factors for steroid-induced OHT. We hypothesized that the occurrence of steroid-induced OHT among patients who have received intravitreal DEX injections would differ according to their AXL.

Received: March 29, 2022 **Revised:** July 18, 2022

Accepted: July 22, 2022 **Published online:** August 18, 2022

Co-corresponding authors: Min Kim, MD, PhD, Department of Ophthalmology, Gangnam Severance Hospital, 211 Eonju-ro, Gangnam-gu, Seoul 06273, Korea. Tel: 82-2-2019-3442, Fax: 82-2-3463-1049, E-mail: minkim76@gmail.com and Gong Je Seong, MD, PhD, Department of Ophthalmology, Gangnam Severance Hospital, 211 Eonju-ro, Gangnam-gu, Seoul 06273, Korea. Tel: 82-2-2019-3441, Fax: 82-2-3463-1049, E-mail: gjseong@yuhs.ac

•The authors have no potential conflicts of interest to disclose.

© Copyright: Yonsei University College of Medicine 2022

This is an Open Access article distributed under the terms of the Creative Commons Attribution Non-Commercial License (<https://creativecommons.org/licenses/by-nc/4.0>) which permits unrestricted non-commercial use, distribution, and reproduction in any medium, provided the original work is properly cited.

MATERIALS AND METHODS

Patient enrollment

This retrospective study was conducted on patients who underwent DEX implantation between March 2014 and May 2019 at Yonsei University Health System, Korea. The inclusion criteria were availability of AXL data and records of intraocular pressure (IOP) measurements up to 12 months post-injection. Information on the patients' medical history, sex, primary diagnosis, age, and ocular examination was obtained from the medical records. Ocular assessments included measurements of IOP, AXL, and central corneal thickness and fundus examination.

This study was approved by the Institutional Review Board of Gangnam Severance Hospital. The requirement for informed consent was waived since this study was a retrospective review of existing medical records (IRB number: 3-2020-0310). The study protocol adhered to the tenets of the Declaration of Helsinki and was in compliance with the Health Insurance Portability and Accountability Act.

Study design

A total of 467 eyes were finally eligible for inclusion. Patients who underwent one DEX implantation were included in the study. We defined and classified IOP elevation as previously described: a post-injection IOP ≥ 25 mm Hg or an IOP elevation ≥ 10 mm Hg over the baseline measurement.⁴ The baseline measurement was defined as the initial IOP before DEX implantation. IOP was evaluated at seven time points: baseline IOP before injection and IOP 1 week and 1, 2, 3, 6, and 12 months after DEX implantation. The included patients were divided into an OHT and a normal IOP group.

Intravitreal DEX injections

Intravitreal injections were administered as previously described.⁴ Briefly, an eyelid speculum was used to stabilize the eyelids and each eye was sterilized and flushed with 5% povidone iodine eye drops before the injection. The injection was administered under topical anesthesia; 0.5% Alcaine (proparacaine hydrochloride) eye drops. The injections were administered 3.5 mm posterior to the corneal limbus through the pars plana, and a 0.7-mg DEX implant (Ozurdex; Allergan Inc., Irvine, CA, USA) was inserted.⁴

IOP measurements

IOP measurements were performed as previously described.⁵ Briefly, patients underwent eye examinations before and after DEX implantation. IOP was measured using a non-contact tonometer (NCT, KT-800 tonometer; Kowa, Tokyo, Japan) or a Goldmann applanation tonometer (GAT). Unless there was a previous glaucoma diagnosis, the NCT was initially used to measure both pre- and post-injection IOP. However, in cases with a high IOP (>20 mm Hg), measurements were repeated

using a GAT. The IOP measurements were obtained in triplicate within the same sitting, and the average value was considered the final IOP.⁵

Statistical analysis

Data were analyzed with SPSS 22.0 software (IBM Corp., Armonk, NY, USA), SAS version 9.4 (SAS Institute, Cary, NC, USA), and R package version 3.4.4 (<http://www.R-project.org>). Continuous and categorical variables are expressed as the mean (SD) and number of patients (percentage), respectively.

Logistic regression analysis was used to calculate the odds ratio for steroid-induced OHT. The included variables were age, sex, AXL, central corneal thickness, glaucoma history [i.e., primary open-angle glaucoma (POAG), glaucoma suspect, neovascular glaucoma, angle-closure glaucoma, and secondary glaucoma], and medical history [i.e., connective tissue disease, thyroid disease, kidney disease, cancer, benign prostatic hyperplasia, tuberculosis, cardiovascular diseases, cerebrovascular accidents, hypertension, diabetes mellitus (DM), family history of glaucoma, previous history of uveitis, and penetrating keratoplasty]. Firth logistic regression was performed if zero observations in the group were recorded. After calculating odds ratios, significant variables were analyzed using a multivariable model. The optimal cut-off value of AXL for steroid-induced OHT was calculated using the Youden index. *P* values < 0.05 indicated statistical significance.

RESULTS

The total proportion of steroid-induced OHT after DEX implantation was 16.9%. Table 1 summarizes the clinical characteristics of the normal and OHT groups. Major causes of macular edema requiring DEX implantation were diabetic macular edema (DME), retinal vein occlusion, and uveitis (Table 1).

The distribution of the highest postoperative IOP according to the AXL was analyzed via scatter plot analysis. The highest postoperative IOP was calculated for the AXL of each eye, and the trend line was analyzed (Fig. 1).

Univariable analyses for factors associated with steroid-induced OHT

Logistic regression analysis revealed that young age, male sex, long AXL, and absence of DM were significantly related to steroid-induced OHT development ($p < 0.05$) (Table 1).

Multivariable model results

Using all significant variables, we fitted a multivariable model to assess AXL as a risk factor for steroid-induced OHT. The odds ratio was 1.216 [95% confidence interval (CI): 1.004–1.472, $p = 0.0452$], which indicated that a long AXL is an independent risk factor for steroid-induced OHT (Table 2).

Table 1. Clinical Characteristics and Results of Univariable Analyses of Factors that May Cause Steroid-Induced OHT (n=467)

Variables	Normal (n=388)	OHT (n=79)	Univariable analyses OR (95% CI)	p value
Age (yr)	62.116±13.065	58.304±15.393	0.981 (0.964–0.997)	0.0239
AXL (mm)	23.568±1.201	24.000±1.259	1.304 (1.084–1.569)	0.0049
SE (D) (n=432)	-0.314±3.126	-0.498±2.930	0.981 (0.905–1.063)	0.6385
CCT (µm) (n=308)	558.240±54.016	574.111±66.418	1.005 (1.000–1.010)	0.0637
POAG	12 (3.09)	3 (3.80)	1.237 (0.341–4.489)	0.7465
GS	9 (2.32)	5 (6.33)	2.845 (0.927–8.731)	0.0676
NVG	8 (2.06)	3 (3.80)	1.875 (0.486–7.230)	0.3613
Angle closure glaucoma	5 (1.29)	1 (1.27)	0.982 (0.11–8.523)	0.9870
Secondary glaucoma	9 (2.32)	5 (6.33)	2.845 (0.927–8.731)	0.0676
Right eye	212 (54.64)	46 (58.23)	1.157 (0.709–1.889)	0.5590
Previous uveitis history	23 (5.93)	9 (11.39)	2.040 (0.906–4.596)	0.0852
Connective tissue disease	12 (3.09)	4 (5.06)	1.671 (0.525–5.322)	0.3850
Thyroid disease	11 (2.84)	2 (2.53)	0.890 (0.193–4.097)	0.8813
Kidney disease	11 (2.84)	2 (2.53)	0.890 (0.193–4.097)	0.8813
Cancer	19 (4.90)	3 (3.80)	0.767 (0.22–2.656)	0.6752
BPH	7 (1.80)	2 (2.53)	1.414 (0.288–6.937)	0.6692
Tuberculosis	5 (1.29)	1 (1.27)	0.982 (0.113–8.523)	0.9870
Cardiovascular problem	34 (8.76)	4 (5.06)	0.555 (0.191–1.612)	0.2792
CVA	12 (3.09)	2 (2.53)	0.814 (0.179–3.710)	0.7902
HTN	162 (41.75)	24 (30.38)	0.609 (0.362–1.024)	0.0615
Sex (female)	225 (57.99)	35 (44.30)	0.576 (0.354–0.938)	0.0267
LASIK/LASEK	1 (0.26)	2 (2.53)	10.051 (0.900–112.224)	0.0609
Penetrating keratoplasty	0 (0.00)	1 (1.27)	14.822 (0.160–1376.255)	0.2435*
Family history of glaucoma	4 (1.03)	3 (3.80)	3.789 (0.831–17.275)	0.0852
DM	197 (50.77)	29 (36.71)	0.562 (0.341–0.926)	0.0237
Diagnosis in study eye (eyes)				
DME	142 (36.60)	15 (18.99)	ref	
RVO	114 (29.38)	26 (32.91)	2.159 (1.092–4.269)	0.9197
Uveitis	34 (8.76)	15 (18.99)	4.176 (1.862–9.366)	0.0076
Others	98 (25.26)	23 (29.11)	2.222 (1.104–4.472)	0.8150

OR, odds ratio; CI, confidence interval; OHT, ocular hypertension; AXL, axial length; SE, spherical equivalent; D, diopter; CCT, central corneal thickness; POAG, primary open-angle glaucoma; GS, glaucoma suspect; NVG, neovascular glaucoma; BPH, benign prostatic hyperplasia; CVA, cerebrovascular accident; HTN, hypertension; LASIK, laser-assisted in situ keratomileusis; LASEK, laser-assisted subepithelial keratectomy; DM, diabetes mellitus; DME, diabetic macular edema; RVO, retinal vein occlusion.

Data are presented as mean±standard deviation or n (%).

*Firth logistic regression was performed if there were zero observations.

Distribution of steroid-induced OHT according to AXL

The patients were divided into six groups according to the AXL, from the shortest to the longest. Subsequently, the number and proportion of patients with steroid-induced OHT in each group was determined. The AXL of each group was as follows: <22 mm (group 1), 22 to <23 mm (group 2), 23 to <24 mm (group 3), 24 to <25 mm (group 4), 25 to <26 mm (group 5), and ≥26 mm (group 6). The proportion of patients with steroid-induced OHT in each group was as follows: 8.33% in group 1, 14.75% in group 2, 12.28% in group 3, 25.77% in group 4, 22.58% in group 5, and 27.27% in group 6. A continuous increase in the proportion of patients with steroid-induced OHT was observed as the AXL increased (Table 3A and B).

Optimal cut-off point of AXL for clinical use

The optimal cut-off value of AXL for steroid-induced OHT was 23.585 mm. Patients with an AXL ≥23.585 mm exhibited a higher risk of developing steroid-induced OHT than those with an AXL <23.585 mm, with an odds ratio of 2.355 (95% CI: 1.429–3.882, p=0.0008) (Table 3C and D).

DISCUSSION

Steroids are widely used to treat various ophthalmic diseases, and concomitant steroid-related problems, including IOP, are common in the clinical field. Steroid-induced OHT can cause severe complications resulting from pressure-induced optic

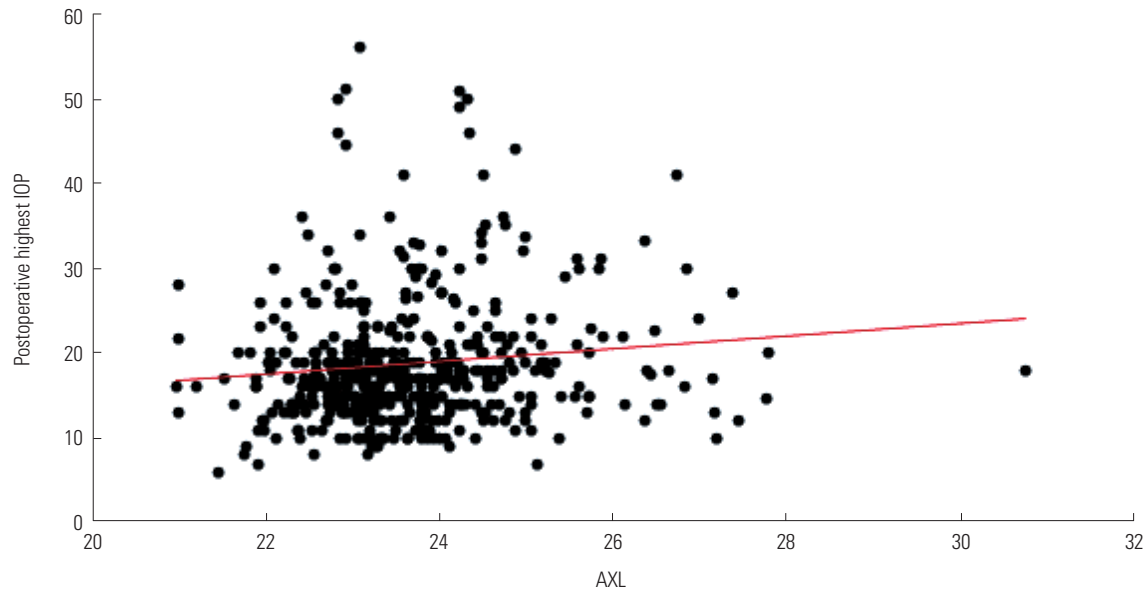


Fig. 1. Distribution of the highest postoperative IOP according to axial length. The maximum postoperative IOP and AXL were analyzed via scatter plot analysis. The highest postoperative IOP was calculated for the AXL of each eye, and the trend line was analyzed. IOP, intraocular pressure; AXL, axial length.

Table 2. Results of Multivariable Analysis Performed Using Factors That May Cause Steroid-Induced Ocular Hypertension

Variables	Multivariable analysis (n=467)	
	OR (95% CI)	p value
Age	0.988 (0.971–1.005)	0.1741
AXL	1.216 (1.004–1.472)	0.0452
Sex (female)	0.635 (0.382–1.057)	0.0807
DM	0.570 (0.342–0.952)	0.0316

OR, odds ratio; CI, confidence interval; AXL, axial length; DM, diabetes mellitus. Multivariable analysis included variables that were significant in univariable analysis.

nerve damage.^{1,6,7} To avoid steroid-induced OHT, many ophthalmologic studies have been conducted to determine its risk factors. However, there are few known risk factors, with controversial data for several of these factors.¹ Proposed risk factors for steroid-induced OHT include POAG, a first-degree relative with POAG, connective tissue disease, young age (<6 years), history of steroid-induced IOP elevation, penetrating keratoplasty (particularly Fuchs' endothelial dystrophy or keratoconus), type 1 DM, and high myopia.⁸⁻¹³

To date, however, there is little evidence of high myopia as a risk factor for steroid-induced OHT. One study, conducted in 1966, was subject to several limitations.² First, it included only 17 participants. Second, among the 17 participants, 14 were aged <20 years. Since young age is a risk factor for steroid-induced OHT, adjustment using multivariable analysis would be necessary to make appropriate conclusions. Third, since high myopia was defined with refractive error, the true AXL was not presented. Moreover, to date, there has been no large-scale study to confirm those findings. The recent SAFODEX study was conducted to evaluate myopia as a risk factor for steroid-

induced OHT; however, owing to insufficient AXL values, multivariable analysis could not be performed.¹⁴ The present study addressed these limitations, as we included a large sample (467 eyes) of patients for whom AXL values were recorded. Both univariable and multivariable models revealed that a long AXL was a significant risk factor for steroid-induced OHT (Tables 2 and 3). This is consistent with the results of the 1966 study.²

Contrarily, a recent study revealed that a short AXL (<23.00 mm) may be a risk factor for steroid-induced OHT,³ which is inconsistent with our findings (Table 3). The inconsistency of these findings may be attributed to several reasons. First, the previous study had a relatively small sample of patients with myopia (84 eyes, all with an AXL <25 mm). Second, as both studies were cross-sectional, selection bias may have occurred in either or both. Third, our study lacked data from patients with an AXL <21 mm. Therefore, there is a need for further studies to determine the exact association between a short AXL and steroid-induced OHT.

It is unclear why a long AXL may be a risk factor for steroid-induced OHT. As POAG is a known risk factor for steroid-induced OHT, and as it is currently widely accepted that high myopia is associated with POAG, there may be several links between these variables.^{2,10,15-17} For example, patients with high myopia may have defective angle development or decreased permeability of the blood-aqueous barrier.^{2,18,19} However, there is a need for further research to determine the underlying mechanisms.

In addition to AXL, absence of DM was also a significant risk factor for steroid-induced OHT (Table 2). According to an analysis per different eye conditions, the risk of steroid-induced IOP was higher among patients with uveitis than among those with DME (Table 1). Although the reason for the potential relationship between DM and steroid-induced OHT is not known, it

Table 3. Distribution of Steroid-Induced OHT according to AXL and Optimal Cut-Off Point

A. Number of patients with steroid-induced OHT in each group						
	AXL (mm)					
	<22	22 to <23	23 to <24	24 to <25	25 to <26	≥26
OHT	2	18	21	25	7	6
Normal	22	104	150	72	24	16

B. Proportion of patients with steroid-induced OHT in each group						
	AXL (mm)					
	<22	22 to <23	23 to <24	24 to <25	25 to <26	≥26
OHT	8.33	14.75	12.28	25.77	22.58	27.27
Normal	91.67	85.25	87.72	74.23	77.42	72.73

C. Optimal cut-off value of AXL for steroid-induced OHT using the Youden index			
Cut-off point	AUC (95% CI)	Sensitivity (95% CI)	Specificity (95% CI)
≥23.585, <23.585	0.6064 (0.5370–0.6758)	63.29 (36.71–77.25)	57.73 (51.54–81.44)

D. Proportion and odds ratio of steroid-induced OHT according to the optimal cut-off point					
AXL (mm)	Total	No	Yes	OR (95% CI)	p value
<23.585	253 (54.18)	224 (57.73)	29 (36.71)	ref	
≥23.585	214 (45.82)	164 (42.27)	50 (63.29)	2.355 (1.429–3.882)	0.0008

AXL, axial length; OR, odds ratio; CI, confidence interval; OHT, ocular hypertension; AUC, area under the receiver operating characteristic curve. Patients were divided into six groups according to the AXL (shortest to longest). Tables A and B summarize the number of patients for steroid-induced OHT in each group. The optimal cut-off value of AXL for steroid-induced OHT was calculated using the Youden index (C and D).

seems that most patients with DM in our study had DME, which may be a protective factor against steroid-induced OHT.

A strength of our study is that all participants received the same type of steroid. DEX implantation is well-known to increase IOP.^{4,5,20-22} Therefore, it was reasonable to assess the risk of steroid-induced OHT among patients who have undergone intravitreal DEX implantation. Another major strength of our study is the large sample that was included, which allowed us to draw more definitive conclusions than researchers conducting smaller studies.

Nevertheless, this study also has several limitations, including its retrospective design and the fact that our findings cannot be directly compared to those of prospective, randomized controlled trials. Second, our study population did not include many patients with extremely short and long AXLs (<21 mm or >28 mm). Third, owing to the cross-sectional design, selection bias may have occurred.

Despite these limitations, however, our findings could be useful to clinicians in this field. As steroids are widely used and steroid-induced OHT is a major concern, our results demonstrate the need for clinicians to be more aware of steroid-induced OHT in patients with myopia. Specifically, we calculated a cut-off value of AXL of 23.585 mm, with an odds ratio of 2.355 (95% CI: 1.429–3.882, *p*=0.0008) (Table 3). Therefore, clinicians may consider administering steroids in patients with an AXL less than 23.585 mm and should be more cautious with patients with a higher AXL. These findings, however, need to be confirmed through large, randomized, prospective studies in the near future since the sensitivity and specificity of the cut-off values were not very high. Along with AXL, other known risk factors must also be evaluated for better predicting possi-

bility of steroid-induced OHT.

In conclusion, we found that a long AXL is a risk factor for steroid-induced OHT and that clinicians should be aware of steroid-induced OHT when treating patients with high myopia with steroids.

ACKNOWLEDGEMENTS

This work was supported by a faculty research grant from Yonsei University College of Medicine (6-2020-0139) and the Basic Science Research Program through the National Research Foundation of Korea (NRF-2022R111A1A01071919 & NRF-2019R1A2C1091089).

AUTHOR CONTRIBUTIONS

Conceptualization: Wungrak Choi, Gong Je Seong, and Min Kim. **Data curation:** Jung Dong Kim and Hyoung Won Bae. **Formal analysis:** Jung Dong Kim and Hyoung Won Bae. **Funding acquisition:** Wungrak Choi and Chan Yun Kim. **Investigation:** Wungrak Choi, Jung Dong Kim, Chan Yun Kim, and Min Kim. **Methodology:** Wungrak Choi, Jung Dong Kim, Hyoung Won Bae, and Min Kim. **Project administration:** Min Kim. **Resources:** Gong Je Seong and Min Kim. **Supervision:** Gong Je Seong and Min Kim. **Validation:** Jung Dong Kim and Hyoung Won Bae. **Visualization:** Gong Je Seong and Min Kim. **Writing—original draft:** Wungrak Choi, Gong Je Seong, and Min Kim. **Writing—review & editing:** Wungrak Choi, Gong Je Seong, and Min Kim. **Approval of final manuscript:** all authors.

ORCID iDs

Wungrak Choi <https://orcid.org/0000-0002-3015-2502>
 Jung Dong Kim <https://orcid.org/0000-0003-4023-9211>

Hyung Won Bae <https://orcid.org/0000-0002-8421-5636>
 Chan Yun Kim <https://orcid.org/0000-0002-8373-9999>
 Gong Je Seong <https://orcid.org/0000-0002-5456-4296>
 Min Kim <https://orcid.org/0000-0003-1873-6959>

REFERENCES

1. Fini ME, Schwartz SG, Gao X, Jeong S, Patel N, Itakura T, et al. Steroid-induced ocular hypertension/glaucoma: focus on pharmacogenomics and implications for precision medicine. *Prog Retin Eye Res* 2017;56:58-83.
2. Podos SM, Becker B, Morton WR. High myopia and primary open-angle glaucoma. *Am J Ophthalmol* 1966;62:1039-43.
3. Choi MY, Kwon JW. Risk factors for ocular hypertension after intravitreal dexamethasone implantation in diabetic macular edema. *Sci Rep* 2020;10:13736.
4. Choi W, Park SE, Kang HG, Byeon SH, Kim SS, Koh HJ, et al. Intraocular pressure change after injection of intravitreal dexamethasone (Ozurdex) implant in Korean patients. *Br J Ophthalmol* 2019;103:1380-7.
5. Choi W, Bae HW, Choi EY, Kim M, Kim EW, Kim CY, et al. Age as a risk factor for steroid-induced ocular hypertension in the non-paediatric population. *Br J Ophthalmol* 2020;104:1423-9.
6. Phulke S, Kaushik S, Kaur S, Pandav SS. Steroid-induced glaucoma: an avoidable irreversible blindness. *J Curr Glaucoma Pract* 2017;11:67-72.
7. Kass MA, Heuer DK, Higginbotham EJ, Johnson CA, Keltner JL, Miller JP, et al. The ocular hypertension treatment study: a randomized trial determines that topical ocular hypotensive medication delays or prevents the onset of primary open-angle glaucoma. *Arch Ophthalmol* 2002;120:701-13.
8. Armaly MF. Effect of corticosteroids on intraocular pressure and fluid dynamics. I. The effect of dexamethasone in the normal eye. *Arch Ophthalmol* 1963;70:482-91.
9. Armaly MF. Effect of corticosteroids on intraocular pressure and fluid dynamics. II. The effect of dexamethasone in the glaucomatous eye. *Arch Ophthalmol* 1963;70:492-9.
10. Becker B, Hahn KA. Topical corticosteroids and heredity in primary open-angle glaucoma. *Am J Ophthalmol* 1964;57:543-51.
11. Davies TG. Tonographic survey of the close relatives of patients with chronic simple glaucoma. *Br J Ophthalmol* 1968;52:32-9.
12. Lam DS, Fan DS, Ng JS, Yu CB, Wong CY, Cheung AY. Ocular hypertensive and anti-inflammatory responses to different dosages of topical dexamethasone in children: a randomized trial. *Clin Exp Ophthalmol* 2005;33:252-8.
13. Gaston H, Absolon MJ, Thurtle OA, Sattar MA. Steroid responsiveness in connective tissue diseases. *Br J Ophthalmol* 1983;67:487-90.
14. Malclès A, Dot C, Voirin N, Vié AL, Agard É, Bellocq D, et al. Safety of intravitreal dexamethasone implant (Ozurdex): the SAFODEX study. Incidence and risk factors of ocular hypertension. *Retina* 2017;37:1352-9.
15. Hsu CH, Chen RI, Lin SC. Myopia and glaucoma: sorting out the difference. *Curr Opin Ophthalmol* 2015;26:90-5.
16. Kimura Y, Akagi T, Hangai M, Takayama K, Hasegawa T, Suda K, et al. Lamina cribrosa defects and optic disc morphology in primary open angle glaucoma with high myopia. *PLoS One* 2014;9:e115313.
17. Yoon JY, Sung KR, Yun SC, Shin JW. Progressive optic disc tilt in young myopic glaucomatous eyes. *Korean J Ophthalmol* 2019;33:520-7.
18. Chen Z, Song Y, Li M, Chen W, Liu S, Cai Z, et al. Schlemm's canal and trabecular meshwork morphology in high myopia. *Ophthalmic Physiol Opt* 2018;38:266-72.
19. D'Ermo F, Salvi GL. [Permeability of the blood-aqueous barrier in myopic subjects having chronic glaucoma]. *Boll Ocul* 1955;34:98-108.
20. Boyer DS, Yoon YH, Belfort R Jr, Bandello F, Maturi RK, Augustin AJ, et al. Three-year, randomized, sham-controlled trial of dexamethasone intravitreal implant in patients with diabetic macular edema. *Ophthalmology* 2014;121:1904-14.
21. Haller JA, Bandello F, Belfort R Jr, Blumenkranz MS, Gillies M, Heier J, et al. Randomized, sham-controlled trial of dexamethasone intravitreal implant in patients with macular edema due to retinal vein occlusion. *Ophthalmology* 2010;117:1134-46.e3.
22. Unsal E, Eltutar K, Sultan P, Erkul SO, Osmanbasoglu OA. Efficacy and safety of intravitreal dexamethasone implants for treatment of refractory diabetic macular edema. *Korean J Ophthalmol* 2017;31:115-22.