



# Methodology in Conventional Head and Neck Reconstruction Following Robotic Cancer Surgery: A Bridgehead Robotic Head and Neck Reconstruction

Jongmin Won<sup>1</sup>, Jong Won Hong<sup>1</sup>, Mi Jung Kim<sup>1</sup>, In-sik Yun<sup>1</sup>, Woo Yeol Baek<sup>1</sup>,  
Won Jai Lee<sup>1</sup>, Dae Hyun Lew<sup>1</sup>, Yoon Woo Koh<sup>2</sup>, and Se-Heon Kim<sup>2</sup>

<sup>1</sup>Department of Plastic and Reconstructive Surgery, Severance Hospital, Yonsei University College of Medicine, Seoul;

<sup>2</sup>Department of Otorhinolaryngology, Severance Hospital, Yonsei University College of Medicine, Seoul, Korea.

**Purpose:** Robotic head and neck surgery is widespread nowadays. However, in the reconstruction field, the use of robotic operations is not. This article aimed to examine methodologies for conventional head and neck reconstruction after robotic tumor surgery in an effort to obtain further options for future reconstruction manipulations.

**Materials and Methods:** A retrospective review of all patients who received head and neck robot surgery and conventional reconstructive surgery between October 2016 and September 2021.

**Results:** In total, 53 cases were performed. 67.9% of the tumors were greater than 4 cm. Regarding defect size, 47.2% of the lesions were greater than 8 cm. In terms of TNM stage, stage 3 disease was recorded in 26.4% and stage 4 in 52.8%. To make a deep and narrow field wider, we changed the patient's posture in pre-op field, additional dissection was done. We used radial forearm flap mostly (62.2%).

**Conclusion:** Conventional head and neck reconstruction after robotic ENT cancer surgery is possible. One key step is to secure additional space in the deep and narrow space left after robotic surgery. For this, we opted for a radial forearm flap mostly. This can be performed as a bridgehead to perform robotic head and neck reconstruction.

**Key Words:** Head neck cancer, robotic surgery, plastic reconstructive surgery

## INTRODUCTION

Despite being around for quite some time, robot-assisted surgery (RAS) has only gained prevalence and widespread use in the early 21st century. Most robotic systems have been used in the removal of cancerous lesions of visceral organs for several reasons.<sup>1</sup> Because of its minimally invasive nature, RAS has

been found to reduce pain post-surgery, to allow for rapid recovery, and to provide cosmetic benefits. RAS has gained headway due to advantages of extensive scope capabilities and magnification over endoscopes,<sup>2</sup> which have led to more prevalent applications in the field of head and neck cancers.<sup>3-8</sup>

Robot-assisted head and neck surgery (Robt HN-surg) can be subdivided into two categories: trans-oral robot surgery (TORS) and retromandibular or retro-auricular incisions with robot-assisted neck dissections (Robt-ND).<sup>4,5,8-12</sup> While TORS was initially popular in smaller tumorous lesions involving T1 and T2 stages,<sup>13</sup> its application has been expanded to T3 and T4 stages.<sup>6,14</sup> However, these larger, more advanced lesions call for wider excisions that ultimately call for reconstruction.<sup>15</sup> For the reconstructive surgeon, conventional methods of reconstruction following Robt HN-surg present several challenges mostly related to the narrow and deep aspects of the reconstructive field.<sup>4,6,9,16</sup> This is particularly the case when attempting to secure aim microscopes for microsurgery following robot

**Received:** March 24, 2022 **Revised:** April 20, 2022

**Accepted:** April 28, 2022

**Corresponding author:** Jong Won Hong, MD, PhD, Department of Plastic and Reconstructive Surgery, Severance Hospital, Yonsei University College of Medicine, 50-1 Yonsei-ro, Seodaemun-gu, Seoul 03722, Korea.  
Tel: 82-2-2228-2210, Fax: 82-2-393-6947, E-mail: hsaturn@hanmail.net

•The authors have no potential conflicts of interest to disclose.

© Copyright: Yonsei University College of Medicine 2022

This is an Open Access article distributed under the terms of the Creative Commons Attribution Non-Commercial License (<https://creativecommons.org/licenses/by-nc/4.0>) which permits unrestricted non-commercial use, distribution, and reproduction in any medium, provided the original work is properly cited.

neck dissections. For these aforementioned reasons, research into reconstruction following TORS has gained momentum: initial explorations of reconstruction following TORS focused on secondary healing and local flaps.<sup>8,17-20</sup> Overtime, this research expanded to reconstruction using free flaps (both flap in-setting and microsurgery).<sup>1,2,9,21,22</sup> Notwithstanding, further research on robot reconstruction is limited, as most reconstruction following TORS integrates conventional reconstructive surgery.

This lack of research has created challenges in generalizing robot reconstruction<sup>1,2,22</sup> and thus, reconstruction following Robt HN-surg is not necessarily followed with robotic reconstruction. Given the fact that the environment of reconstruction following Robt HN-surg is drastically different from that following conventional head and neck surgery (Conv HN-surg),<sup>4,6,9,16</sup> reconstructive surgeons needs to adapt their technical skills in reconstruction following Robt HN-surg and even consider shifting all together to robot reconstruction. This article aims to analyze conventional methods of reconstruction using free flaps following Robt HN-surg and to review the methodologies of surgeons in the challenging yet growing field of robot reconstruction.

## MATERIALS AND METHODS

### Study design and outcome assessment

This retrospective study analyzed 53 cases of conventional reconstruction following Robt HN-surg from October 2016 to September 2021. All reconstruction surgeries were performed by a single surgeon (JW.H). Robot-assisted wide excision (Robt-WE) or Robt-ND were both considered Robt HN-surg. Conventional methods of surgery without a robot were classified as conventional wide excision (Conv-WE) and conventional neck dissection (Conv-ND).

The following variables were analyzed: patient demographics, tumor characteristics, type of flap, and vessels used for anastomosis. For the purposes of overcoming the geospatial challenges of reconstruction following Robt HN-surg, we subdivided regions based on tumor size and location and named them regions 1 through 7. This study design was approved by our Institutional Review Board (No. 4-2021-1359).

### Reconstruction preparation: defect evaluation and securing the operation field

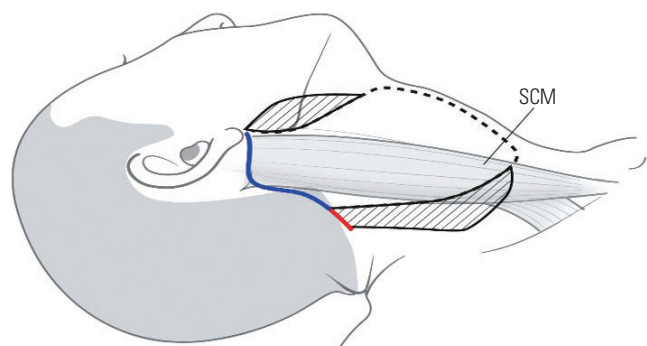
Following Robt-WE or Robt-ND, resection defects and anastomosis sites are located in deep and narrow spaces. It becomes important to analyze the defect's geometry, remaining mucosa margin, and locations available for suturing. One of the trickiest aspects of conventional reconstruction following Robt HN-surg is visualization of the operation field. In order to visualize and secure the surgical field, the surgeon needs to retract the surrounding tissue. However, too much traction can cause compression of nearby tissue or even retract the flap. Early conven-

tional reconstruction following Robt HN-surg relied on the use of the Dingman mouth retractor that was used in TORS. This ultimately caused deformation of normal tissue and geometry of the surgical field. Ultimately, we used other devices, such as a bite block, cheek retractor dental mouth gag, army retractor, and tongue depressor, in order to retract only the minimal necessary field and prevent deformation of surrounding tissue. Primary repair locations that were visible did not require retraction. The surgeon sutured the following sites via the neck dissection field rather than through the oral cavity: deep in the tongue base, vallecular space, deep oropharynx, and upper hypopharynx. Robt-ND created a retromandibular incision that is located laterally.<sup>23</sup> Because the incision site is posterior to the sternocleidomastoid muscles, the reconstructive surgeon made additional incisions in order to expose vessels medial to the sternocleidomastoid. The following additional incisions were made: 1.5-2-cm incision along the hairline inferiorly and near the ear lobule superiorly. If there was a post ENT operative wound that extended to the ear lobule, we did not make an extra incision. Dissection was performed lower, over the sternocleidomastoid and, for the upper part, over the submandibular gland and over the mandible lower margin, all the while being careful not to injure the external jugular vein (EJV) and marginal branch of the facial nerve (Fig. 1).

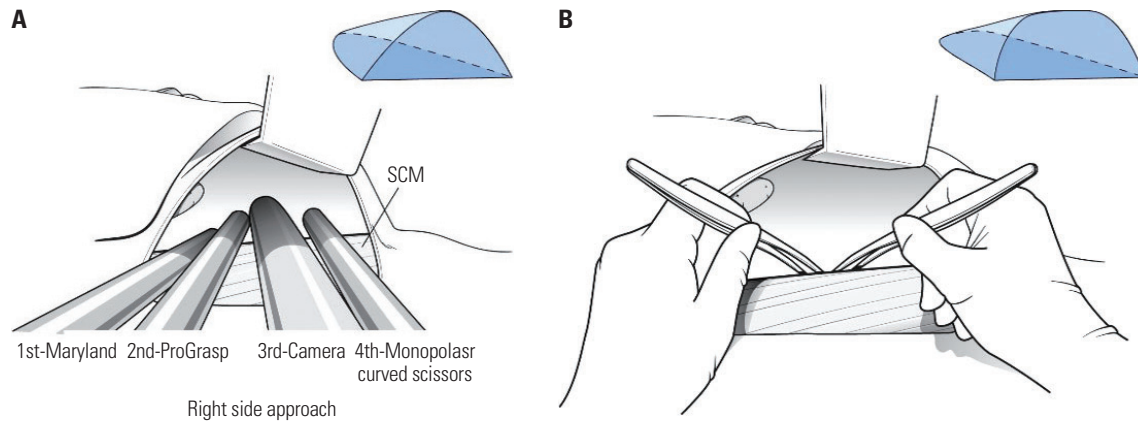
A Richardson retractor with accessory device was used to raise the neck flap in a superior medial direction, while tagging sutures were used for redundant flaps and remaining structures (Figs. 2 and 3).

### Reconstruction: flap selection and inseting

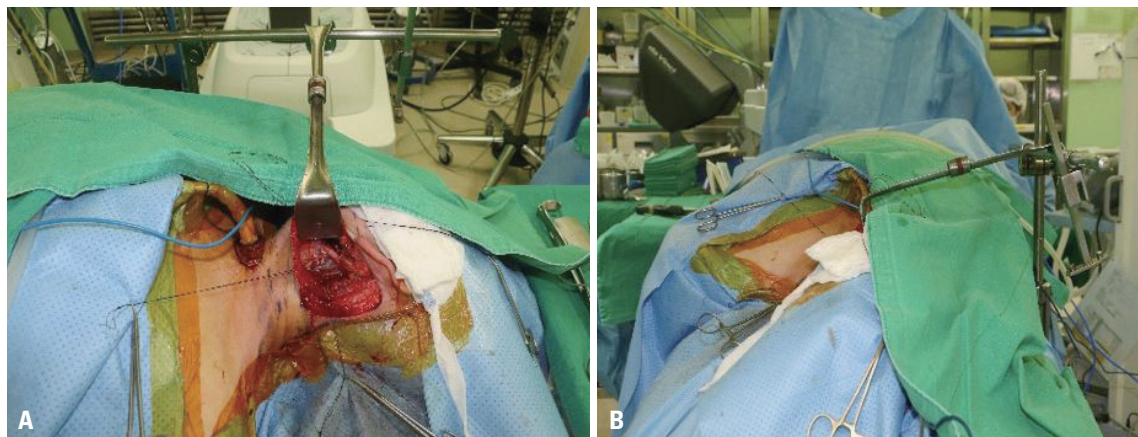
In order to view the narrow surgical field following TORS, we needed to retract the surrounding tissue. However, this could lead to retraction of the defected area and ultimately cause mismeasurement. It was very important that we maintain the neutral state of the defect without it getting extended for flap measurement.



**Fig. 1.** A schematic diagram of post robot neck dissection wound. Blue line means ENT incision, red is PS additional incision for inseting. The dotted line is medial border for dissection, two areas with slash line mean borderline of upper-lower dissection margin. SCM, sternocleidomastoid muscle.



**Fig. 2.** A schematic diagram of ENT robot surgery field (A) and PS reconstruction field (B). SCM, sternocleidomastoid muscle.



**Fig. 3.** (A) Operator's view before micro-anastomosis. (B) Axial view for OP field in same patient. OP, operation.

Flap selections were made based on various factors, including the defect's area, state of the surrounding space following Robt-WE, the recipient vasculature conditions, and flap thickness. Radial forearm flaps (RFF) were the first choice during the flap selection process (with the exception of flaps that needed bone) for several reasons. First, the flap's volume could interfere with flap in-setting because of the narrow and deep nature of the surgical area, thus making the naturally thinner RFF a good option. Second, a longer flap than typically used was needed because the flap needed to be longer pedicle used for anastomosis since anastomosis was usually performed laterally from the incision in Robt-ND (Fig. 2). In cases where the patient had thin thigh muscles, we considered an anterolateral thigh (ALT) flap.

We also created a tunnel that was wide enough for the pedicle to pass comfortably. In order for the pedicle to pass, we performed a few key sutures first before completing the remaining sutures to prevent the flap from moving or deforming.

### Reconstruction: microsurgery

Securing space in the neck area and successful retraction did not necessarily translate into sufficient space to perform vascular anastomosis. Thus, we found it most advantageous to

perform anastomosis near the lateral border of the incision. We dissected the superior thyroid artery to be as long as possible and used this for arterio-arterial anastomosis. Given the thin and fragile nature of veins, we prevented vein kinking by maintaining the original location of the vein. The EJV was used in instances where our original selection for vein anastomosis turned out to be too deep or complex. In cases where this was not even possible, we created a window 2–3 cm immediately superior to the neck flap to perform venovenous anastomosis (Fig. 4). Conventional methods were used to perform venovenous anastomosis. Lastly, we found that the vessels could kink or become compressed by the microscope when returning the patient's rotated neck to a neutral position following completion of anastomosis. Thus, this warranted careful observation of the vasculature when changing positions.

### Other processes and considerations

Hemovac drains were typically positioned away from the pedicle and EJV. In cases where the EJV was used for anastomosis, one drain was placed anteriorly and another posteriorly to the EJV (Fig. 5). Levin tubes may or may not have been inserted during TORS; however, Levin tube insertion was necessary in reconstruction following Robt HN-surg. We found that the use



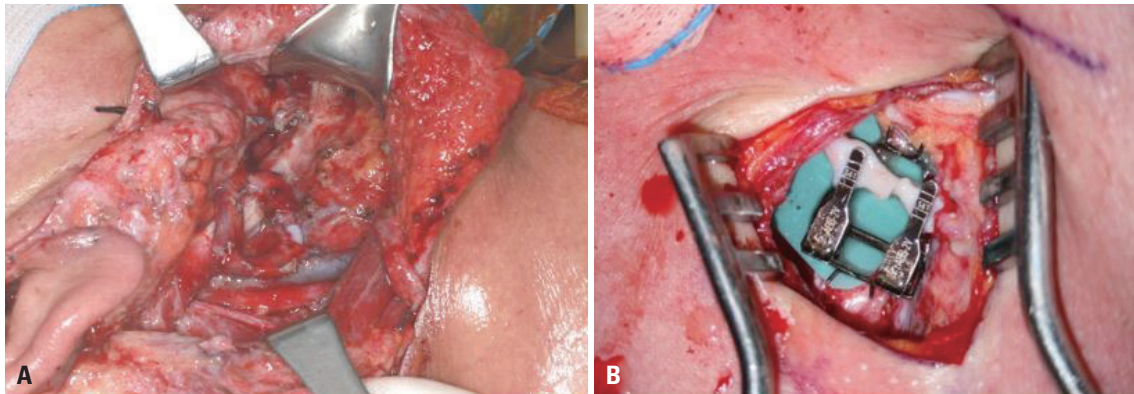


Fig. 4. (A) A loop type setting of arterioarterial microanastomosis. (B) A window above neck flap to perform venovenous microanastomosis.

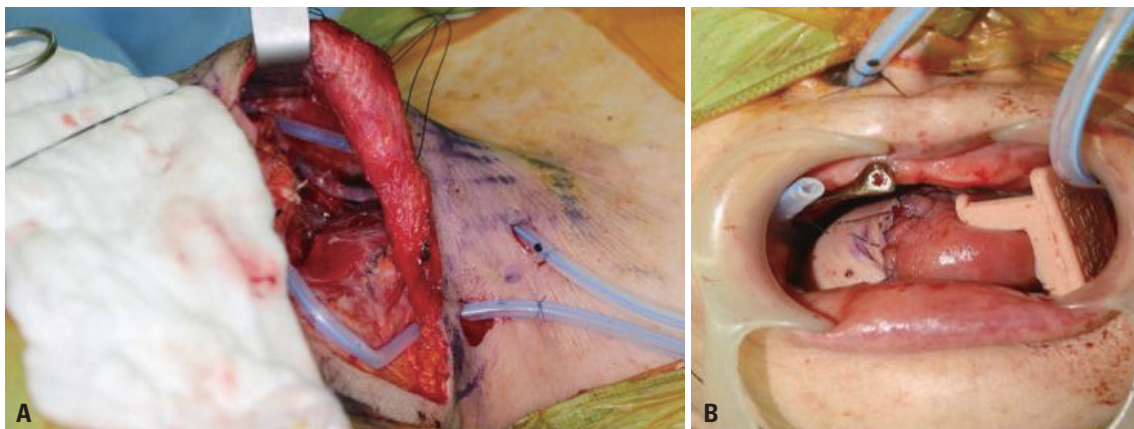


Fig. 5. (A) A photo of hemovac insertion. One on prior EJV, the other on backward EJV. (B) A photo of continuous irrigation system. EJV, external jugular vein.

Table 1. Demographic Data of Patients Undergoing Robotic ENT Surgery (n=53)

Age (yr)	No.
21–30	1
31–40	4
41–50	10
51–60	18
61–70	17
71–	3

of a continuous suction system in the oral cavity and hypopharynx helped limit saliva leaking following surgery (Fig. 5).<sup>24</sup> Lastly, tracheostomy was performed to bypass the obstructed airway during surgery.

## RESULTS

Of the 53 cases in this study, there were 36 male patients and 17 female patients whose ages ranged from 27 to 78 years old (mean age of 55). The majority of patients was in their fifties (18 total) and sixties (17 total) (Table 1). Of the types of surgeries performed, 20 cases were both Robt-WE and Robt-ND; 8

Table 2. Proportion of Robotic Surgeries (n=53)

Type of surgery	No. (%)
Robt-WE+Robt-ND	20 (37.7)
Robt-WE+Conv-ND	8 (15.1)
Conv-WE+Robt-ND	25 (47.2)

Robt-WE, robot-assisted wide excision; Robt-ND, robot-assisted neck dissection; Conv-WE, conventional wide excision; Conv-ND, conventional neck dissection.

cases were Robt-WE and Conv-ND; and 25 cases were Conv-WE and Robt-ND (47.2%) (Table 2). Of the operation locations, the majority of cases (28 cases total) involved region 2 (the tongue and floor of mouth or mandible); 10 cases involved region 3 (oropharynx); and 6 cases involved region 4 (oropharynx and oral cavity) (Table 3).

We only analyzed operations using robotic surgery. There were 22 cases of Robt-WE with or without neck dissections. There were 45 cases of Robt-ND with or without wide excisions (Table 4). Overall, regardless of whether a wide excision or neck dissection was performed, operations with a robot mostly involved region 2, with a total of 32 cases (47.8%), and region 4, with a total of 10 cases (14.9%). When looking at Robt-WE, involvement of the oropharynx (regions 3 and 4) was recorded in most cases, while for Robt-ND, 28 cases involved region 2

**Table 3.** Categorization Based on Tumor Location for Reconstruction following Robt HN-Surg

Lesion	Robt-WE+Robt-ND	Robt-WE+Conv-ND	Conv-WE+Robt-ND	Total (%)
1. Oral cavity (buccal, soft palate)	1	0	0	1 (1.9)
2. Oral cavity (tongue, FOM, mandible)	4	0	24	28 (52.8)
3. Oropharynx (tonsil, RMT, BOT, posterior wall)	5	4	1	10 (18.9)
4. Oropharynx+oral cavity (except tongue)	4	2	0	6 (11.3)
5. Oropharynx+tongue	1	0	0	1 (1.9)
6. Hypopharynx	2	0	0	2 (3.8)
7. Hypopharynx+larynx	4	1	0	5 (9.4)

Robt HN-surg, robot-assisted head and neck surgery; Robt-WE, robot-assisted wide excision; Robt-ND, robot-assisted neck dissection; Conv-WE, conventional wide excision; Conv-ND, conventional neck dissection; FOM, floor of mouth; RMT, retromolar trigon; BOT, base of tongue.

**Table 4.** Defect Classification of Robt-WE and Robt-ND

Lesion	Robt-WE (n=22)	Robt-ND (n=45)	Total (%)
1. Oral cavity (buccal, soft palate)	1	1	2 (3.0)
2. Oral cavity (tongue, FOM, mandible)	4	28	32 (47.8)
3. Oropharynx (tonsil, RMT, BOT, posterior wall)	3	5	8 (11.9)
4. Oropharynx+oral cavity (except tongue)	6	4	10 (14.9)
5. Oropharynx+tongue	1	1	2 (3.0)
6. Hypopharynx	2	2	4 (6.0)
7. Hypopharynx+larynx	5	4	9 (13.4)

Robt-WE, robot-assisted wide excision; Robt-ND, robot-assisted neck dissection; FOM, floor of mouth; RMT, retromolar trigon; BOT, base of tongue.

**Table 5.** Tumor Size, Defect Size, and TNM Stage (n=53)

Variables	No. (%)
Tumor size	
<4 cm	17 (32.1)
≥4 cm	36 (67.9)
Defect size	
<8 cm	28 (52.8)
≥8 cm	25 (47.2)
T category	
Tis	1 (1.9)
1	7 (13.2)
2	12 (22.6)
3	16 (30.2)
4	17 (32.1)
TNM stage	
0	1 (1.9)
1	5 (9.4)
2	5 (9.4)
3	14 (26.4)
4	28 (52.8)

(Table 4). Overall, this data showed that Conv-WE was performed for lesions that were identifiable by the naked eye and easily removable. However, TORS was used in lesions located deep within the oral cavity or oropharynx. While we did not

**Table 6.** Type of Reconstruction Flap

	Radial forearm	ALT	Fibula	Total
1. Oral cavity (buccal, soft palate)	0	1	0	1
2. Oral cavity (tongue, FOM, mandible)	19	7	2	28
3. Oropharynx (tonsil, RMT, BOT, posterior wall)	6	4	0	10
4. Oropharynx+oral cavity (except tongue)	4	2	0	6
5. Oropharynx+tongue	0	1	0	1
6. Hypopharynx	2	0	0	2
7. Hypopharynx+larynx	2	3	0	5
Total	33 (62.2)	18 (34.1)	2 (3.7)	53

FOM, floor of mouth; RMT, retromolar trigon; BOT, base of tongue; ALT, antero-lateral thigh.

analyze differences based on the surgeon, the decision to perform Robt-ND depended on the surgeon.

When looking at tumor size and defect size, 67.9% of the tumors were larger than 4 cm. Among defects involving a wide excision, 47.2% of the lesions were greater than 8 cm. Excluding Tis, the majority of cases was T3 (30.2%) and T4 (32.1%), and only 13.2% were T1. Regarding TNM stages, the majority of cases involved T3 (26.4%) and T4 (52.8%) (Table 5). The majority of flaps used were RFF (62.2%): region 2 in 67.8% (19/28), region 3 in 60% (6/10), and region 4 in 66.75% (4/6) (Table 6).

All anastomoses were performed in the neck dissection region. Arterial anastomosis involved mostly the superior thyroid artery (47 cases). For venous anastomosis in Robt-ND, 15 cases involved one anastomosis, while 30 cases involved two anastomoses, which mostly involved the superior thyroid vein or IJV branch. In Conv-ND, one case involved one anastomosis, while seven cases involved two anastomoses. There were no anastomoses involving the EJV (Table 7). Pathology analysis showed that 45 cases were squamous cell carcinoma, six cases were ACC, and one case was myoepithelial cancer and rhabdomyosarcoma. 24 cases involved CCRT; 14 cases involved RT; and five cases involved CT. Regarding complications, there were two cases of partial necrosis and two cases of total necrosis. There were no other instances of infection, dehiscence, or stricture (Table 8).

**Table 7.** Type of Vein Used for Anastomosis

Robt-ND	One recipient vein (n=15)	Two recipient veins (n=30)	Total	Conv-ND	One recipient vein (n=1)	Two recipient veins (n=7)	Total
Total vein anastomosis	15	60		Total vein anastomosis	1	14	
Superior thyroidal vein	4 (26.7)	19 (31.7)	23	Superior thyroidal vein	1 (100.0)	5 (35.7)	6
IJV br.	5 (33.3)	28 (46.7)	33	IJV br.	0 (0.0)	9 (64.3)	9
EJV	6 (40.0)	13 (21.7)	19	EJV	0 (0.0)	0 (0.0)	0

Robt-ND, robot-assisted neck dissection; Conv-ND, conventional neck dissection; IJV, internal jugular vein; EJV, external jugular vein.

**Table 8.** Postoperative Complications

Complication	No.
Partial necrosis	2
Total necrosis	2
Infection	2
Dehiscence	1
Stricture	1
Fistula	2

## DISCUSSION

Until now most articles on robot reconstruction have described the possibilities and potential benefits thereof based on experience.<sup>4,6,10,16,17,20,25</sup> Yet, little has been persuasive enough to cause a shift in robotic reconstruction for several reasons.<sup>1,17</sup> Areas for reconstruction are typically exposed, and there is just not a pressing need for robotic surgery.<sup>2</sup> In addition to the costs of the devices, most robots have not been designed for reconstruction but rather for removal of lesions.<sup>2,10</sup> Reconstruction also requires greater surgical area than excision or removal procedures because of its “stocking and making” nature. Processes such as suturing flaps require more space for the robot arms to move. While many more surgeons have become more comfortable with performing vascular anastomosis, there are limited microsurgical instruments for robotic surgery.<sup>10,26-29</sup> Thus, there is an increasing need for development of diverse robot instruments.<sup>10,26</sup>

We have made efforts to perform reconstruction using robotic surgery, but have found that the previously mentioned challenges ultimately lead us to perform most reconstructions using conventional methods. While, there have been a few key developments in reconstruction following Robt HN-surg among reconstruction surgeons,<sup>4,6,10,20</sup> there are a limited number of cases that ultimately make it difficult for surgeons to abandon conventional reconstruction all together. Using conventional procedures of reconstruction on patients who have undergone robotic surgery in head, eyes, ears, nose, and throat have forced us to ascertain methodologies to adapt to novel circumstances. Ultimately, we decided to share our *modus operandi* in hopes that this may be helpful in the impending development of robot reconstruction.

Our hope was that our methods and categorization based on tumor location for reconstruction following Robt HN-surg

would aid in future robotic reconstruction developments. The first distinction we made was whether lesions in the oral cavity would be visible with or without retraction. We found that the tongue served as a marker for whether retraction was necessary. This distinction became critical in deciding what type of flap to use, because the thicker the flap, the more difficult it was to perform sutures.

Our results show that robotic surgery in HEENT malignancies involves both wide excisions and neck dissections. TORS was most commonly performed in the oropharynx. Recent trends show surgeons make thyroid incisions in Robt-WE in the treatment of hypopharynx cancer: the decision to do Robt-ND depends on the surgeon’s preference. Previous articles on free flap reconstruction following Robt HN-surg showed limitations in tumors larger than 4 cm.<sup>4,10,17,20,29,30</sup> However, 67.9% of our cases involved tumors larger than 4 cm, which was in line with our data: 62.3% of cases were T3 and T4 and 79.2% of cases were TNM stages 3 and 4 (Table 5). We showed that reconstruction after robotic surgery of larger tumors was possible. In other words, a narrow and deep surgical field of robotic surgery needs not be a contraindication for reconstruction. When we looked at the geometry of the surgical space following excision, we found there were a few challenges when the defect was not visible. First, we had to retract part of the space, which could lead to an overestimation of the defect size. We also found it difficult lining up our prototype flap without retraction. Because of these difficulties, we often selected to do a RFF flap. We only considered an ALT flap if we needed a longer or thicker flap. However, thicker ALT flaps were difficult to suture in the absence of visibility.

In addition to flap insertion difficulties, selecting and connecting recipient vessels for anastomosis posed other challenges. Following Robt-ND, anastomosis is attempted from the lateral side of the patient, which requires the use of longer forceps like Jeweler forceps. In order to overcome the discomforts of using Jeweler forceps, we tried to maintain the longest length possible for either donor or recipient vessels so that anastomosis could be performed closest to the incision site. For arterial anastomosis, we primarily used the superior thyroid artery. For venous anastomosis, we had more flexibility given the neck plexus. The EJV was not a preferred choice because flow was not consistent during increased thoracic cavity pressure, and often it would already have a thrombus from being cut before anastomosis. Despite this, if the EJV was used, we

would ensure there was no thrombus or would remove any present. We ensured that the EJV did not get injured during dissection or tagging retraction. It was important that the EJV and Hemovac drain did not intersect. In our study, the EJV was only used in Robt-ND. We informed the neck dissection surgeon of our intent to use the EJV for reconstruction.

It can be assumed that Robt-WE (TORS)+Conv-ND and Conv-WE+conv-ND are not different. However, there is much more remnant normal tissue in TORS, and the surgical field is different even if Conv-ND is done. Significant retraction is necessary for surgeons in Robt HN-surg to reach deep lesions. This causes significant edema, especially during the suturing of flaps in the tongue base and vallecula area. Because we were aware of edema of surrounding tissue, we often performed a tracheostomy. In cases where we performed oral intubation or nasal intubation, we had to proceed with caution during retraction because retraction often shifted or pressed on the intubation tubes. In these cases, we also often performed a tracheostomy following completion of reconstruction because of the possibility of edema developing in the neck. Bottom line, reconstruction following HEENT robotic surgery requires thorough discussion with anesthesiologists.

We made tunnels for the pedicle and vessels wide enough so that they would not be put under too much pressure by nearby tissues and edema following robotic surgery. If there was a chance the pedicle would be pressed or vessels kinked despite our efforts, we chose not to use an ALT flap. In our cases, there were two total necrosis cases—one of which was a hemiglossectomy followed by ALT reconstruction that become necrotic, most likely because of a kinked pedicle. Despite the necrotic flap, the pedicle perfusion was good before the anastomosis site. We ultimately removed the necrotic ALT flap and replaced it with a RFF flap 4 days later. We learn from this case. Dissection to pass the pedicle should be much wider. If the defect is deep and narrow, we should choose an RFF, for which the pedicle is straighter and thicker. The other total necrosis case involved a narrow and long defect (8×3 cm). We took a RFF flap to cover it up, but the flap become necrotic. The defect was healed by secondary healing. From this case, we learned that if a defect is able to be closed by primary repair, it should be.

There are a few articles on the possibility of saliva leakage or iatrogenic fistulas arising during tunneling in reconstruction following TORS.<sup>31,32</sup> We found that these possibilities were nominal, which was supported by other articles.<sup>4,20</sup> In fact, we argue that it is more important to make a wide excision that allows for successful flap reconstruction in spite of a risk of a fistula forming. Moreover, we believe that a defective margin or incomplete connection to the flap may cause a fistula in Robt HN-surg. To prevent this situation, we found it important to ensure all margins are cut linearly and also to perform primary repair in cases where traction is difficult and flap suturing may be challenging due to a narrow surgical space.

Overall, we were satisfied with the results in all of our cases.

However, from the standpoint of the surgeon, positioning during surgery was awkward and uncomfortable. We have been fortunate enough to not have had to use a pectoralis major flap, but we wonder if a pectoralis major flap would even fit in an incision made in robotic surgery. The purpose of HEENT surgery is to remove a cancerous lesion and ultimately regain normal function through reconstruction. Robotic surgery has been shown to be beneficial in even larger lesions. While there are challenges in reconstruction following robotic surgery, we have shown that reconstruction is indeed possible. We hope that this article touches upon ideas that can be used to further develop reconstruction in the field of robotic surgery. Though our novel or unconventional techniques may seem elaborate at first, our ultimate aim was to benefit patient outcomes. We share the same sentiments as Arora, et al.<sup>20</sup> on conventional reconstruction following Robt HN-surg and hope our review assists other surgeons contemplating reconstruction following Robt HN-surg and those interested in the development of robot reconstruction.

There are limitations to this study. First, comparison with robotic surgery and conventional surgery was not done. Until now, robotic head and neck cancer surgery is not a main method. In a prior study, patients with stage 1 or 2 cancer underwent reconstruction surgery with TORS. However, we now perform surgery for patients with severe cancer stages (3, 4). In the aspect of robotic neck dissection, this center is a pioneer for this surgery, and we need more robotic cases and further study for comparisons directly with conventional surgery. Second, this article is based on single-center, single reconstruction plastic surgeon. A learning curve is needed to create and modulate a surgical environment, compared to conventional reconstruction.

We performed 53 cases of free flap conventional reconstruction following Robt HN-surg. Using various techniques of retraction, we secured enough visual space to perform reconstruction after Robt-WE or Robt-ND. We also changed the patient's position so that we could employ a vertical approach using our microscope. We were even able to perform free flap reconstruction following large tumor removals and mostly used RFF. For arterial anastomosis, we mostly used the superior thyroid artery because of its extensive length and ease in dissection. For vein anastomosis, the chances of using the EJV were high, so we tended to preserve neck dissection in advance. These efforts allowed us to perform reconstruction after Robt HN-surg; which in turn ultimately allowed HEENT surgeons to remove large tumors using Robt HN-surg to begin with.

## ACKNOWLEDGEMENTS

The authors thank Medical Illustration & Design, part of the Medical Research Support Services of Yonsei University College of Medicine, for all artistic support related to this work. We also appreciate Mr. Dong-su Jang who worked on the illustration.

This study was supported by a faculty research grant from



the Yonsei University College of Medicine (6-2017-0065).

## AUTHOR CONTRIBUTIONS

**Conceptualization:** Jong Won Hong. **Data curation:** Jongmin Won and Mi Jung Kim. **Formal analysis:** Jong Won Hong and Jongmin Won. **Funding acquisition:** Jong Won Hong. **Investigation:** Jongmin Won and Mi Jung Kim. **Methodology:** Jong Won Hong. **Project administration:** Jong Won Hong and Jongmin Won. **Resources:** In-sik Yun and Woo Yeol Baek. **Software:** Jong Won Hong and Jongmin Won. **Supervision:** Won Jai Lee and Dae Hyun Lew. **Validation:** Yoon Woo Koh and Se-Heon Kim. **Visualization:** Jongmin Won and Jong Won Hong. **Writing—original draft:** Jong Won Hong and Jongmin Won. **Writing—review & editing:** Jongmin Won. **Approval of final manuscript:** all authors.

## ORCID iDs

Jongmin Won	<a href="https://orcid.org/0000-0002-0827-7915">https://orcid.org/0000-0002-0827-7915</a>
Jong Won Hong	<a href="https://orcid.org/0000-0002-7762-0940">https://orcid.org/0000-0002-7762-0940</a>
Mi Jung Kim	<a href="https://orcid.org/0000-0002-7126-6661">https://orcid.org/0000-0002-7126-6661</a>
In-sik Yun	<a href="https://orcid.org/0000-0003-1103-7047">https://orcid.org/0000-0003-1103-7047</a>
Woo Yeol Baek	<a href="https://orcid.org/0000-0002-6638-4110">https://orcid.org/0000-0002-6638-4110</a>
Won Jai Lee	<a href="https://orcid.org/0000-0003-3056-0503">https://orcid.org/0000-0003-3056-0503</a>
Dae Hyun Lew	<a href="https://orcid.org/0000-0002-2625-5664">https://orcid.org/0000-0002-2625-5664</a>
Yoon Woo Koh	<a href="https://orcid.org/0000-0002-9734-1682">https://orcid.org/0000-0002-9734-1682</a>
Se-Heon Kim	<a href="https://orcid.org/0000-0002-6407-5859">https://orcid.org/0000-0002-6407-5859</a>

## REFERENCES

- Hassanein AH, Mailey BA, Dobke MK. Robot-assisted plastic surgery. *Clin Plast Surg* 2012;39:419-24.
- Struk S, Qassemayr Q, Leymarie N, Honart JF, Alkhashnam H, De Fremicourt K, et al. The ongoing emergence of robotics in plastic and reconstructive surgery. *Ann Chir Plast Esthet* 2018;63:105-12.
- McLeod IK, Mair EA, Melder PC. Potential applications of the da Vinci minimally invasive surgical robotic system in otolaryngology. *Ear Nose Throat J* 2005;84:483-7.
- Park YM, Lee WJ, Yun IS, Lee DW, Lew DH, Lee JM, et al. Free flap reconstruction after robot-assisted neck dissection via a modified face-lift or retroauricular approach. *Ann Surg Oncol* 2013;20:891-8.
- Tae K, Ji YB, Song CM, Min HJ, Kim KR, Park CW. Robotic selective neck dissection using a gasless postauricular facelift approach for early head and neck cancer: technical feasibility and safety. *J Laparoendosc Adv Surg Tech A* 2013;23:240-5.
- Kim WS, Park JH, Byeon HK, Chang JW, Ban MJ, Koh YW, et al. A study comparing free-flap reconstruction via the retroauricular approach and the traditional transcervical approach for head and neck cancer: a matched case-control study. *Ann Surg Oncol* 2015;22 Suppl 3:S349-54.
- Ji YB, Song CM, Bang HS, Park HJ, Lee JY, Tae K. Functional and cosmetic outcomes of robot-assisted neck dissection by a postauricular facelift approach for head and neck cancer. *Oral Oncol* 2017;70:51-7.
- Byrd JK, Duvvuri U. Current trends in robotic surgery for otolaryngology. *Curr Otorhinolaryngol Rep* 2013;1:153-7.
- Roselló À, Albuquerque R, Roselló-Llabrés X, Marí-Roig A, Estrugo-Devesa A, López-López J. Transoral robotic surgery vs open surgery in head and neck cancer. A systematic review of the literature. *Med Oral Patol Oral Cir Bucal* 2020;25:e599-607.
- Song HG, Yun IS, Lee WJ, Lew DH, Rah DK. Robot-assisted free flap in head and neck reconstruction. *Arch Plast Surg* 2013;40:353-8.
- Garg A, Dwivedi RC, Sayed S, Katna R, Komorowski A, Pathak KA, et al. Robotic surgery in head and neck cancer: a review. *Oral Oncol* 2010;46:571-6.
- Kucur C, Durmus K, Gun R, Old MO, Agrawal A, Teknos TN, et al. Safety and efficacy of concurrent neck dissection and transoral robotic surgery. *Head Neck* 2016;38 Suppl 1:E519-23.
- Tae K, Ji YB, Song CM, Sung ES, Chung JH, Lee SH, et al. Feasibility of robot-assisted modified radical neck dissection by post-auricular facelift approach. *Int J Oral Maxillofac Surg* 2016;45:1351-7.
- Genden EM, Desai S, Sung CK. Transoral robotic surgery for the management of head and neck cancer: a preliminary experience. *Head Neck* 2009;31:283-9.
- Lallemant B, Moriniere S, Ceruse P, Lebalch M, Aubry K, Hans S, et al. Transoral robotic surgery for squamous cell carcinomas of the posterior pharyngeal wall. *Eur Arch Otorhinolaryngol* 2017;274:4211-6.
- Longfield EA, Holsinger FC, Selber JC. Reconstruction after robotic head and neck surgery: when and why. *J Reconstr Microsurg* 2012;28:445-50.
- Konofaos P, Hammond S, Ver Halen JP, Samant S. Reconstructive techniques in transoral robotic surgery for head and neck cancer: a North American survey. *Plast Reconstr Surg* 2013;131:188e-97.
- de Almeida JR, Park RC, Genden EM. Reconstruction of transoral robotic surgery defects: principles and techniques. *J Reconstr Microsurg* 2012;28:465-72.
- Avilés-Jurado FX, Vilaseca I. Transoral reconstruction of oropharyngeal tumors. The Hospital Clínic algorithm. *JPRAS Open* 2020;24:25-31.
- Arora R, Verma VK, Mishra KS, Bhoje H, Kapoor R. Reconstruction with free flaps in robotic head-and-neck onco-surgeries. *Indian J Plast Surg* 2018;51:283-9.
- Genden EM, Kotz T, Tong CC, Smith C, Sikora AG, Teng MS, et al. Transoral robotic resection and reconstruction for head and neck cancer. *Laryngoscope* 2011;121:1668-74.
- Bonawitz SC, Duvvuri U. Robotic-assisted FAMM flap for soft palate reconstruction. *Laryngoscope* 2013;123:870-4.
- Jung BK, Song SY, Kim SH, Kim YS, Lee WJ, Hong JW, et al. Lateral oropharyngeal wall coverage with buccinator myomucosal and buccal fat pad flaps. *Arch Plast Surg* 2015;42:453-60.
- Chang HP, Hong JW, Lee WJ, Kim YS, Koh YW, Kim SH, et al. Incorporating a continuous suction system as a preventive measure against fistula-related complications in head and neck reconstructive surgery. *Arch Plast Surg* 2018;45:449-57.
- Selber JC, Sarhane KA, Ibrahim AE, Holsinger FC. Transoral robotic reconstructive surgery. *Semin Plast Surg* 2014;28:35-8.
- van den Heuvel MGW, van der Hulst RRWJ. Robotic assistance in microvascular surgery. In: Bozovic V, editor. *Medical robotics*. Rijeka: IntechOpen; 2008.
- Saleh DB, Syed M, Kulendren D, Ramakrishnan V, Liverneaux PA. Plastic and reconstructive robotic microsurgery—a review of current practices. *Ann Chir Plast Esthet* 2015;60:305-12.
- Selber JC, Alrasheed T. Robotic microsurgical training and evaluation. *Semin Plast Surg* 2014;28:5-10.
- Lai CS, Lu CT, Liu SA, Tsai YC, Chen YW, Chen IC. Robot-assisted microvascular anastomosis in head and neck free flap reconstruction: preliminary experiences and results. *Microsurgery* 2019;39:715-20.
- Tsai YC, Liu SA, Lai CS, Chen YW, Lu CT, Yen JH, et al. Functional outcomes and complications of robot-assisted free flap oropharyngeal reconstruction. *Ann Plast Surg* 2017;78(3 Suppl 2):S76-82.
- de Almeida JR, Genden EM. Robotic assisted reconstruction of the oropharynx. *Curr Opin Otolaryngol Head Neck Surg* 2012;20:237-45.
- Moore EJ, Olsen KD, Martin EJ. Concurrent neck dissection and transoral robotic surgery. *Laryngoscope* 2011;121:541-4.