



Digital Dermatopathology and Its Application to Mohs Micrographic Surgery

Yeongjoo Oh^{1*}, Hye Min Kim^{2*}, Soon Won Hong², Eunah Shin², Jihee Kim¹, and Yoon Jung Choi²

Departments of ¹Dermatology and ²Pathology, Yongin Severance Hospital, Yonsei University College of Medicine, Yongin, Korea.

Digital pathology is being gradually adopted in hospitals due to technological advances. We propose that digital pathology can be used in Mohs micrographic surgery (Mohs surgery) to precisely check residual tumor cells in frozen tumor margin tissues. This would aid surgeons and pathologists in accurately recording tumor margins and give patients the benefit of shorter operation time.

Key Words: Mohs micrographic surgery, dermatology, clinical pathology, margin of excision, neoplasm

Digital pathology, which includes automated digital scanning of tissue slides, file storage, and displaying of files using high-resolution monitor, has existed for several decades. However, it has only been recently introduced and adopted in the clinical field, as a result of technological development with faster scanning time and higher graphic resolution.^{1,2}

In Yongin Severance hospital, the first hospital with a fully digitalized pathology system, all pathology slides are scanned and shared with clinicians, and used to actively communicate especially with dermatologists.

During clinical practice, dermatologists perform numerous skin biopsies as well as surgical procedures. Due to the plethora of dermatological conditions and subtle differences based on the natural course of disease, reviewing the biopsy specimen is essential for clinical and academic training of dermatologists.^{3,4} Accordingly, dermatologists study dermatopathology

during residency and in most training institutions; therefore, additional glass slides are utilized in the dermatology department. This creates conflict between the pathology and dermatology departments in several institutes due to the amount of resources used for sectioning and supplying additional slides. While using digital pathology, however, there would be no wasting of resources for sharing the slides, as the data would be digitally stored and can be shared via a computer and visualized on a high-resolution monitor.

Mohs micrographic surgery, a surgical procedure for skin cancer, which is performed mainly by dermatologists, can assess the complete tumor margin by examining the frozen section results of the outermost shell of margin tissue during surgery.⁵ When the frozen section result is found to be positive for tumor cells, surgeons visit the frozen section reading room to check precisely where the tumor cells remain among the margin areas using conventional pathology systems. With a digital pathology system, frozen margin tissues can also be scanned and shared. The pathologists can annotate the exact area where tumor cells exist, and surgeons can check the shared digital slides in the operation room (Fig. 1).

Compared to a conventional system, digital pathology system takes one more step of scanning the slide, which takes about 10–30 minutes; therefore, some time delay may occur in reporting pathology results (Fig. 2). However, the digital pathology system still saves time for both surgeons and pathologists, as they do not have to move from the operating room to the pathology room.

One of the advantages of a digital pathology system is its reproducibility. In a conventional system, pathologists directly describe the microscopic findings of frozen section of the tumor

Received: September 8, 2021 **Revised:** November 4 2021

Accepted: November 12, 2021

Co-corresponding authors: Jihee Kim, MD, PhD, Department of Dermatology, Yongin Severance Hospital, Cutaneous Biology Research Institute, Yonsei University College of Medicine, 363 Dongbaekjukjeon-daero, Giheung-gu, Yongin 16995, Korea. Tel: 82-2-2228-2080, Fax: 82-2-393-9157, E-mail: MYGIRLJIHEE@yuhs.ac and Yoon Jung Choi, MD, PhD, Department of Pathology, Yongin Severance Hospital, Yonsei University College of Medicine, 363 Dongbaekjukjeon-daero, Giheung-gu, Yongin 16995, Korea. Tel: 82-31-5189-8447, Fax: 82-31-5189-8247, E-mail: CHRIS316@yuhs.ac

*Yeongjoo Oh and Hye Min Kim contributed equally to this work.

•The authors have no potential conflicts of interest to disclose.

© Copyright: Yonsei University College of Medicine 2022

This is an Open Access article distributed under the terms of the Creative Commons Attribution Non-Commercial License (<https://creativecommons.org/licenses/by-nc/4.0>) which permits unrestricted non-commercial use, distribution, and reproduction in any medium, provided the original work is properly cited.

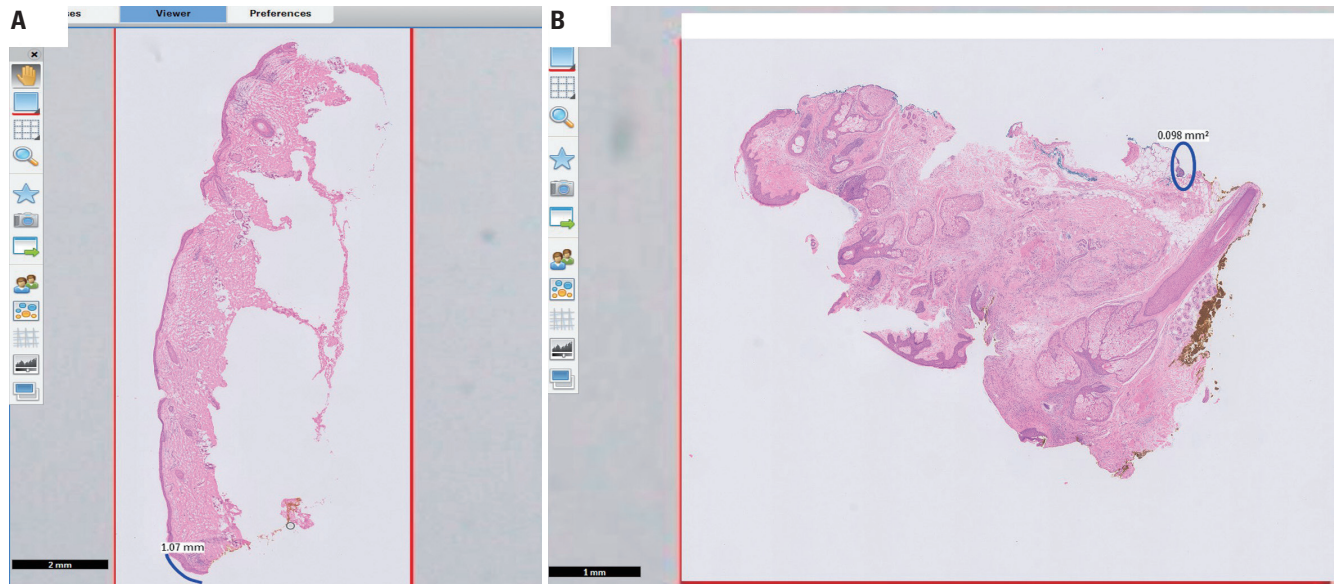


Fig. 1. Shared digital pathology of frozen margin during Mohs surgery. (A) Blue mark at the lateral tumor positive area. (B) Blue mark at the base focal tumor cell cluster.

Tissue sample	Clinician	Report	Tissue arrival time	Report time
Skin MMS margin #1-1	SK/ [redacted]	FFT (Free from tumor)	2021-06-17 09:17	2021-06-17 09:48
Skin MMS margin #1-2	SK/ [redacted]	FFT (Free from tumor)	2021-06-17 09:17	2021-06-17 09:48
Skin MMS margin #1-3	SK/ [redacted]	FFT (Free from tumor)	2021-06-17 09:17	2021-06-17 09:48
Skin MMS margin #1-4	SK/ [redacted]	PFM (Positive for malignancy)	2021-06-17 09:17	2021-06-17 09:48
Skin MMS margin #2-5	SK/ [redacted]	FFT (Free from tumor)	2021-06-17 10:43	2021-06-17 10:54

Fig. 2. Frozen pathology report during Mohs surgery with digital pathology. The upper four frozen tissues are tissues from the first Mohs stage. It took about 30 minutes for the tissues to arrive at the pathology department to be made into slides and scanned, and for the pathologist to report the results with scanned digital pathology. The last tissue is from the second Mohs stage, and it took only 10 minutes to arrive and be reported.

margin to the surgeon, which limits the exact pictorial description of positive margins. In a digital system, pathologists can freely mark or attach notes on the slide file. Even if the clinician is not as well-trained as the pathologist, they can quickly check the cancer cells and the area by checking the marked area only.⁶ Therefore, using a digital pathology system is convenient and precise when retrospectively reviewing the tumor margin during and after the surgery.

The advantages of digital pathology described above are also applicable to other procedures and surgeries, which require confirmation using frozen tissue results. In surgeries other than Mohs surgery, surgeons do not directly check the pathology slides, but only check whether the result for tumor cell is positive. However, with digital pathology, surgeons in the operating room can easily and accurately check tumor cell characteristics and locations via a computer screen.

Despite various advantages, there are still some technological challenges that must be overcome.^{2,3} Digitally scanned pathology specimens require much less physical storage area. However, each file could be of a massive size, requiring huge storage and server systems. Despite rapid advances in the scanning technology, thick specimens may present blurred focus due to resolution differences within the tissue. Additionally, when the slide is sectioned with some irregularity, it may be difficult to focus during scanning, and the area of interest could become blurred on the final scanned file. Nevertheless, these technological limitations will undoubtedly be resolved within few years. After overcoming these few limitations, additional benefits are expected in the era of digital pathology. Currently, additional pathology slides must be sectioned when transferring the patient to other hospitals. This sectioning of additional tissues requires several human and material resources and a greater

number of tissue samples. If most hospitals are equipped with a digital pathology system and such file exchange is legally recognized, hospitals can share patient pathology slides through simple file transfer without using additional resources.⁷

Digital pathology aids surgeons and pathologists in accurately recording tumor margins, which indirectly gives patients the benefit of reduced surgery time in Mohs surgery. With the reproducibility of digital pathology, the patient can get an explanation of the frozen slides even after the surgery. If the patient is referred to another hospital after the surgery, the patient can digitally carry pathology test results, including frozen slides, thereby minimizing physical and economic costs and efforts.

In addition, by applying artificial intelligence (AI) to the digital pathology system, faster and more accurate diagnosis may be possible. AI may not be able to confirm a diagnosis or describe the disease characteristics. However, it may aid pathologists to make a diagnosis and provide simple information to clinicians before pathologic confirmation.^{2,8} Moreover, AI can quickly identify tumor cells of frozen margins during surgery and shorten the operation time.⁸

Despite the technical and legal limitations at every hospital, digital pathology is expected to advance rapidly in a few years. Therefore, we propose that digital pathology be used in Mohs surgery, as it would be advantageous for both surgeons and pathologists, and give the benefit of shortened operation time to the patient.

AUTHOR CONTRIBUTIONS

Conceptualization: Yeongjoo Oh, Hye Min Kim, Jihee Kim, and Yoon Jung Choi. **Data curation:** all authors. **Formal analysis:** Yeongjoo Oh, Hye Min Kim, Jihee Kim, and Yoon Jung Choi. **Investigation:** Yeongjoo Oh, Hye Min Kim, Jihee Kim, and Yoon Jung Choi. **Methodology:** Yeongjoo Oh, Hye Min Kim, Jihee Kim, and Yoon Jung Choi. **Project administration:** all authors. **Resources:** all authors. **Supervision:** Jihee Kim and Yoon Jung Choi. **Validation:** Yeongjoo Oh and Hye Min Kim.

Visualization: Yeongjoo Oh and Hye Min Kim. **Writing—original draft:** Yeongjoo Oh, Hye Min Kim, and Jihee Kim. **Writing—review & editing:** Yeongjoo Oh, Hye Min Kim, Jihee Kim, and Yoon Jung Choi. **Approval of final manuscript:** all authors.

ORCID iDs

Yeongjoo Oh	https://orcid.org/0000-0003-4973-9335
Hye Min Kim	https://orcid.org/0000-0002-2899-9480
Soon Won Hong	https://orcid.org/0000-0002-0324-2414
Eunah Shin	https://orcid.org/0000-0001-5961-3563
Jihee Kim	https://orcid.org/0000-0002-0047-5941
Yoon Jung Choi	https://orcid.org/0000-0002-5701-8864

REFERENCES

1. Evans AJ, Salama ME, Henricks WH, Pantanowitz L. Implementation of whole slide imaging for clinical purposes: issues to consider from the perspective of early adopters. *Arch Pathol Lab Med* 2017; 141:944-59.
2. Nam S, Chong Y, Jung CK, Kwak TY, Lee JY, Park J, et al. Introduction to digital pathology and computer-aided pathology. *J Pathol Transl Med* 2020;54:125-34.
3. Blum AE, Murphy GF, Lee JJ. Digital dermatopathology: the time is now. *J Cutan Pathol* 2021;48:469-71.
4. Glines KR, Haidari W, Ramani L, Akkurt ZM, Feldman SR. Digital future of dermatology. *Dermatol Online J* 2020;26:2.
5. Mariwalla K, Aasi SZ, Glusac EJ, Leffell DJ. Mohs micrographic surgery histopathology concordance. *J Am Acad Dermatol* 2009;60: 94-8.
6. Marsch AF, Espiritu B, Groth J, Hutchens KA. The effectiveness of annotated (vs. non-annotated) digital pathology slides as a teaching tool during dermatology and pathology residencies 2014;41: 513-8.
7. García-Rojo M. International clinical guidelines for the adoption of digital pathology: a review of technical aspects. *Pathobiology* 2016;83:99-109.
8. Cui M, Zhang DY. Artificial intelligence and computational pathology. *Lab Invest* 2021;101:412-22.