



Comparison of Serum Anti-Mullerian Hormone-Level Changes in Single-Port Laparoscopic Endometriotic and Non-Endometriotic Ovarian Cyst Enucleations

Charmaine A. Cabiscuelas, Lan Ying Li, Ki Eun Seon, Yup Kim, Jae Hoon Lee, Eun Ji Nam, Jung-Yun Lee, Sunghoon Kim, Young Tae Kim, Sang Wun Kim

Women's Cancer Center, Yonsei Cancer Center, Department of Obstetrics and Gynecology, Institute of Women's Life Medical Science, Yonsei University College of Medicine, Seoul, Korea

Objectives: This study compared serum anti-Mullerian hormone (AMH) levels in endometriotic cysts (ECs) with those in non-ECs and analyzed changes thereof after single-port laparoscopic (SPL) ovarian cyst enucleation using vasopressin injection.

Methods: In total, 180 patients (EC group, $n = 112$; non-EC group, $n = 68$) who underwent SPL ovarian cyst enucleation were retrospectively reviewed. Their AMH levels were checked preoperatively, on postoperative day 10 (POD10), and on postoperative month 3 (POM3). Changes in AMH levels were analyzed according to tumor type and vasopressin use.

Results: The median initial and postoperative serum AMH levels in the EC group were significantly lower than those in the non-EC group (preoperation: 2.0 vs 3.8 ng/mL, $P < 0.001$; POD10: 1.0 vs 3.2 ng/mL, $P < 0.001$; POM3: 1.2 vs 3.6 ng/mL, $P < 0.001$). The postoperative decrease in AMH levels was higher in the EC group than the non-EC group on POD10 (0.8 vs 0.5 ng/mL, $P = 0.011$) but not on POM3 (0.7 vs 0.5 ng/mL, $P = 0.164$). Vasopressin injection during EC enucleation had no significant effect on the decrease in AMH levels on POD10 (vasopressin group vs non-vasopressin group: 1.0 vs 0.8 ng/mL, $P = 0.253$) and POM3 (vasopressin group vs non-vasopressin group: 1.4 vs 1.1 ng/mL, $P = 0.242$).

Conclusions: AMH levels were lower at baseline and had higher decreasing rates after SPL surgery in the EC group relative to the non-EC group. Vasopressin injection might not protect the ovary from the postoperative decrease in AMH levels.

Key Words: Anti-Mullerian hormone, Endometrioma, Laparoscopic cystectomy, Single-port laparoscopic surgery

INTRODUCTION

Benign ovarian masses are a frequent finding on pelvic examination and imaging studies in women during their reproductive years [1,2]. Surgery is warranted for large and symptomatic masses [2]. In such cases, if the patient is in her childbearing age, the surgeon should attempt to spare as much normal ovarian tissue as possible not only for fertility preservation but also to prevent early surgical menopause. Despite the controversies, laparoscopy is still the treatment of choice.

However, the use of single-port laparoscopic (SPL) surgery in cyst enucleation is not a well-studied area in terms of its effect on ovarian function. Prior studies have raised concerns as to whether SPL surgery causes more damage to normal ovarian tissue due to its restricted instrument mobility [3].

Ovarian reserve is defined as the pool of viable oocytes remaining in the ovary. Antral follicle count, serum follicular stimulating hormone (FSH), and anti-Mullerian hormone (AMH) are markers of ovarian reserve [4]. AMH is a glycoprotein produced by

Received: October 25, 2021 Revised: November 6, 2021 Accepted: November 10, 2021

Address for Correspondence: Sang Wun Kim, Department of Obstetrics and Gynecology, Institute of Women's Life Medical Science, Yonsei University College of Medicine, 50-1 Yonsei-ro, Seodaemun-gu, Seoul 03722, Korea

Tel: 82-2-2228-2230, E-mail: san1@yuhs.ac, ORCID: <https://orcid.org/0000-0002-8342-8701>

the granulosa cells of pre-antral follicles. Unlike FSH, AMH values are fairly constant and stable throughout the menstrual cycle, particularly in the low ranges [2].

The aim of this study was to determine how serum AMH levels change after SPL cyst enucleation on benign ovarian cysts and to compare AMH levels of histologically different ovarian cysts, particularly between endometriotic cyst and other benign cysts (mature cystic teratoma, mucinous cystadenoma, serous cystadenoma). We also aimed to determine if the use of vasopressin during surgery has an effect on AMH levels.

MATERIALS AND METHODS

Patient selection

Patients who underwent SPL ovarian cyst enucleation for benign masses from January 2017 to June 2018 at Yonsei Cancer Center of Severance Hospital (Seoul, Korea) were included. The medical records of these patients were reviewed. Patients who were diagnosed with benign ovarian cyst were included. Exclusion criteria were as follows: patients with (1) ovarian malignancies, (2) history of previous ovarian surgery, (3) presence of other endocrine diseases. All the surgeries were performed by two surgeons experienced in SPL surgery. All the patients had a final diagnosis of a benign ovarian cyst confirmed by histopathology. Serum AMH levels were obtained prior to surgery and repeated 10 days and 3 months after the surgery. This study was approved by the Institutional Review Board (IRB) of Yonsei University College of Medicine (approval No. 4-2018-1005) and the informed consent was waived by the IRB.

Operation technique

The conduct of the operation was similar for all the patients. Prophylactic antibiotics were administered 30 minutes prior to surgery. Each patient was placed in dorsal lithotomy position on Allen stirrups under general endotracheal anesthesia. Indwelling French 18 Foley catheter was inserted for continuous bladder drainage. All the procedures used a single three-channel port that was made using the Alexis retractor (Applied Medical, Rancho Santa Margarita, CA, USA) and a size 7 ½ surgical glove. Approximately 1.2 to 1.5 cm vertical intra-umbilical skin incision and 1.5 to 2 cm incision to the rectus fascia were made to enter the peritoneal cavity, through which the Alexis wound retractor was inserted. The outer ring of the wound retractor was

rolled with the wrist portion of the glove. Holes were made on three finger tips of the glove, to admit two 5-mm trocars and one 11-mm trocar. Pneumoperitoneum was attained with a pressure set at 12 mmHg. A rigid 30° 5 mm laparoscope was used [5]. The cyst enucleation procedure consisted of an incision on the ovarian cyst with monopolar L-hook, identification and removal of the cyst wall from the ovarian cortex by traction with atraumatic forceps, grasping forceps and suction irrigation system. Hemostasis was achieved using advanced energy device, Enseal (Ethicon Endo-Surgery, Cincinnati, OH, USA). For further hemostasis, hemostatic glue, Tisseel (Baxter Healthcare, Deerfield, IL, USA) was applied. The excised mass was placed in LapBag (Sejong Medical, Paju, Korea) to prevent leakage of contents.

For a subset of patients with a diagnosis of endometriotic cyst, diluted vasopressin (0.1 U/mL, i.e., 20 units diluted to 200 mL) was injected between the cyst wall and the normal ovarian cortex from the inside of the cyst as described by Saeki et al. [6] before removing the cyst walls. Multiple injections from different points were done to achieve hydrodissection until ballooning or swelling of the cyst wall was observed. Stripping was initiated from the point of leakage to differentiate the boundaries between the cyst wall and normal ovarian tissue.

Statistical analysis

Statistical analysis was performed using IBM SPSS Statistics (ver. 25.0; IBM, Armonk, NY, USA). Descriptive statistics was used to summarize the demographic and clinical characteristics of the patients. Frequency and proportion were used for categorical variables while median and inter quartile range were used for non-normally distributed continuous variables. Normally distributed continuous variables were demonstrated using mean and standard deviation. Independent sample *t* test, Mann–Whitney *U* test and Fisher's exact test were used to determine the difference of mean, rank and frequency between two independent groups, respectively. All statistical tests were two tailed tests. Shapiro–Wilk was used to test the normality of the continuous variables. Wilcoxon signed rank test was used to determine the difference in AMH levels from preoperation to 10 days and up to 3 months between patients with endometriotic cyst and non-endometriotic cyst. The patients were grouped according to preoperative AMH level and compared (Group 1: 1 to < 2 ng/mL, Group 2:

2 to < 4 ng/mL, Group 3: 4 to < 6 ng/mL, and Group 4: 6 to < 8 ng/mL). A subgroup analysis of patients with preoperative serum AMH of > 0.1 ng/mL was done to observe the magnitude of change. Missing variables was neither replaced nor estimated. Null hypotheses were rejected at 0.05 α -level of significance. To assess the change in AMH and rate of decline, the following formula were used:

(1) Rate of decline (%) = (preoperative AMH level – AMH after surgery)/preoperative AMH levels \times 100

(2) Change in AMH = preoperative AMH level – AMH after surgery

RESULTS

The baseline demographic characteristics and clinical profile of patients are shown in Table 1. Most of the patients with endometriotic cyst had serum AMH of less than 4 ng/mL. Two patients took oral pill before surgery. Fourteen patients (13%) postoperatively took dienogest (Visanne tab.; Bayer, Berlin, Germany) and 78 patients (70%) were injected leuprorelin acetate (Leuplin inj.; Takeda, Tokyo, Japan) subcutaneously after the operation. There was a significant difference in the distribution of preoperative AMH of patients with endometriotic and non-endometriotic cyst with

Table 1. Characteristics of patients who underwent SPL ovarian cystectomy (n = 180)

Characteristic	Frequency (%)
Age (y)	32.6 \pm 7.2
Body mass index (kg/m ²)	21.7 \pm 3.1
Histology	
Endometriotic cyst	112 (62.2)
Mature cystic teratoma	48 (26.7)
Mucinous cystadenoma	12 (6.7)
Serous cystadenoma	4 (2.2)
Others	4 (2.2)
Tumor size (cm)	5.3 (3.8–7.2)
Bilaterality of the tumor	
Unilateral	142 (78.9)
Bilateral	38 (21.1)
No. of cysts	1 (1–3)
Total operation time (min)	96 (69–127)

Data are presented as mean \pm standard deviation, number (%), or median (interquartile range [IQR]).

$P = 0.014$ (Fig. 1). Preoperative level of AMH was neither associated with endometrioma size nor laterality. The preoperative AMH level of endometriotic cyst is significantly less compared to non-endometriotic cyst (2.0 vs 3.8 ng/mL; $P < 0.001$). The postoperative serum AMH in endometriotic cyst was also significantly less compared to non-endometriotic cyst at 10 days (1.0 vs 3.2 ng/mL; $P < 0.001$) and 3 months after surgery (1.2 vs 3.6 ng/mL; $P < 0.001$). In terms of the change in serum AMH from baseline, there was a significant difference in the change in AMH at 10 days and but not at 3 months after surgery (Table 2).

A subgroup analysis of patients with basal AMH of > 0.1 ng/mL showed that the baseline serum AMH level of endometriotic cyst is significantly less compared to non-endometriotic cyst (1.9 vs 3.8 ng/mL; $P < 0.001$) (Table 3). The postoperative serum AMH in endometriotic cyst is also significantly less compared to non-endometriotic cyst at 10 days (1.0 vs 3.0 ng/mL; $P < 0.001$) and 3 months after surgery (1.1 vs 3.6 ng/mL; $P < 0.001$). For both endometriotic and non-endometriotic cysts, there are significant decrease of serum AMH values from baseline to 10 days and 3 months. The change in AMH is significantly higher in endometriotic than non-endometriotic cyst at 10 days after surgery but not at 3 months. The baseline serum AMH level of unilateral endometriotic cyst is significantly less compared to unilateral non-endometriotic cyst (2.27 vs 3.75 ng/mL; $P = 0.009$). The postoperative serum AMH in endometriotic cyst is also significantly less compared to non-endometriotic cyst at 10 days (1.52 vs 3.33 ng/mL; $P < 0.001$) and 3 months after surgery (1.72 vs 3.60 ng/

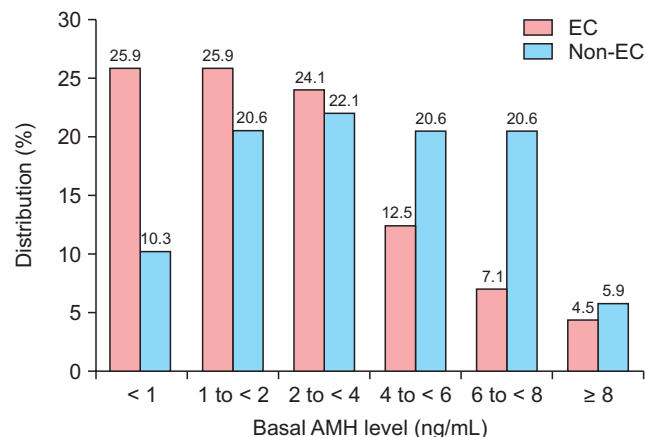


Fig. 1. Distribution (%) of the basal anti-Mullerian hormone (AMH) of patients with endometriotic cyst (EC) versus non-endometriotic cyst (Non-EC) are shown.

Table 2. Patient characteristics and serum AMH changes according to the pathologic type

Characteristic	Endometriotic cyst (n = 112)	Non-endometriotic cyst (n = 68)	P value
Age (y)	34.2 ± 6.8	29.9 ± 7.2	< 0.001
Tumor size (cm)	5 (3.5–6.3)	6.4 (4.5–9.5)	0.001
Operation type			< 0.001
Unilateral cystectomy	78 (69.6)	64 (94.1)	
Bilateral cystectomy	34 (30.4)	4 (5.9)	
Total operation time (min)	99 (75–130)	90 (64–120)	0.069
AMH level (ng/mL)			
Initial (preoperative)	2.0 (1.0–3.8)	3.8 (1.7–6.2)	< 0.001
POD10	1.0 (0.5–2.0)	3.2 (1.5–4.9)	< 0.001
POM3	1.2 (0.4–2.3)	3.6 (1.7–5.1)	< 0.001
Δ 10D	0.8 (0.3–1.7)	0.5 (0–1.4)	0.011
Δ 3M	0.7 (0.2–1.8)	0.5 (–0.2–1.1)	0.164

Data are presented as mean ± standard deviation, number (%), or median (interquartile range [IQR]).

AMH: anti-Mullerian hormone, POD10: postoperative day 10, POM3: postoperative month 3, Δ 10D: AMH decrease at POD10, Δ 3M: AMH decrease at POM3.

Table 3. AMH comparison in endometriotic cyst and non-endometriotic cyst

AMH level (ng/mL)	Endometriotic cyst (n = 106)	Non-endometriotic cyst (n = 66)	P value
Initial (preoperative)	1.9 (1.0–3.5)	3.8 (1.7–6.4)	< 0.001
POD10	1.0 (0.4–2.0)	3.0 (1.5–4.9)	< 0.001
P value	< 0.001	< 0.001	
POM3	1.1 (0.3–2.3)	3.6 (1.5–5.3)	< 0.001
P value	< 0.001	0.006	
Δ 10D	0.8 (0.3–1.7)	0.5 (0–1.4)	0.029
Δ 3M	0.7 (0.2–1.8)	0.4 (–0.2–1.1)	0.108

Data are presented as median (interquartile range [IQR]).

AMH: anti-Mullerian hormone, POD10: postoperative day 10, POM3: postoperative month 3, Δ 10D: AMH decrease at POD10, Δ 3M: AMH decrease at POM3.

Note: Patients with basal AMH > 0.1 ng/mL were included.

mL; $P < 0.001$). In terms of the change in serum AMH from baseline, the magnitude of change is significantly higher in endometriotic cyst than non-endometriotic cyst at 10 days but not at 3 months after surgery.

In the analysis according to basal AMH and histologic type of cyst, it showed that at 10 days after surgery, there was a significant difference in the magnitude of AMH change between endometriotic cyst and non-endometriotic cyst in all groups, with more change seen in the endometriotic cyst (Table 4). The rate of decline at 10 days and 3 months post-surgery is significantly different between endometriotic and non-endometriotic cyst (Fig. 2). At 3 months, a greater change in the endometriotic cyst group was observed, but was only statistically significant in Group 1 and Group 4.

Patients with bilateral or unilateral cysts showed no statistically significant difference between the baseline serum AMH. The postoperative serum AMH was significantly less among those who underwent bilateral cystectomy both at 10 days (0.95 vs 2.41 ng/mL; $P < 0.001$) and 3 months after surgery (1.12 vs 2.26 ng/mL; $P < 0.001$). Consequently, there is a significantly greater difference in serum AMH from the baseline to 10 days (1.54 vs 0.73 ng/mL; $P < 0.001$) and 3 months (1.94 vs 0.57 ng/mL; $P < 0.001$) in patients who underwent bilateral cystectomy compared to those who underwent unilateral cystectomy.

The effect of vasopressin on the post-operative AMH level in patients who underwent endometriotic cyst enucleation showed that the postoperative value of the

Table 4. AMH change comparison between EC and non-EC according to the basal AMH level

	Preoperative AMH									
	1 to < 2 ng/mL		2 to < 4 ng/mL		4 to < 6 ng/mL		6 to < 8 ng/mL			
	EC (n = 29)	Non-EC (n = 14)	EC (n = 27)	Non-EC (n = 15)	EC (n = 14)	Non-EC (n = 14)	EC (n = 8)	Non-EC (n = 14)		
Age (y)	35.6 ± 5.6	32.9 ± 7.9	32.7 ± 5.4	28.7 ± 6.0	0.035	29.5 ± 4.9	27.9 ± 5.1	26.6 ± 4.3	27.9 ± 5.3	0.582
AMH level (ng/mL)										
Preoperative	1.5 (1.4–1.9)	1.5 (1.4–1.7)	2.7 (2.7–3.5)	3.3 (2.8–3.7)	0.010	4.9 (4.5–5.4)	4.9 (4.4–5.3)	7 (6.5–7.8)	6.8 (6.5–7.3)	0.585
POD10	0.8 (0.5–1.3)	1.2 (0.9–1.7)	1.6 (1.0–2.0)	3.1 (2.4–3.5)	< 0.001	2.4 (1.9–3.4)	3.7 (3.0–4.8)	4.4 (3.1–5.5)	5.8 (4.8–7.3)	0.065
POM3	0.8 (0.6–1.2)	1.5 (1.2–2.0)	1.8 (1.2–2.3)	2.9 (2.3–3.9)	0.005	2.7 (2.2–3.3)	4.1 (3.1–4.7)	4.1 (3.2–6.2)	5.8 (4.8–7.6)	0.096
Δ10D	0.7 (0.4–1.1)	0.1 (–0.1–0.5)	1.2 (0.6–1.9)	0.3 (–0.1–0.6)	0.005	2.2 (1.7–2.9)	1.1 (0.5–1.9)	2.6 (1.7–4.3)	1.1 (0.1–2.6)	0.030
Δ3M	0.7 (0.2–1.0)	–0.07 (–0.6–0.2)	1 (0.5–1.5)	0.4 (–0.3–1.1)	0.131	1.8 (1.1–3.1)	0.8 (0.3–2.0)	3.12 (1.8–4.7)	0.7 (–0.3–1.1)	0.045
Rate of decline 10D (%)	45.3 (33.2–66.1)	6.3 (–9.7–36.5)	47.9 (25.8–66.8)	9.2 (–1.7–20.1)	0.001	48.1 (31.7–62.6)	22.5 (10.0–37.8)	36.6 (23.8–57.4)	16.1 (1.7–35.3)	0.041
Rate of decline 3M (%)	40.4 (22–62.7)	6.2 (–22.6–12.7)	32.2 (15.9–52.1)	7.3 (–19.4–29.6)	0.033	43.4 (24.1–59.2)	16.6 (5.5–47.7)	49.5 (16–55.4)	10.2 (–13.1–29.1)	0.070

Data are presented as mean ± standard deviation or median (interquartile range [IQR]).

AMH: anti-Müllerian hormone, EC: endometriotic cyst, POD10: postoperative day 10, POM3: postoperative month 3, Δ10D: AMH decrease at POD10, Δ3M: AMH decrease at POM3.

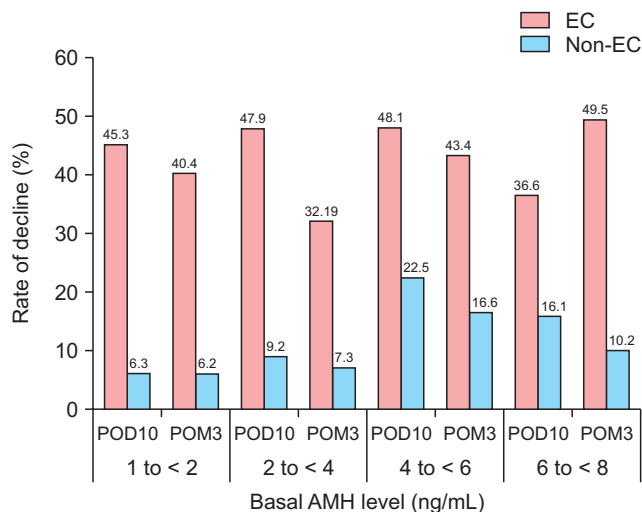


Fig. 2. Rate of decline according to baseline serum AMH in endometriotic cyst (EC) and non-endometriotic cyst (Non-EC). POD10: postoperative day 10, POM3: postoperative month 3.

serum AMH of patients with endometriotic cyst who were given vasopressin during the surgery was higher at 10 days (1.0 vs 0.8 ng/mL; $P = 0.253$) and 3 months (1.4 vs 1.1 ng/mL; $P = 0.242$) than those who were not. However, the difference was not statistically significant. The difference in serum AMH was comparable between the two groups (Table 5).

DISCUSSION

This study demonstrated that SPL ovarian cyst enucleation causes decrease in ovarian function at 10 days and 3 months after surgery as shown by the decrease in serum AMH levels in both endometriotic and other benign ovarian cysts. Moreover, the decrease in serum AMH was significantly greater in the endometriotic cyst group compared to the non-endometriotic cyst group. This finding is consistent with previous published studies which used conventional multiport laparoscopy [7–10]. Meta-analyses of eight eligible studies comprising 237 patients with endometrioma showed that AMH levels are significantly reduced (38%) after cystectomy [11]. Another meta-analysis also confirmed the presence of surgery-related damage to the ovarian reserve after surgical excision of endometriomas [12].

A study comparing single-port (SP), two-port (TP), and conventional multiport laparoscopy (MP) reported a significant decrease in serum AMH after receiving laparoscopic cystectomy, but there was no difference in the post-operative values in all sampling points. No

Table 5. The effect of vasopressin usage on postoperative AMH in endometriotic cyst enucleation (n = 112)

Vasopressin injection	AMH level (ng/mL)				
	Preoperative	POD10	POM3	Δ 10D	Δ 3M
Yes (n = 63)	2.0 (1.0–3.9)	1.0 (0.6–2.1)	1.4 (0.7–2.5)	0.8 (0.3–1.7)	0.6 (0.1–1.7)
No (n = 49)	1.9 (0.9–3.6)	0.8 (0.3–1.9)	1.1 (0.3–2.2)	0.8 (0.4–1.8)	0.7 (0.3–1.8)
<i>P</i> value	0.974	0.253	0.242	0.620	0.374

Data are presented as median (interquartile range [IQR]).

AMH: anti-Mullerian hormone, POD10: postoperative day 10, POM3: postoperative month 3, Δ 10D: AMH decrease at POD10, Δ 3M: AMH decrease at POM3.

significant difference in the serial changes between the SP, TP, and MP groups was found [3].

Ovarian cyst enucleation with stripping technique inadvertently removes normal ovarian tissue. A study showed that healthy ovarian tissue was found adjacent to the benign cyst of the cystectomy samples in up to 92%. Although their functional follicle loss was only slightly higher in the endometriotic cysts, the difference was statistically significant [13]. Another study reported that real cyst capsule was present in non-endometriotic cysts, leading to less normal ovarian tissue removal compared to endometriotic cysts, which have a pseudocapsule instead [14]. The decrease in ovarian function was also due to surgery-related ovarian damage such as electrosurgical coagulation affecting the vascular supply and post-surgery inflammation [15,16]. Fibrosis due to cortex-specific trauma in the ovaries with endometrioma > 4 cm also resulted in significantly lower follicular density compared with normal ovaries [15]. Our study also demonstrated a similar decrease in AMH levels between unilateral endometriotic and non-endometriotic cysts.

Analysis of change in serum AMH showed that there was a significant difference in serum AMH, especially in the short term, as seen in the results at 10 days after surgery. However, at 3 months, the magnitude of change was not significant. This may result from the fact that 92 patients with endometrioma (82.1%) were treated with hormone after the operation. Performance of laparoscopic cystectomy for non-endometriotic ovarian cyst can also cause a significant reduction in serum AMH levels [8-10]. Whether changes in the ovarian reserve after cystectomy in ovarian endometriotic cysts are different from changes in non-endometriotic cysts remains controversial.

When grouped according to laterality, the baseline AMH of unilateral and bilateral cysts were not significantly different. Single-port cyst enucleation decreased serum AMH in both unilateral and bilateral cysts, with

bilateral cyst enucleation having a greater impact. This is consistent with the findings of Chang et al. [9] and Iwase et al. [8] that laparoscopic cystectomy for bilateral endometriomas cause a greater decline of serum AMH levels than unilateral cystectomy.

Although the use of vasopressin in the enucleation of endometriotic cysts facilitates the identification of the plane of dissection, our study showed that its use has no significant effect on the serum AMH level. It suggests that even with hydrodissection, some healthy ovarian tissue adjacent to the cyst wall is still inadvertently removed. In one randomized controlled trial, injection of vasopressin during cystectomy of endometriotic cysts required significantly fewer pinpoint coagulation events compared to control group (power = 0.2, $P = 0.041$). The same was true when it was compared to the saline group (power = 0.9, $P = 0.041$). Since it is known that coagulation for hemostasis can reduce ovarian reserve, the authors stated that the use of vasopressin may provide some protection in ovarian reserve during surgery. However, they did not assess ovarian reserve markers to prove their statement [6].

This study, to the best of our knowledge, is the largest study which evaluated the effect of SPL surgery on ovarian function in both endometriotic and other benign cysts. However, as it is a retrospective cohort study, data on possible confounding factors may have not been recorded. A large portion of endometriotic cyst patient postoperatively took hormonal medications which affects the AMH levels. Moreover, not all types of benign cyst were studied. Since AMH half-life is approximately 27.6 hours, we postulated that 10 days were adequate to reflect the damage on ovarian reserve [17]. Also, there was a practical side to this: postoperative outpatient follow-up was after 10 days. Considering the life span of follicles, a longer follow-up period of up to at least 6 months would be more informative. However, postoperative 3 months serum AMH level follow-up could reflect the degree of ovarian reserve restoration

since folliculogenesis generally begins before postoperative 3 months [9]. A multicenter prospective cohort study with longer follow-up is needed.

The basal serum AMH levels in patients with endometriotic cyst were significantly lower than those with non-endometriotic cysts. The ovarian reserve was more likely to be affected by SPL cystectomy in endometriotic cyst compared to non-endometriotic cysts. The use of vasopressin during surgery had no significant effect on ovarian reserve. SPL is a feasible and safe option for endometriotic and other benign ovarian cyst. However, the effect of surgery on ovarian reserve must be properly counselled and fully considered.

ACKNOWLEDGMENTS

This work was supported by Yonsei Cancer Center of Severance Hospital. This study used Yonsei Severance Hospital data, made by Yonsei University College of Medicine. The authors alone are responsible for the content and writing of the paper.

CONFLICT OF INTEREST

No potential conflict of interest relevant to this article was reported.

REFERENCES

- MacGregor C, Cronin B. Evaluation and management of adnexal masses. *Topics Obstet Gynecol* 2016; 36: 7-8.
- Lobo RA, Gershenson DM, Lentz GM, Valea FA. *Comprehensive gynecology*. Philadelphia: Elsevier; 2016. 968 p.
- Yoon BS, Kim YS, Seong SJ, Song T, Kim ML, Kim MK, et al. Impact on ovarian reserve after laparoscopic ovarian cystectomy with reduced port number: a randomized controlled trial. *Eur J Obstet Gynecol Reprod Biol* 2014; 176: 34-8.
- te Velde ER, Pearson PL. The variability of female reproductive ageing. *Hum Reprod Update* 2002; 8: 141-54.
- Yim GW, Jung YW, Paek J, Lee SH, Kwon HY, Nam EJ, et al. Transumbilical single-port access versus conventional total laparoscopic hysterectomy: surgical outcomes. *Am J Obstet Gynecol* 2010; 203: 26.e1-6.
- Saeki A, Matsumoto T, Ikuma K, Tanase Y, Inaba F, Oku H, et al. The vasopressin injection technique for laparoscopic excision of ovarian endometrioma: a technique to reduce the use of coagulation. *J Minim Invasive Gynecol* 2010; 17: 176-9.
- Jang WK, Lim SY, Park JC, Lee KR, Lee A, Rhee JH. Surgical impact on serum anti-Müllerian hormone in women with benign ovarian cyst: a prospective study. *Obstet Gynecol Sci* 2014; 57: 121-7.
- Iwase A, Hirokawa W, Goto M, Takikawa S, Nagatomo Y, Nakahara T, et al. Serum anti-Müllerian hormone level is a useful marker for evaluating the impact of laparoscopic cystectomy on ovarian reserve. *Fertil Steril* 2010; 94: 2846-9.
- Chang HJ, Han SH, Lee JR, Jee BC, Lee BI, Suh CS, et al. Impact of laparoscopic cystectomy on ovarian reserve: serial changes of serum anti-Müllerian hormone levels. *Fertil Steril* 2010; 94: 343-9.
- Kwon SK, Kim SH, Yun SC, Kim DY, Chae HD, Kim CH, et al. Decline of serum antimüllerian hormone levels after laparoscopic ovarian cystectomy in endometrioma and other benign cysts: a prospective cohort study. *Fertil Steril* 2014; 101: 435-41.
- Raffi F, Metwally M, Amer S. The impact of excision of ovarian endometrioma on ovarian reserve: a systematic review and meta-analysis. *J Clin Endocrinol Metab* 2012; 97: 3146-54.
- Somigliana E, Berlanda N, Benaglia L, Viganò P, Vercellini P, Fedele L. Surgical excision of endometriomas and ovarian reserve: a systematic review on serum antimüllerian hormone level modifications. *Fertil Steril* 2012; 98: 1531-8.
- Dogan E, Ulukus EC, Okyay E, Ertugrul C, Saygili U, Koyuncuoglu M. Retrospective analysis of follicle loss after laparoscopic excision of endometrioma compared with benign nonendometriotic ovarian cysts. *Int J Gynaecol Obstet* 2011; 114: 124-7.
- Muzii L, Bianchi A, Crocè C, Mancini N, Panici PB. Laparoscopic excision of ovarian cysts: is the stripping technique a tissue-sparing procedure? *Fertil Steril* 2002; 77: 609-14.
- Kitajima M, Defrère S, Dolmans MM, Colette S, Squifflet J, Van Langendonck A, et al. Endometriomas as a possible cause of reduced ovarian reserve in women with endometriosis. *Fertil Steril* 2011; 96: 685-91.
- Li CZ, Liu B, Wen ZQ, Sun Q. The impact of electrocoagulation on ovarian reserve after laparoscopic excision of ovarian cysts: a prospective clinical study of 191 patients. *Fertil Steril* 2009; 92: 1428-35.
- Griesinger G, Dafopoulos K, Buendgen N, Cascorbi I, Georgoulas P, Zavos A, et al. Elimination half-life of anti-Müllerian hormone. *J Clin Endocrinol Metab* 2012; 97: 2160-3.