



The Effect of Adalimumab in Korean Patients with Refractory Noninfectious Uveitis

Sung Eun Park^{1,2}, Jae Won Jun¹, Dong Hyun Lee^{1,2}, Sung Chul Lee³, and Min Kim¹

¹Department of Ophthalmology, Institute of Vision Research, Gangnam Severance Hospital, Yonsei University College of Medicine, Seoul;

²Department of Medicine, Yonsei University Graduate School, Seoul;

³Department of Ophthalmology, Konyang University College of Medicine, Myunggok Medical Research Center, Daejeon, Korea.

We sought to analyze the efficacy of adalimumab in active noninfectious uveitis, and evaluate its efficacy and safety for the management of refractory noninfectious uveitis in Korean patients. A retrospective observational study was conducted. A total of 23 eyes of 14 Korean patients with noninfectious uveitis refractory to conventional treatment, including corticosteroid and immunosuppressive agents, were treated with adalimumab between December 2017 and February 2020. The primary outcomes were vitreous haziness grades, anterior chamber cell grades, and central macular thickness measured prior to injection and at 1, 3, 6, and 12 months after the first adalimumab injection. Among the 23 eyes, 14 eyes (60.9%) were diagnosed with panuveitis and 9 eyes (39.1%) with posterior uveitis [mean follow-up period: 22.3 months (7–27)]. The most common etiologic diagnoses requiring adalimumab injection were Behçet's disease (9 eyes, 39.1%), followed by undifferentiated inflammation (6 eyes, 26.1%), Vogt-Koyanagi-Harada disease (3 eyes, 13.0%), psoriasis (2 eyes, 8.7%), serpiginous chorioretinopathy (2 eyes, 8.7%), and systemic lupus erythematosus (1 eye, 4.3%). At the 1-year follow-up after the first injection, anterior chamber cell grade decreased from 0.5 ± 0.4 to 0.3 ± 0.4 , and vitreous haziness grade decreased from 1.1 ± 1.1 to 0.3 ± 0.5 ($p < 0.05$). Central macular thickness improved from $347.2 \pm 98.1 \mu\text{m}$ to $264.3 \pm 61.1 \mu\text{m}$ ($p < 0.05$). Adalimumab injection in patients with refractory noninfectious uveitis decreased the anterior chamber cell grade, vitreous haziness grade, and central macular thickness with no severe side effect. Overall, adalimumab injection may, therefore, be an effective and relatively safe treatment modality for noninfectious uveitis in Korean patients.

Key Words: Uveitis, adalimumab, inflammation, macular edema

Uveitis is a relatively common intraocular inflammatory condition that accounts for approximately 10% of blindness in developed countries, and often causes visual disability in the working-age population.^{1,2} It can be classified as either infectious or noninfectious uveitis, depending on the cause of the inflammation. Noninfectious uveitis is generally more common in developed countries, and can occur as a syndrome iso-

lated to the eye or in association with a systemic condition.^{3,4}

Corticosteroids remain the mainstay therapy for noninfectious uveitis, but their long-term use is limited by well-known ocular and systemic side effects.³ Therefore, multimodal treatments other than corticosteroids are needed for treating chronic ocular inflammation. More effective and safer corticosteroid-sparing immunomodulatory therapies or biological agents are required.³ Noninfectious uveitis is thought to be regulated by a T-cell-mediated immune response. The proinflammatory cytokine tumor necrosis factor α (TNF- α) plays a key role in many autoimmune diseases, including uveitis.^{1,3} Upregulation of TNF- α in aqueous humor and serum is detected in patients with noninfectious uveitis,³ and is considered the target of treatment. Adalimumab is a fully human monoclonal IgG1 TNF- α antibody that was first approved in 2002 by the US Food and Drug Administration (FDA) for the treatment of rheumatoid arthritis.¹

Based on the two randomized placebo-controlled trials VI-

Received: September 23, 2020 **Revised:** November 27, 2020

Accepted: December 7, 2020

Corresponding author: Min Kim, MD, PhD, Department of Ophthalmology, Institute of Vision Research, Gangnam Severance Hospital, Yonsei University College of Medicine, 211 Eonju-ro, Gangnam-gu, Seoul 06273, Korea.
Tel: 82-2-2019-3440, Fax: 82-2-3463-1049, E-mail: minkim76@gmail.com

•The authors have no potential conflicts of interest to disclose.

© Copyright: Yonsei University College of Medicine 2021

This is an Open Access article distributed under the terms of the Creative Commons Attribution Non-Commercial License (<https://creativecommons.org/licenses/by-nc/4.0>) which permits unrestricted non-commercial use, distribution, and reproduction in any medium, provided the original work is properly cited.

SUAL-1 and VISUAL-2, adalimumab has now been approved for the treatment of adults with noninfectious intermediate, posterior, and panuveitis by the European Medicines Agency and the FDA.⁵ Furthermore, many uveitis experts suggest that adalimumab is also a useful treatment modality in cases of children and patients with anterior uveitis.¹ Uncontrolled case series, retrospective chart reviews, and small open-label studies in Western countries have suggested that adalimumab is effective in treating patients with chronic or refractory uveitis, and ultimately helps to reduce corticosteroid use.⁶⁻¹¹ However, there has been no published study on the clinical outcome of noninfectious uveitis patients treated with anti-TNF- α in Korea. The purpose of this study was to retrospectively analyze the efficacy and safety of adalimumab, an anti-TNF- α drug, in Korean patients with active, refractory noninfectious uveitis.

A retrospective observational study was conducted. A total of 23 eyes from 14 Korean patients with refractory noninfectious uveitis treated with adalimumab (Humira[®]; AbbVie, Chicago, IL, USA) between December 2017 and February 2020 at Yonsei University Medical Center were enrolled. Relapse of uveitis or refractory uveitis was defined when patients were receiving the highest anti-inflammatory or immunosuppressant regimen in their lives and these were insufficient to keep the disease under control; or when patients had a history of at least one relapse of uveitis in the year before enrollment that required an increase in the dose of oral corticosteroids or other immunosuppressive agents, including methotrexate, azathioprine, mycophenolate mofetil, and cyclosporine, to control the episode.⁵

We included patients with the diagnosis of chronic, noninfectious, refractory uveitis who were treated with an ineffective therapy, including increased dosage of corticosteroids or at least one additional immunosuppressant drug besides corticosteroids that was unable to prevent relapses, ultimately requiring an elevation of the oral corticosteroid or other immunosuppressant dosage to control the inflammation. Patients who had no evidence of malignancy or systemic infection were enrolled. The exclusion criteria comprised any patient enrolled in other investigative clinical trial and recently had serious, recurrent, or chronic infection. Patients who underwent intraocular surgery in the recent 3 months prior to the first adalimumab injection were excluded. Other exclusion criteria were patients who had liver, renal, cardiac, or demyelinating diseases, or transplanted organ.

The study adhered to the tenets of the Declaration of Helsinki. Approval for this study was obtained from the Gangnam Severance Hospital Institutional Review Board, which provided a waiver of informed consent owing to the retrospective review of existing patient records (IRB number: 3-2020-0200). Medical records were systematically evaluated, and data including medical history, age, sex, clinical diagnosis, complete ocular examination findings at baseline and follow-up visits, prior local and systemic therapies, response to therapy, and side effects were reviewed.

The main outcome measures included composite endpoint of treatment failure encompassing active inflammatory chorioretinal or retinal vascular lesions, intraocular inflammation grade, and visual acuity. Intraocular inflammation was analyzed with different effect factors: anterior chamber cell grade for anterior uveitis patients, vitreous haziness grade for intermediate uveitis patients, central macular thickness for posterior uveitis patients, and all three factors for panuveitis patients. Through slit lamp examination, anterior chamber cells were graded according to the Sun Working Group Grading System, which established anatomic classification of uveitis and grading of inflammation from 0 to 4+. Vitreous haziness was measured through slit lamp and fundus examinations, and graded according to the standardized photographic scale. Central macular thickness was examined with optical coherence tomography.

Active inflammatory status of each eye at baseline was defined based on the clinical findings: at least one active inflammatory chorioretinal or retinal vascular lesion, anterior chamber cell grade of 1+ or higher, according to the SUN Working Group.

Data were analyzed with the SPSS ver. 22.0 software (IBM Corp., Armonk, NY, USA), and values are expressed as mean \pm standard deviation. Differences in macular thickness between baseline and after 1 year of follow-up were examined by paired t-test, and those in anterior chamber cell and vitreous haziness grades within groups were examined by Wilcoxon signed-rank test. $p < 0.05$ was considered statistically significant.

We studied 23 eyes from 14 patients with an average age of 40.0 years (range: 18–62 years). The mean follow-up period was 22.3 months (range: 7–27 months). Baseline characteristics are summarized in Table 1. The average number of injections for the total enrolled patients was 24.9 per patient (Table 1).

All four patients who showed positive IGRA result used anti-tuberculosis drugs at least 3 weeks before starting adalimumab treatment. All patients were diagnosed with either posterior uveitis or panuveitis; posterior uveitis was found in 9 eyes (39.1%) and panuveitis in 14 eyes (60.9%). More than half of the patients had macular edema at baseline (14 eyes, 60.9%). The most common etiologic diagnoses requiring adalimumab injection were Behçet's disease (9 eyes, 39.1%), followed by undifferentiated inflammation (6 eyes, 26.1%), VKH disease (3 eyes, 13.0%), uveitis associated with psoriasis (2 eyes, 8.7%), serpiginous chorioretinopathy (2 eyes, 8.7%), and systemic lupus erythematosus (1 eye, 4.3%).

All patients were considered "active" if they had at least one eye with active inflammation at baseline that required an increase in the dose of oral corticosteroids or other immunosuppressive drugs to control the inflammatory status. None of the patients showed satisfactory inflammatory control with multiple drugs, including corticosteroids and immunosuppressive agents (Table 2).

At the 1-year follow-up after the first injection, visual acuity remained stable with no significant decrease during 12 months

Table 1. Baseline Clinical Characteristics

Clinical parameters	Values (14 patients, 23 eyes)
Age (yr)	
Mean (range)	40 (18–62)
Sex (person)	
Male	9 (64.3)
Female	5 (35.7)
Bilaterality (person)	9 (64.3)
Cataract op. history (eyes)	13 (56.5)
Diabetes mellitus (person)	1 (7.1)
Hypertension (person)	1 (7.1)
IGRA positive (person)	4 (28.6)
Autoimmune antibody positive (eyes)	
ANA	0
HLA-B27	0
HLA-B51	4 (17.4)
Mean baseline visual acuity (LogMAR)	0.4±0.4
Mean baseline IOP (mm Hg)	14.6±4.5
Mean central macular thickness (µm)	347.2±98.1
Etiological diagnosis in study eye (eyes)	
Behçet's disease	9 (39.1)
Undifferentiated (idiopathic)	6 (26.1)
Vogt-Koyanagi-Harada syndrome	3 (13.0)
Psoriasis	2 (8.7)
Serpiginous chorioretinopathy	2 (8.7)
Systemic lupus erythematosus	1 (4.3)
Anatomical diagnosis in study eye (eyes)	
Posterior uveitis	9 (39.1)
Panuveitis	14 (60.9)
Average number of adalimumab injections per patient	24.9
Mean follow-up period (range)	22.3 (7–27)
Adalimumab interruption Hx. (patients)	3 (21.4)

IGRA, interferon gamma release assay; ANA, antinuclear antibodies; HLA, human leukocyte antigen; LogMAR, logarithm of the minimum angle of resolution; IOP, intraocular pressure.

Data are presented as mean±standard deviation or n (%).

of adalimumab injection ($p=0.859$) (Fig. 1, Table 3). Anterior chamber cell and vitreous haziness grades were significantly improved at the 1-year follow-up ($p<0.05$) (Fig. 1, Table 3). At baseline, macular edema was found in 14 eyes (60.9%). At 1 year after the initiation of the treatment with adalimumab, five out of 14 eyes showed complete resolution of macular edema, whereas the remaining nine eyes had residual macular edema. Central macular thickness significantly reduced from 347.2±98.1 µm to 264.3±61.1 µm ($p<0.05$) (Fig. 1, Table 3).

Overall, only one patient showed a mild side effect of skin rash on his thigh and body trunk. Nonetheless, adalimumab was restarted for the patient, and no additional side effects were observed. Two patients achieved stable disease status after adalimumab injection and did not need further adalimumab

Table 2. Baseline Treatment Regimens of 14 Patients with Noninfectious Refractory Uveitis

Treatments at baseline	No. (%) of patients
Corticosteroids only*	3 (21.4)
Corticosteroids and methotrexate	1 (7.1)
Corticosteroids and cyclosporine	1 (7.1)
Corticosteroids and mycophenolate mofetil	3 (21.4)
Corticosteroids and ≥2 immunosuppressants†	6 (42.9)

*List of corticosteroids: oral corticosteroids, subtenon corticosteroids injection, and intravitreal corticosteroid or glucocorticoid injection (Ozurdex®, Allergan).

†List of immunosuppressants used: methotrexate, cyclosporine, and mycophenolate mofetil.

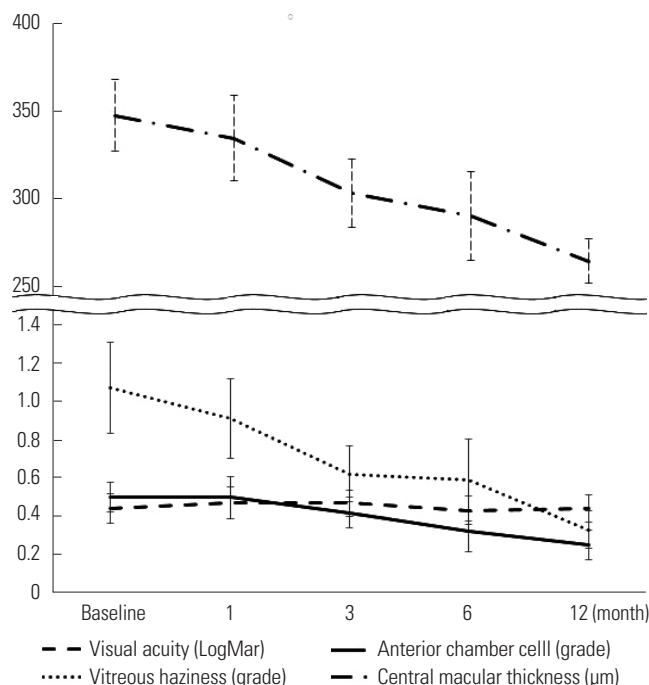


Fig. 1. Changes in the mean visual acuity (LogMAR), anterior chamber cell (grade), vitreous haziness (grade), and central macular thickness (µm) after adalimumab injection measured prior to injection and at 1, 3, 6, and 12 months post-injection. LogMAR, logarithm of the minimum angle of resolution.

treatment.

This retrospective study showed the effectiveness and safety of adalimumab injection as a corticosteroid-sparing agent for the control of noninfectious uveitis in a real-world setting. As a result, 23 eyes with active inflammation at baseline were treated with adalimumab injection and followed up for an average of 22.3 months. Visual acuity was maintained without any significant worsening after adalimumab therapy, and clinically relevant outcomes associated with uveitic inflammation, such as anterior chamber cell and vitreous haziness grades and central macular thickness, were improved after adalimumab treatment. Especially, posterior manifestations of uveitis, including vitreous haziness and central macular edema, were improved to a greater degree compared to those of the anterior

Table 3. Comparison of Outcome Variables before Treatment with Adalimumab and at Final Visit

Clinical parameters	Months		p value
	Baseline (pre-treatment visit)	12 months (final visit)	
Visual acuity (LogMAR)	0.4±0.4	0.4±0.4	0.859*
Anterior chamber cell (grade)	0.5±0.4	0.3±0.4	<0.05†
Vitreous haziness (grade)	1.1±1.1	0.3±0.5	<0.05†
Central macular thickness (µm)	347.2±98.1	264.3±61.1	<0.05*

LogMAR, logarithm of the minimum angle of resolution.

Data are presented as mean±standard deviation.

*Paired-sample t-test, †Wilcoxon signed-rank test.

segment. Therefore, we can expect adalimumab treatment to be significantly effective in patients with posterior uveitis and panuveitis.

Adalimumab was approved by the European Medicines Agency and the FDA following the two randomized placebo-controlled trials, VISUAL-1³ and VISUAL-2,¹² which reported the efficacy of adalimumab in the treatment of adults with non-infectious intermediate, and posterior panuveitis. This multinational phase 3 trial involving 217 patients with active noninfectious intermediate uveitis, posterior uveitis, or panuveitis, despite being treated with prednisone for 2 or more weeks, the median time to treatment failure was 24 weeks in the adalimumab group and 13 weeks in the placebo group. In addition, intraocular inflammation of the anterior chamber and vitreous cavity as well as visual acuity were significantly better in the adalimumab group than in the placebo group.³ Moreover, treatment with adalimumab led to significant reductions in corticosteroid dose and immunosuppression load, demonstrating significantly lower risk of treatment failure in the adalimumab-treated group than in the placebo group. However, patients with isolated anterior uveitis or more than one concomitant immunosuppressive drug excluding corticosteroids within 4 weeks of the baseline visit were excluded. With this restriction, it can be presumed that a similar efficacy might not be achieved in a heterogeneous real-world patient population.

In our study, adalimumab was shown to be effective in patients with active, vision-threatening, noninfectious, intermediate, and posterior panuveitis. The effectiveness of adalimumab was indicated by a significant decrease in anterior chamber cell and vitreous haziness grades as well as a reduction in macular thickness. Therefore, the present results confirmed the findings of previous foreign studies indicating the efficacy of adalimumab in chronic, noninfectious, refractory uveitis.

There have been quite a number of studies abroad reporting the effectiveness of adalimumab in noninfectious refractory uveitis. Callejas-Rubio, et al.⁷ reported a pilot study of 10 patients with different forms of refractory uveitis, and showed improvement of intraocular inflammation of the anterior chamber and vitreous cavity in all patients; two patients used adalimumab as a first-line therapy with similar satisfactory results, whereas eight other patients maintained additive methotrexate.⁷ Furthermore, adalimumab showed lower immunogenic-

ity compared to infliximab; in fact, anti-drug antibody reaction due to adalimumab was rare.⁷ Therefore, an anti-TNF-α agent could be a promising therapeutic regimen for patients with noninfectious refractory uveitis. Petropoulos, et al.¹³ reported the case series of 15 patients with different forms of uveitis who showed no response or low tolerability to classic immunosuppressive therapies and maintained adalimumab therapy for a mean follow-up period of 18 months.¹⁴ In a recent study of childhood noninfectious chronic uveitis, adalimumab was shown to be effective in controlling pediatric noninfectious uveitis related with Behçet’s disease 5 and spondyloarthritis.¹⁵

The limitations of our study include its retrospective design, as well as the fact that it did not have a control group of other ethnicities. Moreover, the results of our retrospective study did not include inactive inflammation status at baseline and a placebo group; therefore, the results cannot be directly compared to those of randomized placebo-controlled trials, such as VISUAL-1 and VISUAL-2. To ensure the safety of adalimumab treatment, the effect of drug-drug interactions should be investigated in the future. The relatively small number of patients and short follow-up period also limited the results of our study. Therefore, further clinical studies with a large number of patients and longer follow-up term are required. However, despite these limitations, our study has the strength of being the first study to evaluate the efficacy of adalimumab in Korean patients with noninfectious uveitis of various etiologies in a real-world setting.

In conclusion, adalimumab injection in Korean patients with noninfectious uveitis who are refractory to conventional corticosteroid treatment and immunosuppressive agents led to significant anatomical improvement of anterior chamber inflammation, vitreous haziness, and central macular thickness with no serious side effect. Overall, adalimumab injection may, therefore, be an effective and relatively safe treatment modality for Korean patients with noninfectious uveitis.

ACKNOWLEDGEMENTS

This study was supported by the “Hankook Ilbo Seung Myung Ho” Faculty Research Assistance Program of Yonsei University College of Medicine (6-2020-0236), by the National Research Foundation of Korea (NRF) grant funded by the Korean govern-

ment (MSIT) (No.2019R1G1A1008122) and by the Korean Association of Retinal Degeneration.

AUTHOR CONTRIBUTIONS

Conceptualization: Min Kim and Sung Eun Park. **Data curation:** Min Kim and Sung Eun Park. **Formal analysis:** Min Kim and Sung Eun Park. **Funding acquisition:** Min Kim. **Investigation:** Sung Eun Park. **Methodology:** Min Kim and Sung Eun Park. **Project administration:** Min Kim, Sung Eun Park, and Dong Hyun Lee. **Resources:** Min Kim and Sung Eun Park. **Software:** Sung Eun Park. **Supervision:** Min Kim, Sung Chul Lee, and Dong Hyun Lee. **Validation:** Min Kim, Sung Eun Park, and Dong Hyun Lee. **Visualization:** Sung Eun Park and Jae Won Jun. **Writing—original draft:** Min Kim, Sung Eun Park, Dong Hyun Lee, and Jae Won Jun. **Writing—review & editing:** Min Kim, Sung Eun Park, and Dong Hyun Lee. **Approval of final manuscript:** all authors.

ORCID iDs

Sung Eun Park	https://orcid.org/0000-0001-6093-6888
Jae Won Jun	https://orcid.org/0000-0003-3214-7093
Dong Hyun Lee	https://orcid.org/0000-0002-6957-1042
Sung Chul Lee	https://orcid.org/0000-0001-9438-2385
Min Kim	https://orcid.org/0000-0003-1873-6959

REFERENCES

1. Chang JH, Wakefield D. Uveitis: a global perspective. *Ocul Immunol Inflamm* 2002;10:263-79.
2. Lee JT, Yates WB, Rogers S, Wakefield D, McCluskey P, Lim LL. Adalimumab for the treatment of refractory active and inactive non-infectious uveitis. *Br J Ophthalmol* 2018;102:1672-8.
3. Jaffe GJ, Dick AD, Brézin AP, Nguyen QD, Thorne JE, Kestelyn P, et al. Adalimumab in patients with active noninfectious uveitis. *N Engl J Med* 2016;375:932-43.
4. Tsirouki T, Dastiridou A, Symeonidis C, Tounakaki O, Brazitikou I, Kalogeropoulos C, et al. A focus on the epidemiology of uveitis. *Ocul Immunol Inflamm* 2018;26:2-16.
5. Díaz-Llopis M, Salom D, Garcia-de-Vicuna C, Cordero-Coma M, Ortega G, Ortego N, et al. Treatment of refractory uveitis with adalimumab: a prospective multicenter study of 131 patients. *Ophthalmology* 2012;119:1575-81.
6. Ming S, Xie K, He H, Li Y, Lei B. Efficacy and safety of adalimumab in the treatment of non-infectious uveitis: a meta-analysis and systematic review. *Drug Des Devel Ther* 2018;12:2005-16.
7. Callejas-Rubio JL, Sánchez-Cano D, Serrano JL, Ortego-Centeno N. Adalimumab therapy for refractory uveitis: a pilot study. *J Ocul Pharmacol Ther* 2008;24:613-4.
8. Diaz-Llopis M, García-Delpech S, Salom D, Udaondo P, Hernández-Garfella M, Bosch-Morell F, et al. Adalimumab therapy for refractory uveitis: a pilot study. *J Ocul Pharmacol Ther* 2008;24:351-61.
9. Dobner BC, Max R, Becker MD, Heinz C, Veltrup I, Heiligenhaus A, et al. A three-centre experience with adalimumab for the treatment of non-infectious uveitis. *Br J Ophthalmol* 2013;97:134-8.
10. Suhler EB, Lowder CY, Goldstein DA, Giles T, Lauer AK, Kurz PA, et al. Adalimumab therapy for refractory uveitis: results of a multicentre, open-label, prospective trial. *Br J Ophthalmol* 2013;97:481-6.
11. Cordero-Coma M, Yilmaz T, Onal S. Systematic review of anti-tumor necrosis factor-alpha therapy for treatment of immune-mediated uveitis. *Ocul Immunol Inflamm* 2013;21:19-27.
12. Nguyen QD, Merrill PT, Jaffe GJ, Dick AD, Kurup SK, Sheppard J, et al. Adalimumab for prevention of uveitic flare in patients with inactive non-infectious uveitis controlled by corticosteroids (VISUAL II): a multicentre, double-masked, randomised, placebo-controlled phase 3 trial. *Lancet* 2016;388:1183-92.
13. Petropoulos IK, Vaudaux JD, Guex-Crosier Y. Anti-TNF-alpha therapy in patients with chronic non-infectious uveitis: the experience of Jules Gonin Eye Hospital. *Klin Monbl Augenheilkd* 2008;225:457-61.
14. Guedry J, LeHoang P, Bodaghi B. Anti-tumor necrosis factor-alpha agents in noninfectious uveitis. *Dev Ophthalmol* 2012;51:63-78.
15. Guignard S, Gossec L, Salliot C, Ruysen-Witrand A, Luc M, Duclos M, et al. Efficacy of tumour necrosis factor blockers in reducing uveitis flares in patients with spondylarthropathy: a retrospective study. *Ann Rheum Dis* 2006;65:1631-4.