Asian Journal of Surgery 44 (2021) 1166–1171

Contents lists available at ScienceDirect

Asian Journal of Surgery

journal homepage: www.e-asianjournalsurgery.com

Original Article

Modified version of minimally invasive open thyroidectomy using an unilateral incision

Soo Young Kim [a], Hee Jun Kim [b], Hojin Chang [c], Seok-Mo Kim [c], Yong Sang Lee [c], Hang-Seok Chang [c], Cheong Soo Park [b, *]

[a] Department of Surgery, Ajou University of Medicine, Suwon, Republic of Korea
[b] Department of Surgery, CHA Ilsan Medical Center, Goyang-si, Republic of Korea
[c] Department of Surgery, Thyroid Cancer Center, Gangnam Severance Hospital, Institute of Refractory Thyroid Cancer, Yonsei University College of Medicine, Seoul, Republic of Korea

ARTICLE INFO

Article history:
Received 8 December 2020
Received in revised form
10 January 2021
Accepted 7 February 2021
Available online 1 April 2021

Keywords:
Minimally invasive open thyroidectomy
Minimally invasive thyroidectomy
Thyroid cancer
Thyroidectomy

ABSTRACT

Background/objective: Open thyroidectomy has been the standard approach for patients undergoing thyroidectomy. However, this approach leads to prominent scars, hypesthesia, paresthesia, and uncomfortable sensations. We aimed to describe our modified technique of minimally invasive open thyroidectomy (MIT) and to compare the results with those of conventional thyroidectomy.
Methods: This study included 880 patients who underwent surgery between January 2016 and December 2016. Modified MIT was performed in 249 patients (28.3%), and conventional thyroidectomy was performed in the remaining 631 patients.
Results: Lobectomy was performed in the majority of cases (MIT 204 [81.9%] vs. conventional 429 [67.9%]). There were no significant differences in complications between the two approaches (6 [2.4%] vs. 8 [1.3%]). Patients who underwent surgery using the minimally invasive approach had a shorter operative time (77.99 ± 34.5 vs. 91.23 ± 36.58 min) and were discharged earlier (2.4 ± 0.8 vs. 3.2 ± 0.8) than those who underwent conventional thyroidectomy.
Conclusion: Modified MIT is a safe alternative to standard open thyroidectomy and allows the performance of bilateral total thyroidectomy with proper central compartment neck dissection.
Level of evidence: 2b.
© 2021 Asian Surgical Association and Taiwan Robotic Surgery Association. Publishing services by Elsevier B.V. This is an open access article under the CC BY-NC-ND license (http://creativecommons.org/licenses/by-nc-nd/4.0/).

1. Introduction

Open thyroidectomy has been the standard approach for patients undergoing thyroidectomy. The conventional technique of thyroidectomy normally requires a long collar incision, usually 6–10 cm in length, wide skin flaps on the anterior neck, and a long midline opening of the strap muscles to provide exposure of the thyroid glands, regardless of the extent of thyroidectomy planned. This conventional approach may cause a wide neck scar and a variety of potential complications related to raising the skin flaps and vertically opening the strap muscles.[1] However, this approach leads to prominent scars, hypesthesia, paresthesia, and uncomfortable sensations. The desire for improving the cosmetic outcome with low complication rates has driven the introduction of several new techniques.

Since the development of minimally invasive open thyroidectomy (MIT) in the 1990s, different surgical approaches to the thyroid have been described. “Minimally” invasive thyroidectomy may include thyroidectomy carried out using conventional, endoscopic, or non-endoscopic techniques through a small neck incision or endoscopically, reaching the target organ from outside of the neck, such as breast, anterior chest, or axilla.[2,3] A video-assisted minimally invasive surgery has been previously reported, which was shown to reduce immunosuppression and minimize the risk of injury. Minimally invasive video-assisted thyroidectomy (MIVAT) as a hybrid procedure is performed partly under magnified vision (videoscopic assistance) and partly under direct vision (as in open surgery). Magnified visualization allows better identification and preservation of critical neck structures.[4,5] However, Brunaud et al

* Corresponding author. Department of Surgery, CHA Ilsan Medical Center, 1205, Jungang-ro, Ilsandong-gu, Goyang-si, Gyeonggi-do, Republic of Korea.
E-mail address: sohopeacock@naver.com (C.S. Park).

https://doi.org/10.1016/j.asjsur.2021.02.024
1015-9584/© 2021 Asian Surgical Association and Taiwan Robotic Surgery Association. Publishing services by Elsevier B.V. This is an open access article under the CC BY-NC-ND license (http://creativecommons.org/licenses/by-nc-nd/4.0/).

proposed that the term "minimally" should be used only to describe thyroid and parathyroid procedures that are routinely associated with an incision shorter than 3.0 cm for thyroidectomy and 2.5 cm for parathyroidectomy.[6]

MIT without using endoscopic techniques is called differently, such as minimal neck incision thyroidectomy (MNIT).[2,7] Other studies have reported about minimal access thyroid surgery (MATS) with a 2.5 cm lateral incision placed directly over the nodule with exposure gained by dissecting the plane between the sternomastoid muscle and the lateral edge of the strap muscle.[8] The main advantages of minimally invasive surgery are not only good cosmetic outcomes but also reduced postoperative pain, shorter hospital stay, and lower social costs. Particularly important is the aesthetic benefit, as most of the patients undergoing thyroid surgery are young women, and an unsightly scar on the anterior neck can be distressing for the patient.[9–13]

A study has reported on MIT with a small skin incision of 3.0–4.5 cm approaching the thyroid directly via a transverse division of the strap muscles without raising the skin flaps to minimize tissue trauma by obviating unnecessary neck exploration.[1] Recently, we developed a new surgical approach, which is a modified version to our previously reported approach without transverse dissection of the strap muscles. This technique decreased tissue trauma by obviating unnecessary neck exploration, postoperative pain, and discomfort while swallowing related to a large skin incision and raising of the skin flap.

This paper aimed to describe our technique of performing modified MIT and to compare the results with those achieved by conventional thyroidectomy.

2. Methods

This retrospective study included 880 patients with thyroid nodules who underwent surgery at our hospital between January 2016 and December 2016. Surgery was performed when malignant or benign lesions of increasing mass size caused pressure symptoms or cosmetic disfiguration and when there was difficulty in differentiating between malignant and benign lesions preoperatively, such as in follicular neoplasms. Modified MIT was performed in 249 patients (28.3%), and conventional thyroidectomy was performed in the remaining 631 patients. Patients who required radical neck dissection were not included in this study. All procedures were performed by Prof. Cheong Soo Park solely. Written informed consent was obtained from all the patients. This study was approved by the institutional ethics committee (IRB number 3-2016-0345).

2.1. Operative technique

The patient was placed in a supine position with neck extension after the induction of general anesthesia. A unilateral incision of 2.5–3.5 cm not crossing the midline was made along the skin crease in the lower neck. In case of unilateral disease, the incision was made at the same side laterally, whereas for bilateral disease, in which case bilateral total thyroidectomy was performed, the incision was made on the side of the main lesion. Electrocautery was used to divide the platysma. Dissection along the anterior edge of the sternocleidomastoid muscle was performed to identify the omohyoid muscle and to expose the lateral margin of the strap muscles. The omohyoid muscle was used as a superior landmark. The sternocleidomastoid muscle was then retracted laterally. The fascia covering the strap muscle was incised, and the thyroid was approached by dissecting between the sternohyoid and sternothyroid muscles. The strap muscles were not divided; instead, they were retracted to obtain adequate exposure of the diseased thyroid gland (Fig. 1). Next, the thyroid gland was retracted inferiorly and medially to expose the branches of the superior thyroid artery and vein, which were individually clamped, divided, and ligated as close as possible to the upper pole.

Then, the isthmus was completely freed from the trachea and divided to expose the medial margin.

The middle thyroid vein was divided and ligated. To elevate and medially rotate the lower pole, the lymphatic and capsular vessels on the anterior surface of the gland and its lower pole were dissected. The dissected lobe was removed out of the wound after full mobilization of the isthmus and upper and lower poles of the thyroid (Fig. 2).

The surgical procedures for the identification and preservation of the recurrent laryngeal nerve and parathyroid glands, as well as for the central compartment lymph node dissection, were identical to those used in the conventional thyroidectomy. For bilateral total thyroidectomy, the same procedure described above was performed using the same lateral incision (Fig. 3). The drain was not inserted routinely. The platysma and subcutaneous tissues were approximated, and the skin was closed using 5-0 vicryl subcuticular sutures.

In case of malignancy, we further analyzed the central compartment neck nodes by frozen section to determine the size and involvement of the central compartment neck node, consuming approximately 20–30 min of the total operative time. In case of thyroid nodes which were not confirmed as cancer preoperatively, the node was sent for frozen-section examination and intraoperative immunohistochemical staining to determine the pathological diagnosis, consuming approximately 30–60 min of the total operative time.

2.2. Statistical analysis

Statistical analyses of the data were performed using the standard t-test and the chi-squared test. SPSS 23.0 (SPSS, Inc, Chicago, Illinois) was used for the statistical analysis. A p-value of <0.05 was considered significant.

3. Results

Among the 880 surgeries performed, 631 were performed using the conventional approach and 249 were performed using the minimally invasive approach. There were no significant differences in sex, tumor size, and histology. The majority of the patients were diagnosed with papillary carcinoma (minimally invasive approach: 235 [94.4%] vs. conventional approach: 589 [93.2%]). The patients who underwent MIT were significantly younger than those who underwent conventional thyroidectomy (41.8 ± 10.8 vs. 45.7 ± 11.9 years) (Table 1).

Less than total thyroidectomy, including hemithyroidectomy and isthmectomy, was more frequently observed in MIT (204 [81.9%] vs. 429 [67.9%]) (Table 2).

There were no significant differences regarding complications between the two approaches (6 [2.4%] vs. 8 [1.3%]). In the MIT group, 3 hematoma cases and 3 transient hypocalcemia cases were detected, whereas in the conventional thyroidectomy group, 1 hematoma case and 7 transient hypocalcemia cases were observed. No other complications occurred in our case series (Table 3).

The operative time was significantly shorter in the minimally invasive approach (77.99 ± 34.5 vs. 91.23 ± 36.58 min). However, given that there were more less than total thyroidectomies performed using the minimally invasive approach, we further analyzed the operative time required for less than total thyroidectomy and bilateral total thyroidectomy separately. Less than total thyroidectomy showed significantly shorter operative time when performed

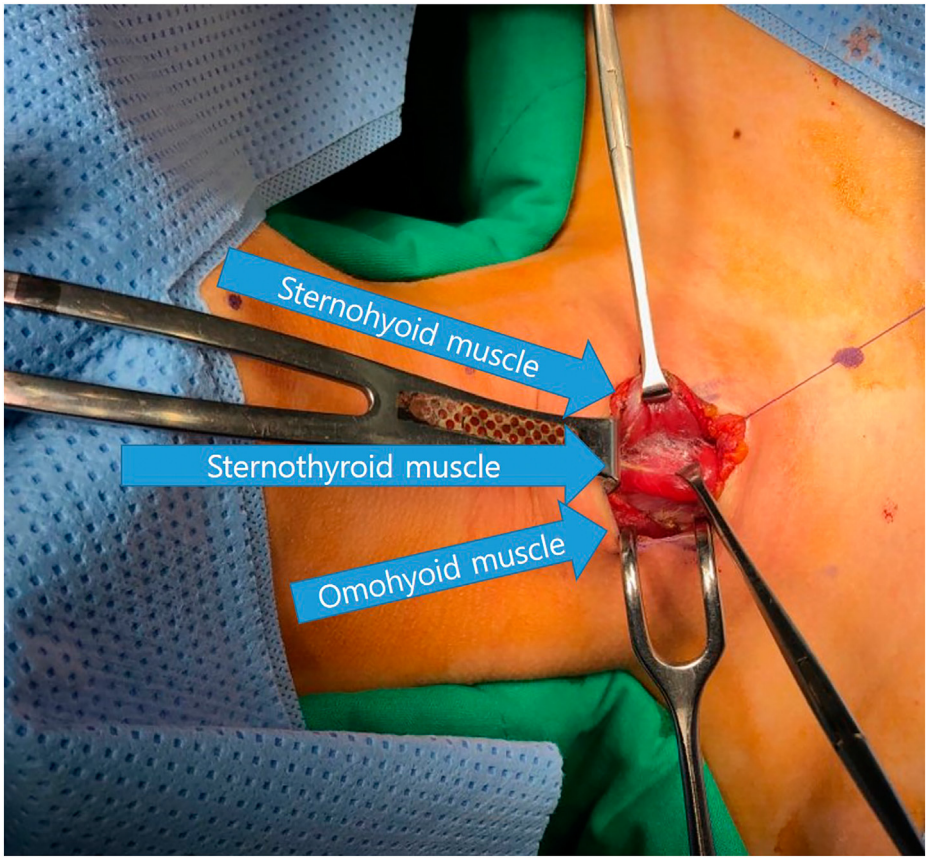

Fig. 1. Medial border of the sternocleidomastoid muscles; the omohyoid muscle can be identified. On dissecting between the sternohyoid and sternothyroid muscles, the thyroid is exposed.

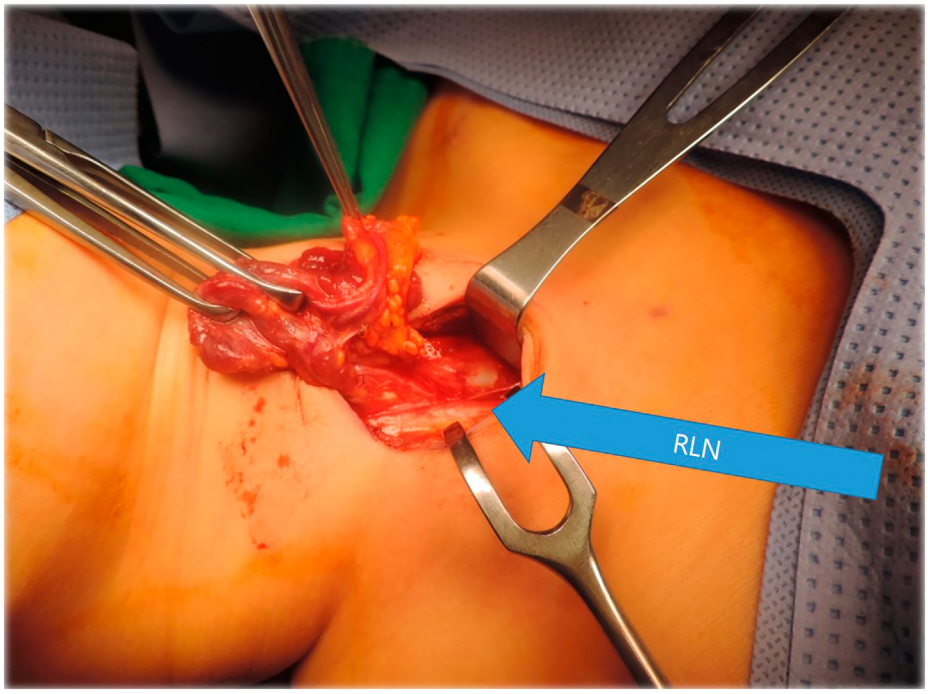

Fig. 2. When the upper pole of the thyroid gland is dissected, the whole thyroid gland can be removed out of the skin incision. A recurrent laryngeal nerve can be identified.

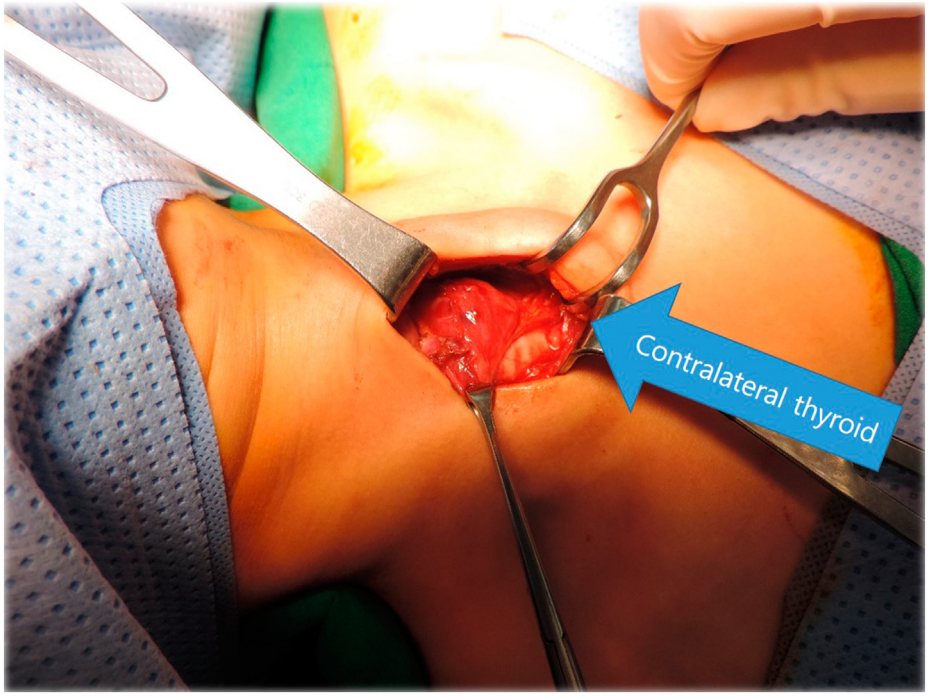

Fig. 3. Bilateral total thyroidectomy by retracting the contralateral thyroid to the opening.

Table 1
Comparison of characteristics between patients who underwent minimally invasive open thyroidectomy and those who underwent conventional thyroidectomy.

Variable		MIT (N = 249)	Conventional (N = 631)	p-value
Age		41.8 ± 10.8	45.7 ± 11.9	0.025
Female		211 (84.7%)	500 (79.1%)	ns
Tumor size (cm)		0.91 ± 0.78	1.03 ± 0.83	ns
Histology	Adenomatous Hyperplasia	9 (3.6%)	31 (4.9%)	ns
	Hurthle Cell Adenoma	0	1 (0.1%)	
	Follicular Adenoma	1 (0.1%)	0	
	Degenerative Lesion	0	1 (0.1%)	
	Thyroiditis	1 (0.1%)	3 (0.3%)	
	Papillary Carcinoma	235 (94.4%)	589 (93.2%)	
	Medullary Carcinoma	1 (0.4%)	0	
	Poorly Differentiated Carcinoma	0	1 (0.2%)	
	Follicular Carcinoma	2 (0.8%)	6 (0.9%)	

Table 2
Type of operation performed.

OP type	MIT (N = 249)	Conventional (N = 631)	p-value
Less than total	204 (81.9%)	429 (67.9%)	<0.001
Bilateral total thyroidectomy	45 (18.1%)	203 (32.1%)	

Table 3
Comparison of surgical outcomes.

Clinical Outcomes		MIT (N = 249)	Conventional (N = 631)	p-value
Complications	Hematoma	3 (1.2%)	1 (0.2%)	ns
	Transient Hypocalcemia	3 (1.2%)	7 (1.1%)	
OP time		77.99 ± 34.5	91.23 ± 36.58	<0.001
	Less than total	73.04 ± 33.70	84.93 ± 35.68	<0.001
	Bilateral total thyroidectomy	100.42 ± 28.70	104.54 ± 34.93	ns
Discharge Day		2.4 ± 0.8	3.2 ± 0.8	<0.001
	Less than total	2.4 ± 0.1	3.1 ± 0.04	<0.001
	Bilateral total thyroidectomy	2.8 ± 0.2	3.4 ± 0.7	<0.001
Drain		2 (0.8%)	605 (95.7%)	<0.001

via the minimally invasive approach (73.04 ± 33.70 vs. 84.93 ± 35.68 min). In total thyroidectomy cases, there were no differences observed regarding the two approaches (100.42 ± 28.70 vs. 104.54 ± 34.93).

Patients who underwent MIT could be discharged earlier than those who underwent conventional thyroidectomy (2.4 ± 0.8 vs. 3.2 ± 0.8 days). Only two patients (0.8%) who underwent the minimal approach required drain insertion, whereas 605 patients (95.7%) who underwent the conventional approach required such procedures (Table 3). Regarding the cosmetic outcome, the scar became almost invisible after 1 year of MIT (Fig. 4a and b).

4. Discussion

In this study, we modified our previously reported technique of MIT by making a unilateral incision and not transecting the strap muscles. Visibility was maintained by reaching the thyroid through dissection between the sternohyoid and sternothyroid muscles. Different from our previous reported technique and techniques reported by Ikeda and Sabuncuoglu, we performed a lateral skin incision and not a central incision.[13,14]

In the previously reported MATS, injection of bupivacaine with adrenaline solution was used for the subplatysmal plane. Most of the cases were benign diseases (84%) and only four had malignant disease (16%). Three patients with thyroid cancer subsequently underwent uncomplicated completion thyroidectomy through standard open incisions.[8] Whereas conventional open thyroidectomy is suitable for any thyroid disease, MNIT was limited to small-volume diseases. However, with our new method of MIT, both lobectomy and total thyroidectomy are feasible with a small incision.

With the modified approach, contralateral thyroidectomy is feasible without any restrictions; thus, total thyroidectomy is possible. We believe that when good retraction is available, key anatomical structures in the neck can easily be seen through small incisions as in big incisions.

The modified invasive open thyroidectomy described here is technically similar to conventional thyroidectomy, and each step in the procedure can be performed by the traditional approach that most surgeons are familiar with. Govednik et al reported on MIT with a 2 cm anterior transverse cervical incision, which was made as close to the isthmus as possible. The strap muscles were divided at the midline along the crease into a diamond-shaped opening with a length of >2 cm. Pediatric-sized instruments were used, along with loupe magnification (×2.5) and headlamps for improved operative exposure. No drains were used.[7]

The procedure differs from that of the previously reported MIT, in that it has a lateral skin incision in case of bilateral total thyroidectomy and it does not require transverse division of the strap muscles. This technique does not need raising of skin flaps; thus, it can avoid damage to the subcutaneous tissue and surgical trauma to the midline of the neck, minimizing the potential risk of complications related to the raising of skin flaps and longitudinal opening of the strap muscles.

Even though the wound opening is small in the minimally invasive technique, sufficient exposure for dissection of the pretracheal and paratracheal spaces can be obtained by lateral retraction of the wound and anteromedial traction of the specimen outside the open wound. This allows access to the entire length of the recurrent laryngeal nerve, parathyroid glands, and lymph nodes along the tracheoesophageal groove. Given that this approach is minimally invasive, no wound drains are necessary in most cases. Moreover, it is associated with a shorter operative time and shorter hospital stay without compromising the extent of surgery. In addition, the cosmetic results are superior to those of the conventional approach.

Our data revealed that modified MIT has a similar or shorter operative time, comparable surgical morbidity (hemorrhage and hypoparathyroidism), and shorter hospital stay than the conventional approach. The long-term effects on cosmesis and locoregional disease control need to be studied further. From the surgical perspective, conversion to conventional open thyroidectomy is always unexpected. To avoid the need for this conversion, strict inclusion criteria need to be met for MIT.

Significant stretching of the intraoperative incision is likely to occur during MIT. Follow-up data suggested that the increase in incision length is not permanent and resolves upon postoperative follow-up.[15] The goal of minimally invasive surgery is not only to improve aesthetics but also to minimize damage to the surgical field, which is related to minimizing wound complications, decreasing pain, and facilitating shorter hospital stay. Takami stated that minimally invasive mini-incision thyroidectomy shows better results than endoscopic and conventional thyroidectomies in terms of postoperative pain and uncomfortable sensations, operative time and hospital stay, and cost-effectiveness.[16] However, making a small incision in the neck is not associated with better satisfaction[17]; the length of the skin incision may not influence the perception of pain after surgery.[18] Nevertheless, minimally invasive approaches have a variety of advantages in terms of shorter hospital stay and cost-effectiveness with similar complication rates as those of the conventional approaches.

Perigli reported that patients undergoing minimal-incision thyroidectomy experienced significantly less postoperative pain and were more satisfied with the cosmetic result than those who underwent conventional thyroidectomy, but postoperative complications were similar between the two groups.[19]

In conclusion, in selected patients, modified MIT through a small

Fig. 4. a Scar immediately after skin closure. 4b Scar 1 year after surgery.

unilateral incision without transection of the strap muscles and without any endoscopic or videoscopic assistance is a safe alternative to standard open thyroidectomy in the hands of an experienced endocrine surgeon. The clinical results are comparable to those of the conventional approach. Moreover, the operative time is shorter in MIT than in conventional thyroidectomy. The MIT technique is applicable not only to benign thyroid disease but also to thyroid carcinoma requiring central compartment node dissection. Besides lobectomy, total thyroidectomy is also feasible with a small incision. Minimally invasive surgical techniques are attractive not only in terms of the cosmetic benefit of a small incision but also in terms of their advantage of less tissue trauma.

References

1. Park CS, Chung WY, Chang HS. Minimally invasive open thyroidectomy. *Surg Today*. 2001;31:665–669.
2. Dralle H, Machens A, Thanh PN. Minimally invasive compared with conventional thyroidectomy for nodular goitre. *Best Pract Res Clin Endocrinol Metabol*. 2014;28:589–599.
3. Gagner M. Endoscopic subtotal parathyroidectomy in patients with primary hyperparathyroidism. *Br J Surg*. 1996;83, 875-875.
4. Bakkar S, Materazzi G, Biricotti M, et al. Minimally invasive video-assisted thyroidectomy (MIVAT) from A to Z. *Surg Today*. 2016;46:255–259.
5. Fan YB, Guo BM, Guo SL, et al. Minimally invasive video-assisted thyroidectomy: experience of 300 cases. *Surg Endosc*. 2010;24:2393–2400.
6. Brunaud L, Zarnegar R, Wada N, Ituarte P, Clark OH, Duh QY. Incision length for standard thyroidectomy and parathyroidectomy - when is it minimally invasive? *Arch Surg-Chicago*. 2003;138:1140–1143.
7. Govednik CM, Snyder SK, Quinn CE, Saxena S, Jupiter DC. Minimally invasive, nonendoscopic thyroidectomy: a cosmetic alternative to robotic-assisted thyroidectomy. *Surgery*. 2014;156:1030–1037.
8. Gosnell JE, Sackett WR, Sidhu S, Sywak M, Reeve TS, Delbridge LW. Minimal access thyroid surgery: technique and report of the first 25 cases. *ANZ J Surg*. 2004;74:330–334.
9. Miccoli P, Berti P, Materazzi G, Minuto M, Barellini L. Minimally invasive video-assisted thyroidectomy: five years of experience. *J Am Coll Surg*. 2004;199:243–248.
10. Timon C, Miller IS. Minimally invasive video-assisted thyroidectomy: indications and technique. *Laryngoscope*. 2006;116:1046–1049.
11. Ferzli GS, Sayad P, Abdo Z, Cacchione RN. Minimally invasive, nonendoscopic thyroid surgery. *J Am Coll Surg*. 2001;192:665–668.
12. Perigli G, Cortesini C, Qirici E, Boni D, Cianchi F. Clinical benefits of minimally invasive techniques in thyroid surgery. *World J Surg*. 2008;32:45–50.
13. Sabuncuoglu MZ, Sabuncuoglu A, Sozen I, Benzin MF, Cakir T, Cetin R. Minimally invasive surgery using mini anterior incision for thyroid diseases: a prospective cohort study. *Int J Clin Exp Med*. 2014;7:3404–3409.
14. Ikeda Y, Takami H, Tajima G, et al. Direct mini-incision thyroidectomy. *Biomed Pharmacother*. 2002;56:60s–63s.
15. Chen N, Stephenson LA, Jorgensen JB, Zitsch RP. Stretch of the minimally invasive incision during thyroid and parathyroid surgery. *Otolaryng Head Neck*. 2014;151:582–585.
16. Takami H. Section 2. Thyroid - introduction. *Biomed Pharmacother*. 2002;56:53s–54s.
17. Linos D, Economopoulos KP, Kiriakopoulos A, Linos E, Petralias A. Scar perceptions after thyroid and parathyroid surgery: comparison of minimal and conventional approaches. *Surgery*. 2013;153:400–407.
18. Alesina PF, Rolfs T, Ruhland K, Brunkhorst V, Groeben H, Walz MK. Evaluation of postoperative pain after minimally invasive video-assisted and conventional thyroidectomy: results of a prospective study ESES Vienna Presentation. *Langenbeck Arch Surg*. 2010;395:845–849.
19. Perigli G, Qirici E, Badii B, et al. Feasibility and safety of minimal-incision thyroidectomy for Graves' disease: a prospective, single-center study. *Head Neck-J Sci Spec*. 2013;35:1345–1348.