The influence of distance from the wound margin to the insertion point in a mattress suture on ideal primary closure in alveolar mucosa: an *in vitro* experimental study

Won-Ho Lee
Department of Dentistry
The Graduate School, Yonsei University

The influence of distance from the wound margin to the insertion point in a mattress suture on ideal primary closure in alveolar mucosa: an *in vitro* experimental study

Directed by Professor Jung-Seok Lee

The Doctoral Dissertation
submitted to the Department of Dentistry
and the Graduate School of Yonsei University
in partial fulfillment of the requirements for the degree of
Ph.D. in Dental Science

Won-Ho Lee

June 2021

This certifies that the Doctoral Dissertation
of Won-Ho Lee is approved.

Thesis Supervisor: Jung-Seok Lee

Seong-Ho Choi

Jae-Kook Cha

Young-Taek Kim

Hyun-Chang Lim

The Graduate School
Yonsei University
June 2021

감사의 글

치주과 박사 과정을 마치며 도움을 주신 모든 분들께 진심으로 감사 인사를 드립니다. 가장 먼저, 치주과 의사이자 연구자로서 본보기가 되어주시고 이 논문이 완성되기까지 부족한 저를 끊임없이 지도해주시고 격려해주신 이중석교수님께 진심으로 감사 드립니다. 또한, 저의 치주과 수련과정 및 대학원 재학중의 은사님들이신 조규성, 최성호, 김창성, 정의원, 차재국, 백정원 교수님께 깊이 감사를 드립니다. 바쁘신 와중에도 저의 학위 논문 심사를 맡아주시고 아낌없는 조언을 해주신 김영택 교수님, 임현창 교수님께도 감사를 드립니다. 수련기간 동안 함께했던 치주과 의국원들과 연구원 선생님들께도 감사의 마음을 전합니다.

마지막으로 오늘의 저를 있게 해주신, 언제나 저를 믿고 지켜봐 주시고 든든한 버팀목이 되어주신 사랑하는 부모님께 사랑과 감사의 마음을 전합니다. 아낌없는 사랑과 격려로 항상 저를 일으켜준 사랑하는 아내 보화, 그리고 존재 자체만으로도 힘을 주는 사랑하는 아들 한빈에게 감사의 마음을 전합니다.

2021년 6월

저자 이원호

Table of Contents

List of Figures

List of Tables

Abstract

The influence of distance from the wound margin to the insertion point in a mattress suture on ideal primary closure in alveolar mucosa: an *in vitro* experimental study

Won-Ho Lee, D.D.S, M.S.

Department of Dentistry
The Graduate School, Yonsei University

(Directed by Professor Jung-Seok Lee, D.D.S., M.S.D., PhD.)

Purpose: To determine how the distance of the near insertion points in a vertical mattress suture from the wound margin influences the pattern of primary closure in an *in vitro* experimental model.

Materials and methods: Pairs of 180 porcine gingiva and alveolar mucosa samples were harvested from 90 pig-jaws and fixed to a specially designed model. A vertical mattress suture was performed with the near insertion point at three different distances from the wound margin (1, 3, and 5mm) on both the gingival and mucosal samples (six groups; *n*=30 for each group). The margin discrepancy and the presence of epithelium between the wound margins were measured on histologic slides.

Results: The margin discrepancy decreased significantly as the near insertion point became closer to the wound margin in both mucosal tissue (0.241±0.169mm, 0.945±0.497mm, and 1.306±0.773 mm for 1-, 3-, and 5-mm group, respectively) and gingival tissue (0.373±0.304mm, 0.698±0.431mm, and 0.713±0.691mm, respectively). The frequency of complicated wound margin adaptations reduced as the distance of the near insertion point from the wound margin decreased in both mucosal and gingival tissues.

Conclusions: Placing the near insertion point close to the wound margin enhances the precision of wound margin approximation/adaptation in vertical mattress suture.

Keywords: Mattress suture, Insertion point, Clinical protocol, Soft tissue management

The influence of distance from the wound margin to the insertion point in a mattress suture on ideal primary closure in alveolar mucosa: an *in vitro* experimental study

Won-Ho Lee, D.D.S, M.S.

Department of Dentistry
The Graduate School, Yonsei University

(Directed by Professor Jung-Seok Lee, D.D.S., M.S.D., PhD.)

I. Introduction

The vertical mattress suture technique has frequently been recommended for various oral regenerative surgeries, such as in guided tissue regeneration [1], minimally invasive surgical technique [2], and guided bone regeneration [3,4]. This suture technique was initially introduced for dermal tissue based on the advantages of precise adaptation and an everting wound margin, and moving the tension away from the margin [5]. The vertical mattress suture is also used in dentistry for the same purposes; that is, resisting muscle pulling, everting the wound margins, and firmly adapting the tissue flaps to underlying

structures such as bones, regenerative membranes, and implants [6,7]. However, although some characteristics differ between the oral mucosa and dermal tissue (thin and a ridge shape versus thick and flat) [8], there are no clear guidelines for the use of the vertical mattress suture on the oral mucosa.

Wound healing depends on early vascularization from the two opposing tissues, and the vertical mattress suture aims at enhancing the adaptation between vessel-abundant connective tissues from the superficial to deep layers. However, even though the mattress suture technique had been applied in some cases, incomplete wound healing such as dehiscence can occur following the alveolar augmentation procedure [9-11]. The presence of epithelium between the connective tissues of wound margins is one of the causal risk factors, in addition to the flap thickness and tension [7,12]. In this context, properly controlling the insertion points of the suture appears critical for the precise approximation of the wound margins in a mechanical aspect [13,14].

In a conventional protocol of the vertical mattress suture for dermal tissue, the far-far insertion points are recommended to be located 4 to 8 mm from the wound margin, and the near-near insertion points at 1 to 2 mm [15]. However, for the purpose of enhancing wound margin adaptation and promoting wound healing, the closer near-near insertion points should be applied. In addition, the farther insertion points in a mattress suture cannot be used to apply force in an appropriate direction for ensuring margin adaptation by tightening the suture. Further, it has been suggested that the near-near insertion point should be as superficial as possible [5], and that when the near-near insertion point is far

from the wound margin, healing is delayed and/or compromised due to an ‘eversion-inversion phenomenon’ at the two wound margins that remain unsupported [16]. However, there has been no systematic assessment of how the distance of the insertion point from the wound margin in the vertical mattress suture influences the pattern of primary wound closure in gingival and oral mucosal incisional wounds.

This study aimed to determine how the distance of the insertion point closest to the wound margin in a vertical mattress suture influences the pattern of primary wound closure using an *in vitro* experimental model mimicking the alveolar ridge crest.

II. Materials and Methods

1. Study design

This in vitro study was performed using alveolar mucosa and gingiva from pig-jaws as described for a previous study that evaluated suture tension [17]. The harvested porcine mucosa and gingiva were fixed on a specially designed model fabricated by replicating the dental cast of a partially edentulous maxilla using silicone putty (HySil Putty, Osstem, Seoul, Korea) (Figure 1), and suturing was performed. Six experimental groups were formed according to the distance of the near insertion point from the wound margin and the type of oral mucosa: 1, 3, and 5 mm in mucosa and gingival flaps.

2. Experimental model

This study retrieved 180 alveolar mucosa samples and 180 gingival samples from 90 fresh lower pig-jaws. One pair of standardized mucosa samples (12 mm×12 mm) obtained from the floor of the mouth (nonkeratinized tissue with a thickness of 1–1.5 mm) and one pair of gingival samples with the same dimensions obtained from the alveolar ridge (keratinized tissue with a thickness of 2–4 mm) were harvested from each pig-jaw using a surgical scalpel and a periosteal elevator. The tissue samples were kept moist with wet gauzes soaked with saline and stored in a refrigerator until suturing in order to prevent them drying out and any tissue degeneration. To mimic the clinical setting for

suturing, one pair of harvested tissue samples (mucosa or gingiva from the same pig-jaw) was fixed (tacked) to a silicone model using metal pins at a position that allowed 1 mm of overlap between the wound margins. Finally, a total of 90 mucosal and 90 gingival experimental models were prepared and divided into each three experimental groups according to the distance of the near insertion point from the wound margin and the type of tissue.

3. Experimental procedures

Three vertical mattress sutures were performed on one prepared experimental model with intervals of 3 mm. One expert (W.H.L.) performed vertical mattress suture under professional supervision (J.S.L.). The suture was started using far-to-far insertion followed by near-to-near insertion between the tissue flaps on the buccal and palatal sides of the prepared model, using a monofilament suture (Monosyn 6-0, B.BraunAesculap, Tuttlingen, Germany). The near insertion points were positioned according to the group allocation, and the far insertion point was located 3 mm from the near insertion point. The knot was formed on the buccal side after passing through the loop between the near and far points on the palatal side (modified vertical mattress suture technique). After placing the sutures, all samples showed tight primary closure and there was no discrepancy between the flaps in clinical observations. The sample (including the model) was fixed with 10% neutral buffered formalin.

4. Histologic preparation

After 7 days of fixation, the specimens were mechanically fixed using an additional fixation pin at the center of the sample in order to minimize deformation during gross sectioning, and the specimens containing sutures were sectioned at the most-central region. The sectioned specimens were placed in tissue processing cassettes and fixed in buffered formalin for an additional 2 days. The silicone putty was then carefully removed, and the residual specimen was dehydrated by immersing in a series of ethanol solutions. The specimens were embedded in paraffin and cut along the longitudinal axis immediately adjacent to the central suture to a thickness of 4 μm using a microtome (RM2255, Leica, Nussloch, Germany). The sections were stained with hematoxylin-eosin, and histologic slides were digitally scanned and converted into digital image files for the histologic analysis.

5. Margin discrepancy between wound margins

The discrepancy between the two wound margins (i.e., the vertical difference between the tops of the epithelial of the two wound margins) was measured on histologic slides (Figure 2) using computer software (CaseViewer2.0, 3DHisTech, Budapest, Hungary) to evaluate the accuracy of primary closure according to the distance of the near insertion points. The maximum value measured on three histologic slides of the same experimental sample was considered to be the representative value of that sample.

6. Histologic observations of complicated primary closure

Considering that the purpose of a suture is to make two wound margins meet precisely, the occurrence of certain complications in primary closure is a risk factor for delayed healing. The frequencies of the following complications were counted to evaluate the pattern of primary closure (Figure 3):

- Overlapping, where the epithelium of one of the flaps rolls down the other one, resulting in contact of the epithelium with the connective-tissue layer.
- Folding, where both wound margins are folded such that the outer surfaces of the epithelium are in contact with each other.
- Sliding, where one flap slides completely under the connective tissue of the opposing flap.

7. Statistical analysis

A required sample size of 30 samples per group was calculated using R software (R 3.6.3, The R Foundation, Vienna, Austria) with the margin discrepancy as the primary outcome, for a one-way analysis of variance with a two-sided alpha level of 5%, a statistical power of 95%, and an effect size of 0.4 [18]. The statistical analysis was performed using SPSS software (SPSS version 23.0, SPSS, Chicago, IL, USA). The mean and standard-deviation values of the margin discrepancy were calculated. Whether the data conformed to a normal distribution was evaluated using the Kolmogorov-Smirnov test, with then either one-way analysis of variance or the Kruskal-Wallis test applied accordingly. Either the Bonferroni or Mann-Whitney post-hoc test was also

applied. The frequencies of complications were compared between experimental groups using Pearson's chi-square test and Fisher's exact test. The criterion for statistical significance was set at $P<0.05$.

III. Results

All samples showed tight primary closure of the flaps after suture in clinical inspections. However, the histologic results revealed various types of contact between the two flaps, including complicated situations such as a dislocated apposition of each wound margin and epithelium being caught between the two wound margin (overlapping, folding, and sliding; Figure 3).

1. Measurements of the margin discrepancy

The measured margin discrepancies are presented in Table 1 and Figure 4. The margin discrepancies in the mucosal samples were 0.241±0.169mm, 0.945±0.497mm, and 1.306±0.773 mm for the 1-, 3-, and 5-mm groups, respectively; the corresponding values in the gingival samples were 0.373±0.304mm, 0.698±0.431mm, and 0.713±0.691mm. Multiple comparisons revealed that the 1-mm group showed a statistically significant difference compared to 3-mm and 5-mm groups in mucosal samples, and to 3-mm group in gingival samples.

2. Frequency of complications

The results for the frequency of complications are presented in Table 2. In general, the complications were more frequent in samples of the oral mucosa rather than in the

gingiva samples. The most-frequent complication in all of the samples was overlapping (53.62% and 85.37% of mucosal and gingival samples, respectively), followed by sliding (36.23% and 14.63%) and folding (10.14% and 0%). The total frequency of complications was significantly lower in the 1-mm group (43.33%) than in the 3-mm (93.33%) and 5-mm (93.33%) groups for the mucosal samples (P=0.005). The frequency of sliding in mucosal samples was also significantly lower in the 1-mm group (0%) than in both the 3-mm (33.33%) and 5-mm (50.00%) groups (P=0.005). Overlapping and folding occurred at similar frequencies regardless of the distance of the near insertion point from the wound margin. The frequency of complications in gingival samples also showed an increasing tendency as the near insertion point moved farther from the wound margin (36.67%, 43.33%, and 56.67% for the 1-, 3-, and 5-mm groups, respectively; P> 0.05). Only sliding in gingival samples occurred at a significantly higher rate in the 5-mm group, and it did not occur in the 1-mm group.

IV. Discussion

Suturing is the last step in most oral surgeries and critically affects their clinical success. The precise approximation of wound margins is one of the requirements for an ideal suture [13], and the vertical mattress suture is one of the widely applied techniques with this aim in the fields of periodontal and implant surgery [19]. However, there is little scientific evidence in the literature for producing a guideline for the clinical protocol of the suture, especially regarding how the details of each step influence the outcome.

The present in vitro study is the first to evaluate how the primary closure pattern varies with the distance of the near insertion point from the wound margin for vertical mattress sutures in mucosal and gingival tissues (Figure 5). Two main findings were obtained: (1) the closest near insertion point of the vertical mattress suture (i.e., 1 mm from the wound margin) reduced the discrepancy between the two wound margins in both mucosal and gingival tissues, with the difference being statistically significant in mucosal tissue, and (2) the frequency of complications (epithelium being caught between the flaps) was significantly higher in specimens with farther near insertion points (3 and 5 mm) than in those with the closest near insertion point (1 mm) in both mucosal and gingival tissues.

Wound healing includes inflammatory, proliferative, and remodeling phases [20]. The first two phases are delayed in cases of secondary-intention healing (e.g., with wound dehiscence). In contrast, in primary-intention healing, the precisely approximated wound margins share the same structure of epithelium and connective tissue layers as well as

small vessels, and wound healing is promoted by minimizing the inflammatory and proliferative tissue phases. However, improper suturing can result in an unsupported or gapped superficial wound margin and/or a discrepancy between the wound margins, which will negatively influence healing and may lead to scar formation [16]. A previous clinical study of dermal tissue suturing found that an additional interrupted suture could enhance the approximation of the superficial wound margins and reduce scar formation compared to a single vertical mattress suture in the deeper layer of a wound [21]. The vertical mattress suture was originally devised by Mario Donati to enhance the approximation of wound margins and move the tension from the wound margin to the intermediate flap region between the near and far insertion points [5]. In oral mucosa suturing for augmentation surgery, a modified version of mattress suturing was also introduced to increase the precise approximation of the superficial wound margins [19].

The present study found that the precision of the approximation of the flaps in mattress sutures was significantly enhanced when the near insertion point was closer to the wound margin. This corresponds to the methodology of the originally devised mattress suture technique for dermal tissue, for which it was suggested that the near insertion point be placed as superficially as possible [5]. Another previous report described a complicated situation of ‘eversion-inversion phenomenon’ in which the superficial region was unsupported and healing was delayed for the farther near insertion point in mattress suture [16]. In the suture technique performed on the crest of the alveolar ridge, this pattern can be exaggerated due to the flap tension acting in the apical

direction, especially in augmentation surgery.

The optimal distance of the near insertion point should be separately considered along with the optimal bite size of the single interrupted suture. Some experts have recommended that the bite size should never be less than 1–2 mm, due to the risk of tearing the mucosal wound margin [22]. In contrast, in mattress suture, the tension is concentrated in the area between the near and far insertion points rather than around the wound margin, and so using closer near insertion points might enhance the precision in the approximation between the flaps without inducing excessive stress at the wound margin.

The presence of epithelial tissue between two wound margins can delay the healing process. Incised wound margins share the continuous structures of the epithelium, connective tissue, and vessels, and these can be unified with minimal inflammatory and proliferative responses. On the other hand, wound healing can be delayed by degradation of a squeezed epithelial layer, which extends the initial healing phases of inflammation. In particular, if the epithelium slides under the opposing flap, this may induce complete separation of the each flap margin and limited wound healing, and it can be the beginning of the wound dehiscence or membrane exposure. A previous clinical study of the lateral ridge augmentation found that 70% of wound dehiscence occurred in the mandibular region that showed more mucosal tissue and less gingival tissue than the maxilla [23]. The present study found that a significantly increased rate of overall (epithelium-related) complications and especially of a sliding epithelium can produce the aforementioned

clinical result. However, the occurrence of complications (even in mucosal tissue) was significantly reduced when the near insertion point was closer to the wound margin (1 mm). Therefore, the guideline of a closer near insertion point should be emphasized, especially when suturing mucosal tissues.

The present study was performed in vitro using harvested mucosal and gingival samples in a clinically mimicked alveolar ridge-shaped model, which could have resulted in critical limitations due to differences between vital and nonvital tissues and between human and porcine tissues. Many other factors such as flap advancement may also affect discrepancies or other complications in primary closure. Therefore, the present results need to be confirmed in future studies with other designs and clinical settings.

V. Conclusion

Notwithstanding the limitations of this study, the present results clearly revealed tendencies of an increasing discrepancy of the wound margin and an increased rate of epithelium-related complications when the near insertion points were further from the wound margin (3 and 5 mm) compared to the closest near insertion point (1 mm). These findings may represent scientific evidence for the guideline of using closer near insertion points in the mattress suture technique.

References

1. Griffin TJ, Hur Y, Bu JJCAiP. Basic Suture Techniques for Oral Mucosa. 2011;1:221-32.
2. Cortellini P, Tonetti MS. Improved wound stability with a modified minimally invasive surgical technique in the regenerative treatment of isolated interdental intrabony defects. J Clin Periodontol 2009;36:157-63.
3. Urban IA, Lozada JL, Wessing B, Suarez-Lopez del Amo F, Wang HL. Vertical Bone Grafting and Periosteal Vertical Mattress Suture for the Fixation of Resorbable Membranes and Stabilization of Particulate Grafts in Horizontal Guided Bone Regeneration to Achieve More Predictable Results: A Technical Report. Int J Periodontics Restorative Dent 2016;36:153-9.
4. Plonka AB, Urban IA, Wang HL. Decision Tree for Vertical Ridge Augmentation. Int J Periodontics Restorative Dent 2018;38:269-75.
5. Dietz UA, Kuhfuss I, Debus ES, Thiede A. Mario Donati and the vertical mattress suture of the skin. World J Surg 2006;30:141-8.
6. Silverstein LH, Kurtzman GM. A review of dental suturing for optimal soft-tissue management. Compend Contin Educ Dent 2005;26:163-6, 9-70; quiz 71, 209.
7. Burkhardt R, Lang NP. Influence of suturing on wound healing. Periodontol 2000 2015;68:270-81.
8. Moore RL, Hill M. Suturing techniques for periodontal plastic surgery. Periodontol 2000 1996;11:103-11.
9. Fugazzotto PA. Maintenance of soft tissue closure following guided bone regeneration: technical considerations and report of 723 cases. J Periodontol 1999;70:1085-97.

10. Lorenzoni M, Pertl C, Polansky R, Wegscheider W. Guided bone regeneration with barrier membranes--a clinical and radiographic follow-up study after 24 months. Clin Oral Implants Res 1999;10:16-23.

11. Sanz-Sanchez I, Ortiz-Vigon A, Sanz-Martin I, Figuero E, Sanz M. Effectiveness of Lateral Bone Augmentation on the Alveolar Crest Dimension: A Systematic Review and Meta-analysis. J Dent Res 2015;94:128S-42S.

12. Burkhardt R, Lang NP. Role of flap tension in primary wound closure of mucoperiosteal flaps: a prospective cohort study. Clin Oral Implants Res 2010;21:50-4.

13. Moy RL, Waldman B, Hein DW. A review of sutures and suturing techniques. J Dermatol Surg Oncol 1992;18:785-95.

14. Adams B, Anwar J, Wrone DA, Alam M. Techniques for cutaneous sutured closures: variants and indications. Semin Cutan Med Surg 2003;22:306-16.

15. Zuber TJ. The mattress sutures: vertical, horizontal, and corner stitch. Am Fam Physician 2002;66:2231-6.

16. Miller CJ, Antunes MB, Sobanko JF. Surgical technique for optimal outcomes: Part II. Repairing tissue: suturing. J Am Acad Dermatol 2015;72:389-402.

17. Burkhardt R, Preiss A, Joss A, Lang NP. Influence of suture tension to the tearing characteristics of the soft tissues: an in vitro experiment. Clin Oral Implants Res 2008;19:314-9.

18. Cohen J. Statistical power analysis for the behavioral sciences. Academic press; 2013.

19. Wachtel H, Fickl S, Zuhr O, Hurzeler MB. The double-sling suture: a modified technique for primary wound closure. Eur J Esthet Dent 2006;1:314-24.

20. Velnar T, Bailey T, Smrkolj V. The wound healing process: an overview of the cellular and molecular mechanisms. J Int Med Res 2009;37:1528-42.

21. Joo JS, Zhuang AR, Tchanque-Fossuo C, Tartar D, Armstrong AW, King TH, et al. Dermal suture only versus layered closure: A randomized, split wound comparative effectiveness trial. J Am Acad Dermatol 2019;81:1346-52.

22. Zuhr O, Akakpo DL, Hurzeler M. Wound closure and wound healing. Suture techniques in contemporary periodontal and implant surgery: Interactions, requirements, and practical considerations. Quintessence Int 2017:647-60.

23. Mordenfeld A, Johansson CB, Albrektsson T, Hallman M. A randomized and controlled clinical trial of two different compositions of deproteinized bovine bone and autogenous bone used for lateral ridge augmentation. Clin Oral Implants Res 2014;25:310-20.

Figure Legends

Figure 1. Study design and experimental procedures

(A) To mimic the shape of the alveolar ridge crest, a specially designed experimental model was fabricated using silicone putty by duplicating the dental cast of a partial edentulous maxilla. (B) To reproduce the clinical setting, the ridge-shaped edentulous area of the silicone model was used in suture experiments. (C) One pair of harvested tissue samples (standardized dimensions: 12 mm×12 mm) from porcine gingiva and mucosa were fixed to the silicone model using pins, with 1mm of overlap between the wound margins. (D) Three modified vertical mattress sutures were performed on the fixed tissue samples at intervals of 3 mm. The near insertion point of the vertical mattress suture was located 1mm, 3mm, or 5mm from the wound margin depending on the group assignment, and the far insertion point was located 3mm from the near insertion point. After the sutures were completed, all samples showed precise wound margin adaptation and tight primary closure in clinical observations. (E) Schematic of the experimental model. The distance of the near insertion point from the wound margin was the main variable. Three groups of mucosal and gingival tissue samples were produced according to the position of the near insertion point.

Figure 2. Histologicmeasurements of the margin discrepancy

The vertical distance between the tops of the epithelium of the two wound margins was measured on histologic slides.

Figure 3. Classification of complications according to the flap adaptation morphologies

Three types of complications were considered in this study: (1) overlapping, where the epithelium of one flap rolls down the other one; (2) folding, where both wound margins are folded such that the outer epithelial surfaces contact each other; and (3) sliding, where one flap slides completely under the connective tissue of the opposing flap.

Figure 4. Histologic measurements of the margin discrepancies in the gingival and mucosal tissues

Each box plot indicates the median, first and third quartiles, and maximum and minimum values of the margin discrepancy. The scatter plot shows the distribution of the margin-discrepancy values within each group. The margin discrepancy in both the mucosal and gingival tissues tended to decrease when the near insertion point was closer to the wound margin.

Figure 5. Representative histologic slides in each group of mucosal and gingival tissues

The dotted area in each low-magnification histologic slide is displayed in the corresponding high-magnification slide. The flap approximation was more precise in both mucosal and gingival tissues when the near insertion point was closer to the wound margin.

Tables

Table 1. Marginal discrepancy measurement results in gingival and mucosal tissue.

Marginal discrepancy (mm)	**1mm** (*n*=30)	**3mm** (*n*=30)	**5mm** (*n*=30)	**One way ANOVA *P*-value**
Gingival tissue	0.373±0.304[a,b)]	0.698±0.431[a)]	0.713±0.691[b)]	0.028
Mucosal tissue	0.241±0.169[c,d)]	0.945±0.497[c,e)]	1.306±0.773[d,e)]	<0.001

Note: Data are presented mean±standard deviation.

[a)]Significant difference (*P*=0.042) between 1mm group and 3mm group at gingival tissue.

[b)]Significant difference (*P* =0.030) between 1mm group and 5mm group at gingival tissue.

[c)]Significant difference (*P* <0.001) between 1mm group and 3mm group at mucosal tissue.

[d)]Significant difference (*P* <0.001) between 1mm group and 5mm group at mucosal tissue.

[e)]Significant difference (*P* =0.034) between 3mm group and 5mm group at mucosal tissue.

Table 2. Frequency of complications in gingival and mucosal tissue.

Complication		Group			Proportion
		1mm	**3mm**	**5mm**	
Mucosa[a)]	Overlap	10/30 (33.33%)	15/30 (50.00%)	12/30 (40.00%)	53.623%
	Folding	3/30 (10.00%)	3/30 (10.00%)	1/30 (3.33%)	10.145%
	Sliding	0/30 (0%)	10/30 (33.33%)	15/30 (50.00%)	36.232%
	Total	13/30 (43.33%)	28/30 (93.33%)	28/30 (93.33%)	-
Gingiva	Overlap	11/30 (36.67%)	12/30 (40.00%)	12/30 (40.00%)	85.366%
	Folding	0/30 (0%)	0/30 (0%)	0/30 (0%)	0%
	Sliding	0/30 (0%)	1/30 (3.33%)	5/30 (16.67%)	14.634%
	Total	11/30 (36.67%)	13/30 (43.33%)	17/30 (56.67%)	-
Overall[a)]	Overlap	21/60 (35.00%)	27/60 (45.00%)	24/60 (40.00%)	65.455%
	Folding	3/60 (5.00%)	3/60 (5.00%)	1/60 (1.67%)	6.363%
	Sliding	0/60 (0%)	11/60 (18.33%)	20/60 (33.33%)	28.182%
	Total	24/60 (40.00%)	41/60 (68.33%)	45/60 (75.00%)	-

[a)] Statistically significant difference between 1mm group and 3mm, 5mm group (P <0.05)

Figures

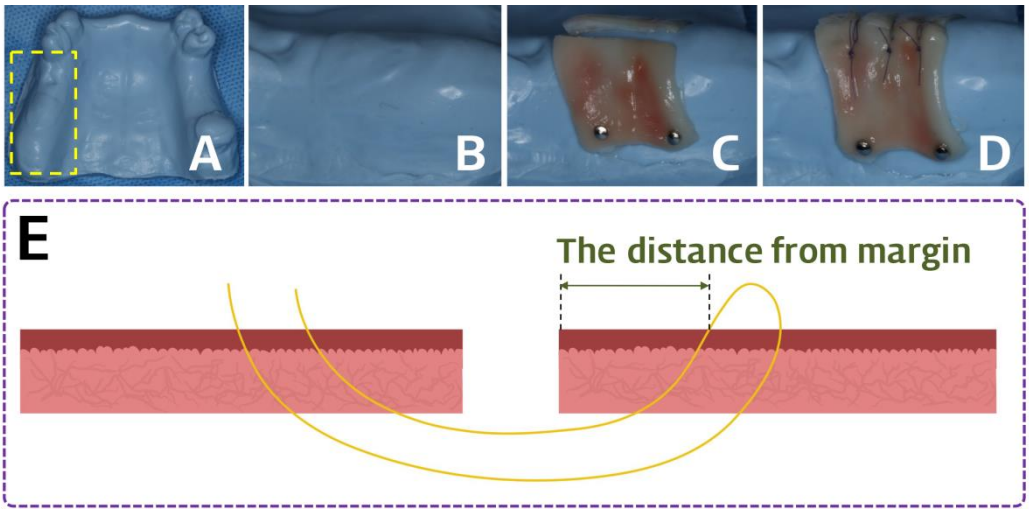

Figure 1

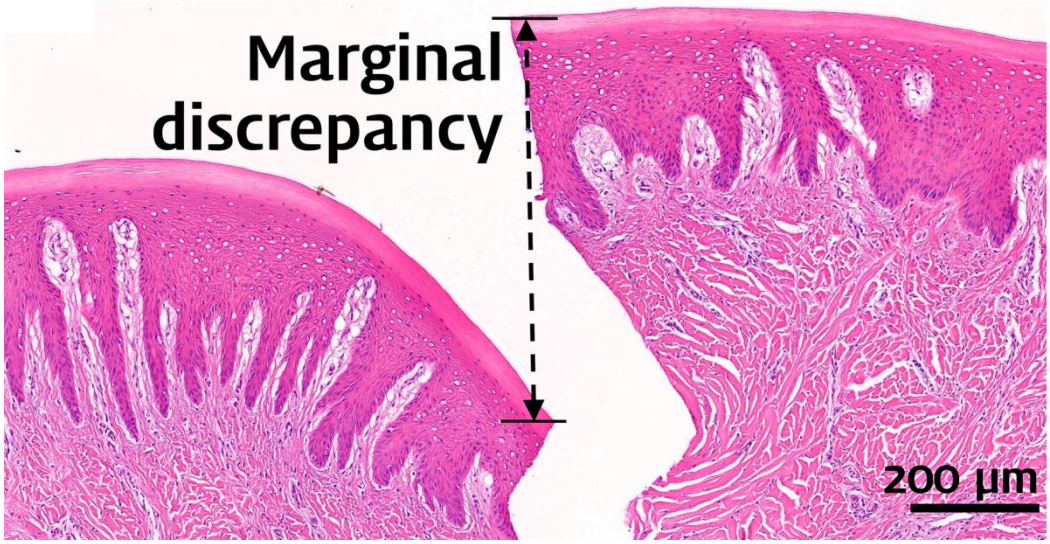

Figure 2

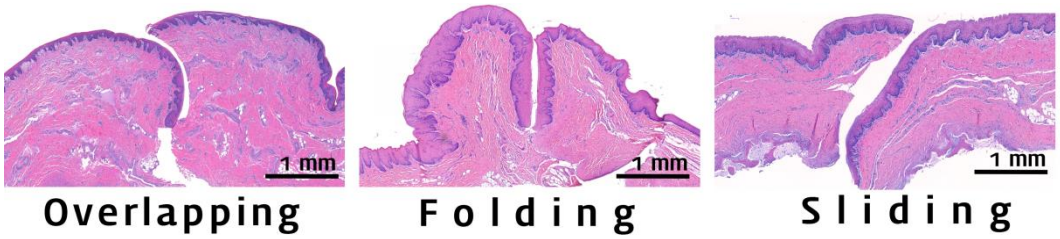

Figure 3

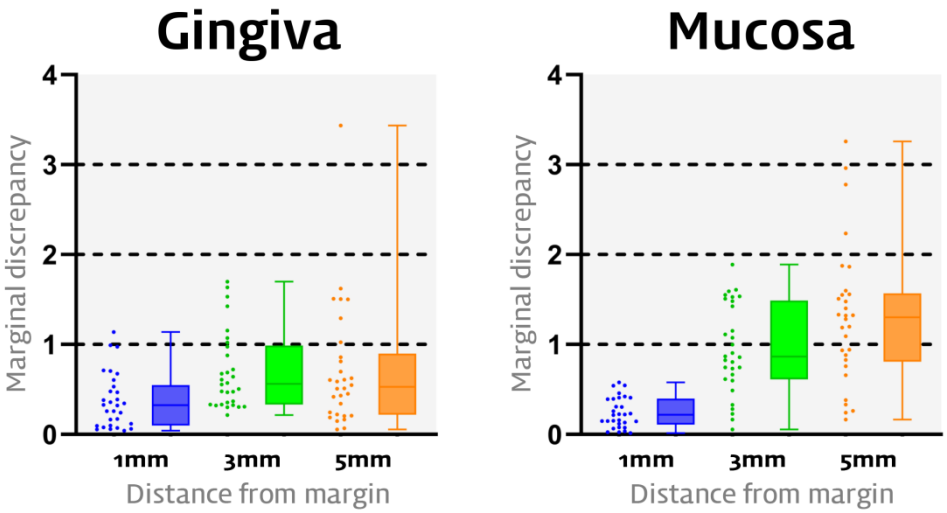

Figure 4

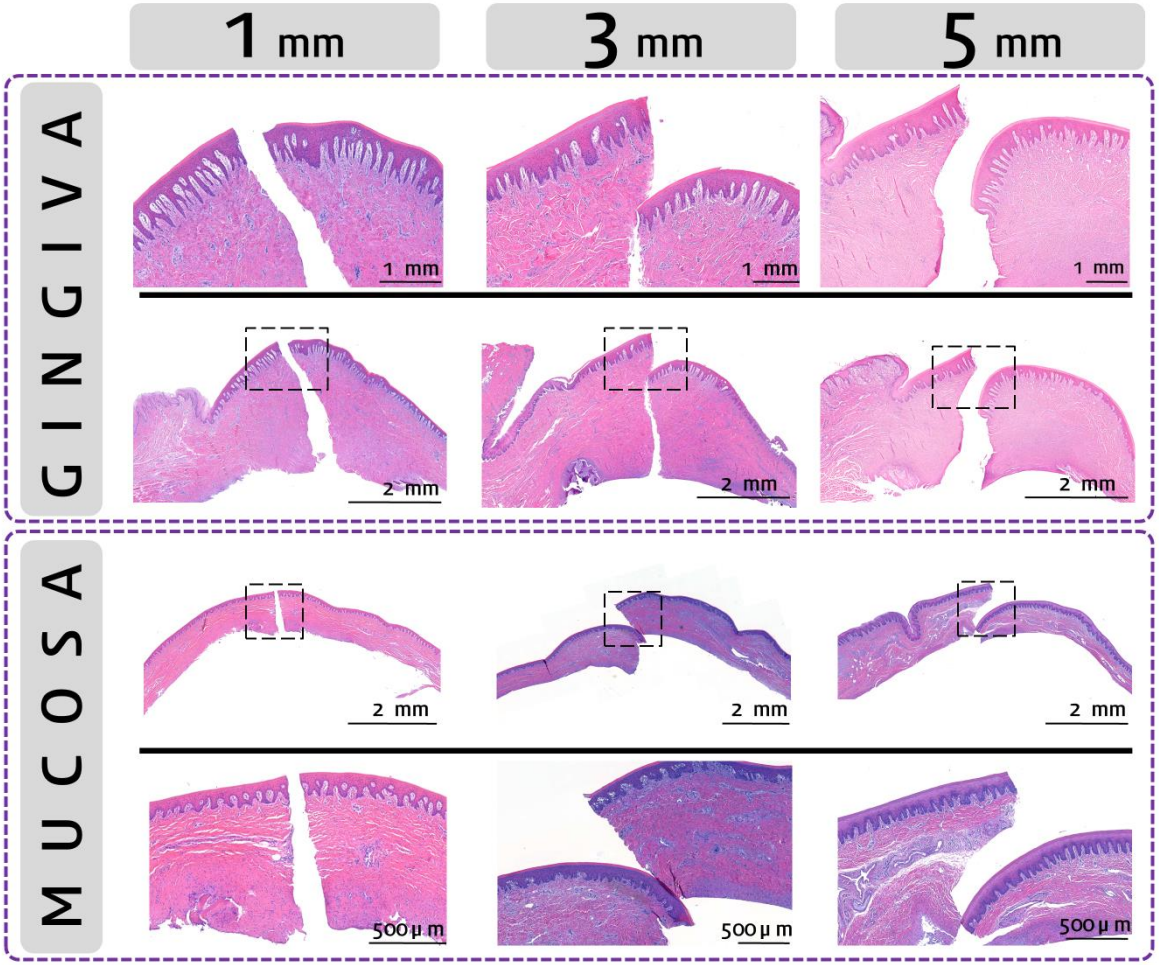

Figure 5

국문요약

창상 변연으로부터 누상봉합의 자입점까지의 거리가 이상적인 일차 창상 폐쇄에 미치는 영향

<지도교수 **이 중 석**>
연세대학교 대학원 치의학과
이 원 호

수직누상봉합은 치주수술과 임플란트 수술 분야에서 널리 사용되어 왔지만, 수직누상봉합의 임상적인 프로토콜에 대한 명확한 지침이 존재하지 않는다. 더욱이, 근위자입점의 위치가 일차 창상 폐쇄에 어떻게 영향을 미치는지에 대한 과학적인 근거가 문헌상으로 부족한 실정이다.

본 연구는 수직누상봉합을 시행할 때 창상변연으로부터 근위자입점까지의 거리가 어떻게 일차 창상 폐쇄 패턴에 영향을 미치는지 평가하기 위하여 *in vitro* 실험모델에서 수행되었다.

총 180 쌍의 돼지 치은과 치조점막 샘플이 90 개 돼지 턱 카데바에서 채취되었으며, 치조제의 형태를 모방하여 특별히 고안된 모델에 고정되었다. 치은과 치조점막 샘플의 창상변연으로부터 근위자입점까지의 거리에 따라 각각 3 개의 군으로 분류하여 (1, 3, 그리고 5mm), 전체 6 개의 군으로 분류되었으며, 각 군당 샘플은 30 개로 설정되었다. 각각의 연조직 샘플에 수직누상봉합을 수행하였고, 두 연조직 판막 사이의 창상 경계 불일치 정도와 상피의 존재 여부가 조직슬라이드 상에서 계측되었다.

창상 경계 불일치 정도는 치조점막 조직과 치은조직에서 모두 근위자입점의 위치가 창상경계로 가까워질수록 유의미하게 감소하였다. 이상적인 치유를 방해하고 문제를 야기할 수 있는 부적절한 창상변연 접합의 빈도는 창상변연으로부터 근위자입점까지의 거리가 감소할수록 치은과 치조점막 조직에서 모두 줄어들었다.

본 연구의 한계 내에서, 창상변연에 가깝게 근위자입점을 위치시키는 것은 수직누상봉합에서 창상변연의 접근 및 접합의 정확성을 향상시킨다고 결론 내릴 수 있으며, 이러한 발견은 수직누상봉합 기술에서 창상변연에 더 가까운 자입점을 사용하는 지침에 대한 과학적 근거를 제시할 수 있다.

핵심되는 말 : 누상봉합, 자입점, 임상적 프로토콜, 연조직 처치