Clinical benefits of ridge preservation for implant placement compared to natural healing in maxillary teeth: A retrospective study

Su-Hyun Park

Department of Dentistry

The Graduate School, Yonsei University

Clinical benefits of ridge preservation for implant placement compared to natural healing in maxillary teeth: A retrospective study

Directed by Professor Ui-Won Jung

The Doctoral Dissertation

submitted to the Department of Dentistry

and the Graduate School of Yonsei University

in partial fulfillment of the requirements for the degree of

Ph.D. in Dental Science

Su-Hyun Park

December 2020

This certifies that the Doctoral Dissertation
of Su-Hyun Park is approved.

Thesis Supervisor: Ui-Won Jung

Seong-Ho Choi

Jung-Seok Lee

Jae-Kook Cha

Young Woo Song

The Graduate School
Yonsei University
December 2020

감사의 글

끝날 것 같지 않았던 학위과정을 마무리하고 드디어 학위논문을 출판하게 되어서 감개무량합니다. 먼저, 학위논문이 완성되기까지 부족한 저에게 애정어린 마음으로 지도해 주시고 이끌어 주신 정의원 교수님께 큰 감사의 말씀을 드리고 싶습니다. 3년 간의 수련과정 동안 교수님의 옆에서 임상적, 학술적으로 보고 배울 수 있어서 정말 영광이었습니다.

논문작성 과정에서 항상 격려해주시고 논리적 흐름을 잡아주셨던 차재국 교수님, 의국생활이 즐거운 기억으로 남게 해주시고 본인의 논문처럼 섬세하게 피드백해주셨던 송영우 선생님께 감사의 말씀을 드립니다. 그리고 한국에서의 짧은 일정에도 제 논문의 구절 하나하나를 놓치지 않고 지도해 주셨던 Ignacio Sanz-Martín 교수님께도 감사드립니다.

치주과 전문의로서의 기본을 알려주신 채중규 교수님, 환자를 진심으로 대하는 법을 알려주시고 위트가 넘치시는 조규성 교수님, 자식처럼 하나라도 더 챙겨주시고 아껴주시는 최성호교수님, 치주치료의 근본과 중요성을 일깨워주신 김창성 교수님, 임상과 학술적인 면에서 구체적이면서도 깊이있게 가르침 주신 이중석 교수님, 항상 미소로 대해주시고 따뜻한 말씀해주신 백정원 교수님께 깊이 감사드립니다. 그리고 의국에서 동고동락하며 3년이라는 시간을 함께 보낸 동기들과 선후배님들에게도 고맙다는 말을 전하고 싶습니다.

마지막으로 가족들을 위해 헌신하고 언제나 내편인 우리 엄마, 표현은 서툴지만 항상 응원해주는 우리 아빠, 늘 걱정해주고 속이 깊은 우리 언니, 언제나 곁을 든든하게 지켜주고 지칠때마다 힘이 되어주는 우

리 남편 영주오빠와 너무나 사랑스러운 우리 아들 지한이에게 감사와 사랑의 마음을 전합니다.

2020년 12월

박 수 현

Table of Contents

List of Figures

List of Tables

Abstract

Clinical benefits of ridge preservation for implant placement compared to natural healing in maxillary teeth: A retrospective study

Su-Hyun Park, DDS;

Department of Dentistry

The Graduate School, Yonsei University

(Directed by Professor Ui-Won Jung, D.D.S., M.S.D., PhD.)

Purpose: The purpose of this retrospective study was to determine clinical benefits of ridge preservation in terms of surgical invasiveness of implant placement compared to natural healing in the maxilla.

Materials and methods: This study included 178 patients with 206 implants placed at ridge-preserved sites and 493 patients with 656 implants placed at naturally healed sites in maxillary anterior and posterior regions. Patient- and implant-related data were collected from electronic dental records including additional augmentation

procedures performed before or during implant placement and surgical complications. Cumulative survival rate was assessed using Kaplan-Meier method. The annual peri-implant marginal bone loss between the two groups was compared using the Mann-Whitney U-test.

Results: The follow-up period was 24.4±18.1 months (mean±standard deviation) for ridge-preserved sites and 45.7±29.6 months for naturally healed sites. Sinus augmentation was performed at similar frequencies in the two groups, but lateral approach was applied significantly more at naturally healed sites (37.2%) than ridge-preserved sites (8.3%, P≤0.001). There was no intergroup difference in the cumulative survival rate or annual peri-implant marginal bone loss.

Conclusions: Ridge preservation can be clinically beneficial for minimizing the invasiveness of implant surgery by simplifying the procedure when sinus augmentation is expected in the maxilla.

Key words: ridge preservation, dental implant, extraction socket, bone augmentation, sinus augmentation

Clinical benefits of ridge preservation for implant placement compared to natural healing in maxillary teeth: A retrospective study

Su-Hyun Park, DDS;

Department of Dentistry

The Graduate School, Yonsei University

(Directed by Professor Ui-Won Jung, D.D.S., M.S.D., PhD.)

I. Introduction

Tooth extraction leads to changes in both vertical and horizontal dimensions of the alveolar bone, more pronounced in the buccal aspect (M. G. Araujo & Lindhe, 2005; Farmer & Darby, 2014). These resorptions make subsequent prosthetically-driven implant placement difficult and frequently leads to the necessity for augmentation procedures, which may increase the complexity of surgical procedures performed by

clinicians and worsen clinical experiences for patients (Milinkovic & Cordaro, 2014). Ridge preservation (RP) has therefore been suggested for maintaining the alveolar ridge volume after tooth extraction (Hammerle, Araujo, Simion, & Osteology Consensus, 2012). Previous clinical studies have demonstrated the superiority of RP in minimizing dimensional changes of the alveolar ridge compared to natural healing after tooth extraction (Cardaropoli, Tamagnone, Roffredo, Gaveglio, & Cardaropoli, 2012; Jung, Sapata, et al., 2018). The volume maintenance achieved by RP can reduce the need for additional augmentation procedures during implant surgery, thereby, minimizing the invasiveness and reducing the possible incidence of complications (Barone, Ricci, Tonelli, Santini, & Covani, 2013; Mardas, Trullenque-Eriksson, MacBeth, Petrie, & Donos, 2015). Particularly in the posterior maxilla, RP may reduce sinus pneumatization as well as minimize crestal bone resorption and therefore reduce the need of performing sinus augmentation (Cha et al., 2019; Rasperini, Canullo, Dellavia, Pellegrini, & Simion, 2010). Similarly, RP in the anterior maxilla may allow implant placement with improved soft and hard tissue conditions and a minimal risk of aesthetic complications (Jung, Ioannidis, Hammerle, & Thoma, 2018; A. M. H. Lee & Poon, 2017).

Several studies have compared implant-related outcomes such as marginal bone loss (MBL) and survival rate between ridge-preserved and naturally healed sites (Apostolopoulos & Darby, 2017; Barone et al., 2012; Marconcini et al., 2018), but their outcomes were not consistent. A randomized clinical trial of Marconcini et al. (2018) found that the survival and success rates of implants placed in either ridge-preserved or

nongrafted sites were 100% after 4 years of functional loading, while the mean MBL was significantly greater at the nongrafted sites. Conversely, Barone et al. (2012) found that the survival rates of implants at the two sites were both around 95%, and that there were no significant intergroup differences in the peri-implant marginal bone levels during the 3-year study period. The recent retrospective study of Apostolopoulos & Darby (2017) found that the mean peri-implant MBL was lower at ridge-preserved sites than at naturally healed sites after up to 3 years of functional loading, but greater from that time up to 7 years or longer.

Given the heterogeneity of the available data and lack of studies with large patient samples, the advantages of RP in the maxilla over spontaneous healing remain unclear. The aim of this retrospective study was therefore to determine whether RP provides clinical benefits compared to naturally healed sites in the maxilla by assessing the need for additional surgical procedures at the time of implant placement, survival rate, and peri-implant MBL.

II. Materials & Methods

1. Study design and population

This retrospective cohort study included patients who received dental implants after tooth extraction in the posterior and anterior maxilla at the Department of Periodontology, Yonsei University Dental Hospital from 2009 to 2018 and analyzed electronic dental records in the clinical database research system. The included patients were categorized into two groups: (1) those who received RP at the time of extraction (RP group) and (2) those with spontaneous healing after extraction (control group). The follow-up duration, defined as the period from implant placement to the most-recent visit or implant failure, was 24.4±18.1 months (mean±standard deviation, SD; ranging from 1.5 to 102.6 months) in the RP group and 56.4±12.9 months (mean±SD; ranging from 0.6 to 112.8 months) in the control group. Ethical approval was obtained from the Institutional Review Board at Yonsei University Dental Hospital (Approval No. 2-2019-0005). The study was conducted in accordance with the STROBE checklist.

2. Inclusion and exclusion criteria

Patients who underwent extraction and the subsequent placement of single or multiple implants in the maxilla were screened using the relevant treatment codes in the clinical database research system. All the implants placed according to early or late implant placement protocol, except for immediate implant placement protocol, were included

(Hammerle, Chen, & Wilson, 2004). Through chart reviews, patients with incomplete final restoration, immediately loaded implants, or insufficient records regarding patient- and surgery-related data were excluded. We also excluded the cases with sufficient vertical bone height that are not expected to require maxillary sinus augmentation for implantation in pre-extraction panoramic radiographs with following criteria: the distance between the root apex and the maxillary sinus floor is >2 mm and the distance from the crest to the maxillary sinus floor is >10 mm.

3. Data collection

The electronic dental records of the patients included were reviewed by a single examiner (S.H.P.), and the following data were obtained:

1) Patient information: age, sex, and general health status (i.e., presence of cardiovascular disease, diabetes mellitus, or osteoporosis).
2) Extraction details: time of extraction, location (according to FDI tooth number), and reason for extraction (periodontal, endodontic, fracture, caries, or unknown).
3) RP details: types of bone-graft materials and barrier membranes.
4) Implant surgery details: time of implant placement, additional augmentation procedures performed prior to or simultaneously with implant placement, implant manufacturer, implant diameter and length, and insertion torque.
5) Prostheses details: time at which prosthesis placement was completed.
6) Complications after each surgical intervention (i.e., wound dehiscence, pain and

swelling, hemorrhage, infection, and sinus membrane perforation).

4. Outcome measurements

4.1 Additional augmentation procedures

Additional vertical and horizontal augmentation procedures performed either prior to or at the time of implant surgery were identified in electronic dental records and radiographs. The types of additional augmentation procedures were as follows:

1) Sinus augmentation via a lateral approach: two-stage and one-stage techniques.
2) Sinus augmentation via a crestal approach: osteotome sinus-floor elevation (OSFE) and bone-added osteotome sinus-floor elevation (BAOSFE) (Summers, 1994; Tan, Lang, Zwahlen, & Pjetursson, 2008)
3) Staged horizontal or vertical ridge augmentation: guided bone regeneration (GBR) and bone grafting.
4) Simultaneous horizontal or vertical ridge augmentation at the time of implant placement: GBR, bone grafting, and ridge splitting or expansion.

4.2 Implant survival

Implant survival was defined as the implant being present with no indication for its removal at the most-recent follow-up visit (Pabst et al., 2015). Implant failure was defined as the absence of the implant in the oral cavity for any reason. Implant failure and survival were assessed using the most-recent radiographs.

4.3 Peri-implant marginal bone loss

The marginal bone levels around the implant were assessed based on periapical radiographs obtained immediately after implant placement and at the most-recent follow-up visit using image-processing software (ZeTTA PACS, Taeyoung Soft, Seoul, Korea) (J. S. Lee et al., 2013). The analyzed periapical radiographs were taken by extension cone paralleling technique using digital sensor positioning devices (Dentsply Rinn, Elgin, IL, USA). After calibration using the known fixture length, one experienced examiner (S.H.P.) measured the marginal bone level. The reference line was set at the top of the implant fixture for bone-level implants and the border between the polished surface and rough surface for tissue-level implants. The marginal bone levels were measured from the reference line to the most-coronal bone-to-implant contact point on the mesial and distal sides of the implants (Kang, Jung, Cho, & Lee, 2018).

5. Statistical analysis

All data were statistically analysed using SPSS (version 23, IBM Corporation, Armonk, NY, USA). Mean, SD, and percentage values were presented as descriptive statistics. Pearson's chi-square test and Fisher's exact test were used to test relationships between categorical variables. After the normality test, the Mann-Whitney U-test was used for comparison of the annual MBL. Cumulative survival rates (CSR) were assessed using the Kaplan-Meier method in implant- and patient-based analyses, and intergroup differences in survival curves were tested using the Log-rank test. The criterion for statistical

significance was $P<0.05$.

III. Results

1. Patient demographics

The RP group involved 206 implants in 178 patients (87 males and 91 females) aged 53.0±14.6 years (ranging from 19 to 86 years) at the time of extraction. The control group involved 656 implants in 493 patients (253 males and 240 females) aged 56.4±12.9 years (ranging from 18 to 82 years) (Table 1). The distribution for the number of extracted teeth and implants placed at patient level in both groups is as follows: (1) Single extraction and single implant: 146 in the RP group and 336 in the control group (2) Multiple extractions and multiple implants in contiguous area: 12 versus 59 (3) Multiple extractions and multiple implants in non-contiguous area: 13 versus 57 (4) Multiple extractions in contiguous area and single implant: 7 versus 41. The diameter and length of the implants according to location are presented in Figure 1. The number of implants placed in the anterior region was 102 in the RP group and 215 in the control group. Implants with diameters from 3.75 to 4.5 mm were the most common accounting for 65.7% in the RP group and 63.3% in the control group, respectively, followed by those with diameters smaller than 3.75 mm (34.3% versus 35.8%). Most of the implants in the RP group had a length of 8.0–10.0 mm (80.4%), while the control group included similar proportions between the implants with lengths of 8.0–10.0 mm (49.8%) and >10.0 mm (50.2%). There were 104 and 441 implants placed in the posterior region in the RP and control groups, respectively. Wide implants with diameters >4.5 mm were the most common in both groups,

with more of them in the RP group (74.0% versus 66.4%). Most implants had lengths of 8.0–10.0 mm in both groups (96.2% versus 88.4%), with more implants exceeding 10.0 mm in the control group (1.9% versus 10.0%).

2. Additional augmentation procedures

The proportions of cases where additional augmentation procedures were performed for implant placement differed significantly between the ridge-preserved and naturally healed sites (69.4% versus 79.7%, P=0.002; Table 2). Sinus augmentation was performed in 69.2% of the patients in the RP group and 68.3% of those in the control group. Regarding the cases where sinus augmentation was performed, lateral approach was performed more frequently in the control than in the RP group. The lateral approach was performed in 37.2% and the crestal approach was performed in 62.8% in the control group while, on the contrary, 8.3% and 91.7% in the RP group, respectively (P<0.001, Table 3). In the anterior region, additional augmentation procedures were performed more significantly at naturally healed sites (P=0.016, Table 3). Among the implants with additional augmentation, staged GBR was performed slightly more in the control group, but there was no statistically significant difference between the two groups (P=0.289).

3. Implant survival

3.1 Cumulative survival rates

The CSR found in the RP group at the implant and patient levels were 96.1% and 95.5%,

respectively, and 93.4% and 92.3% in the control group (Fig. 2). The log-rank test showed that there were no significant differences in the survival between the two groups (P=0.684 for implant level and P=0.715 for patient level).

3.2 Implant loss pattern

Detailed information about failed implants in the RP group is presented in Table 4. All the failed implants were placed in the posterior region. Two implants were placed without any additional augmentation and other 5 implants were accompanied by sinus augmentation. Five implants were removed before loading, all due to osseointegration failure. The remaining two implants were removed after loading that lasted less than 1 year as a result of abrupt disintegration without any peri-implant MBL.

Table 5 presents details on failed implants in the control group. All 5 implants placed in the anterior region were accompanied by GBR. Of the 19 implants placed in the posterior region, 15 implants were placed with sinus augmentation, 3 implants with GBR and 1 implant without any augmentation. Among the implants that failed before loading, eight were removed due to infection, five due to osseointegration failure, and two due to the loss of bone-graft material. Among the implants that failed after loading, five were removed due to peri-implantitis and three were removed due to abrupt disintegration after less than 1 year of loading.

4. Peri-implant marginal bone loss

The peri-implant marginal bone levels were measured in 177 implants in the RP group and 589 implants in the control group both at implant placement and the most-recent follow-up visit. Since all the median values of annual MBL in both groups were 0, the mean values were presented (Table 6). In the anterior region, the mean annual MBL was 0.16±0.41 mm in the RP group and 0.11±0.34 mm in the control group (P=0.16). In the posterior region, 0.04±0.19 mm and 0.05±0.26 mm, respectively (P=0.57). The annual MBL did not differ significantly in both anterior and posterior regions between the ridge-preserved and naturally healed sites.

5. Surgical complications

Twenty-three of 206 implants in the RP group experienced surgical complications: nine after RP, one after staged augmentation procedure, and 13 after implant placement. After RP, pain and swelling was the most common complication (n=5). After implant placement, wound dehiscence was the most common (n=7), followed by sinus membrane perforation (n=2). Of all 656 implants in the control group, 76 experienced surgical complications: one after extraction, 21 after staged augmentation procedure, and 54 after implant placement. The most common complication after staged augmentation procedure was sinus membrane perforation (n=10), followed by wound dehiscence (n=6). Post-implant placement complications were in the order of wound dehiscence (n=21), infection (n=11), and sinus membrane perforation (n=10).

IV. Discussion

This retrospective study investigated the clinical benefits of RP compared with natural healing in terms of the need for additional surgical procedures, the implant survival rate, and the peri-implant MBL. Additional augmentation was performed significantly less frequently in the RP group than in the control group (69.4% versus 79.7%, P=0.002). Although sinus augmentation procedures were performed in the two groups with a comparable proportion, a proportion of lateral approaches performed was significantly lower at ridge-preserved sites than at naturally healed sites ($P \leq 0.001$). The CSR and MBL did not differ significantly between the groups.

RP has been shown to be effective in reducing the need for additional augmentation during implant placement. Barone et al. (2012) reported that three of 20 implants in the grafted group required additional bone augmentation during implant placement, while this was required in 10 of 20 implants in the control group. A previous systematic review found that the rate of further augmentation performed was 15% lower for RP than for spontaneous healing (Mardas et al., 2015). The results in the present study are consistent with these studies. Especially in the posterior region, sinus augmentation was performed at similar frequencies in the two groups, whereas crestal approach was performed more frequently than lateral approach at the ridge-preserved sites, suggesting that RP was associated with less invasive sinus augmentation procedures. Although lateral approach for sinus augmentation is an effective treatment option that is associated with high implant survival

and success rates, it has a high risk of complications such as perforation of sinus membrane and excessive pain or swelling (Stacchi et al., 2017; Thoma, Zeltner, Hüsler, Hämmerle, & Jung, 2015). In the present study, complications related to sinus augmentation occurred in 26 of the 118 implants with lateral approach, whereas in 16 of the 255 implants with crestal approach. The most common complication of lateral approach was sinus membrane perforation (n=11) followed by pain and swelling (n=5).

In the anterior region, the proportion of horizontal or vertical augmentation procedures was lower at ridge-preserved sites than at naturally healed sites (62.7% versus 75.8%, P=0.016). It has been demonstrated that the GBR procedure performed either prior to or simultaneously with implant placement is a predictable technique for horizontal or vertical augmentation in the atrophic alveolar ridge (Jepsen et al., 2019; Naenni, Lim, Papageorgiou, & Hammerle, 2019; Urban, Montero, Monje, & Sanz-Sanchez, 2019; Wessing, Lettner, & Zechner, 2018). However, extensive GBR procedures which frequently require flap mobilization further increase discomfort and surgical morbidity of patients. It was reported that patients who were treated with dental implants simultaneously with GBR experienced more postoperative swelling and bruising than those who underwent only implant placement (Yao et al., 2017). Another study found that simultaneous bone augmentation was associated with a higher degree of facial swelling and negative impacts on the oral-health-related quality of life after implant surgery (Kamankatgan, Pimkhaokham, & Krisdapong, 2017). Therefore, it may be suggested that invasiveness of surgery could be minimized as a result of RP procedure, simplifying an implant surgery in the anterior

maxilla.

In the present study, the cases of immediate implant placement that requires an intact buccal bone and possibly entails complications associated with this intervention were excluded from the study. In this study, early implant placements were performed at 149 cases in the control group, of which 80% had additional augmentation prior to or at the time of implant placement. Despite early implant placement has an advantage of short healing period, regeneration procedure, in most cases, is accompanied with implant placement (Graziani et al., 2019).

On the other hand, RP requires 3-4 months of healing period before implant placement, which can lead to a prolonged total duration of treatment (M. Araujo, Linder, Wennstrom, & Lindhe, 2008; Avila-Ortiz, Chambrone, & Vignoletti, 2019). However, a recent systematic review concluded that a long healing period of over 3-4 months after RP might be unnecessary since there was no significant difference between RP and spontaneous healing in the histological data (De Risi, Clementini, Vittorini, Mannocci, & De Sanctis, 2015). Moreover, a recent in-vivo study found that early implantation after RP demonstrated comparable histomorphometric outcomes to those obtained from spontaneous healing (Thoma et al., 2017). In our study, most of the implants in the RP group were placed after 16 weeks, while 18 implants (15 in the anterior region and three in the posterior region) were placed before 12 weeks. Half of these 18 implants were placed without any additional augmentation, and the other half were accompanied by minor bone augmentation simultaneously with implant placement: all these implants functioned

successfully during the 34.6±18.1-month follow-up. On the other hand, additional augmentation was performed in 60% of the 22 implants placed after 12-16 weeks and in 75% of the 161 implants placed after over 16 weeks. Although evidence for the clinical success of early implantation after RP is still lacking, our results might suggest a potential of its clinical application.

This study found no statistically significant difference in the 8-year CSR between the implants placed in ridge-preserved and naturally healed sites. This is consistent with the results of previous retrospective studies comparing RP and natural healing for implant-related outcomes (Apostolopoulos & Darby, 2017; Wu et al., 2019). In this study, the CSR of implants in the RP group was 96.1% at the implant level and 95.5% at the patient level, which are slightly lower than the proportions found in other retrospective studies. These results may be attributable to the inclusion criteria of this study limited to the maxilla, and a larger number of samples compared to the previous studies.

In the present study, there was no significant difference in peri-implant MBL between the two groups, which in agreement with other previous studies. Barone et al. (2012) observed peri-implant MBL of 1.00±0.20 mm and 1.02±0.30 mm in grafted and nongrafted extraction sockets at 3 years after loading, respectively. A recent retrospective study found that the MBL at the ridge preserved sites was 0.09±0.34mm and 0.06±0.51 mm at naturally healed sites (Wu et al., 2019). However, since the standardization of radiograph was limited in that several clinicians took the periapical radiographs, the present findings should be interpreted with caution. Furthermore, the fact that the baseline periapical radiographs at

the time of implant placement, not at the time of final restoration, was taken into account for radiographic analysis also remains a limitation.

There was a substantial difference in the number of patients and follow-up duration between the two groups, 24.4±18.1 months in 178 patients in the RP group and 45.7±29.6 months in 493 patients in the control group, which could lead to biased comparison. Another limitation of this study is that its findings are based on the dental records and radiographs of the patients, rather than the clinical parameters measured. This also relates to the fact that the success rate of implants and the prevalence of peri-implant mucositis or peri-implantitis—which can be diagnosed by clinical features—could not be retrieved. Moreover, the possibility of subjective assessments made by the surgeons associated with the selection of additional augmentation procedures cannot be excluded. Patient-reported outcome measures and treatment costs should also be analysed to determine the benefits of RP from a patient's standpoint. Further prospective randomized controlled trials with longer follow-ups are needed to strengthen an evidence for determining the clinical effects of RP in relation to implant treatment.

V. Conclusion

Within the limitations of this retrospective study, it can be concluded that RP minimizes the invasiveness of implant surgery by simplifying the procedure when sinus augmentation is expected in the maxilla.

References

Apostolopoulos, P., & Darby, I. (2017). Retrospective success and survival rates of dental implants placed after a ridge preservation procedure. Clinical Oral Implants Research, 28(4), 461-468.

Araujo, M., Linder, E., Wennstrom, J., & Lindhe, J. (2008). The influence of Bio-Oss Collagen on healing of an extraction socket: an experimental study in the dog. International Journal of Periodontics & Restorative Dentistry, 28(2), 123-135.

Araujo, M. G., & Lindhe, J. (2005). Dimensional ridge alterations following tooth extraction. An experimental study in the dog. Journal of Clinical Periodontology, 32(2), 212-218.

Avila-Ortiz, G., Chambrone, L., & Vignoletti, F. (2019). Effect of alveolar ridge preservation interventions following tooth extraction: A systematic review and meta-analysis. Journal of Clinical Periodontology, 46 Suppl 21, 195-223.

Barone, A., Orlando, B., Cingano, L., Marconcini, S., Derchi, G., & Covani, U. (2012). A randomized clinical trial to evaluate and compare implants placed in augmented versus non-augmented extraction sockets: 3-year results. Journal of Periodontology, 83(7), 836-846.

Barone, A., Ricci, M., Tonelli, P., Santini, S., & Covani, U. (2013). Tissue changes of extraction sockets in humans: a comparison of spontaneous healing vs. ridge preservation with secondary soft tissue healing. Clinical Oral Implants Research, 24(11), 1231-1237.

Cardaropoli, D., Tamagnone, L., Roffredo, A., Gaveglio, L., & Cardaropoli, G. (2012). Socket preservation using bovine bone mineral and collagen membrane: a randomized controlled clinical trial with histologic analysis. International Journal of Periodontics & Restorative Dentistry, 32(4), 421-430.

Cha, J. K., Song, Y. W., Park, S. H., Jung, R. E., Jung, U. W., & Thoma, D. S. (2019). Alveolar ridge preservation in the posterior maxilla reduces vertical dimensional change: A randomized controlled clinical trial. Clinical Oral Implants Research, 30(6), 515-523.

De Risi, V., Clementini, M., Vittorini, G., Mannocci, A., & De Sanctis, M. (2015). Alveolar ridge preservation techniques: a systematic review and meta-analysis of histological and histomorphometrical data. Clinical Oral Implants Research, 26(1), 50-68.

Farmer, M., & Darby, I. (2014). Ridge dimensional changes following single-tooth extraction in the aesthetic zone. Clinical Oral Implants Research, 25(2), 272-277.

Graziani, F., Chappuis, V., Molina, A., Lazarin, R., Schmid, E., Chen, S., & Salvi, G. E. (2019). Effectiveness and clinical performance of early implant placement for the replacement of single teeth in anterior areas: A systematic review. Journal of Clinical Periodontology, 46 Suppl 21, 242-256.

Hammerle, C. H., Araujo, M. G., Simion, M., & Osteology Consensus, G. (2012). Evidence-based knowledge on the biology and treatment of extraction sockets. Clinical Oral Implants Research, 23 Suppl 5, 80-82.

Hammerle, C. H., Chen, S. T., & Wilson, T. G., Jr. (2004). Consensus statements and recommended clinical procedures regarding the placement of implants in extraction sockets. International Journal of Oral & Maxillofacial Implants, 19 Suppl, 26-28.

Jepsen, S., Schwarz, F., Cordaro, L., Derks, J., Hammerle, C. H. F., Heitz-Mayfield, L. J., Urban, I. (2019). Regeneration of alveolar ridge defects. Consensus report of group 4 of the 15th European Workshop on Periodontology on Bone Regeneration. Journal of Clinical Periodontology, 46 Suppl 21, 277-286.

Jung, R. E., Ioannidis, A., Hammerle, C. H. F., & Thoma, D. S. (2018). Alveolar ridge preservation in the esthetic zone. Periodontology 2000, 77(1), 165-175.

Jung, R. E., Sapata, V. M., Hammerle, C. H. F., Wu, H., Hu, X. L., & Lin, Y. (2018). Combined use of xenogeneic bone substitute material covered with a native bilayer collagen membrane for alveolar ridge preservation: A randomized controlled clinical trial. Clinical Oral Implants Research, 29(5), 522-529.

Kamankatgan, S., Pimkhaokham, A., & Krisdapong, S. (2017). Patient-based outcomes following surgical implant placements. Clinical Oral Implants Research, 28(1), 17-23.

Kang, M. H., Jung, U. W., Cho, K. S., & Lee, J. S. (2018). Retrospective radiographic observational study of 1692 Straumann tissue-level dental implants over 10 years. II. Marginal bone stability. Clinical Implant Dentistry and Related Research, 20(5), 875-881.

Lee, A. M. H., & Poon, C. Y. (2017). The Clinical Effectiveness of Alveolar Ridge Preservation in the Maxillary Anterior Esthetic Zone-A Retrospective Study. Journal of Esthetic and Restorative Dentistry, 29(2), 137-145.

Lee, J. S., Kim, H. M., Kim, C. S., Choi, S. H., Chai, J. K., & Jung, U. W. (2013). Long-term retrospective study of narrow implants for fixed dental prostheses. Clinical Oral Implants Research, 24(8), 847-852.

Marconcini, S., Giammarinaro, E., Derchi, G., Alfonsi, F., Covani, U., & Barone, A. (2018). Clinical outcomes of implants placed in ridge-preserved versus nonpreserved sites: A 4-year randomized clinical trial. Clinical Implant Dentistry and Related Research, 20(6), 906-914.

Mardas, N., Trullenque-Eriksson, A., MacBeth, N., Petrie, A., & Donos, N. (2015). Does ridge preservation following tooth extraction improve implant treatment outcomes: a systematic review: Group 4: Therapeutic concepts & methods. Clinical Oral Implants Research, 26 Suppl 11, 180-201.

Milinkovic, I., & Cordaro, L. (2014). Are there specific indications for the different alveolar bone augmentation procedures for implant placement? A systematic review. International Journal of Oral and Maxillofacial Surgery, 43(5), 606-625.

Naenni, N., Lim, H. C., Papageorgiou, S. N., & Hammerle, C. H. F. (2019). Efficacy of lateral bone augmentation prior to implant placement: A systematic review and meta-analysis. Journal of Clinical Periodontology, 46 Suppl 21, 287-306.

Pabst, A. M., Walter, C., Ehbauer, S., Zwiener, I., Ziebart, T., Al-Nawas, B., & Klein, M. O. (2015). Analysis of implant-failure predictors in the posterior maxilla: a retrospective study of 1395 implants. Journal of Cranio-Maxillo-Facial Surgery, 43(3), 414-420.

Rasperini, G., Canullo, L., Dellavia, C., Pellegrini, G., & Simion, M. (2010). Socket grafting in the posterior maxilla reduces the need for sinus augmentation. International Journal of Periodontics & Restorative Dentistry, 30(3), 265-273.

Stacchi, C., Andolsek, F., Berton, F., Perinetti, G., Navarra, C. O., & Di Lenarda, R. (2017). Intraoperative Complications During Sinus Floor Elevation with Lateral Approach: A Systematic Review. International Journal of Oral & Maxillofacial Implants, 32(3), e107-e118.

Summers, R. B. (1994). The osteotome technique: Part 3--Less invasive methods of elevating the sinus floor. Compendium (Newtown, Pa.), 15(6), 698, 700, 702-694 passim; quiz 710.

Tan, W. C., Lang, N. P., Zwahlen, M., & Pjetursson, B. E. (2008). A systematic review of the success of sinus floor elevation and survival of implants inserted in combination with sinus floor elevation. Part II: transalveolar technique. Journal of Clinical Periodontology, 35(8 Suppl), 241-254.

Thoma, D. S., Naenni, N., Benic, G. I., Munoz, F., Hammerle, C. H. F., & Jung, R. E. (2017). Effect of ridge preservation for early implant placement - is there a need to remove the biomaterial? Journal of Clinical Periodontology, 44(5), 556-565.

Thoma, D. S., Zeltner, M., Hüsler, J., Hämmerle, C. H. F., & Jung, R. E. (2015). EAO Supplement Working Group 4 - EAO CC 2015 Short implants versus sinus lifting with longer implants to restore the posterior maxilla: a systematic review. Clinical Oral Implants Research, 26, 154-169.

Urban, I. A., Montero, E., Monje, A., & Sanz-Sanchez, I. (2019). Effectiveness of vertical ridge augmentation interventions: A systematic review and meta-analysis. Journal of Clinical Periodontology, 46 Suppl 21, 319-339.

Wessing, B., Lettner, S., & Zechner, W. (2018). Guided Bone Regeneration with Collagen Membranes and Particulate Graft Materials: A Systematic Review and Meta-Analysis. International Journal of Oral & Maxillofacial Implants, 33(1), 87-100.

Wu, I. H., Bakhshalian, N., Galaustian, R., Naini, R. B., Min, S., Freire, M., & Zadeh, H. H. (2019). Retrospective Analysis of the Outcome of Ridge Preservation with Anorganic Bovine Bone Mineral: Marginal Bone Level at Implants Placed Following Healing of Grafted Extraction Sockets. International Journal of Periodontics & Restorative Dentistry, 39(1), 131-140.

Yao, J., Lee, K. K., McGrath, C., Wu, Y. N., Li, K. Y., & Mattheos, N. (2017). Comparison of patient-centered outcomes after routine implant placement, teeth extraction, and periodontal surgical procedures. Clinical Oral Implants Research, 28(4), 373-380.

Figure legends

Figure 1. Distribution of diameter and length of implants according to the position. (a) anterior region (b) posterior region.

Figure 2. Cumulative survival rates of implants placed at ridge preserved and naturally healed sites. (a) implant-level (b) patient-level.

Tables

Table 1. Demographic data of subjects and implants

	Ridge preservation	Natural healing
Number of patients (n)	178	493
Gender		
Male (n [%])	87 (48.9)	253 (51.3)
Female (n [%])	91 (51.1)	240 (48.7)
Age (mean ± SD, years)	53.0 ± 14.6 (range 19-86)	56.4 ± 12.9 (range 18-82)
Follow-up time (mean ± SD, months)	24.4 ± 18.1	45.7 ± 29.6
Number of implants (n)	206	656
Anterior (n [%])	102 (49.5)	215 (32.8)
Single extraction (n [%])	82 (80.4)	161 (74.9)
Multiple extraction† (n [%])	20 (19.6)	54 (25.1)
Posterior (n [%])	104 (50.5)	441 (67.2)
Single extraction (n [%])	82 (78.8)	324 (73.5)
Multiple extraction† (n [%])	22 (21.2)	117 (26.5)

† Included extraction of two or more teeth in contiguous area

Table 2. Comparison of additional augmentation performed, n (%)

	Ridge preservation	Natural healing	*P* value
Simple	63 (30.6)	133 (20.3)	0.002*
Additional augmentation†	143 (69.4)	523 (79.7)	

P value was calculated using the Pearson's chi-square test

† Included sinus augmentation (staged lateral approach, simultaneous lateral/crestal approach) and horizontal or vertical bone augmentation (staged GBR, simultaneous bone graft, GBR, and ridge splitting/expansion).

Table 3. Comparison of additional augmentation procedures according to location, n (%)

		Ridge preservation	Natural healing	*P* value
Anterior				
	None	38 (37.3)	52 (24.2)	0.016*
	Horizontal or vertical augmentation	64 (62.7)	163 (75.8)	
	Staged GBR	1 (1.6)	9 (5.5)	0.289
	Simultaneous augmentation†	63 (98.4)	154 (94.5)	
Posterior				
	None	32 (30.8)	140 (31.7)	0.847
	Sinus augmentation	72 (69.2)	301 (68.3)	
	Lateral approach	6 (8.3)	112 (37.2)	0.001*
	Crestal approach	66 (91.7)	189 (62.8)	

P value was calculated using the Pearson's chi-square test and Fisher's exact test

† Included bone graft, GBR and ridge splitting/expansion.

* Statistically significant ($P<0.05$)

Table 4. Case list of failed implants in the RP group (GBR, guided bone regeneration; OSFE, osteotome sinus floor elevation; BAOSFE, bone-added osteotome sinus floor elevation HTN, hypertension; DM, diabetes mellitus N-S, nonspecific; NA, not available)

Patient No.	Patient characteristics			Ridge preservation					Implant characteristics		
	Age (years)	Sex	Systemic disease	Tooth No.	Extraction reason	Extraction span	Bone material	Membrane	System	Diameter (mm)	Length (mm)
1	70	M	HTN, DM	27	Perio	Single	Synthetic graft	Collagen plug	Straumann (Tissue level)	4.8	6
2	74	F	N-S	16	Perio	Multiple (2 teeth)	Synthetic graft	Collagen plug	Straumann (Tissue level)	4.8	10
3	41	F	N-S	17	Perio	Single	Xenograft + Synthetic graft	Collagen plug	Straumann (Tissue level)	4.8	8
4	52	M	N-S	14	Perio	Single	Xenograft	Collagen plug	Dentium	4.5	10
5	75	F	N-S	14	Crack	Single	Xenograft	Collagen plug	Dentium	3.8	10
6	39	M	N-S	14	Perio	Single	Xenograft	Cross-linked collagen membrane	Dentium	4	10
7	65	F	HTN, Osteoporosis	16	Perio	Single	Xenograft	Native collagen membrane	Straumann (Bone level)	4.8	8

Surgery		Implant loss			
Time of implant placement (days)	Additional augmentation	Insertion torque (Ncm)	Function period (days)	Duration before implant failure (days)	Failure reason
Type 4 (165)	OSFE	30	252	454	Unknown
Type 4 (172)	BAOSFE	50	NA	113	Osseointegration failure
Type 4 (164)	N-S	20	111	298	Unknown
Type 4 (259)	Staged GBR	20	NA	71	Osseointegration failure
Type 4 (215)	Staged sinus augmentation + Bone graft	40	NA	78	Osseointegration failure
Type 3 (105)	N-S	50	NA	46	Osseointegration failure
Type 3 (99)	OSFE	20	NA	180	Osseointegration failure

Table 5. Case list of failed implants in the control group (GBR, guided bone regeneration; OSFE, osteotome sinus floor elevation; BAOSFE, bone-added osteotome sinus floor elevation HTN, hypertension; DM, diabetes mellitus N-S, nonspecific; NA, not available)

Patient No.	Patient characteristics			Extraction			Implant characteristics		
	Age (years)	Sex	Systemic disease	Tooth No.	Extraction reason	Extraction span	System	Diameter (mm)	Length (mm)
1	65	F	Osteoporosis	16	Perio	Multiple (3 teeth)	Straumann (Tissue level)	4.8	10
2	70	F	HTN	26	Endo	Single	Dentium	4.3	8
3	53	F	DM	26	Perio	Single	Osstem	5	10
4	47	F	HTN	17	Perio	Single	Dentium	4.8	8
5	49	M	DM	16	Perio	Single	Astra	5.0	9.0
6	24	F	N-S	27	Fracture	Single	Osstem	5	10
7	63	M	HTN, DM	25	Perio	Multiple (3 teeth)	Dentium	3.8	10
				26	Perio	Multiple (3 teeth)	Dentium	3.8	10
8	63	F	HTN, DM	16	Perio	Single	Shinhung	5	8.5
9	68	M	HTN	17	Perio	Single	Straumann (Bone level)	4.8	8
10	51	M	HTN, DM	27	Perio	Single	Nobel Biocare	5	10
11	64	F	DM	21	Perio	Multiple (3 teeth)	Dentium	3.8	12
				23	Perio	Multiple (3 teeth)	Dentium	4.3	10
12	51	F	N-S	12	Endo	Single	Straumann (Bone level)	3.3	12
	53	M	HTN	11	Fracture	Single	Straumann (Bone level)	4.1	10
13	59	F	Osteoporosis	26	Caries	Single	Implantium	4.8	10
14	63	F	N-S	16	Perio	Multiple (2 teeth)	Shinheung	5	11.5
15	38	M	Unknown	16	Endo	Single	Dentium	4.8	10
16	52	M	HTN	26	Perio	Single	Osstem	4.8	8
17	60	M	HTN	15	Perio	Single	Dentium	3.8	10
18	58	F	N-S	12	Perio	Single	Osstem	4	10
19	49	M	N-S	14	Perio	Single	Osstem	4	10
				16	Perio	Single	Osstem	5	10
20	25	M	N-S	15	Caries	Single	Astra	4.5	11

Surgery		Implant loss			
Time of implant placement (days)	Additional augmentation	Insertion torque (Ncm)	Function period (days)	Duration before implant failure (days)	Failure reason
Type 4 (216)	Sinus augmentation (lateral)	20	NA	405	Osseointegration failure
Type 4 (360)	Staged sinus augmentation	40	129	1940	Peri-implantitis
Type 4 (1490)	OSFE	20	NA	20	Infection
Type 4 (652)	BAOSFE	20	120	392	Unknown
Type 4 (474)	GBR	50	754	940	Unknown
Type 2 (81)	OSFE	50	NA	28	Osseointegration failure
Type 4 (305)	Staged sinus augmentation	40	NA	123	Infection
Type 4 (305)	Staged sinus augmentation	30	NA	123	Infection
Type 2 (49)	BAOSFE	40	171	432	Unknown
Type 3 (110)	GBR	<20	199	415	Unknown
Type 4 (116)	Sinus augmentation (lateral)	Unknown	582	2602	Peri-implantitis
Type 2 (60)	GBR	40	NA	97	Infection
Type 2 (60)	GBR	40	NA	97	Infection
Type 3 (100)	GBR	30	NA	135	Osseointegration failure
Type 2 (67)	GBR	40	NA	57	GBR failure
Type 3 (89)	N-S	40	NA	81	Infection
Type 4 (150)	OSFE	50	NA	21	Osseointegration failure
Type 4 (217)	Sinus augmentation (lateral)	50	NA	1307	GBR failure
Type 4 (142)	BAOSFE + Bone graft	40	144	1994	Peri-implantitis
Type 2 (64)	BAOSFE + GBR	40	NA	67	Infection
Type 3 (92)	GBR	40	NA	41	Infection
Type 4 (330)	Staged GBR + GBR	30	395	1961	Peri-implantitis
Type 4 (330)	Staged sinus augmentation	40	395	1961	Peri-implantitis
Type 4 (337)	BAOSFE	3	NA	17	Osseointegration failure

Table 6. Annual radiographic peri-implant marginal bone losses in ridge preserved and naturally healed sites according to location, (mean±SD, mm)

		Ridge preservation	Natural healing	*P* value
Anterior		(n=89)	(n=185)	
	Mesial	0.22 ± 0.55	0.13 ± 0.54	0.060
	Distal	0.10 ± 0.35	0.08 ± 0.21	0.482
	Mean	0.16 ± 0.41	0.11 ± 0.34	0.155
Posterior		(n=88)	(n=404)	
	Mesial	0.04 ± 0.18	0.03 ± 0.37	0.497
	Distal	0.03 ± 0.27	0.06 ± 0.23	0.130
	Mean	0.04 ± 0.19	0.05 ± 0.26	0.572

P value was calculated using the Mann-Whitney *U*-test

Figures

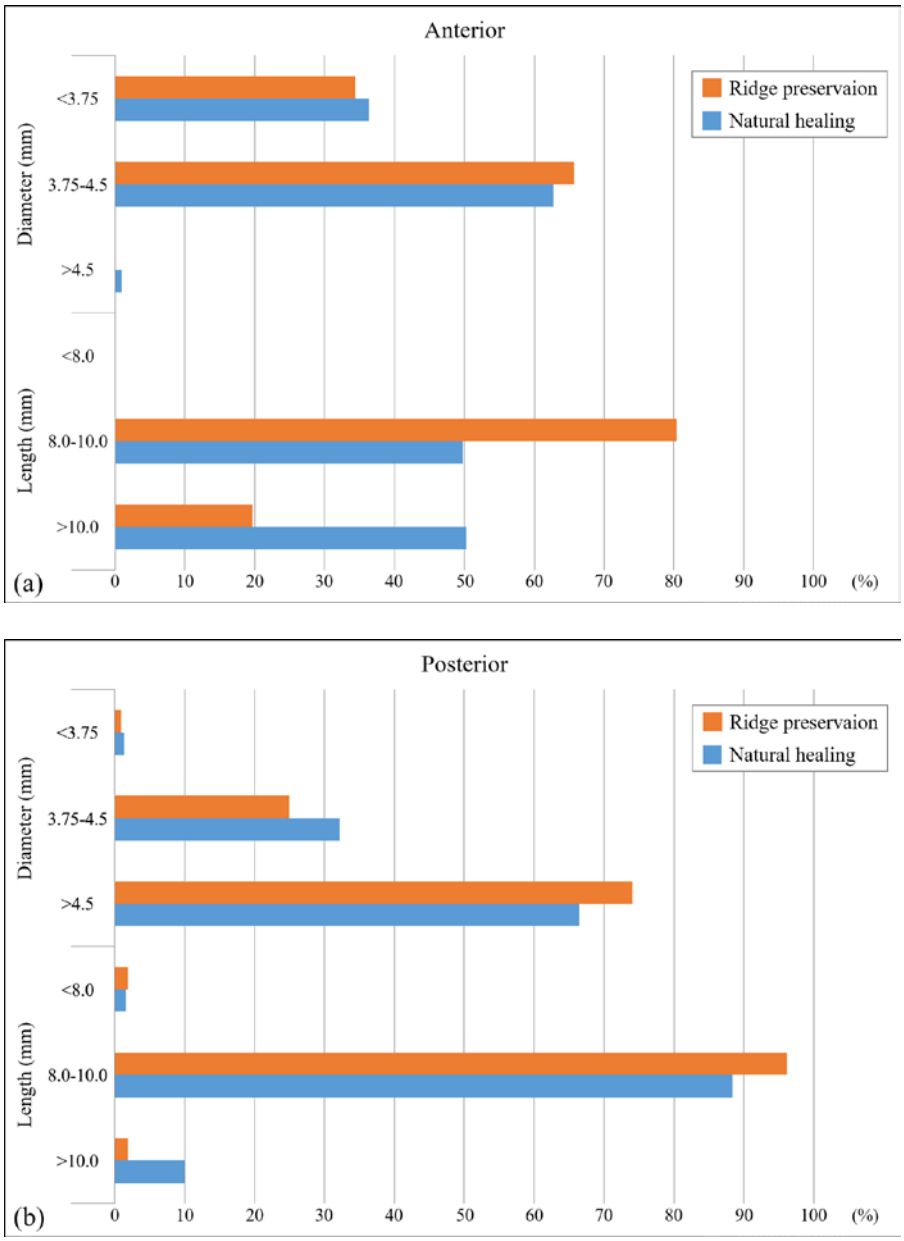

Figure 1

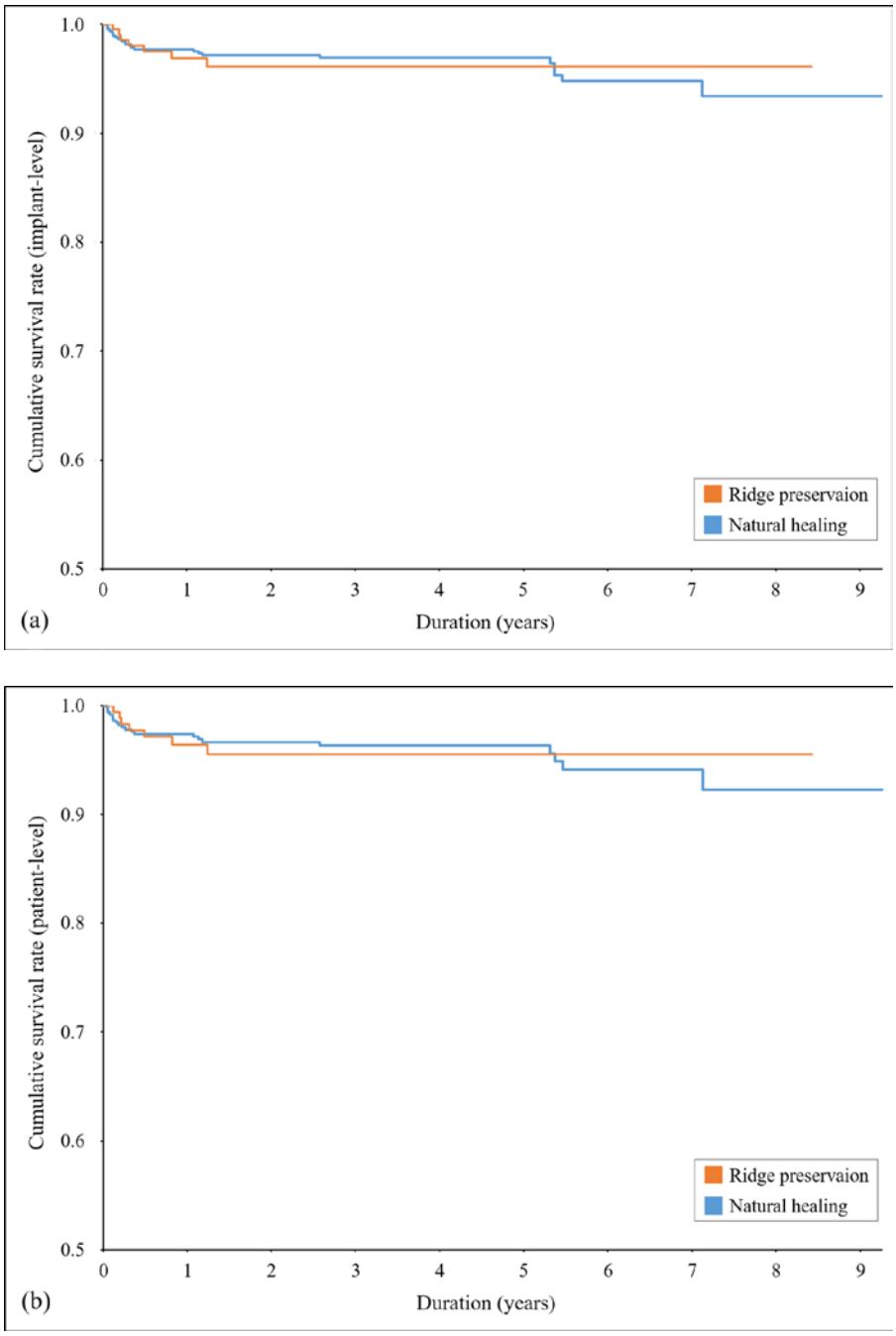

Figure 2

국문요약

상악 치아에서 자연 치유와 비교하여 임플란트 식립을 위한 치조제 보존술의 임상적 이점: 후향적 연구

<지도교수 **정 의 원**>

연세대학교 대학원 치의학과

박 수 현

발치 후 발생하는 치조제의 수평적, 수직적 흡수로 인해 임플란트 식립을 위한 골량이 충분하지 않은 경우, 임플란트 식립술과 함께 골유도재생술이나 상악동 거상술과 같은 추가적인 골증강술이 수반된다. 이전의 여러 연구들을 통해 치조제 보존술 (Ridge preservation; RP)이 발치 후 나타나는 치조제의 부피 감소를 줄여주는 데 효과가 있음이 밝혀졌다. 부피가 유지된 치조제에 임플란트 식립을 할 경우 자연치유 된 치조제에서 보다 간단하게 임플란트를 식립할 수 있으며 외과적 합병증도 감소할 수 있다. 특히 상악 구치부의 경우 최근 연구에 따르면 치조제 보존술을 통해 상악동의 함기화를 예방하여 추후 임플란트 식립에 필요한 골량을 확보할 수 있다. 본 후향적 연구에서는 상악

치아를 대상으로 자연치유 된 경우와 비교하여 임플란트 식립술의 침습도 측면에서 치조제 보존술의 임상적 이점을 밝히는 데 있다. 또한 치조제 보존술을 한 경우와 자연치유 된 경우 간에 임플란트 생존율과 변연골 소실을 포함한 임플란트 관련 결과를 비교하는 데 있다.

2009년부터 2018년까지 연세대학교 치과대학병원 치주과에서 상악 전치부 및 구치부에 발치와 임플란트 식립을 받은 환자를 대상으로 하였으며, 치조제 보존술을 받은 178명의 환자 (206개의 임플란트)를 RP군, 자연치유시킨 493명의 환자 (656개의 임플란트)를 대조군으로 분류하였다. 임플란트 식립 전 또는 식립 중 시행된 추가적인 골증강술 비율에 대한 비교분석, 카플란 마이어법(Kaplant-Meier method)을 이용한 생존분석 및 임플란트 주변 변연골 소실량을 계측하여 방사선학적 분석을 시행하였다.

연구결과 임플란트 식립 전 또는 식립 중 시행된 추가적인 골증강술은 통계적으로 유의미하게 대조군에서 더 많이 시행되었다 (P=0.002). 상악동 증강술이 시행된 경우 측방 접근법이 시행된 비율이 대조군에서는 37.2%, RP군에서는 8.3%로 통계적으로 유의미한 차이를 보였다 (P<0.001). 임플란트 및 환자 수준에서 임플란트의 누적 생존율은 RP군에서 각각 96.1%와 95.5%, 대조군에서 각각 93.4%와 92.3%로 두 군간에 통계학적인 차이가 없었다. 연간 변연골 소실량은 전치부의 경우 RP군에서 0.16±0.41 mm, 대조군에서 0.11±0.34 mm (P=0.16), 구치부의 경우 RP군에서 0.04±0.19 mm, 대조군

에서 0.05±0.26 mm (P=0.57)로 두 군간에 통계학적 차이를 나타내지 않았다.

후향적 연구라는 한계 내에서 본 연구는 치조제 보존술이 상악에서 상악동 증강술을 보다 간단하게 하여 임플란트 식립술의 침습도를 감소시켜줄 수 있을 것으로 결론지어 진다.

핵심되는 말: 골증강술, 치과 임플란트, 발치와, 치조제 보존술, 상악동 증강술