Clinical efficacy of Nonsurgical Root Canal Treatment Using a Single-cone technique with White EndoSeal MTA ; A Randomized Clinical Trial

Ji-hyung Kim

The Graduate School

Yonsei University

Department of Dentistry

Clinical efficacy of Nonsurgical Root Canal Treatment Using a Single-cone technique with White EndoSeal MTA ; A Randomized Clinical Trial

A Master's Thesis
Submitted to the Department of Dentistry
And the Graduate School of Yonsei University
In partial fulfillment of the
Requirements for the degree of
Master of Dental Science

Ji-hyung Kim

January 2021

This certifies that the Master's Thesis of

Ji-hyung Kim is approved.

_____

Il-Young Jung

_____

Su-Jung Shin

_____

Sin-Yeon Cho

The Graduate School

Yonsei University

January 2021

감사의 글

보존과 수련 기간동안 많은 분들의 도움으로 깊은 학문적 배움을 얻을 수 있었습니다. 지금 생각해 보면 보존과 수련을 한 3년은 제 인생에서 많은 것을 바뀌게 한 전환점이었던 것 같습니다. 이러한 경험을 하게 해주신 진심으로 존경하는 제 지도교수님, 정일영 교수님께 감사의 말씀을 드립니다. 그리고 한명의 어엿한 보존과 전문의로 거듭날 수 있게 이끌어 주신 노병덕 교수님, 박성호 교수님, 김의성 교수님, 박정원 교수님, 신수정 교수님, 신유석 교수님, 김선일 교수님, 김도현 교수님, 강수미 교수님께 깊이 감사드립니다.

보존과 수련 생활을 하면서 여러 힘든 순간들이 있었지만 따듯한 선후배들 덕분에 지금의 제가 있는 것 같습니다. 함께 보낸 회식들, 엠티, 사진 촬영 등은 평생 기억될 추억거리가 되었습니다. 3년간 많이 힘들었지만 졸업하여 로컬에서 진료를 하다 보니 보존과만큼 많은 걸 배우는 과는 없는 것 같습니다. 후배들도 많이 힘들겠지만 3년간 열심히 보낸다면 다른 어떤 치과의사보다 내실 있는 치과의사가 될 수 있다고 당부드리고 싶습니다.

마지막으로 6 년의 치과대학 과정과 4 년의 전공의 과정이라는 긴 기간동안 많은 응원과 지원을 해주신 아버지, 어머니, 시아버지, 시어머니께 사랑과 감사의 마음을 전합니다. 또한 항상 저를 사랑해 주는 제 남편과 딸인 전태린에게도 감사와 사랑을 보냅니다.

2021년 1월

김 지 형

Table of Contents

List of Figures

List of Tables

Abstract

Clinical efficacy of Nonsurgical Root Canal Treatment Using a Single-cone technique with White EndoSeal MTA ; A Randomized Clinical Trial

Ji-hyung Kim, D.D.S.

Department of Dentistry

The Graduate School, Yonsei University

(Directed by Professor, Il-Young Jung, D.D.S., M.S.D., Ph.D.)

The aim of this study was to investigate clinical efficacy of nonsurgical root canal treatment using a single-cone technique with White Endoseal MTA (WEM, Maruchi,

Wonju, Korea), a novel calcium silicate-based sealer. For this, a single-blinded randomized clinical trial was conducted on outpatients of the Department of Conservative Dentistry, College of Dentistry, Yonsei University, Seoul, Korea between April 2018 and September 2018 who needed nonsurgical root canal treatment including initial and retreatment cases. To assess clinical efficacy, we have compared the results of the experimental group treated by a single-cone technique with WEM in terms of postoperative pain, canal obturation quality, clinical outcome with results of the control group treated by conventional method, a continuous wave technique with AH plus (Dentsply DeTrey GmbH, Konstanz, Germany).

Ninety volunteers, 96 teeth were enrolled and randomly distributed to either experimental or control group. To confirm postoperative pain, all patients were asked to record the degree of pain on a Numeric Rating Scale after 4 hours, 24 hours, 48 hours or canal obturation. Canal obturation quality was assessed in terms of sealer extrusion, root filling voids and a level of the root filling based on periapical radiograph taken on the day of canal obturation. After at least 6 months from canal obturation, patients were recalled and evaluated through clinical and radiographic examinations. The result of nonsurgical root canal treatment was determined as healed, healing, and diseased based on clinical sign and symptom and PAI score in periapical views. Healed and healing cases were assorted as success and Fisher's exact test was done to find out differences between the 2 groups and possible prognostic factors for clinical outcome.

Sixty-four patients and 70 teeth were recalled. The result showed that there were no differences between the 2 groups in terms of postoperative pain and clinical outcome. After the mean follow-up time of 17 months, the overall success rate was 93.9% for the experimental group and 91.9% for the control group. However, the experimental group showed less sealer extrusion compared to the control group ($P = 0.025$). Sealer extrusion and post-operative pain were determined to be prognostic factors ($P < 0.05$).

Within the limitation of this study, it was found that a single-cone technique using WEM can be a possible alternative to a continuous wave technique using AH Plus.

Keywords : calcium silicate-based sealer; White Endoseal MTA; clinical efficacy; root canal obturation; a single-cone technique

Clinical efficacy of Nonsurgical Root Canal Treatment Using a Single-cone technique with White EndoSeal MTA ; A Randomized Clinical Trial

Ji-hyung Kim

Department of Dentistry
The Graduate School, Yonsei University
(Directed by Professor Il-Young Jung)

I. Introduction

Root canal obturation is a procedure done at the final stage of root canal treatment and one of the factors for success in endodontic treatment. The other factors include debridement and thorough disinfection. For proper obturation, the canal system should be sealed three-dimensionally, which means to be sealed apically, coronally, and laterally. The aim of obturation is to prevent or treat periapical disease by preventing recontamination by bacteria that might have remained in the dentinal tubules or that exist in the oral cavity (Ray and Trope 1995). They reported the quality of coronal sealing is more important than that of apical sealing for apical periodontal health. However, a meta-analysis of factors influencing the efficacy of primary root canal treatment found that not only adequate coronal restoration but also quality of apical sealing, i.e., root canal filling with no voids, obturation to within 2.0mm of the apex, are key factors influenced success of root canal treatment (Ng et al. 2008). Therefore, good root filling is crucial to success of root canal treatment. To achieve this, various types of obturation techniques and materials have been developed.

In terms of materials, most techniques employ a core material and sealer. For a core material, gutta-percha is the most popular and widely used. For a sealer, which is essential to achieve hermetic seal in root canal system, various types have been developed and experimented. An ideal root canal sealer provides a complete microscopic seal, possesses antimicrobial activity, and is biocompatible. However, Komabayashi et al. (2020) said contemporary sealers excel for some criteria but fall short when evaluated for all of them.

Recently, a new category of root canal sealer based on calcium silicate is gaining popularity because of its bioactivity to enhance bone formation and induce the hydroxyapatite formation within dentin which can result in self-seal (Prati and Gandolfi 2015). Calcium silicate-based endodontic sealers enable these by inducing the differentiation of odontoblasts and mineralization in preosteoblasts. Also, calcium silicate-based endodontic sealers promote periapical tissue healing by reducing inflammation (Lee et al. 2019a). In terms of cytotoxicity in *in vitro* models, it is controversial whether there are differences between calcium silicate-based endodontic sealers and their resin-based counterpart, AH Plus (Dentsply DeTrey GmbH, Konstanz, Germany) in cytotoxicity. Some authors suggested calcium silicate-based sealers are less cytotoxic than AH Plus (Lee et al. 2019b; Seo et al. 2019), while another author suggested there are no differences (da Silva et al. 2017). Additionally, they exhibit satisfactory physical properties such as bond strength, radiopacity, pH, solubility, setting and working time, dimensional change, flow, calcium ion release (Silva Almeida et al. 2017; Silva et al. 2016).

In terms of techniques, on the other hand, many techniques have been developed and devised in attempts of better sealing. Single-cone obturation technique, lateral condensation technique, warm lateral condensation, warm vertical compaction technique, thermoplastic injection techniques and the continuous wave technique are representative techniques. However, there is little evidence to support one method of obturation is superior to another (Ng et al. 2007). The prospective Toronto studies advocated that warm vertical compaction might be superior to lateral compaction but there was no statistically significant

difference (Friedman et al. 2003). In addition, a meta-analysis comparing those two techniques found out that the treatment outcomes were similar in terms of postoperative pain prevalence, long-term outcomes, and obturation quality (Peng et al. 2007). However, the most commonly used method at present is the continuous wave technique, a variation of warm vertical compaction technique, due to increased use of nickel-titanium rotary preparation techniques and the fabrication of greater taper standard cones. This technique suits filling of root canals prepared by nickel-titanium rotary files in that thermoplasticizing techniques allow the best adaptation to the prepared root canals (Weller et al. 1997). Additionally, if gutta-percha cones which have similar taper to prepared root canal are used, greater hydraulic forces are generated resulting in obturation of more lateral canals when appropriately tapered pluggers are used (Nahmias et al. 2001). Despite its advantages, disadvantages of this technique are more apical extrusion of sealer due to the applied pressure (Keçeci et al. 2005), the heat generated during using pluggers which might affect root cementum, periodontal ligament and alveolar bone (Lipski 2005), and excessive stress on the root dentin while applying pressure to the tooth which can lead to cracks (Capar et al. 2015).

To overcome these shortcomings, the single-cone obturation technique using calcium silicate-based endodontic sealers described above is an alternative to the continuous wave technique. Capar (2015) found out that the single-cone obturation technique induced less apical cracks than the warm vertical compaction technique did. Also, since there are no hydraulic forces or heat generation in the root canal, the single-cone technique is expected

to induce less sealer extrusions or damage to periodontium. Traditionally, the single-cone obturation technique, which fills the root canal with the sealer and a single cone, was not adopted due to its inferiority in a durable seal against bacterial leakage compared to the warm vertical compaction technique (Monticelli et al. 2007). However, as calcium silicate-based endodontic sealers were developed, single-cone obturation technique, which manufacturers of these sealers recommend, is used nowadays. Since the ratio of sealer in the root canal is higher than in the thermoplastic obturation technique (Ozawa et al. 2009), the physical property of the sealer used in the single-cone obturation technique is more emphasized than in the continuous wave technique. As mentioned above, calcium silicate-based endodontic sealers show many biological advantages and verified great physical properties in *ex vivo* and *in vitro* models (Zhang et al. 2009; Zhou et al. 2013). A recent retrospective clinical study demonstrated 90.9% overall success rate after minimum 1-year recall using a single-cone obturation technique with EndoSequence BC Sealer (Brasseler USA, Savannah, GA, USA), one of calcium silicate-based sealer (Chybowski et al. 2018).

Additionally, based on their biological properties, i.e., calcium silicate-based sealers' ability to reduce inflammation and possible better biocompatibility, calcium silicate-based sealers are expected to have less post-operative pain. Moreover, due to the characteristics of the single-cone technique, calcium silicate-based sealers are expected to induce less sealer extrusion which might affect post-operative pain rate. Sealer extrusion itself does not affect success rate of root canal treatment (Friedman et al. 2003) but causes periapical inflammation and pain (Shashirekha et al. 2018).

White EndoSeal MTA (WEM, Maruchi, Wonju, Korea) is one of calcium silicate-based sealers which is currently commercially available. WEM is an upgraded version of EndoSeal MTA (Maruchi, Wonju, Korea) to satisfy ISO standards more in terms of setting time. Also, WEM causes less discoloration and has better biocompatibility compared to EndoSeal MTA according to the manufacturer. EndoSeal MTA showed acceptable physicochemical properties, i.e., flowability, radiopacity, dimensional stability meeting ISO standards except for setting time in previous *in vitro* study (Lee et al. 2017). A single-cone technique using WEM is preferred by clinicians for not only the sealer's properties but also its low technique sensitivity of canal obturation method. Many previous studies evaluated mechanical and biological properties of EndoSeal MTA. Despite the material's clinical popularity and many *in vitro* studies, there are no well-regulated clinical trial with clinical follow-up using EndoSeal MTA or WEM. The only prospective clinical study regarding EndoSeal MTA is a study evaluating postoperative pain (Aslan and Dönmez Özkan 2020). Therefore, the purpose of this study was to evaluate clinical efficacy in terms of postoperative pain, the quality of root canal obturation, and clinical outcome with short-term follow-up of nonsurgical root canal therapy using WEM and a single-cone technique through a randomized clinical trial. Randomized clinical trials are considered to be the most reliable method for evaluating the efficacy of treatments (Greenhalgh 2001). With this background, this study was designed to conduct a 1-year follow-up clinical study based on funding of government to establish evidences for use of WEM.

II. Materials and methods

2.1. Study design and population

This study was designed as a randomized, single-blinded clinical trial to compare a single-cone technique using WEM and a continuous wave technique using AH Plus sealer in terms of postoperative pain, the quality of root canal obturation, and short-term clinical outcome. The study was approved by the Institutional Review Board of Yonsei University Dental Hospital (IRB number: 2-2018-0009). The patients were enrolled from the outpatients in clinic of the Department of Conservative Dentistry, College of Dentistry, Yonsei University, Seoul, Korea, between April 2018 and September 2018. All patients participating in this study had teeth with fully formed apices requiring root canal therapy. The subjects were older than 18 years and were in good health (American Society of Anesthesiologists classification I or II). Exclusion criteria included the following:

1. Patients unable to communicate their symptoms due to psychologic disorders etc.

2. Tooth with poor prognosis affected by cracks extending into root canal, severe periodontal bone loss due to chronic periodontitis accompanying mobility of the tooth or vertical root fracture, etc.

3. Tooth that a root canal was not negotiable within 2mm of the radiographic apex.

After screening, the candidates were explained to the clinical study and written informed consents to participate were obtained before enrolling them in the study for those who agreed to do.

2.2. Sample-size determination

The required sample size was calculated using sealed envelope software (Clerkenwell Workshops, London, UK) for a comparison of two experimental groups with a significance level of 5%, a statistical power of 80%, and an equivalence limit of 10%. Based on a previous study (Imura et al. 2007), success rate of nonsurgical root canal treatment is 90~95% based on loose criteria, and so 80 teeth were needed for each group.

2.3. Treatment procedure and Randomization

Teeth were treated by 6 dentists including well-trained 3-year residents in Yonsei university, department of conservative dentistry. All of the practices were done in at least 2 visits.

On first visit, after local anesthesia and rubber dam isolation, an access opening was made and working length was determined using an electronic apex locator (Root ZX II; J Morita, Irvine, CA). The canals were prepared using the operator's preferred rotary instruments. The master apical file size was determined by the operator according to initial apical file size. The canals were irrigated using 2.5% sodium hypochlorite with a 27-G side-vented needle. In some cases, such as retreatment cases, passive ultrasonic irrigation

was accompanied to help remove severe contamination. In specific, an ultrasonic irrigator, Endosonic Blue (Maruchi, Wonju, Korea) was used at the power of 30kHz.

At the visit for canal obturation, when there was no or only minor sign and symptom, the patients were asked to participate in the study. Those who agreed to participate and signed the informed consent form were included in this study. Each participant was given an enrollment number and then randomly assigned to one of the two groups based on the obturation protocol: continuous wave technique with AH Plus sealer (CWA) and single-cone technique with WEM sealer (SCW). After the enrollment number was given to the participant, the clinician was given the enrollment-number-matched sealed envelope containing which method would be used based on the table of random numbers.

Gutta-percha cones were fitted and a periapical radiograph was taken to confirm the working length. Canals were dried using paper points.

For SCW group, WEM sealer was dispensed into the middle third of the canal using a 24-gauge needle tip. A single gutta percha cone (DiaDent, Cheongjusi, Korea) was inserted into the canal by up-and-down motion for 3 times to allow the sealer to penetrate better. For wide canals, one or two additional gutta percha cones were inserted for better sealing. After cutting the gutta percha cone at the orifice level, Obtura S-Kondenser (Obtura Spartan, Earth City, MO, USA) was used to compact the gutta percha vertically.

For CWA group, gutta percha cones were coated with AH plus sealer and inserted into the prepared root canals. A heated plugger (SuperEndo Alpha 2, B & L Biotech, Ansan,

Korea) that penetrates 4 or 5 mm short of the working length was inserted into the canal to cut and compact the master cone. Backfill of the canal was performed by warm gutta-percha injection using the SuperEndo Beta 2 (B & L Biotech).

2.4. Outcome variable

2.4.1. Postoperative pain

Patients recorded their pain on a 0–10 numerical rating scale (NRS) with 0 indicating 'No pain' and 10 indicating 'The worst pain'. Patients were required to report their pain level via wire or wireless communication according to the patients' preference at the following time-points: 4, 24, 48 hours after canal obturation. The pain scores were assorted as none, mild, moderate and severe.

1. "None": The treated tooth felt normal and the participant answered to have no pain at all

2. "Mild": The tooth was slightly painful and the participant described pain range as NRS 1~3, but there was no need to take analgesics

3. "Moderate": The tooth caused discomfort and pain which was somewhat tolerable but sometimes needing analgesics. The participant described pain range as NRS 4~7

4. "Severe": The pain caused by the treated tooth disturbed normal activity or sleep, and analgesics had little or no effect. The participant described pain range as NRS 8~10.

2.4.2. The quality of root canal obturation

Quality of root canal obturation was evaluated in terms of sealer extrusion, root filling voids and a level of the root filling. Evaluation was done based on periapical view immediately after canal obturation by 2 calibrated examiners. Specifically, sealer extrusion and root filling voids were examined as absence or presence. If there were sealer extrusion or root filling voids in at least 1 root for multirooted teeth, the teeth were evaluated as "presence" of sealer extrusion or root filling voids. The level of the root filling was recorded as "adequate" when the filling reached within 2mm of the radiographic apex. When fillings were beyond the radiographic apex, they were assorted "long" (Sjogren et al. 1990). Since cases with short working length were excluded during screening in this clinical study before canal obturation, there were no teeth in which the canals were filled shorter than 2mm of the radiographic apex.

2.4.3. The outcome assessment of nonsurgical root canal treatment

The participants were recalled after at least 6 months. During recall appointments, a radiographic and clinical examination of the treated tooth were done. Radiographic examination was done based on periapical views and they were evaluated according to PAI score (Orstavik et al. 1986) by 2 calibrated examiners. Multirooted teeth were given the highest score for any of the roots. Clinical examination included presence/absence of pain, swelling, other symptoms and sinus tract in addition to functionality. Healing of a case was determined as decreased PAI score and lack of symptom.

The teeth were divided into outcome categories based on the following classification.

1. Healed: functional, asymptomatic teeth with PAI≤2

2. Diseased: nonfunctional, symptomatic teeth with PAR≥3

3. Healing: teeth that are asymptomatic and functional with a decreased size of radiographic periradicular radiolucency

“Healed” and “Healing” categories were assorted as success and “Diseased” category was assorted as failure. Examples of each outcome category are shown in Figure 1.

Treatment-related variables were evaluated to identify possible prognostic factors. The factors were as below

-Patient-related factors: sex, age

-Tooth-related factors: tooth type, presence/absence of vitality, preoperative PAI score, pre-operative pain, pre-operative percussion and palpation sensitivity

-Treatment factors: treatment type (initial treatment or retreatment), presence of apical patency, sealer extrusion, root filling voids, root filling length, post-operative pain

Healed(SCW group) 25 Month Recall

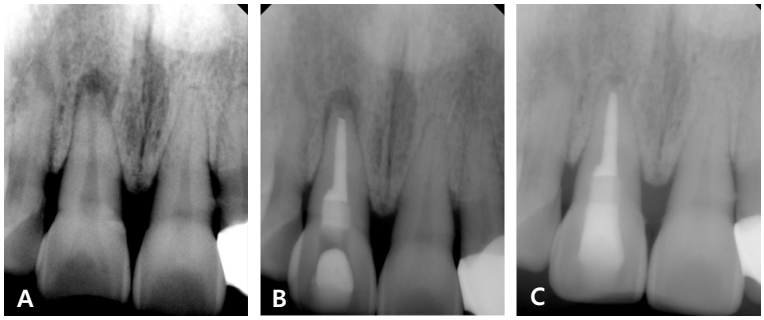

Healing(SCW group) 24 Month Recall

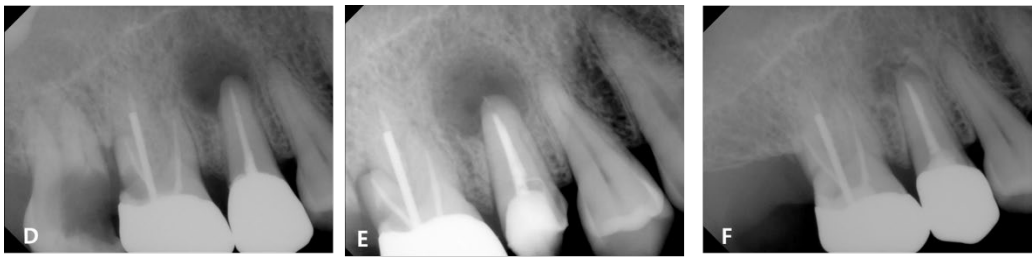

Diseased(SCW group) 10 Month Recall

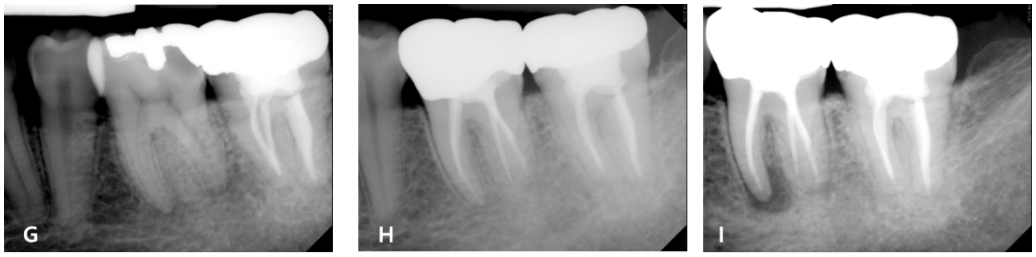

Figure 1. *(A,D, and G)* Preoperative, *(B,E and H)* Postoperative, *(C,F, and I)* Recall radiograph,

2.5. Statistical analysis

Postoperative pain after obturation by each sealer and the quality of root canal obturation were analyzed statistically by a Pearson chi square test or Fisher's exact test. A P value < 0.05 was considered significant. Survival analysis was performed using the Kaplan-Meier method and the log-rank test was used to examine the differences in success rates between two groups ($P < 0.05$). The effect of possible prognostic factors was verified through Fisher's exact test.

III. Results

3.1. Participants

In total, 90 volunteers and 96 teeth were enrolled. Two patients were excluded due to advanced periodontitis, one patient was excluded due to endodontic surgery for severe pain immediately after canal filling, and one patient was excluded due to unrestorable fracture of the treated tooth. Resultingly, 64 patients (70 teeth) were recalled. The overall procedure is described in the flow chart (Figure 2).

Figure 2. Flow chart illustrating the procedure of the clinical trial

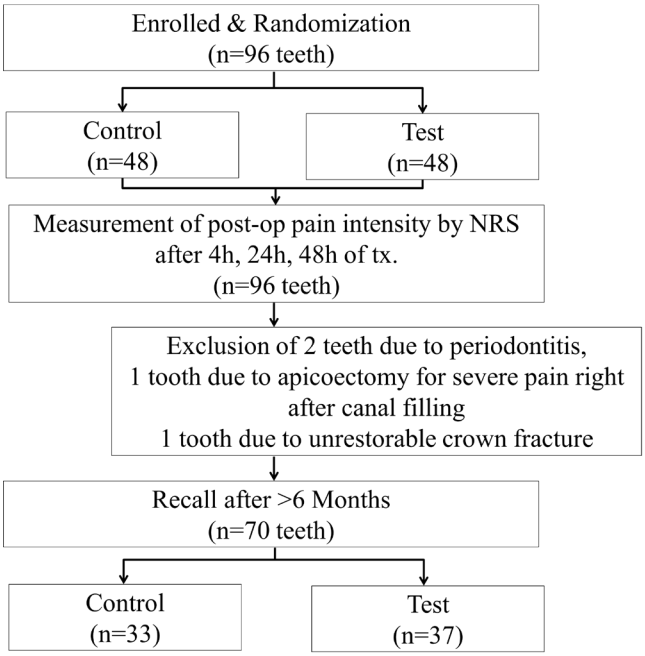

The demographic data of the enrolled participants are presented in Table 1; none of their characteristics differed significantly between the two groups.

Table 1. Population demographics

Factors		Group	
		CWA, n	SCW, n
Age			
	≤45y	28	23
	>45y	20	25
Sex			
	Female	24	24
	Male	24	24
Preoperative pain			
	Present	19	26
	Absent	29	22
Tooth			
	Maxillary anterior	11	5
	Mandibular anterior	7	7
	Maxillary premolar	8	6
	Mandibular premolar	1	2
	Maxillary molar	3	4
	Mandibular molar	18	24
Preoperative PAI score			
	1	12	11
	2	8	9
	3	6	4
	4	16	19
	5	6	5
Treatment type			
	RCT	36	33
	re-RCT	12	15
Vitality of tooth			
	Present	17	16
	Absent	19	17
	re-RCT	12	15

3.2. Postoperative pain

There were no significant differences between the two groups at any time points assessed ($P > 0.05$).

Table 2. Postoperative pain

`	Group		
	CWA, n (%)	SCW, n (%)	
After 4h			***P* value**
None	17 (35.4)	20 (41.7)	0.519
Mild	30 (62.5)	26 (54.2)	
Moderate	1 (2.1)	2 (4.2)	
Severe	0 (0.0)	0 (0.0)	
After 24h			
None	26 (54.2)	27 (56.3)	0.837
Mild	21 (43.8)	21 (43.8)	
Moderate	1 (2.1)	0 (0)	
Severe	0 (0.0)	0 (0.0)	
After 48h			
None	31 (64.6)	30 (62.5)	0.747
Mild	17 (35.4)	18 (37.5)	
Moderate	0 (0.0)	0 (0.0)	
Severe	0 (0.0)	0 (0.0)	

***Pearson chi square test**

3.3. The quality of root canal obturation

The quality of root canal obturation analyzed is described in Table 3. Root filling length and voids did not differ significantly between CWA and SCW groups. However, in terms of sealer extrusion, SCW resulted in less sealer extrusion significantly.

Table 3. The quality of canal obturation

Canal obturation quality factor	Group		
	CWA, n	SCW, n	***P* value**
Sealer extrusion			
Present	21	11	**0.025**
Absent	27	37	
Void			
Present	15	17	0.414
Absent	33	31	
Root filling length			
Adequate	46	47	0.5
Long	2	1	

***Fisher's exact test**

3.4. The outcome of nonsurgical root canal treatment

The periapical views immediately after root canal obturation and each follow-up were analyzed by 2 calibrated examiners. The Kappa score for interexaminer agreement after the first calibration session was κ= 0.8. After the second session performed 1 week later, the Kappa score for intraexaminer agreement was κ = 0.9. Both scores indicated good

agreement (Landis and Koch 1977). Mean time to follow-up was 17 months.

The Kaplan-Meier survival curves revealed that the cumulate survival after non-surgical root canal treatment was 91.9% for CWA group and 93.9% for SCW group. The result is shown in Figure 3. The long-rank test indicated that there was no significant difference between the 2 groups.

To evaluate possible prognostic factors that could affect the clinical outcome, Fisher's exact test was used. Among the factors evaluated, sealer extrusion and level of post-operative pain influenced on the nonsurgical treatment outcome significantly ($P < 0.05$).

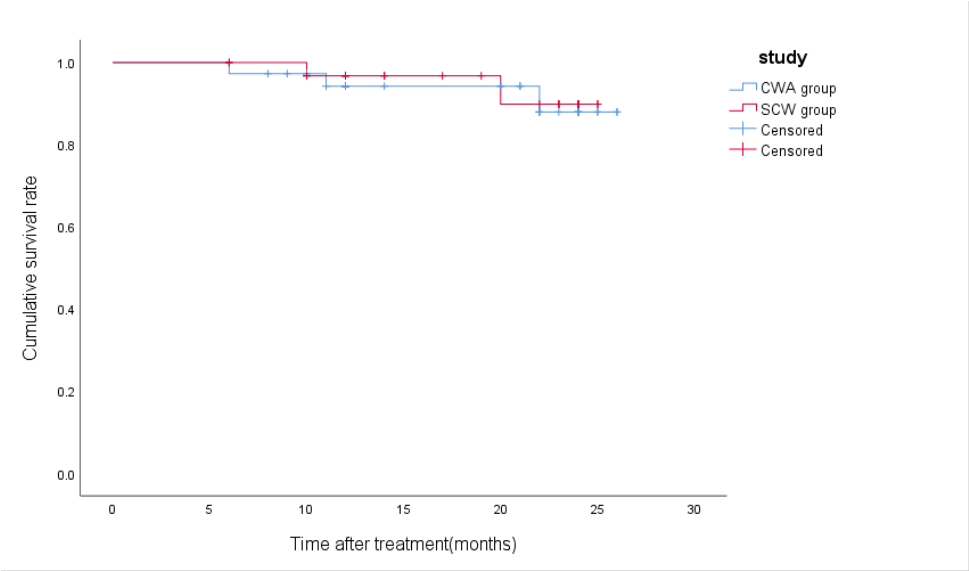

Figure 3. The Kaplan-Meier survival function curves by either CWA or SCW groups.

Table 4. Treatment outcome by factors and demographics

Factor/Demographic(n)	Healed, n	Healing, n	Diseased, n	Success, n(%)	***P* value**
Group					
CWA(37)	19	15	3	34(91.3)	1
SCW(33)	24	7	2	31(93.9)	
Sex					
Male(36)	24	11	1	35(97.2)	0.192
Female(34)	19	11	4	30(88.3)	
Age					
≤50(46)	25	17	4	42(91.3)	0.654
>50(24)	18	5	1	23(95.8)	
Tooth type					
Incisor(14)	8	5	1	13(92.9)	0.388
Premolar(18)	13	5	0	18(100)	
Molar(38)	22	12	4	34(89.5)	
Presence/absence of vitality					
Present(23)	15	4	4	19(82.6)	0.052
Absent(28)	19	9	0	28(100)	
Retreatment(19)	9	9	1	18(94.7)	
preoperative PAI score					
1(18)	11	4	3	15(83.3)	0.583

2(14)	11	2	1	13(92.9)	
3(8)	5	3	0	8(100)	
4(22)	13	8	1	21(95.5)	
5(8)	3	5	0	8(100)	
Pre-operative pain					
Present(27)	16	8	3	24(88.9)	0.367
Absent(43)	27	14	2	41(95.3)	
Pre-operative percussion and palpation sensitivity					
Present(33)	16	15	2	31(93.9)	1
Absent(37)	27	7	3	34(91.9)	
Treatment type					
Initial(51)	32	15	4	47(92.2)	1
Retreatment(19)	11	7	1	18(94.7)	
Sealer extrusion					
Present(23)	11	8	4	19(82.6)	**0.037**
Absent(47)	32	14	1	46(97.9)	
Root filling voids					
Present(24)	16	6	2	22(91.7)	1
Absent(46)	27	16	3	43(93.5)	
Root filling length					

Adequate(68)	43	21	4	64(94.1)	0.139
Long(2)	0	1	1	1(50.0)	
Post-operative pain					
None(22)	13	9	0	22(100)	**0.012**
Mild(40)	27	11	2	38(95.0)	
Moderate(3)	1	1	1	2(66.7)	
Severe(5)	2	1	2	3(60.0)	
Apical patency					
Present(57)	35	17	5	52(91.2)	0.346
Absent(13)	0	13	0	13(100)	

***Fisher's exact test**

IV. Discussion

Recently, calcium silicate-based sealers are widely used in endodontics because of its physical and biological properties. There have been many *in vitro* and *in vivo* studies regarding these sealers, however there has not been any prospective clinical study. This study was randomized clinical trial (RCT) to show clinical efficacy of WEM, one of calcium silicate-based sealers. RCT is the second highest in the hierarchy of evidence in clinical studies followed by systematic reviews of RCTs (Greenhalgh 2001). Because RCTs require expenses and a lot of time, they are rarely done but the most effective method to see the effect of certain therapy by excluding all other biases. However, due to the characteristics, most RCTs have too small sample size giving less power to statistics. This study was done by funding of government and there was limited time to use the fund. For reward to the participants, small amount of transportation expenses was supplied for every visit. Unfortunately, since there was limit to use the fund, there were limited number of participants resultingly. Therefore, there were differences between the number of participants we calculated to enroll and the number of participants we actually enrolled which was much less resulting in too small sample size. If other clinical trials are done using WEM, systematic review can be considered to overcome this drawback. Regardless, this study is the first to evaluate clinical outcome of WEM used with a single-cone technique, which is valuable in the era when a single-cone technique with calcium silicate-

based sealers is preferred by clinicians.

According to previous study of a meta-analysis, in cases of primary root canal treatment, factors influencing success are the absence of a pretreatment periapical lesion, root canal fillings with no voids, obturation to within 2.0mm of the apex and an adequate coronal restoration (Ng et al. 2008). In retreatment cases, outcome was better in teeth with inadequate previous root filling, without perforation and radiolucency (de Chevigny et al. 2008). In this study, the factor of pretreatment periapical lesion, the prognostic factor for both initial treatment and retreatment, was well regulated by equal distribution of participants with various condition of apical periodontitis as shown in the PAI score of population demographics through randomization. Also, for retreatment cases, there were no cases with perforation and all cases had some drawbacks in previous root filling such as inadequate root filling density and root filling voids.

Based on the meta-analysis of Ng et al. (2008), we investigated the effect of root canal filling voids on the outcome of the root canal treatment. Sealer extrusion is not known to be a factor that influences the result of nonsurgical root canal treatment (Ricucci et al. 2016), but was investigated because it can affect postoperative pain after canal obturation (Shashirekha et al. 2018). In terms of root canal filling voids, both CWA and SCW groups showed equal results. In terms of sealer extrusion, SCW group showed less sealer extrusion than CWA group did. However, postoperative pain did not differ between two groups. This is probably because even though when sealer was extruded, it was only small amount of it

in most cases since all procedures were done by skilled dentists.

Even though both groups showed excellent results in terms of canal obturation quality, according to previous study, non-destructive methods are less precise in analysis of root canal voids than destructive methods (Kim et al. 2018). In the study, micro-computed tomography was used for non-destructive method and in our study only periapical view, much less accurate than micro-computed tomography, was used. Therefore, it is hard to conclude that single-cone technique using WEM has same sealing ability with continuous wave technique using AH plus and long-term follow up is needed to confirm its sealing ability.

Moreover, unlike other studies (Chybowski et al. 2018; Fonseca et al. 2019), the bioceramic sealer we tested, WEM showed sealer extrusion in small number of cases. According other authors, the bioceramic sealers show higher rate of sealer extrusion due to their flowability (Chybowski et al. 2018). Flowability is important property for bioceramic sealers because mostly bioceramic sealers are used through a single-cone technique. For a fluid-tight seal, flowability is crucial to penetrate into the dentinal tubules and root canal complexities to prevent recontamination (Mamootil and Messer 2007). In an *in vitro* study, EndoSeal MTA, the previous version of WEM, showed higher flowability than AH plus sealer (Jo et al. 2020). However, according to Kim's *ex vivo* study (Kim et al. 2019), EndoSeal MTA with single-cone technique showed significant less penetration of sealer into dentinal tubules than AH Plus with continuous wave technique did. In this sense, WEM

resulting in significantly less sealer extrusion compared to AH Plus sealer could have both favorable and unfavorable effects. The favorable effect is less apical inflammation, pain and faster healing of apical periodontitis (Shashirekha et al. 2018). As Aminoshariae and Kulild (2020) insisted, extruded sealers can induce less healing of apical periodontitis. The unfavorable effect is possibility of recontamination.

As shown in the Figure 1. G~I, the “diseased” case from SCW group was once recovered from apical periodontitis with PAI score 1 in periapical view immediately after root canal obturation but recurred after 6 months. The reason of failure is uncertain but recontamination by remaining bacteria in the root canal system could be a possible reason because coronal restoration was done immediately in this case for better coronal sealing. Penetration of the sealer into dentinal tubules permits hermetic seal which entombing remaining intratubular bacteria (Kirkevang et al. 2000). Lack of this ability could induce recontamination which leaded this case to failure. To overcome this drawback, ultrasonic activation may be necessary to achieve more homogeneous favorable obturation of canal (Kim et al. 2018). Although the manufacturer suggests to use ultrasonic activation, in this study no case used ultrasonic activation because this technique needs a dental assistant but residents did not have one. Additionally, EndoSeal MTA, the previous version of WEM showed significantly less antibacterial effect compared to other sealers (Singh et al. 2016). This also could affect the result.

Interestingly, sealer extrusion and postoperative pain level affected the clinical outcome

of nonsurgical root canal treatment. Among 5 failed cases, 4 cases showed sealer extrusion. Among those 4 cases, 1 case was CWA group with 6-month follow-up. Other than this case, the follow-up periods were more than 10 months. Extrusion of AH plus sealer can affect result of short-term periapical healing for about 6 months according to Sari and Durutuk (2007). Therefore, longer follow-up is needed to confirm the result of the 6-month follow-up case. Additionally, extruded sealer can cause non-healing because of cytotoxicity of sealer itself and it may overburden the immune system of host to heal the previous apical periodontitis (Aminoshariae and Kulild 2020). Among 5 cases, 2 cases had previous apical periodontitis. For postoperative pain level, all failed cases had mild to severe postoperative pain. Among them 2 cases had severe pain. Post-treatment severe pain is related with acute inflammation due to chemical, mechanical, microbial injuries in periapical tissue (Seltzer and Naidorf 1985). In failed cases, remaining microbial factors in root canal system possibly caused severe pain and non-healing of apical tissue.

Apical patency is an important factor affecting outcomes of nonsurgical root canal treatment (Ng et al. 2011). In 13 cases, there were no apical patency. Among those cases, 10 were re-treatment cases and 10 had previous apical periodontitis. For those 13 cases, 8 cases were assessed as “healed” and 5 cases were assessed as “healing”. For healing cases, longer follow-up is needed.

In addition, all tooth enrolled in this study had permanent restoration at the recall so another prognostic factor of primary root canal treatment, an adequate coronal restoration

was excluded on analysis.

One case was excluded because of immediate severe pain after canal obturation. Canal obturation was done with a continuous wave technique using AH plus sealer. The tooth was upper right first molar and endodontic surgery was done on mesiobuccal and distobuccal roots since slight sealer extrusion and minor apical periodontitis was existed in CBCT. After the surgery, the pain was relieved and biopsy result showed chronic inflammatory tissue. The pain could be possibly due to allergic reaction to obturation material.

Based on this study, a single-cone technique using WEM showed equivalency to a continuous wave technique using AH plus sealer.

V. Conclusion

Within the limitation of this study, it was found that a single-cone technique using WEM can be a possible alternative to a continuous wave technique using AH Plus. Sealer extrusion and post-operative pain were determined to be prognostic factors. Cases absent of sealer extrusion and post-operative pain had higher success rate. Further follow-up and other studies with larger sample size are needed for better reliability.

References

Aminoshariae A, Kulild JC. 2020. The impact of sealer extrusion on endodontic outcome: A systematic review with meta-analysis. Australian endodontic journal : the journal of the Australian Society of Endodontology Inc. 46(1):123-129.

Aslan T, Dönmez Özkan H. 2020. The effect of two calcıum sılıcate-based and one epoxy resın-based root canal sealer on postoperatıve paın: A randomızed controlled trıal. International endodontic journal.

Capar ID, Saygili G, Ergun H, Gok T, Arslan H, Ertas H. 2015. Effects of root canal preparation, various filling techniques and retreatment after filling on vertical root fracture and crack formation. Dental traumatology : official publication of International Association for Dental Traumatology. 31(4):302-307.

Chybowski EA, Glickman GN, Patel Y, Fleury A, Solomon E, He J. 2018. Clinical outcome of non-surgical root canal treatment using a single-cone technique with endosequence bioceramic sealer: A retrospective analysis. Journal of endodontics. 44(6):941-945.

da Silva E, Zaia AA, Peters OA. 2017. Cytocompatibility of calcium silicate-based sealers in a three-dimensional cell culture model. Clinical oral investigations. 21(5):1531-1536.

de Chevigny C, Dao TT, Basrani BR, Marquis V, Farzaneh M, Abitbol S, Friedman S. 2008. Treatment outcome in endodontics: The toronto study--phases 3 and 4: Orthograde

retreatment. Journal of endodontics. 34(2):131-137.

Fonseca B, Coelho MS, Bueno C, Fontana CE, Martin AS, Rocha DGP. 2019. Assessment of extrusion and postoperative pain of a bioceramic and resin-based root canal sealer. European journal of dentistry. 13(3):343-348.

Friedman S, Abitbol S, Lawrence HP. 2003. Treatment outcome in endodontics: The toronto study. Phase 1: Initial treatment. Journal of endodontics. 29(12):787-793.

Greenhalgh T. 2001. How to read a paper. BMJ books.

Imura N, Pinheiro ET, Gomes BP, Zaia AA, Ferraz CC, Souza-Filho FJ. 2007. The outcome of endodontic treatment: A retrospective study of 2000 cases performed by a specialist. Journal of endodontics. 33(11):1278-1282.

Jo SB, Kim HK, Lee HN, Kim YJ, Dev Patel K, Campbell Knowles J, Lee JH, Song M. 2020. Physical properties and biofunctionalities of bioactive root canal sealers in vitro. Nanomaterials (Basel, Switzerland). 10(9).

Keçeci A, Çelik Ünal G, Şen B. 2005. Comparison of cold lateral compaction and continuous wave of obturation techniques following manual or rotary instrumentation. International endodontic journal. 38(6):381-388.

Kim JA, Hwang YC, Rosa V, Yu MK, Lee KW, Min KS. 2018. Root canal filling quality of a premixed calcium silicate endodontic sealer applied using gutta-percha cone-mediated ultrasonic activation. Journal of endodontics. 44(1):133-138.

Kim Y, Kim BS, Kim YM, Lee D, Kim SY. 2019. The penetration ability of calcium silicate root canal sealers into dentinal tubules compared to conventional resin-based sealer:

A confocal laser scanning microscopy study. Materials (Basel, Switzerland). 12(3).

Kirkevang LL, Ørstavik D, Hörsted-Bindslev P, Wenzel A. 2000. Periapical status and quality of root fillings and coronal restorations in a danish population. International endodontic journal. 33(6):509-515.

Komabayashi T, Colmenar D, Cvach N, Bhat A, Primus C, Imai Y. 2020. Comprehensive review of current endodontic sealers. Dental Materials Journal. 39(5):703-720.

Landis JR, Koch GG. 1977. The measurement of observer agreement for categorical data. Biometrics. 33(1):159-174.

Lee BN, Hong JU, Kim SM, Jang JH, Chang HS, Hwang YC, Hwang IN, Oh WM. 2019a. Anti-inflammatory and osteogenic effects of calcium silicate-based root canal sealers. Journal of endodontics. 45(1):73-78.

Lee JK, Kim S, Lee S, Kim HC, Kim E. 2019b. In vitro comparison of biocompatibility of calcium silicate-based root canal sealers. Materials (Basel, Switzerland). 12(15).

Lee JK, Kwak SW, Ha JH, Lee W, Kim HC. 2017. Physicochemical properties of epoxy resin-based and bioceramic-based root canal sealers. Bioinorganic chemistry and applications. 2017:2582849.

Lipski M. 2005. Root surface temperature rises during root canal obturation, in vitro, by the continuous wave of condensation technique using system b heatsource. Oral surgery, oral medicine, oral pathology, oral radiology, and endodontics. 99(4):505-510.

Mamootil K, Messer HH. 2007. Penetration of dentinal tubules by endodontic sealer

cements in extracted teeth and in vivo. 40(11):873-881.

Monticelli F, Sadek FT, Schuster GS, Volkmann KR, Looney SW, Ferrari M, Toledano M, Pashley DH, Tay FR. 2007. Efficacy of two contemporary single-cone filling techniques in preventing bacterial leakage. Journal of endodontics. 33(3):310-313.

Nahmias Y, Mah T, Dovgan JSJOH. 2001. The thermo hydraulic condensation technique. 91(12):11-18.

Ng YL, Mann V, Gulabivala K. 2011. A prospective study of the factors affecting outcomes of nonsurgical root canal treatment: Part 1: Periapical health. International endodontic journal. 44(7):583-609.

Ng YL, Mann V, Rahbaran S, Lewsey J, Gulabivala K. 2007. Outcome of primary root canal treatment: Systematic review of the literature - part 1. Effects of study characteristics on probability of success. International endodontic journal. 40(12):921-939.

Ng YL, Mann V, Rahbaran S, Lewsey J, Gulabivala K. 2008. Outcome of primary root canal treatment: Systematic review of the literature -- part 2. Influence of clinical factors. International endodontic journal. 41(1):6-31.

Orstavik D, Kerekes K, Eriksen HM. 1986. The periapical index: A scoring system for radiographic assessment of apical periodontitis. Endodontics & dental traumatology. 2(1):20-34.

Ozawa T, Taha N, Messer HH. 2009. A comparison of techniques for obturating oval-shaped root canals. Dent Mater J. 28(3):290-294.

Peng L, Ye L, Tan H, Zhou X. 2007. Outcome of root canal obturation by warm gutta-percha versus cold lateral condensation: A meta-analysis. Journal of endodontics. 33(2):106-109.

Prati C, Gandolfi MG. 2015. Calcium silicate bioactive cements: Biological perspectives and clinical applications. Dental materials : official publication of the Academy of Dental Materials. 31(4):351-370.

Ray HA, Trope M. 1995. Periapical status of endodontically treated teeth in relation to the technical quality of the root filling and the coronal restoration. International endodontic journal. 28(1):12-18.

Ricucci D, Rôças IN, Alves FR, Loghin S, Siqueira JF, Jr. 2016. Apically extruded sealers: Fate and influence on treatment outcome. Journal of endodontics. 42(2):243-249.

Sari S, Duruturk L. 2007. Radiographic evaluation of periapical healing of permanent teeth with periapical lesions after extrusion of ah plus sealer. Oral surgery, oral medicine, oral pathology, oral radiology, and endodontics. 104(3):e54-59.

Seltzer S, Naidorf IJ. 1985. Flare-ups in endodontics: I. Etiological factors. Journal of endodontics. 11(11):472-478.

Seo DG, Lee D, Kim YM, Song D, Kim SY. 2019. Biocompatibility and mineralization activity of three calcium silicate-based root canal sealers compared to conventional resin-based sealer in human dental pulp stem cells. Materials (Basel, Switzerland). 12(15).

Shashirekha G, Jena A, Pattanaik S, Rath J. 2018. Assessment of pain and dissolution of

apically extruded sealers and their effect on the periradicular tissues. 21(5):546-550.

Silva Almeida LH, Moraes RR, Morgental RD, Pappen FG. 2017. Are premixed calcium silicate-based endodontic sealers comparable to conventional materials? A systematic review of in vitro studies. Journal of endodontics. 43(4):527-535.

Silva EJ, Carvalho NK, Prado MC, Zanon M, Senna PM, Souza EM, De-Deus G. 2016. Push-out bond strength of injectable pozzolan-based root canal sealer. Journal of endodontics. 42(11):1656-1659.

Singh G, Gupta I, Elshamy FMM, Boreak N, Homeida HE. 2016. In vitro comparison of antibacterial properties of bioceramic-based sealer, resin-based sealer and zinc oxide eugenol based sealer and two mineral trioxide aggregates. European journal of dentistry. 10(3):366-369.

Sjogren U, Hagglund B, Sundqvist G, Wing K. 1990. Factors affecting the long-term results of endodontic treatment. Journal of endodontics. 16(10):498-504.

Weller RN, Kimbrough WF, Anderson RW. 1997. A comparison of thermoplastic obturation techniques: Adaptation to the canal walls. Journal of endodontics. 23(11):703-706.

Zhang W, Li Z, Peng B. 2009. Assessment of a new root canal sealer's apical sealing ability. Oral surgery, oral medicine, oral pathology, oral radiology, and endodontics. 107(6):e79-82.

Zhou HM, Shen Y, Zheng W, Li L, Zheng YF, Haapasalo M. 2013. Physical properties of

5 root canal sealers. Journal of endodontics. 39(10):1281-1286.

Abstract (In Korean)

비수술적 근관치료 중 White Endoseal MTA를 단일콘충전법으로 근관충전에 이용시 임상적 유용성 ; 무작위 임상 시험

김 지 형

연세대학교 대학원

치의학과

(지도교수 정 일 영)

본 연구의 목적은 bioceramic 실러의 일종인 칼슘 실리케이트 계통 실러 중 White Endoseal MTA (WEM, 마루치, 원주, 한국)을 단일콘충전법으로

근관충전에 이용시 비수술적 근관치료의 임상적 유용성에 대해 평가하기 위함이다. 이를 위해 무작위 임상 시험이 시행되었으며 그 대상은 연세대학교 치과대학병원 치과보존과에 2018년 4월부터 2018년 9월까지 내원하는 외래환자 중 근관치료를 필요로 하는 환자로 하였다. 임상적 유용성을 평가하기 위해 실험군은 근관충전시 WEM을 단일콘충전법으로 시행하였고 대조군은 근관충전시 전통적 방법인 AH plus (Dentsply DeTrey GmbH, Konstanz, Germany)를 연속파가압법으로 시행하였다. 평가항목은 술후 통증, 근관충전의 질, 임상적 결과로 하였다.

총 90명의 지원자와 96개의 치아가 등록되었으며 무작위로 실험군 혹은 대조군으로 분류되었다. 술후통증을 평가하기 위해 환자는 근관충전 4시간, 24시간, 48시간 이후 통증을 숫자통증척도를 통해 기록하였다. 근관충전의 질은 근관충전 직후 촬영된 치근단 방사선사진에 기반하여 sealer extrusion, root filling voids, 근관충전의 길이 세가지 항목을 통해 평가되었다. 적어도 6개월 이후 추적관찰이 이루어 졌으며 근관치료의 임상적 결과를 평가하기 위해 임상 및 방사선 검사가 시행되었다. 결과는 임상증상과 PAI score에 기반하여 healed, healing, diseased 이렇게 세가지로 분류되었고 healed와 healing은 성공으로 간주 두 군간 성공율에 차이가 있는지 통계적으로 분석하였다. 또한 Fisher’s exact test를 통해 근관치료의 성공에 유의한

영향을 끼치는 예측인자를 조사하였다.

총 64명의 환자와 70개의 치아가 추적관찰되었다. 결과적으로 두 군간 술후통증과 임상적 결과면에서는 차이가 없었다. 평균 17개월의 추적관찰 후, 실험군의 근관치료 성공율은 93.9%였으며 대조군에서는 91.9%였다. 그러나 실험군에서는 대조군에 비해 sealer extrusion이 유의하게 낮았다(P = 0.025). Sealer extrusion과 술후통증 유무가 임상적 결과의 예측인자로 밝혀졌다. ($P < 0.05$)

본 연구의 결과로 볼 때 단일콘충전법을 통한 WEM으로 근관충전을 하는 방법은 연속파가압법을 통한 AH plus으로 근관충전 하는 벙법을 대체할 수 있을 것으로 보인다.

핵심 되는 말 : 칼슘 실리케이트 계통 실러; White Endoseal MTA; 임상적 유용성; 근관 충전; 단일콘충전법