creative commons

COMMONS DEED

저작자표시-비영리-변경금지 2.0 대한민국

이용자는 아래의 조건을 따르는 경우에 한하여 자유롭게

- 이 저작물을 복제, 배포, 전송, 전시, 공연 및 방송할 수 있습니다.

다음과 같은 조건을 따라야 합니다:

저작자표시. 귀하는 원저작자를 표시하여야 합니다.

비영리. 귀하는 이 저작물을 영리 목적으로 이용할 수 없습니다.

변경금지. 귀하는 이 저작물을 개작, 변형 또는 가공할 수 없습니다.

- 귀하는, 이 저작물의 재이용이나 배포의 경우, 이 저작물에 적용된 이용허락조건을 명확하게 나타내어야 합니다.
- 저작권자로부터 별도의 허가를 받으면 이러한 조건들은 적용되지 않습니다.

**저작권법에 따른 이용자의 권리는 위의 내용에 의하여 영향을 받지 않습니다.**

이것은 이용허락규약(Legal Code)을 이해하기 쉽게 요약한 것입니다.

Disclaimer

dCollection

연세대학교
YONSEI UNIVERSITY

# Changes in mucogingival junction after an apically positioned flap with collagen matrix at sites with or without previous guided bone regeneration : a prospective comparative cohort study

**Kyung A Ko**

**Department of Dentistry**

**The Graduate School, Yonsei University**

연세대학교
YONSEI UNIVERSITY

# Changes in mucogingival junction after an apically positioned flap with collagen matrix at sites with or without previous guided bone regeneration : a prospective comparative cohort study

Directed by Professor Jung-Seok Lee

The Doctoral Dissertation
submitted to the Department of Dentistry
and the Graduate School of Yonsei University
in partial fulfillment of the requirements for the degree of
Ph.D. in Dental Science

Kyung A Ko

February 2021

연세대학교
YONSEI UNIVERSITY

This certifies that the Doctoral Dissertation of Kyung-A Ko is approved.

Thesis Supervisor: Jung-Seok Lee

Seong-Ho Choi

Ui-Won Jung

Jae-Kook Cha

Young Woo Song

The Graduate School

Yonsei University

December 2020

연세대학교
YONSEI UNIVERSITY

# 감사의 글

설렘과 떨림으로 시작했던 학위과정이 끝나가면서 지난 시간들이 주마등처럼 스쳐 지나갑니다.

먼저, 본 논문이 완성되기까지 부족한 저를 이끌어주시고 바쁘신 중에도 열정과 관심으로 지도해주신 이중석교수님께 진심으로 감사드립니다. 그리고 언제나 저에게 아낌없이 격려와 조언을 주신 조규성, 최성호, 김창성, 정의원, 차재국, 백정원, 송영우교수님과 바쁘신 와중에도 저의 학위논문 심사를 맡아주신 김성택, 이동운 교수님께 진심으로 감사 드립니다.

또한, 학위과정과 연구를 병행함에 있어 많은 도움을 준 치주과 연구원 선생님들, 의국원 및 치주과 선생님들, 치과대학 409-2 선생님들께 감사의 마음을 전합니다.

항상 언제나 힘이 되어준 사랑하는 영훈오빠, 세상 하나뿐인 우리 승현이에게 사랑과 고마움을 전합니다. 그리고 항상 저의 뒤에서 힘이 되어주고 응원해준 시부모님과 친정부모님, 두 언니들과 형부, 도련님과 동생, 조카들, 친구들에게도 사랑과 감사의 마음을 전합니다.

2021 년 2 월

저자 고경아

연세대학교
YONSEI UNIVERSITY

**Table of Contents**

List of Figures ····· iii

List of Table ····· iv

Abstract (English) ····· v

I. Introduction ····· 1

II. Materials & Methods ····· 4

1. Study Design ····· 4

2. Sample-size determination ····· 4

3. Participants ····· 5

4. Experimental timeline and surgical procedures ····· 5

5. Clinical examination ····· 6

6. Radiographic examinations ····· 8

7. Statistical analysis ····· 8

III. Results ····· 9

1. Clinical findings and measurements ····· 9

2. Changes in the MGJ/MM ····· 10

연세대학교
YONSEI UNIVERSITY

3. Thickness of the keratinized mucosa ····· 10

IV. Discussion ····· 11

V. Conclusion ····· 15

References ····· 16

Figure Legends ····· 23

Tables ····· 25

Figures ····· 26

Abstract (Korean) ····· 30

연세대학교
YONSEI UNIVERSITY

# List of Figures

**Figure 1.** Experimental and observational flow of the prospective cohort study.

**Figure 2.** Representative clinical photographs of groups GBR and nonGBR.

**Figure 3.** Representative digital scan images and CBCT images for measuring the MGJ and MM.

**Figure 4.** Measured changes in the MGJ, MM, and the width of the keratinized mucosa.

연세대학교
YONSEI UNIVERSITY

# List of Tables

**Table 1.** Descriptions of the patients and clinical outcome measurements.

연세대학교
YONSEI UNIVERSITY

Abstract

# Changes in mucogingival junction after an apically positioned flap with collagen matrix at sites with or without previous guided bone regeneration: a prospective comparative cohort study

**Kyung A-Ko, M.S.D**

*Department of Dentistry*
*The Graduate School, Yonsei University*

(Directed by Professor Jung-Seok Lee, D.D.S., M.S.D., PhD.)

**Purpose:** To assess changes in the position of the mucogingival junction (MGJ) after an apically positioned flap (APF) with collagen matrix performed at sites with or without previous guided bone regeneration (GBR).

**Materials and methods:** Dental implants were placed with or without GBR (group GBR or nonGBR) depending on the available ridge width in 30 patients with a

연세대학교
YONSEI UNIVERSITY

limited width of keratinized mucosa (MGJ placed more coronally than the expected prosthetic margin). An apically positioned flap with collagen matrix was performed in both groups. Changes in the position of the MGJ from the day of an apically positioned flap up to 1, 3, and 12 months thereafter were assessed on digital scans (primary endpoint). Secondary endpoints were the width and thickness of the keratinized mucosa, and the position of the mucosal margin.

**Results:** The position of the MGJ changed significantly from baseline to the first month, by 5.25±2.10 and 4.40±1.41 mm in groups GBR and nonGBR, respectively. Thereafter the position remained stable in both groups up to 1 year (changes from baseline of 5.46±2.28 and 4.58±1.92mm, respectively; $p$=0.34). The position of the mucosal margin did not differ between groups GBR and nonGBR (–1.57±2.04 and –1.75±2.08 mm, respectively; $p$=0.84); nor did the width of the keratinized mucosa (1.20±1.03 and 0.99±0.66 mm, $p$=0.91) or its thickness (1.28±0.44 and 1.40±0.78 mm, $p$=0.87).

**Conclusion:** Apically positioned flap combined with a collagen matrix results in a more apical position of the MGJ at sites with or without GBR. Following a coronal shift during the first month after the apical positioning of the flap, the level of the MGJ remained stable.

---

**Keywords:** dental implants, apically positioned flap, mucogingival junction, digital scan

연세대학교
YONSEI UNIVERSITY

# Changes in mucogingival junction after an apically positioned flap with collagen matrix at sites with or without previous guided bone regeneration: a prospective comparative cohort study

**Kyung A Ko, M.S.D**

*Department of Dentistry*
*The Graduate School, Yonsei University*

(Directed by Professor Jung-Seok Lee, D.D.S., M.S.D., PhD.)

## I. INTRODUCTION

Surgical interventions for increasing the width of keratinized tissue or the mucosa thickness aim to reduce inflammation and marginal bone loss around dental implants(Han et al. 1995; Brito et al. 2014; Thoma et al. 2017; Seo et al. 2019). Such interventions are

연세대학교
YONSEI UNIVERSITY

often performed after alveolar ridge augmentation procedures. This is mostly due to such augmentation procedures resulting in the mucogingival junction (MGJ) being repositioned more coronally as well as lingually/palatally to ensure primary wound closure. A subsequent surgical relocation of the MGJ is needed at augmented sites to allow for the physiologic movement of the oral vestibule and for the maintenance of peri-implant health(Yeung 2008; Adibrad et al. 2009). The soft tissues overlying implant sites that have received guided bone regeneration (GBR) consist of a thick layer of dense connective tissue around the membrane. It is expected that the covering soft tissues are then replaced by a keratinized tissue. However, this represents speculation since scientific evidence is lacking (Hammerle et al. 2008; Sanz & Vignoletti 2015; Cha et al. 2017; Jung et al. 2017).

The keratinization that is a specific feature of the masticatory oral mucosa is determined intrinsically by the underlying connective tissue, rather than functionally (Karring et al. 1971; Karring et al. 1975; Thoma et al. 2009). This claim is supported by preclinical studies demonstrating that the epithelial keratinization is re-established after transplantation of the connective-tissue layer from the masticatory mucosa(Karring et al. 1971; Karring et al. 1975). In addition, the characteristics of the recipient site can further affect keratinization. Those studies also observed a regenerated keratinized gingiva in the area adjacent to the teeth despite the complete removal of preexisting keratinized tissue. This has been explained by the regenerative capacity of the underlying periodontium. The characteristics of recipient sites can also be critical for the keratinized gingiva augmentation using soft-tissue substitutes (e.g., collagen matrices), which had been developed as alternatives to

연세대학교
YONSEI UNIVERSITY

autogenous connective tissue with the aim of reducing patient morbidity(Sanz et al. 2009; Schmitt et al. 2016).

Recent clinical studies have found substantial increases in the keratinized gingiva/mucosa when using collagen matrices with an apically positioned flap (APF) at sites having an underlying periodontium or periosteum(Lorenzo et al. 2012; McGuire & Scheyer 2014). However, it remains unknown whether a GBR procedure affects the outcomes of the APF as assessed by the increased amount of keratinized tissue and changes in the level of the MGJ. Previous preclinical studies histologically demonstrated a dense connective-tissue layer overlying GBR sites(Jung et al. 2013; Seo et al. 2019). Although a soft-tissue layer tightly incorporating porcine collagen membranes has been described as a 'periosteum-like tissue'(Mattout & Mattout 2000; Hammerle et al. 2008; Jung et al. 2017), other clinically retrieved histologic samples exhibited a scar-like dense fibrous tissue around the GBR membrane with minimal cellularity(Cucchi et al. 2019). Therefore, a procedure for increasing the width of keratinized tissue should be separately evaluated in the augmented alveolar ridge.

The aim of the present study was therefore to assess the changes in the position of the MGJ after an APF with collagen matrix, performed at sites with or without previous GBR.

연세대학교
YONSEI UNIVERSITY

# II. MATERIALS AND METHODS

## 1. Study design

The study was designed as a prospective comparative clinical trial performing an APF with a porcine-derived collagen matrix (Mucograft, Geistlich, Wolhusen, Switzerland) at (i) sites having received a GBR procedure using a collagen membrane (BioGide, Geistlich) and a deproteinized bovine bone mineral (DBBM; BioOss, Geistlich) (group GBR) and (ii) sites without GBR (group nonGBR). The clinical protocol followed the Helsinki Declaration (version revised in Tokyo in 2004) and Good Clinical Practice Guidelines, and was approved by the Institutional Review Board for clinical research at the Dental Hospital of Yonsei University (approval number 2-2016-0032). The manuscript was prepared according to STROBE guidelines.

## 2. Sample-size determination

The required sample size was determined by a power calculation with a 5% significance level and a statistical power of 90%, using an expected mean difference in the position of the MGJ of 1 mm. This value was chosen arbitrarily based on a previous study finding a standard deviation of 0.74 mm(McGuire & Scheyer 2014). The sample size was 15 in each group based on an assumed maximum dropout rate of 30%.

연세대학교
YONSEI UNIVERSITY

## 3. Participants

Patients planned to receive an implant in a partially edentulous ridge with a limited width of keratinized/attached mucosa were screened based on the following inclusion criteria: >18 years old, able to understand the protocol, and providing signed informed consent. The limited width of keratinized/attached mucosa was defined by the case that MGJ was placed more coronally than the expected prosthetic margin. The exclusion criteria were uncontrolled metabolic diseases, genetic connective-tissue disorders (Marfan syndrome or Ehlers-Danlos syndrome), systemic lupus erythematosus, scleroderma, radiotherapy history in the oral or maxillofacial region during the previous 1 year, allergy to collagen, being pregnant or lactating, having cardiac procedures or a surgery history within the previous 6 months, receiving bisphosphonate medication within the previous 4 months, or dental implants with minimal primary stability (final insertion torque <20 N/cm). Furthermore, only sites with simultaneous horizontal bone augmentation were considered for inclusion in group GBR.

At the time of implant placement, patients were assigned to either group GBR (in case of a GBR procedure being necessary) or group nonGBR (when no GBR was necessary).

## 4. Experimental timeline and surgical procedures

All participants visited at five time points (Fig. 1): (1) dental implant installation in all areas of the maxilla/mandible with or without GBR, (2) for APF in conjunction with collagen matrix at 3 months after implant surgery and/or GBR, and (3) 1 month, (4) 3

연세대학교
YONSEI UNIVERSITY

months, and (5) 1 year after the APF. At the first visit, dental implants were installed at the optimal location after elevating a full-thickness flap. Sites showing buccal dehiscence defects or a significantly reduced buccal volume were assigned to group GBR, in which a GBR procedure was performed using DBBM and a collagen membrane. The implants in both groups were submerged, and primary closure was achieved with an internal mattress suture technique. The sutures were removed 1 week later. Three months thereafter, a partial-thickness apically positioned flap was prepared while leaving 1 mm of keratinized tissue in the apical flap. The flap was positioned in a more-apical position in line with the level of the adjacent MGJ (neighboring teeth), and sutured on the periosteum at nonGBR sites or on the thick layer of dense connective tissue in group GBR (Fig. 2). Abutment connection was performed through a punch technique, and the healing abutment was connected. A collagen matrix was placed to cover the area exposed by the apically positioned flap, and fixed with interrupted sutures to the periosteum or the connective-tissue layer. Clinical and radiographic examinations were performed at visits 3–5. Prosthesis placement was planned at 2 months after the APF (i.e., 5 months after implant installation).

## 5. Clinical examination

Digital scanning was performed at visits 2–5 (Fig. 1 and 3A–D) and measured by one examiner. The entire maxilla or mandible was scanned in three dimensions (including the surrounding mucosa) using a digital oral scanner (TRIOS 3, 3Shape, Copenhagen,

연세대학교
YONSEI UNIVERSITY

Denmark), which allowed precise measurements of the clinical dimensions of the keratinized mucosa and the level of the MGJ. Clinical parameters were measured on the scan images using computer software (Rapidform 2004, Inus Technology, Seoul, Korea). In addition, the distance between the surgically relocated MGJ and the mucosal margin (MM) was clinically measured using a periodontal probe (UNC15, Hu-Friedy, Illinois, USA). In order to measure the serial changes in the parameters, all of the three-dimensional (3D) scan images (as obtained immediately and at 1, 3, and 12 months after the APF) were merged using computer software (Geomagic Verify 16, 3D Systems, South Carolina, USA) employing an automated best-fit alignment option and landmarks of the adjacent residual teeth (occlusal and buccal/lingual/lateral surfaces; Fig. 3A–G). The following clinical parameters were digitally measured at the center of the implant site on the merged images:

1. Surgical correction by APF: the distance from the preoperative MGJ to the MGJ surgically relocated by APF.
2. Change in the MGJ (primary endpoint): the distance between the MGJ at each follow-up visit and MGJ surgically relocated by the APF (visit 2). The proportional value was calculated based on the surgical correction.
3. Change in the MM: the distance between the MM at each follow-up visit and the MM immediately after the APF and the healing abutment connection (visit 2).

연세대학교
YONSEI UNIVERSITY

4. Width of the keratinized mucosa: the distance from the MM to the MGJ on the scan images at each visit. The proportional value at each visit was calculated based on the postoperative keratinized mucosa width.

## 6. Radiographic examinations

Cone-beam computed tomography (CBCT) scans were obtained immediately after an apically positioned flap (visit 2) and at the 1-year follow-up (visit 5). In order to assess the thickness of the soft tissue at the surgical site, a radiopaque paste (Sealapex, Kerr, Bioggio, Switzerland) was applied to the tissue surface before performing CBCT (Fig. 3H–J). The following measurements were performed at the center of the implant site:

5. Mucosa thickness: the distance from the bottom of the radiopaque paste to the outer surface of the alveolar ridge (bone contour) on the CBCT images obtained at visits 2 and 5.

## 7. Statistical analysis

The normality of the data was evaluated using the Shapiro-Wilk test ($P>0.05$), and the sphericity was evaluated by Mauchly's test ($\alpha<0.05$) and Greenhouse Geisser correction (epsilon value). Repeated measurement of ANOVA was used to evaluate the effects of the intervention (GBR) and time on each outcome. Groups GBR and nonGBR were compared at the same visit using the Mann-Whitney U-test. The significance cutoff was set at 0.05(SPSS statistics 23, IBM, New York, USA).

연세대학교
YONSEI UNIVERSITY

# III. RESULTS

## 1. Clinical findings and measurements

This study consecutively enrolled 30 participants whose demographic characteristics are given in Table 1. One participant in group nonGBR was lost during the follow-up period due to an adverse systemic condition that was unrelated to the study. All sites showed uneventful healing, with the prostheses being placed 1 month after the APF in all except three patients in each of groups GBR and nonGBR, in whom the prostheses were placed after 3 months. The surgically exposed mucosa due to APF (distance from the preexisting MGJ to the surgically relocated MGJ) in groups GBR and nonGBR measured 7.00±1.82 and 5.90±1.03 mm, respectively. Following the placement of the collagen matrix and suturing, the distance from the MM to the surgically relocated MGJ was 7.71±1.42 and 7.40±1.35 mm in groups GBR and nonGBR, respectively; (p=0.51). The width of the keratinized mucosa decreased mainly during the initial 1 month of healing, after which it decreased more slowly (Fig. 4). The widths in groups GBR and nonGBR were 2.52±1.57 mm (32.96±21.28%) and 2.25±1.68 mm (29.55±20.49%), respectively; (p=0.45), at 1 month, 1.83±1.30 mm (24.78±18.76%) and 1.80±1.43 mm (24.58±18.92%) at 3 months; (p=0.72), and 1.20±1.03 mm (16.81±13.18%) and 0.99±0.66 mm (13.68±9.44%) at 12 months; (p=0.90).

연세대학교
YONSEI UNIVERSITY

## 2. Changes in the MGJ/MM (digital measurements on scan images)

The position of the MGJ changed significantly to a more-coronal position ($p<0.01$) during the first month, and remained stable thereafter (Fig. 4). The changes in groups GBR and nonGBR from the time of the APF were 5.25±2.1 mm (75.89±27.69%) and 4.40±1.41 mm (75.58±21.54%), respectively; ($p=0.30$), at 1 month, followed by much smaller changes of -0.003±0.710 mm (0.44±11.44%) and –0.29±1.27 mm (3.20±27.03%) at 3 months, and 0.22±0.95 mm (3.89±13.34%) and 0.47±1.91 mm (7.08±38.36%) at 1 year. There were no statistically significant differences between groups and observation periods ($p>0.05$).

The MM continuously shifted apically during the 1-year observation period in groups GBR and nonGBR (Fig. 4), with the main changes occurring during the first 3 months: by –0.50±2.04 and –0.52±1.80 mm, respectively, at 1 month; ($p=1.00$), –1.15±2.01 and –1.41±1.87 mm at 3 months; ($p=0.75$), and –1.57±2.04 and –1.75±2.08 mm at 1 year; ($p=0.84$) (negative values indicate an apical shift).

## 3. Thickness of the keratinized mucosa

The mucosa thickness remained stable in both groups GBR and nonGBR during the 1-year follow-up, being 1.36±0.64 and 1.33±0.51 mm, respectively; ($p=0.66$), after the APF, and 1.28±0.44 and 1.40±0.78 mm at 1 year; ($p=0.87$).

연세대학교
YONSEI UNIVERSITY

# IV. DISCUSSION

The present clinical trial was designed to determine whether or not the newly formed periosteum-like tissue covering GBR sites clinically affects the formation of keratinized mucosa and/or the position of the MGJ after an APF. The underlying connective tissue affects keratinization of the mucosal epithelium when placed directly on the periosteum(Karring et al. 1975). However, there is a lack of scientific evidence about sites having received a GBR procedure prior to an APF; in such cases an APF is performed within a periosteum-like tissue overlying the GBR membrane. The present study comparing the APF at sites with or without prior GBR predominantly demonstrated (i) a substantial relapse of the MGJ during the first month of healing, but a stable position thereafter, (ii) a minimal increase in the width of the keratinized mucosa due to the coronal movement of the MGJ and an apical movement of the MM in both groups, and (iii) no significant differences between the two groups during the 1-year follow-up.

The present study performed digital measurements to assess the level of the MGJ during a 1-year follow-up. Previous clinical studies have evaluated various gingival augmentation techniques by clinically measuring the width of keratinized mucosa only or at the level of the MGJ relative to the position of teeth (incisal line or cementoenamel junction)(Herford et al. 2010; McGuire & Scheyer 2010, 2014; Schmitt et al. 2016). These clinical studies had limitations when evaluating APF, especially for the period before the final prosthetic treatment due to the reference point being unstable. The present results demonstrated a

연세대학교
YONSEI UNIVERSITY

rapid relapse of the MGJ during the first 1 month and a stable position thereafter in both groups. This contrasts with the width of the keratinized mucosa changing continuously, mainly due to a more-apical shift of the MM. The pattern of MGJ remaining stable after the initial healing in both groups could be related to previous results for other mucogingival surgeries showing the same pattern of stable maintenance in dimension or the location of the mucogingival complex after 1 month(Egli et al. 1975; Ainamo 1978; Ainamo et al. 1992; Gurgan et al. 2004; Sanz et al. 2009; Thoma et al. 2020). Although the mean change in the MGJ level was slightly larger (by 1 mm) in group GBR than in group nonGBR, there was no statistically significant difference, nor in the proportions of relapses from the time of the surgical correction by the APF (78.83±32.68% and 79.47±36.65% for groups GBR and nonGBR, respectively). In summary, the newly formed periosteum-like tissue at a GBR site might play a role comparable to that of the pristine periosteum in terms of enhancing the width of the keratinized mucosa using an apically positioned flap in cases where the exposed area is covered with a collagen matrix.

The increases in the widths of keratinized tissue (1.20±1.03 and 0.99±0.66 mm in groups GBR and nonGBR, respectively) were slightly lower than those in a previous study that applied the same procedure of APF and coverage with a collagen matrix(Sanz et al. 2009). These differences could be caused by the use of different measuring methodologies and observation periods, including the change in the mucosa following prosthesis placement. The present study assessed the width of the keratinized mucosa using a digital approach on 3D scan images rather than by making direct clinical measurements. Our previous study

연세대학교
YONSEI UNIVERSITY

comparing direct clinical and digital measurements of the keratinized mucosa dimension with *in situ* histologic measurements revealed a higher accuracy and reliability of the digital measurements and a tendency for overestimation in clinical measurements (Jung-Seok et al. 2020). Inherent errors of clinical measurements related to the placing a periodontal probe and/or reading a scale could be reasons for results differing between the present and the previous study. In addition, the apical repositioning of the MM occurred following prosthesis placement (Fig. 4). This change might have reduced the dimension of the keratinized mucosa to a greater extent than in the previous study showing a stable MM(Park 2006).

Some researchers had reported the presence of periosteum-like tissue in the neogenetic connective-tissue layer around the GBR membrane(Gutta et al. 2009; Dimitriou et al. 2012). However, previous histology investigations(Proussaefs & Lozada 2006; Jung et al. 2017) revealed fibrous capsulation with a dense fiber network and no cell-rich layer (osteoblasts or preosteoblasts). This represents a critically different characteristic from the pristine periosteum(Mattout & Mattout 2000; Cho et al. 2011). Nevertheless, GBR sites in the present study also found an immobile keratinized mucosa and a similar relocation of the MGJ in both groups. Even this minimal increase in keratinized mucosa is expected to be favorable for the maintenance of peri-implant health(Chung et al. 2006; Evans & Chen 2008; Zigdon & Machtei 2008; Seo et al. 2019).

There are some limitations in the present study. First, the effect of collagen matrix can cover up the keratinized tissue healing potential from both sites with and without the

연세대학교
YONSEI UNIVERSITY

previous GBR. Despite the clinical advantages of the use of collagen matrix in previous clinical studies(Sanz et al. 2009; Thoma et al. 2010; Thoma et al. 2017), the present results should be interpreted with cautions due to the absence of direct comparison with the group of APF without collagen matrix. Second, despite more accuracy and reliability of digital measuring, the baseline data (postoperative MGJ after APF) was taken by the conventional measuring method due to bleeding on the surgical site. Overestimation tendency within 1mm in the conventional measuring should be considered for the interpretation of the alteration of MGJ level from the baseline(APF).

Within the limitations of the present study, the clinical trial involving two cohort sites (with or without GBR) showed a dramatic relapse of coronal relocation of the MGJ during the initial 1 month, but stable maintenance thereafter for 1 year, and with comparable findings for both cohorts. Thus it is suggested that the combination of the collagen matrix with the APF can relocate and stably maintain the MGJ around the dental implant at sites that have received GBR.

연세대학교
YONSEI UNIVERSITY

# V. CONCLUSION

Apically positioned flap combined with a collagen matrix results in a more-apical position of the MGJ comparably at sites with or without GBR. Following a coronal shift, during the first month from an apically positioned flap, the level of the MGJ remains stable.

연세대학교
YONSEI UNIVERSITY

# REFERENCE

Adibrad, M., Shahabuei, M. & Sahabi, M. (2009) Significance of the width of keratinized mucosa on the health status of the supporting tissue around implants supporting overdentures. *The Journal of Oral Implantology* **35**: 232-237. doi:10.1563/aaid-joi-d-09-00035.1

Ainamo, A. (1978) Influence of age on the location of the maxillary mucogingival junction. *Journal of Periodontal Research* **13**: 189-193. doi:10.1111/j.1600-0765.1978.tb00169.x

Ainamo, A., Bergenholtz, A., Hugoson, A. & Ainamo, J. (1992) Location of the mucogingival junction 18 years after apically repositioned flap surgery. *Journal of Clinical Periodontology* **19**: 49-52. doi:10.1111/j.1600-051x.1992.tb01148.x

Brito, C., Tenenbaum, H.C., Wong, B.K.C., Schmitt, C. & Nogueira-Filho, G. (2014) Is keratinized mucosa indispensable to maintain peri-implant health? A systematic review of the literature. *Journal of Biomedical Materials Research Part B: Applied Biomaterials* **102**: 643-650. doi:10.1002/jbm.b.33042

Cha, J.K., Joo, M.-J., Yoon, S., Lee, J.-S., Choi, S.-H. & Jung, U.-W. (2017) Sequential healing of onlay bone grafts using combining biomaterials with cross-linked collagen in dogs. *Clinical Oral Implants Research* **28**: 76-85. doi:10.1111/clr.12763

Cho, E.-H., Park, J.-C., Cha, J.-K., Kim, Y.-T., Jung, U.-W., Kim, C.-S., Choi, S.-H. & Kim, C.-K. (2011) Dimensional change of the healed periosteum on surgically created defects. *Journal of Periodontal & Implant Science* **41**: 176-184.

연세대학교
YONSEI UNIVERSITY

Chung, D.M., Oh, T.-J., Shotwell, J.L., Misch, C.E. & Wang, H.-L. (2006) Significance of Keratinized Mucosa in Maintenance of Dental Implants With Different Surfaces. *Journal of Periodontology* **77**: 1410-1420. doi:10.1902/jop.2006.050393

Cucchi, A., Sartori, M., Aldini, N.N., Vignudelli, E. & Corinaldesi, G. (2019) A Proposal of Pseudo-periosteum Classification After GBR by Means of Titanium-Reinforced d-PTFE Membranes or Titanium Meshes Plus Cross-Linked Collagen Membranes. *The International Journal of Periodontics & Restorative Dentistry* **39**: e157-e165. doi:10.11607/prd.3598 10.11607/prd.e3598

Dimitriou, R., Mataliotakis, G.I., Calori, G.M. & Giannoudis, P.V. (2012) The role of barrier membranes for guided bone regeneration and restoration of large bone defects: current experimental and clinical evidence. *BMC Medicine* **10**: 81. doi:10.1186/1741-7015-10-81

Egli, U., Vollmer, W.H. & Rateitschak, K.H. (1975) Follow-up studies of free gingival grafts. *Journal of Clinical Periodontology* **2**: 98-104. doi:10.1111/j.1600-051x.1975.tb01730.x

Evans, C.D.J. & Chen, S.T. (2008) Esthetic outcomes of immediate implant placements. *Clinical Oral Implants Research* **19**: 73-80. doi:10.1111/j.1600-0501.2007.01413.x

Gurgan, C.A., Oruc, A.M. & Akkaya, M. (2004) Alterations in location of the mucogingival junction 5 years after coronally repositioned flap surgery. *Journal of Periodontology* **75**: 893-901. doi:10.1902/jop.2004.75.6.893

Gutta, R., Baker, R.A., Bartolucci, A.A. & Louis, P.J. (2009) Barrier Membranes Used for Ridge Augmentation: Is There an Optimal

연세대학교
YONSEI UNIVERSITY

Pore Size? *Journal of Oral and Maxillofacial Surgery* **67**: 1218-1225. doi:https://doi.org/10.1016/j.joms.2008.11.022

Hammerle, C.H., Jung, R.E., Yaman, D. & Lang, N.P. (2008) Ridge augmentation by applying bioresorbable membranes and deproteinized bovine bone mineral: a report of twelve consecutive cases. *Clinical Oral Implants Research* **19**: 19-25. doi:10.1111/j.1600-0501.2007.01407.x

Han, T.J., Klokkevold, P.R. & Takei, H.H. (1995) Strip gingival autograft used to correct mucogingival problems around implants. *The International Journal of Periodontics & Restorative Dentistry* **15**: 404-411.

Herford, A.S., Akin, L., Cicciu, M., Maiorana, C. & Boyne, P.J. (2010) Use of a Porcine Collagen Matrix as an Alternative to Autogenous Tissue for Grafting Oral Soft Tissue Defects. *Journal of Oral and Maxillofacial Surgery* **68**: 1463-1470. doi:https://doi.org/10.1016/j.joms.2010.02.054

Jung-Seok, L., Yoon-Sun, J., Strauss, F.-J., Jung, H.-I. & Gruber, R. (2020) Digital scanning is more accurate than using a periodontal probe to measure the keratinized tissue width. *Scientific Reports (Nature Publisher Group)* **10** doi:http://dx.doi.org/10.1038/s41598-020-60291-0

Jung, U.W., Cha, J.K., Vignoletti, F., Nunez, J., Sanz, J. & Sanz, M. (2017) Simultaneous lateral bone augmentation and implant placement using a particulated synthetic bone substitute around chronic peri-implant dehiscence defects in dogs. *Journal of Clinical Periodontology* **44**: 1172-1180. doi:10.1111/jcpe.12802

연세대학교
YONSEI UNIVERSITY

Jung, U.W., Lee, J.S., Lee, G., Lee, I.K., Hwang, J.W., Kim, M.S., Choi, S.H. & Chai, J.K. (2013) Role of collagen membrane in lateral onlay grafting with bovine hydroxyapatite incorporated with collagen matrix in dogs. *Journal of Periodontal & Implant Science* **43**: 64-71. doi:10.5051/jpis.2013.43.2.64

Karring, T., Lang, N.P. & Loe, H. (1975) The role of gingival connective tissue in determining epithelial differentiation. *Journal of Periodontal Research* **10**: 1-11. doi:10.1111/j.1600-0765.1975.tb00001.x

Karring, T., Ostergaard, E. & Loe, H. (1971) Conservation of tissue specificity after heterotopic transplantation of gingiva and alveolar mucosa. *Journal of Periodontal Research* **6**: 282-293. doi:10.1111/j.1600-0765.1971.tb00619.x

Lorenzo, R., García, V., Orsini, M., Martin, C. & Sanz, M. (2012) Clinical efficacy of a xenogeneic collagen matrix in augmenting keratinized mucosa around implants: a randomized controlled prospective clinical trial. *Clinical Oral Implants Research* **23**: 316-324. doi:10.1111/j.1600-0501.2011.02260.x

Mattout, P. & Mattout, C. (2000) Conditions for success in guided bone regeneration: retrospective study on 376 implant sites. *Journal of Periodontology* **71**: 1904-1909. doi:10.1902/jop.2000.71.12.1904

McGuire, M.K. & Scheyer, E.T. (2010) Xenogeneic Collagen Matrix With Coronally Advanced Flap Compared to Connective Tissue With Coronally Advanced Flap for the Treatment of Dehiscence-Type Recession Defects. *Journal of Periodontology* **81**: 1108-1117. doi:10.1902/jop.2010.090698

연세대학교
YONSEI UNIVERSITY

McGuire, M.K. & Scheyer, E.T. (2014) Randomized, Controlled Clinical Trial to Evaluate a Xenogeneic Collagen Matrix as an Alternative to Free Gingival Grafting for Oral Soft Tissue Augmentation. *Journal of Periodontology* **85**: 1333-1341. doi:10.1902/jop.2014.130692

Park, J.-B. (2006) Increasing the Width of Keratinized Mucosa Around Endosseous Implant Using Acellular Dermal Matrix Allograft. *Implant Dentistry* **15**: 275-281. doi:10.1097/01.id.0000227078.70869.20

Proussaefs, P. & Lozada, J. (2006) Use of Titanium Mesh for Staged Localized Alveolar Ridge Augmentation: Clinical and Histologic-Histomorphometric Evaluation. *The Journal of Oral Implantology* **32**: 237-247. doi:10.1563/1548-1336(2006)32[237:Uotmfs]2.0.Co;2

Sanz, M., Lorenzo, R., Aranda, J.J., Martin, C. & Orsini, M. (2009) Clinical evaluation of a new collagen matrix (Mucograft prototype) to enhance the width of keratinized tissue in patients with fixed prosthetic restorations: a randomized prospective clinical trial. *Journal of Clinical Periodontology* **36**: 868-876. doi:10.1111/j.1600-051X.2009.01460.x

Sanz, M. & Vignoletti, F. (2015) Key aspects on the use of bone substitutes for bone regeneration of edentulous ridges. *Dental Materials* **31**: 640-647. doi:https://doi.org/10.1016/j.dental.2015.03.005

Schmitt, C.M., Moest, T., Lutz, R., Wehrhan, F., Neukam, F.W. & Schlegel, K.A. (2016) Long-term outcomes after vestibuloplasty with a porcine collagen matrix (Mucograft((R)) ) versus the free gingival graft: a comparative prospective clinical trial. *Clinical Oral Implants Research* **27**: e125-e133. doi:10.1111/clr.12575

연세대학교
YONSEI UNIVERSITY

Seo, G.Y., Thoma, D.S., Jung, U.W. & Lee, J.S. (2019) Increasing the tissue thickness at implant sites using guided bone regeneration and an additional collagen matrix: Histologic observations in beagle dogs. *Journal of Biomedical Materials Research. Part B, Applied Biomaterials* **107**: 741-749. doi:10.1002/jbm.b.34168

Thoma, D.S., Benić, G.I., Zwahlen, M., Hämmerle, C.H.F. & Jung, R.E. (2009) A systematic review assessing soft tissue augmentation techniques. *Clinical Oral Implants Research* **20**: 146-165. doi:10.1111/j.1600-0501.2009.01784.x

Thoma, D.S., Jung, R.E., Schneider, D., Cochran, D.L., Ender, A., Jones, A.A., Görlach, C., Uebersax, L., Graf-Hausner, U. & Hämmerle, C.H.F. (2010) Soft tissue volume augmentation by the use of collagen-based matrices: a volumetric analysis. *Journal of Clinical Periodontology* **37**: 659-666. doi:10.1111/j.1600-051X.2010.01581.x

Thoma, D.S., Lim, H.-C., Paeng, K.-W., Kim, M.J., Jung, R.E., Hämmerle, C.H.F. & Jung, U.-W. (2020) Augmentation of keratinized tissue at tooth and implant sites by using autogenous grafts and collagen-based soft-tissue substitutes. *Journal of Clinical Periodontology* **47**: 64-71. doi:https://doi.org/10.1111/jcpe.13194

Thoma, D.S., Naenni, N., Benic, G.I., Hämmerle, C.H.F. & Jung, R.E. (2017) Soft tissue volume augmentation at dental implant sites using a volume stable three-dimensional collagen matrix – histological outcomes of a preclinical study. *Journal of Clinical Periodontology* **44**: 185-194. doi:10.1111/jcpe.12635

Yeung, S. (2008) Biological basis for soft tissue management in implant dentistry. *Australian Dental Journal* **53**: S39-S42.

연세대학교
YONSEI UNIVERSITY

doi:10.1111/j.1834-7819.2008.00040.x

Zigdon, H. & Machtei, E.E. (2008) The dimensions of keratinized mucosa around implants affect clinical and immunological parameters. *Clinical Oral Implants Research* **19**: 387-392. doi:10.1111/j.1600-0501.2007.01492.x

연세대학교
YONSEI UNIVERSITY

# Figure legends

**Figure 1.** Experimental and observational flow of the prospective cohort study. Thirty patients received dental implants with or without a guided bone regeneration (GBR) procedure in the buccal region (15 in each of groups GBR and nonGBR). At 3 months from the dental implant surgery (0), an apically positioned flap (APF) combined with collagen matrix coverage was performed. Digital oral scanning was performed before an APF, and the distance between the surgically relocated mucogingival junction (MGJ) and the mucosal margin (MM) were clinically measured using a periodontal probe after an APF. Digital oral scanning was performed at 1, 3, and 12 months after an APF to measure changes in the MGJ and MM. Cone-beam computed tomography (CBCT) was used to measure the thickness of the mucosa immediately and 12 months after the surgery.

**Figure 2.** Representative clinical photographs of groups GBR and nonGBR. Both sites showed a restricted width of keratinized mucosa in the edentulous area, and an apically positioned flap was performed in conjunction with coverage of a collagen matrix. The MGJ was significantly shifted more coronally after 1 month, but remained there for up to 1 year. However, the MM continuously shifted to the apical direction due to the prosthesis placement and the tissue adjustment.

연세대학교
YONSEI UNIVERSITY

**Figure 3.** Representative digital scan images and CBCT images for measuring the MGJ and MM (at the same site as the GBR site from Fig. 2). Serial scan images from baseline (APF), and after 1, 3, and 12 months of observation were merged (A to F), and measurements were performed on the buccopalatal section at the center of the implant (G). The MGJ was marked by the color difference on the scan images using computer software before merging the images, and the distance between each of the marked MGJs (arrows in the panel G) was measured for the MGJ on the merged image. CBCT images were obtained for screening (H), and immediately (I) and 1 year (J) after APF. The mucosa thickness [the distance between the alveolar bone and the bottom of the radiopaque marking (arrow heads)] was measured immediately and 1 year after APF (I and J).

**Figure 4.** Measured changes in the MGJ, MM, and the width of the keratinized mucosa. The lines and data points for groups GBR and nonGBR show similar patterns in the changes in the clinical parameters. The MGJ significantly shifted to the coronal direction during the initial 1 month after APF, but then remained stable for up to 1 year. The MM and the keratinized mucosa width continuously shifted apically during the 1-year follow-up. The decrease in the keratinized mucosa width from 3 months after APF was caused by the apical shifts of the MM. Black: group GBR, red: group nonGBR.

연세대학교
YONSEI UNIVERSITY

# Tables

**Table 1.** Descriptions of the patients and clinical outcome measurements.

| | Group | |
|---|---|---|
| | nonGBR | GBR |
| Patients | | |
| Age, years | 61.7±16.0 | 52.1±15.7 |
| Sex, females/males | 10(66.7%)/5(33.3%) | 11(73.3%)/4(26.7%) |
| Sites | | |
| Maxilla/mandible | 3(20.0%)/12(80.0%) | 6(37.5%)/10(62.5%) |
| Incisor/premolar/molar | 0(0.0%)/2(13.3%)/13(86.7%) | 3(18.8%)/5(31.2%)/8(50.0%) |
| Baseline condition in surgical sites | | |
| Surgical correction by APF* | 5.90±1.03 mm | 7.00±1.82 mm |

Data are mean±standard-deviation or *N* values. GBR, guided bone regeneration. APF, apically positioned flap.
*Distance from the preexisting mucogingival junction (MGJ) to the surgically fixed mucosal margin (MM) after APF.

연세대학교
YONSEI UNIVERSITY

# Figures

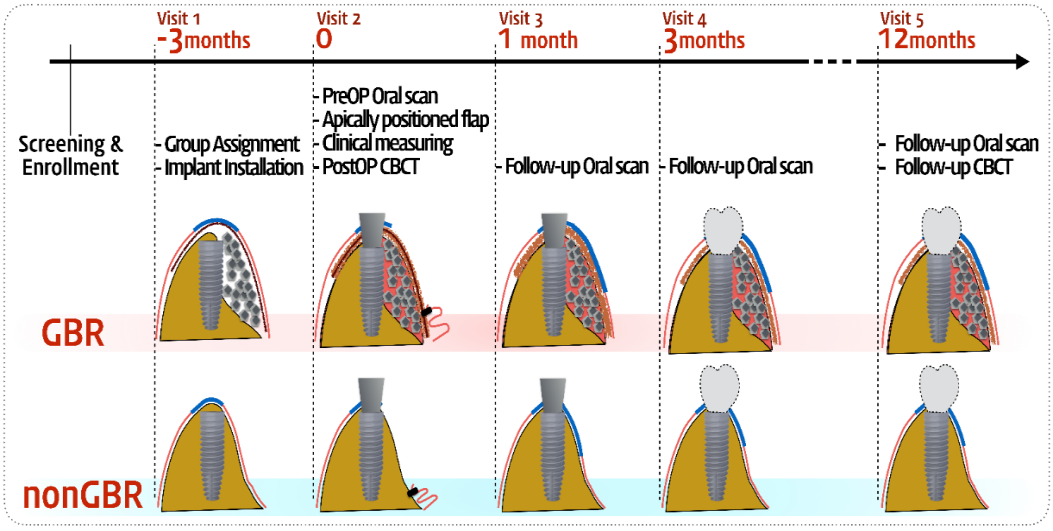


**Figure 1**

연세대학교
YONSEI UNIVERSITY

**Figure 2**

연세대학교
YONSEI UNIVERSITY

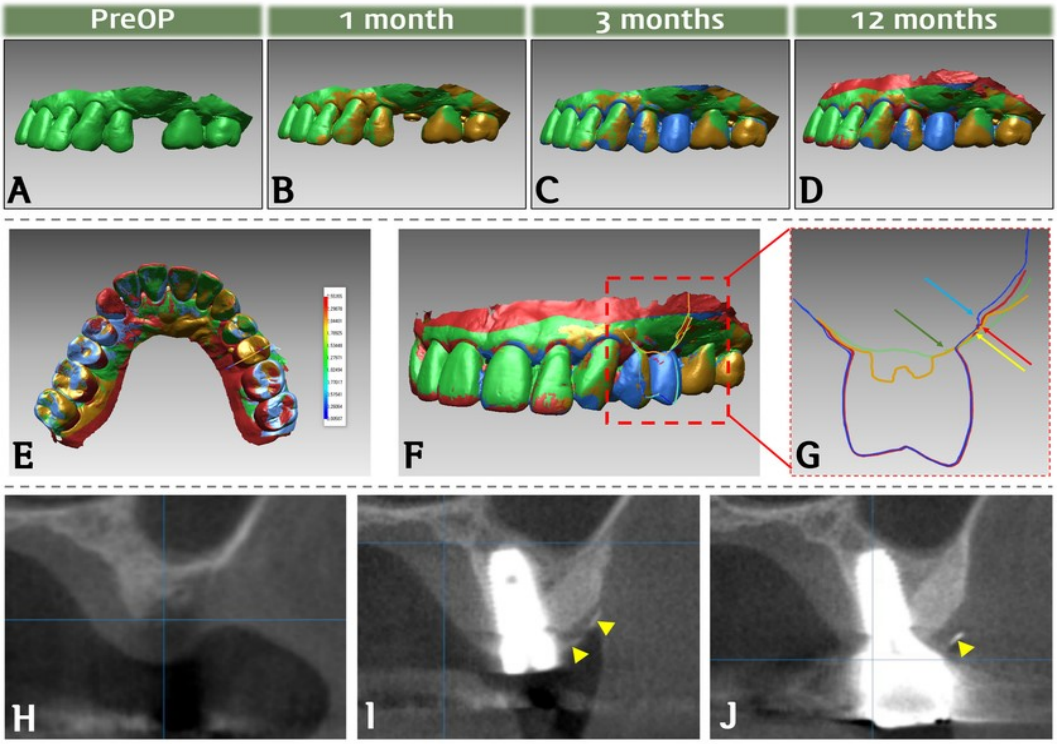


**Figure 3**

연세대학교
YONSEI UNIVERSITY

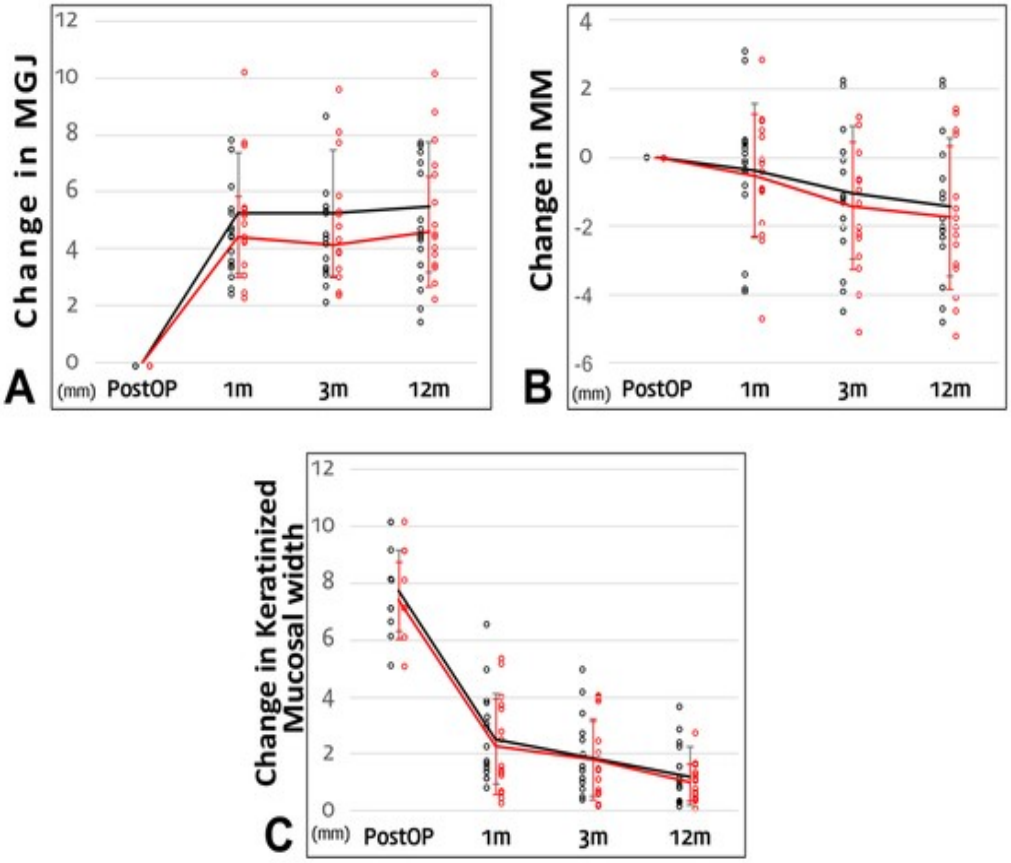


**Figure 4**

연세대학교
YONSEI UNIVERSITY

국문요약

# 골유도재생술 유무에 따라 콜라겐 매트릭스를 이용한 근단변위판막술 후 치은-점막 경계부의 변화 : 전향적 비교 코호트 연구

<지도교수 **이 중 석**>

연세대학교 대학원 치의학과

**고 경 아**

각화된 조직의 두께와 폭을 늘리기 위한 외과적 술식은 치과 임플란트 주변 염증 및 변연골 손실을 줄이는 것을 목표로 한다. 골유도재생술의 경우 일차적 상처 봉합을 위해 치은-점막 경계부가 더 치관쪽으로 재배치되기 때문에 이후 임플란트 주변 건강 유지를 위해 근단변위판막술과 같은 외과적 술식이 필요하다. 골유도재생술 후 조직학적으로 조밀한 결합조직층이 관찰됐으며 고정된 조직층에 연조직대체재(콜라겐 매트릭스)를 이용한 근단변위판막술을 할 경우 각화치은을 생성을 기대할 수 있으나 이에 관련된 과학적 근거가 부족하다. 또한, 일부 연구에서 콜라겐 매트릭스를 이용한 근단변위판막술 후 각화된 조직의 두께와 폭이 늘어난다고 보고되었지만,

연세대학교
YONSEI UNIVERSITY

골유도재생술이 근단변위판막술 결과에 영향을 미치는가에 대해서는 평가가 필요하다. 따라서 본 연구의 목적은 골유도재생술 유무에 따라 콜라겐 매트릭스를 이용한 근단변위판막술 후 치은-점막 경계부의 위치변화에 대해 평가하는 것이다.

연세대학교 치과병원 치주과를 내원한 환자들 중에서 제한된 각화치은 폭을 포함한 부분무치악 부위 임플란트 수술 계획된 30 명 환자 중 골유도재생술이 필요한 그룹(실험군)과 그렇지 않은 그룹(대조군)으로 각각 15 명씩 나누어 진행하였다. 두 그룹 모두 방문 일정은 동일했으며, 치은-점막 경계부 변화는 근단변위판막술 직후에는 치주 probe 를 이용하고 1 달, 3 달, 12 개월 방문에는 디지털 스캐너를 이용하여 측정한 후 데이터 중첩하여 평가하였고, 치은 점막의 두께는 CBCT 를 이용하여 근단변위판막술 직후, 12 개월 뒤 측정 및 평가하였다. 두 그룹간에 대한 비교는 비모수검정(Mann-Whitney U-test)을 진행하였고 그룹 내 결과값에 대해서는 시점에 따라 반복측정 분산분석(RM-ANOVA)하였다.

연구 결과, 치은-점막 경계부 위치는 근단변위판막술 후 1 개월동안 실험군 및 대조군에서 각각 5.25±2.10(75.89±27.69%) 및 4.40±1.41 mm(75.58±21.54%)로 크게 변화되었으나, 그 후 1 년동안 5.46±2.28(78.83±32.68%) 및 4.58±1.92mm(79.47±36.65%)로 안정적으로 유지되었다. 뿐만 아니라, 각화된 점막 너비, 두께도 두 그룹 모두 1 년동안 차이가 없었으며, 통계적으로

연세대학교
YONSEI UNIVERSITY

유의하지 않았다(P>0.05).

본 연구는 디지털 데이터를 통해 골유도재생술 유무에 관계없이 근단변위판막술 후 치은-접막경계부 위치가 1 개월동안 치관쪽으로 위치하고 이후 안정적인 것을 확인하였다. 임상적으로 평가할 수 없는 연조직 변화에 대해 디지털 데이터 중첩을 통해 확인함으로써, 이 방법은 연조직 변화에 대한 평가로 유용하게 활용될 것으로 생각된다.

**핵심되는 말:** 임플란트, 근단변위판막술, 치은-점막경계부, 디지털 스캔