



유전자 *CYP2C9* 및 *VKORC1* 변이로 인한 와파린 과민성을 동반한 가와사키병 환자 1례

이명섭 · 은영민

연세대학교 의과대학 소아청소년과학교실

A child with Kawasaki disease and genetic warfarin sensitivity from *CYP2C9* and *VKORC1* gene variants

Myeongseob Lee, Lucy Youngmin Eun

Department of Pediatrics, Yonsei University College of Medicine, Seoul, Korea

Kawasaki disease (KD) is a common febrile disease in East Asia. Because KD with coronary artery aneurysm (CAA) may predispose to thrombosis, children with KD-associated CAA may need anticoagulation in addition to aspirin. In this report, we describe a 6-year-old girl with KD and CAA who was found to have unexpected warfarin-induced coagulopathy caused by *CYP2C9* and *VKORC1* genotype variants, which affect warfarin metabolism.

Key words: Anticoagulants; Coronary Aneurysm; Cytochrome P-450 Enzyme System; Mucocutaneous Lymph Node Syndrome; Warfarin

Introduction

Coronary artery aneurysm (CAA) is a life-threatening complication of Kawasaki disease (KD). Thrombosis in KD with CAA may lead to morbidity and mortality, such as myocardial infarction¹⁾. Therefore, optimal treatment of children with KD with CAA, is crucial for thromboprophylaxis.

Received: Sep 14, 2020

Revised: Oct 20, 2020

Accepted: Oct 20, 2020

Corresponding author

Lucy Youngmin Eun (ORCID 0000-0002-4577-3168)

Division of Cardiology, Department of Pediatrics, Yonsei University College of Medicine, 50-1 Yonsei-ro, Seodaemun-gu, Seoul 03722, Korea

Tel: +82-2-2019-3350 Fax: +82-2-2019-4881

E-mail: LUCYEUN@yuhs.ac

Depending on the size of the aneurysm, second antiplatelet agents or anticoagulants may be added to aspirin therapy²⁾.

We describe a 6-year-old girl who was treated with warfarin after she had developed multiple, long, and medium-sized CAAs in the left anterior descending artery (LAD) and long segments of irregular dilatation and tortuosity in the right coronary artery (RCA). The girl showed a refractory response to conventional treatment of KD and adjunctive steroid therapy, and was at a risk of thrombosis due to turbulent flow inside the CAAs.

Case

The patient was a previously healthy, 6-year old

girl. In August 2017, she was hospitalized at a hospital for fever that lasted for 7 days, conjunctival injection without any discharge, red lips and tongue, enlarged cervical lymph node, truncal maculopapular polymorphous rash, and edematous changes on both palms and soles. She was treated with intravenous immunoglobulin (2 g/kg) as the standard treatment protocol for KD.

Despite the therapy, her symptoms waxed and waned. Echocardiography showed diffuse coronary artery ectasia of the left main coronary artery, an aneurysm of the LAD, and an irregular fusiform aneurysm and tortuous dilatation of the RCA (Fig. 1). Given these multiple CAAs, she was then referred to our hospital, and hospitalized to the general ward. The initial vital signs were as follows: blood pressure, 121/71 mmHg; heart rate, 88 beats per minute; temperature, 36.5°C; and alert mentality. Her weight was 21 kg (25–50 percentile).

Initial laboratory findings showed a C-reactive protein concentration of 27.0 mg/L and procalcitonin concentration of 0.67 ng/mL (reference value, 0.02–0.5 ng/mL). Other laboratory findings were as follows: white blood cell count, $6.40 \times 10^3/\mu\text{L}$; hemoglobin, 10.8 g/dL; hematocrit, 31.5%; platelet,

$488 \times 10^3/\mu\text{L}$; serum sodium, 136 mmol/L; potassium, 4.2 mmol/L; aspartate aminotransferase, 30 IU/L; alanine aminotransferase, 72 IU/L; albumin, 3.0 g/dL; total bilirubin, 0.5 mg/dL; and B-type natriuretic peptide, 218.4 pg/mL.

Adjunctive steroid therapy was performed in addition to intravenous immunoglobulin and aspirin, and no further manifestations of KD were noted. However, echocardiography showed coronary arteriopathy with aneurysms (spindle-shaped LAD ectasia of 5–6 mm [Z-score = 5.2] and RCA ectasia of 4–6 mm [Z-score = 5.1]). Cardiac computed tomography for evaluation of the distal coronary arteries showed aneurysms in multiple coronary segments, which were wider and longer than those reported in the echocardiography performed at the referring hospital (Fig. 2).

As per the 2017 American Heart Association guidelines, KD with medium-sized CAAs does not always require the administration of low-molecular-weight heparin or warfarin as thromboprophylaxis³⁾. However, the anatomical features of the CAAs in our patient could cause turbulent blood flow inside the lesions, which is mentioned as a risk factor for myocardial ischemia in the guidelines³⁾.

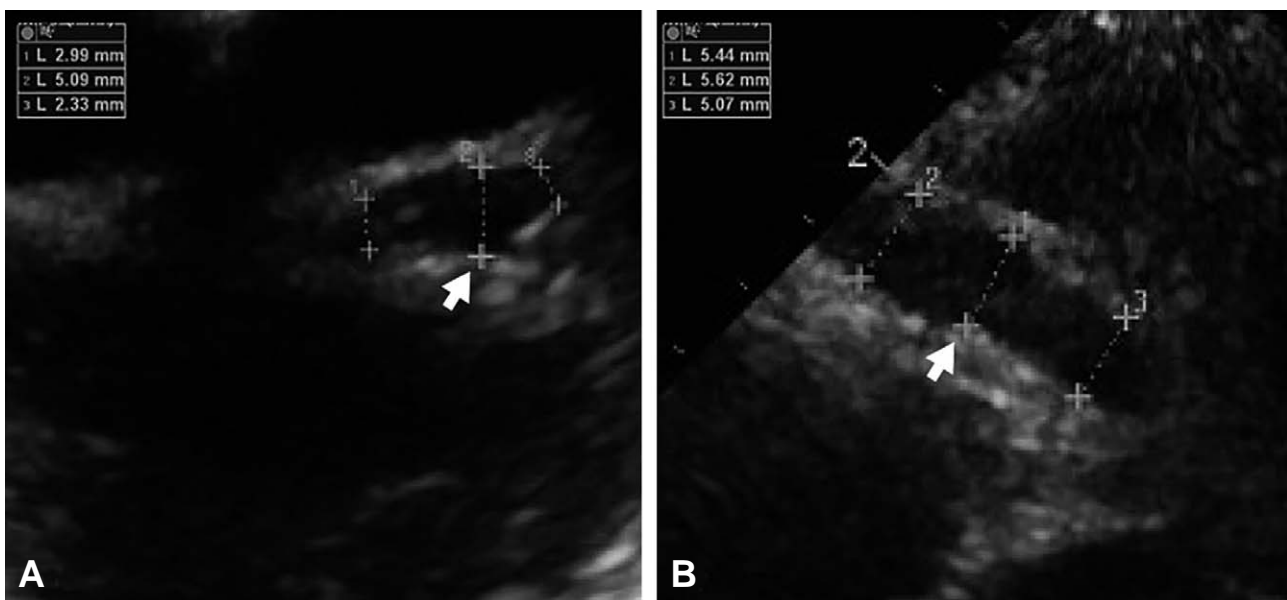


Fig. 1. Echocardiographic findings after the first intravenous immunoglobulin therapy. It shows the left main coronary artery and proximal portion of the dilated left descending artery (arrow; diameter, 4.3–5.1 mm; Z-score = 5.0) (A) and a fusiform diffuse dilatation of the right coronary artery (arrow; diameter, 5.6–6.0 mm; Z-score = 5.1) (B).

Thus, we initiated long-term anticoagulation therapy with warfarin (2.5 mg/day). International normalized ratio (INR) remained within the target of 2–4 for 5 consecutive days without acute bleeding. The concentrations of C-reactive protein and procalcitonin normalized, and initial blood culture showed no bacterial growth. On day 7, she was discharged without residual manifestations of KD.

After 3 days, she visited the emergency department (ED) for mild fever and erythematous skin rash on her back, neck, and both legs. Laboratory tests related to KD showed normal results. In addition, the rash recurred on the same site as before, and disappeared spontaneously. She was discharged without measuring INR because the rash was not considered to be due to a potential coagulopathy.

Three days after the ED visit, she returned to the outpatient department with evident petechiae. Given a follow-up INR of 6.28, we concluded that it was risky to continue warfarin therapy. After discontinuing the therapy, her INR normalized within 2 days. Given her unusually high INR with the dose of warfarin, we performed genetic assays for warfarin-related genes to investigate the causes. The assays showed that her *CYP2C9* genotype was *1/*3 (intermediate metabolizer) and her vitamin K epoxide reductase complex 1 (*VKORC1*; -1639G>A) genotype was AA. Because there are no dose-adjust-

ment guidelines for children with genetic warfarin sensitivity, we decided to replace warfarin with clopidogrel.

Follow-up echocardiography every 3 months showed no further dilatation or thrombosis of the CAAs. Moreover, a 29-month follow-up cardiac computed tomography (January 2020) showed significant improvement of the RCA and LAD lesions, even with residual mild dilatation and focal dilatation of the left circumflex artery (Fig. 3).

Discussion

This case report shows clinical implications of the genetic warfarin sensitivity in settings of anticoagulation for KD with CAA, and the potential for bleeding in cases of delayed detection of the sensitivity. Two previous articles have shown that dose adjustment and longer monitoring of INR are necessary in warfarin therapy for children with KD and associated warfarin sensitivity^{4,5}.

CYP2C9 has 3 genetic variants, including wild-type *CYP2C9* *1, and variants *2 and *3. Variants *2 and *3 reduce the enzymatic activity, and result in relative sensitivity to warfarin compared to wild-type *CYP2C9* *1. The *VKORC1* gene, another major gene of warfarin sensitivity, encodes the vitamin K

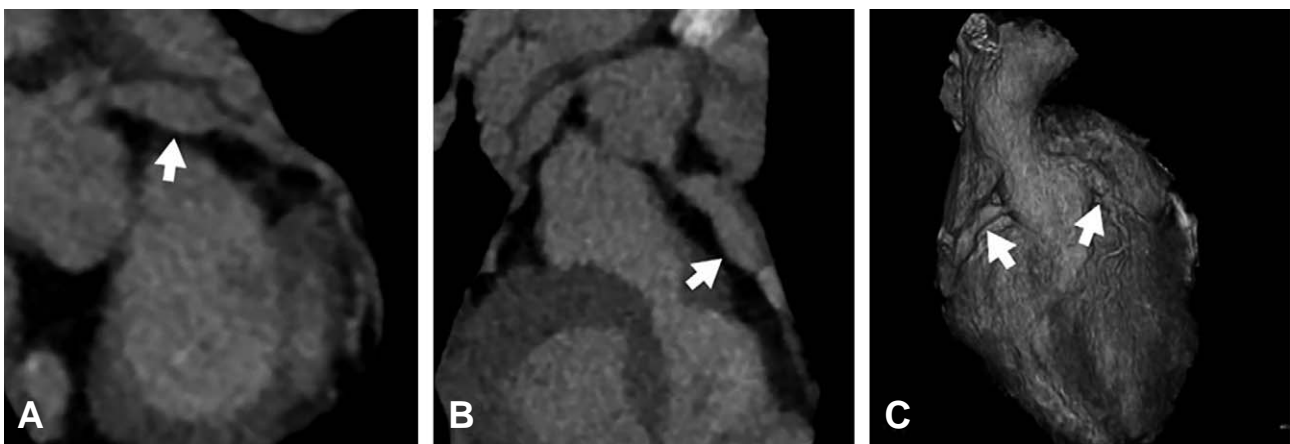


Fig. 2. Cardiac computed tomography findings after the second therapy. It shows a spindle-shaped coronary ectasia of the left main coronary artery (arrow; length, about a bit more than 2.0 cm; diameter, 6.2 mm; Z-score = 6.1) (A) and a long fusiform aneurysm of the right coronary artery (arrow; length, about 3.6 cm; diameter, 6.7 mm; Z-score = 5.6) (B). These findings are also seen in a 3-dimensional reconstruction image (arrows; C).

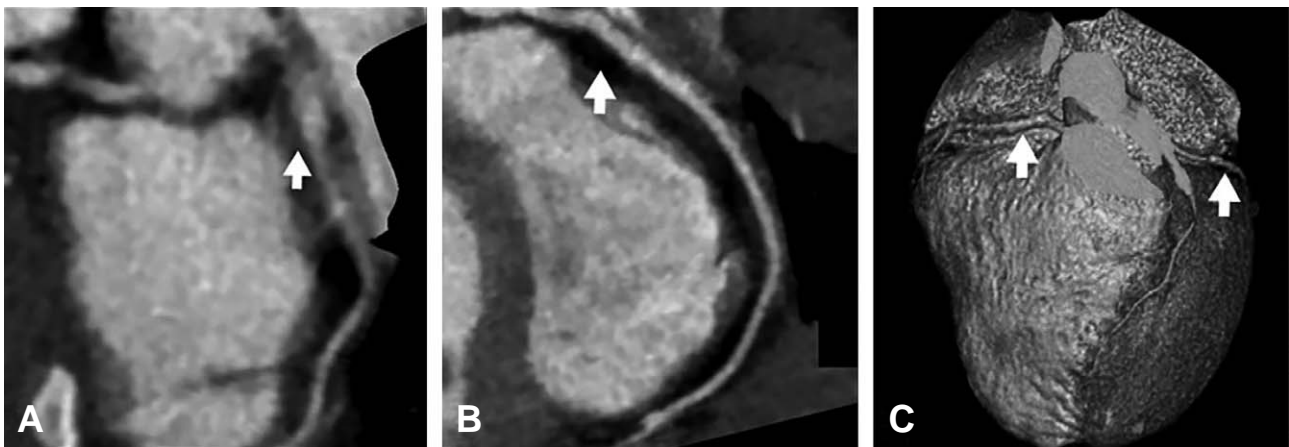


Fig. 3. The 29-month follow-up cardiac computed tomography findings (January 2020). It shows the improved left main and ascending coronary arterial ectasia (arrow; length, 11 mm; diameter, 4.7 mm; Z-score = 4.0) with mild residual dilatation and focal dilatation of the left circumflex artery (diameter, 4.2 mm) (A) and a right coronary arterial ectasia (arrow; diameter, 4.3 mm; Z-score = 2.9) with minimal residual coronary dilatation (B). These findings are also seen in a 3-dimensional reconstruction image (arrows; C).

epoxide reductase enzyme that promotes vitamin K recycling. A common non-coding variant, $-1639G>A$, may increase warfarin sensitivity. In $-1639A$ carriers who need warfarin therapy, initial and maintenance doses should be lower than in $-1639G$ carriers⁶.

For children with variant alleles, such as $CYP2C9$ $*1/*3$, $*2/*2$, $*2/*3$, $*3/*3$, $VKORC1$ GA, or AA, it takes longer to reach the maximum INR (about 2–4 weeks after the first warfarin administration)^{6,7}. When reached, INR is higher in children with the variants than in those with the wild-type gene^{6,7}. Therefore, in cases of children with genetic variants affecting warfarin metabolism, a hospital length of stay of 3–5 days for warfarin maintenance may be too short to prevent iatrogenic coagulopathy, resulting in unexpected return visits to EDs with bleeding. Given that the genotype-based, therapeutic dose recommendations for warfarin are available for adults, further studies are needed to determine pediatric guidelines⁶.

Furthermore, because KD is characterized by polymorphic erythematous skin lesions, in children with recently diagnosed KD, coagulopathy-induced petechiae can be misdiagnosed as improving, incompletely treated or refractory KD. Hence, it is important to distinguish KD from coagulopathy. In typical KD, polymorphic rash is followed by desqua-

mation⁸, and erythematous changes in the extremities and at the Bacille Calmette–Guérin inoculation sites are common⁹. In coagulopathy, petechiae do not blanch under pressure. If these differences are not recognized, there may be a delay in detecting life-threatening bleeding. Thus, this case suggests that history of recent anticoagulation needs to be obtained in EDs.

In conclusion, this case suggests that iatrogenic coagulopathy needs to be monitored in children with KD associated with CAA who have undergone recent anticoagulation. It is vital to obtain the relevant history, and if available, genetic assays for warfarin sensitivity in the children. To prevent not only thrombosis but also bleeding, regular monitoring of INR is mandatory until the confirmation of warfarin maintenance doses.

ORCID

Myeongseob Lee (<https://orcid.org/0000-0001-7055-3100>)

Lucy Youngmin Eun (<https://orcid.org/0000-0002-4577-3168>)

Conflicts of interest

No potential conflicts of interest relevant to this article were reported.

Funding source

No funding source relevant to this article was reported.

References

1. Kim DS. Kawasaki disease. *Yonsei Med J* 2006;47:759-72.
2. Giglia TM, Massicotte MP, Tweddell JS, Barst RJ, Bauman M, Erickson CC, et al. Prevention and treatment of thrombosis in pediatric and congenital heart disease: a scientific statement from the American Heart Association. *Circulation* 2013;128:2622-703.
3. McCrindle BW, Rowley AH, Newburger JW, Burns JC, Bolger AF, Gewitz M, et al. Diagnosis, treatment, and long-term management of Kawasaki disease: a scientific statement for health professionals from the American Heart Association. *Circulation* 2017;135:e927-99.
4. Wang Z, Zhang L, Huang P, Gu X, Xie X, Wang Y, et al. Weight and the vitamin K epoxide reductase 1 genotype primarily contribute to the warfarin dosing in pediatric patients with Kawasaki disease. *Thromb Res* 2018;167:32-6.
5. Yang D, Kuang H, Zhou Y, Cai C, Lu T. Height, VKORC1 1173, and CYP2C9 genotypes determine warfarin dose for pediatric patients with Kawasaki disease in Southwest China. *Pediatr Cardiol* 2019;40:29-37.
6. Dean L. Warfarin therapy and VKORC1 and CYP genotype. In: Pratt VM, McLeod HL, Rubinstein WS, Scott SA, Dean LC, Kattman BL, et al., editors. *Medical genetics summaries*. Bethesda (MD): National Center for Biotechnology Information; 2012.
7. Johnson JA, Gong L, Whirl-Carrillo M, Gage BF, Scott SA, Stein CM, et al. Clinical Pharmacogenetics Implementation Consortium Guidelines for CYP2C9 and VKORC1 genotypes and warfarin dosing. *Clin Pharmacol Ther* 2011;90:625-9.
8. Wang S, Best BM, Burns JC. Periungual desquamation in patients with Kawasaki disease. *Pediatr Infect Dis J* 2009; 28:538-9.
9. Uehara R, Igarashi H, Yashiro M, Nakamura Y, Yanagawa H. Kawasaki disease patients with redness or crust formation at the Bacille Calmette-Guerin inoculation site. *Pediatr Infect Dis J*. 2010;29:430-3.