



Accuracy of 2D CT-Based Measurements of Rotational Alignment of the Femoral Component for Total Knee Arthroplasty

Jun Young Park¹, Hyuck Min Kwon², Byung Woo Cho³, Woo-Suk Lee³, Ick Hwan Yang¹, and Kwan Kyu Park¹

¹Department of Orthopedic Surgery, Severance Hospital, Yonsei University College of Medicine, Seoul;

²Department of Orthopedic Surgery, Yong-In Severance Hospital, Yonsei University College of Medicine, Yongin;

³Department of Orthopedic Surgery, Gangnam Severance Hospital, Yonsei University College of Medicine, Seoul, Korea.

Purpose: We aimed to investigate the accuracy of two-dimensional computed tomography (2D-CT)-based methods for measuring rotational alignment of the femoral component during total knee arthroplasty in comparison to reference values for three-dimensional (3D) reconstruction.

Materials and Methods: We selected the “most protruding transepicondylar axis section,” “most protruding posterior condylar line section,” and “distal femoral cut section” on 2D-CT images for 100 knees. We investigated posterior condylar angle (PCA) and condylar twist angle (CTA) values using three different methods on 2D-CT and compared to these values to those obtained using a 3D model.

Results: The mean PCA and CTA values were 2.8° and 7.0° on the 3D model and 2.0° to 2.1° and 5.9° to 6.0° on 2D-CT, respectively. Errors in PCA and CTA measurement included internal rotation of 0.8° and 1.1° with the 1-plane and 2-plane methods and 0.9° and 1.0° with the assumed resection method, respectively.

Conclusion: Mean errors in PCA and CTA values measured using three different methods on 2D-CT were not significantly different. However, PCA and CTA values measured on 2D-CT were approximately 1° smaller than their 3D values. Thus, we suggest that adding 1° to the mean PCA and CTA values obtained from a single plane of 2D-CT would provide values similar to those obtained from 3D reconstruction.

Key Words: Knee, osteoarthritis, total knee arthroplasty, rotational alignment of the femoral component, 2D-CT, 3D reconstruction

INTRODUCTION

Total knee arthroplasty (TKA) is the one of the most successful surgical procedures, providing excellent clinical outcomes for end-stage osteoarthritis (OA) of the knee. However, about

20% of patients are not satisfied with the results of TKA.¹ The rotational alignment of the femoral component is one of the most important factors that affect clinical outcomes after TKA.² Malposition of the femoral component is one source of early revision TKAs.³ Malrotation of the femoral component in the axial plane can cause postoperative pain in the anterior knee, patellofemoral mal-tracking, and tibiofemoral instability during flexion.^{2,3}

In the measured resection technique, distal femur cuts for proper rotational alignment are based on bony anatomical landmarks.^{4,5} The surgical transepicondylar axis (sTEA), which is the central axis for the flexion-extension of the knee,^{6,7} is a line that connects the lateral epicondyle and sulcus of the medial epicondyle.⁸ However, previous studies have suggested that it is difficult to localize the sulcus of the medial epicondyle intraoperatively.⁹⁻¹¹ Thus, sTEA on preoperative comput-

Received: December 14, 2020 **Revised:** February 5, 2021

Accepted: February 15, 2021

Corresponding author: Kwan Kyu Park, MD, PhD, Department of Orthopedic Surgery, Yonsei University College of Medicine, 50-1 Yonsei-ro, Seodaemun-gu, Seoul 03722, Korea.

Tel: 82-2-2228-2183, Fax: 82-2-363-1139, E-mail: kkpark@yuhs.ac

•The authors have no potential conflicts of interest to disclose.

© Copyright: Yonsei University College of Medicine 2021

This is an Open Access article distributed under the terms of the Creative Commons Attribution Non-Commercial License (<https://creativecommons.org/licenses/by-nc/4.0>) which permits unrestricted non-commercial use, distribution, and reproduction in any medium, provided the original work is properly cited.

ed tomography (CT) slices has been used to obtain helpful information with which to determine the degree of external rotation of the femoral component.^{6,9,10}

Several orthopedic surgeons choose one slice out of several CT scans of the region around the actual medial and lateral epicondyles to identify the transepicondylar axis (TEA), owing to their intuitive understanding and convenience of measurement. However, the medial and lateral epicondyles, medial sulcus, and posterior femoral condyles cannot always be identified together on a single CT slice. Oshima, et al.¹² used three serial CT sections instead of a single image to determine the sTEA in their study. To date, however, no study has evaluated the idealization of a method for measuring sTEA and the clinical transepicondylar axis (cTEA) using two-dimensional (2D)-CT. Hirschmann, et al.¹³ suggested that measurements on three-dimensional (3D) were statistically better than those obtained from 2D-CT, and Okamoto, et al.¹⁴ stated that 3D measurements were more reliable and reproducible than 2D measurements. We sought to investigate the accuracy of various measurement methods using 2D-CT by taking advantage of the fact that bony anatomical landmarks can be selected accurately on a 3D reconstruction model.

The purposes of this study were as follows: 1) to measure posterior condylar angle (PCA) and condylar twist angle (CTA) values on a 3D reconstruction model and 2D-CT using three different measurement methods, 2) to investigate the degree of error in the PCA and CTA values measured using each 2D-CT method in comparison to reference values on 3D models, and 3) to determine the most accurate method of measurement.

MATERIALS AND METHODS

Data collection

This study was approved by the independent Institutional Review Board of Severance Hospital (IRB #4-2020-0115) and was waived of the requirement for informed consent. We retrospectively analyzed the CT images of 100 knees (50 women), composed of 50 normal knees (25 patients) and 50 knees (25 patients) with a degenerative OA. Angiographic CT images of the lower extremities of 25 patients (50 knees) with normal knees were obtained. These participants had visited our institution for the examination of lower extremity vessel status between November 2011 and March 2016. Patients with a history of surgery for the knee joint and apparent knee pathologies were excluded. We recruited another 25 patients who were scheduled to undergo TKA for both knees by a single orthopedic surgeon between January 2012 and February 2016. Patients with a history of previous knee surgery, post-traumatic arthritis, or rheumatoid arthritis were excluded from this study. Preoperative lower extremity CT studies of 25 patients (50 knees) were also included in this study. We measured the hip-knee-ankle angle of recruited participants by using standing

long leg plain radiographs for patients with an OA knee and supine CT scanogram for participants with a normal knee.

3D reconstruction of bony models

All patients underwent CT from the 10th thoracic vertebra level to both feet in the supine position, with both knees extended as much as possible. Patients with normal knees underwent CT using the SOMATOM Definition Flash (Siemens, Forchheim, Germany) device, with 2.0-mm slices, 100 kVp, and 150 mAs. Patients with OA of the knee underwent CT using the SOMATOM Sensation 64 (Siemens) system with 0.6-mm slices, 100 kVp, and 150 mAs. The scanned image data of each patient were acquired in the Digital Imaging and communications in Medicine (DICOM) format (National Electrical Manufacturers Association, Rosslyn, Virginia). The acquired DICOM data were imported to Mimics software (19.0, Materialise, Leuven, Belgium) and segmented to construct bony 3D reconstruction models of the distal femur.

Measurement using the 3D reconstruction model

The coordinate system on the 3D reconstruction models was defined as in the previous study.¹⁵ We defined the center of the hip as the center of the sphere that is best fitted to the femoral head. The cTEA was defined as a line connecting the most prominent point of the lateral epicondyle and medial epicondyle. We defined the center of the knee as the midpoint bisecting the cTEA. The Z-axis of the knee was defined as the extension of the mechanical axis of the femur connecting the centers of the hip and knee. We defined the plane perpendicular to the Z-axis at the center of the knee as the X-Y plane. The X-axis was defined as the extension of the cTEA, which was projected on the X-Y plane perpendicular to the Z-axis. The Y-axis was defined as the line normal to the coronal plane (X-Z plane) at the center of the knee.

The sTEA, cTEA, and posterior condylar line (PCL) were drawn on the 3D reconstruction bony model of each patient. sTEA and cTEA were defined as per previous studies.^{8,16} PCL was defined as the line connecting the most protruding points of the medial and lateral posterior condyles of the femur on the given image. The angle between the sTEA and PCL was defined as the PCA, and that between the cTEA and PCL was defined as the CTA (Fig. 1). A positive value indicated the direction of external rotation relative to the PCL, while a negative value indicated the direction of internal rotation (IR).

Measurement using the 2D CT

We selected the following three sections on the CT studies of each knee. The “most protruding TEA section” was the one where the medial and lateral epicondyles were the most prominent and the medial sulcus could be distinguished clearly from the medial epicondyle. Operators commonly use the section similar to the “most protruding TEA section” to locate TEA on preoperative CT to plan the extent of degrees of external rota-

tion. The “most protruding PCL section” is the one where the medial and lateral posterior condyles of the distal femur appeared the most protruded. Dialing 3° of external rotation is

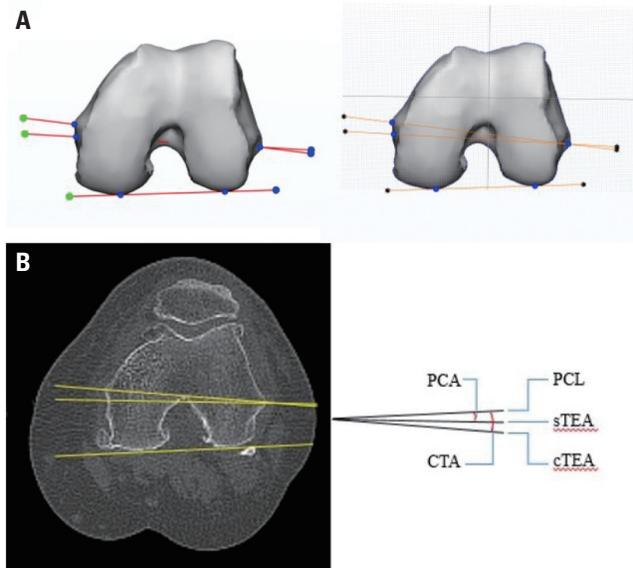


Fig. 1. Measurement of PCA and CTA values. (A) Measurement on the 3D reconstruction model. (B) Measurement on 2D-CT. PCA, posterior condylar angle; CTA, condylar twist angle; 3D, three-dimensional; 2D-CT, two-dimensional computed tomography; sTEA, surgical transepicondylar axis; cTEA, clinical transepicondylar axis; PCL, posterior condylar line.

widely used according to the PCL to determine the rotation of femoral component intraoperatively. We chose another CT slice, which was not the same as the “most protruding TEA section,” to determine the “most protruding PCL section” (Fig. 2). The “distal femoral cut section” is the one that is 9 mm away from the joint line level to ensure a depth of 9 mm for the distal femur cut.

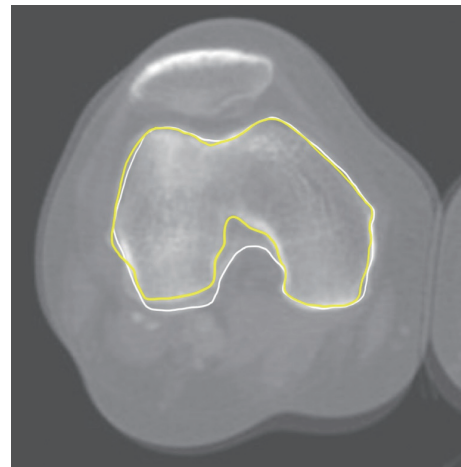


Fig. 2. Superimposed images of the “most protruding TEA section” and “most protruding PCL section.” The yellow line means the “most protruding TEA section,” and the white line means the “most protruding PCL section.” TEA, transepicondylar axis; PCL, posterior condylar line.

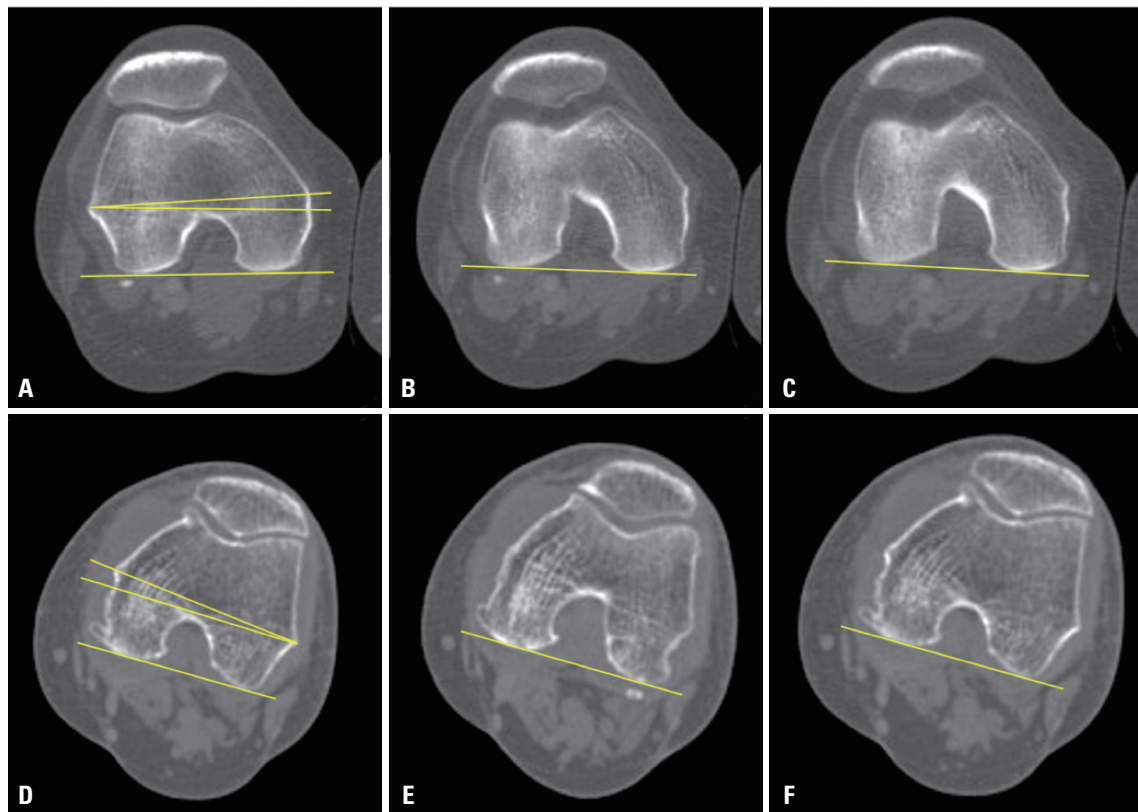


Fig. 3. Three different measurement methods of PCA and CTA values on 2D-CT. (A and D) Most protruding TEA section. (B and E) Most protruding PCL section. (C and F) Distal femoral cut section. (A, B, and C) Normal right knee. (D, E, and F) Left knee with osteoarthritis. PCA, posterior condylar angle; CTA, condylar twist angle; 2D-CT, two-dimensional computed tomography; TEA, transepicondylar axis; PCL, posterior condylar line.

First, we drew the sTEA and cTEA on the “most protruding TEA section” and determined the PCL and CTA from that CT slice (Fig. 3A and D). If the medial sulcus not recognizable due to flattening or bone formation, it was classified as type III (not recognized) as proposed by Akagi, et al.,¹⁷ and the sTEA was not evaluated in such cases. We obtained the PCA and CTA values by measuring the angle between the PCL and the other two axes on the “most protruding TEA section.” This method was designated as the “1-plane method.” Second, we determined another PCL from the “most protruding PCL section,” which differed from that of the “most protruding TEA section” (Fig. 3B and E). The PCA and CTA values were calculated as differences between the sTEA and cTEA obtained from the “most protruding TEA section” and the PCL from the “most protruding PCL section.” We designated this method as the “2-plane method,” because we used two CT slices to obtain the PCA and CTA values. Third, another PCL was determined from the “distal femoral cut section” (Fig. 3C and F). We obtained the PCA and CTA values from the sTEA and cTEA from the “most protruding TEA section” and the PCL from the “distal femoral cut section.” This method was designated as the “assumed resection method.”

Errors in measurements and outliers

Errors in the measurement of PCA and CTA were calculated as the difference between the values obtained using each measurement method on 2D-CT and the reference value measured on the 3D reconstruction models. Errors with positive values meant that the value was (incorrectly) measured to be more externally rotated than the 3D reference value. The PCA and CTA outliers were defined as the range at which the PCA and CTA (obtained from 2D-CT) differed from the value obtained from the 3D reconstruction model by more than 3°.

Evaluation of intrarater and interrater reliability

All measurements on the 2D-CT scans and 3D reconstruction models were performed by two orthopedic surgeons to evaluate interrater reliability. Each rater measured each parameter for the second time, 1–2 weeks after the first measurement, to evaluate the intrarater reliability. Each rater was blinded to others' measurements during the period of rating. The degree of measurement reliability was assessed using intraclass correlation coefficients. The 95% confidence intervals of the intraclass correlation coefficients for intra- and interrater reliability were 0.921–0.959 and 0.879–0.914, respectively.

Statistical analysis

SPSS software, version 21.0 for Windows (IBM Corp., Armonk, NY, USA), was used for statistical analysis. All data are presented as means and standard deviations. Independent t-test and chi-squared test were used to compare the demographics and values of PCA and CTA between OA and non-OA groups. Paired t-test was used to compare differences for CTA and PCA val-

ues obtained between the 3D reconstruction model and those obtained using each measurement method. Repeated measures analysis of variance (ANOVA) was performed to compare the errors of each method. *P* values < 0.05 were considered statistically significant. We used G*Power, version 3.1.9.6 (Heinrich-Heine-Universität Düsseldorf, Düsseldorf, 14 Germany) for calculating adequate sample size.¹⁸ A total of 68 subjects were required to perform repeated measures ANOVA analysis using an alpha error of 0.05, power of 0.95, and effective size of 0.18, and hence, the sample size of our study cohort was acceptable.

RESULTS

The mean age of the participants (100 knees of 50 patients) was 58.3±13.4 years (range 40–81). A significant difference was observed between the mean age of the normal-knee (46.0±3.1 years) and OA-knee (70.6±6.6 years) groups. The mean body mass index (BMI) of all participants was 25.2±4.5 (range 17.6–38.6) kg/m², and the mean BMI of the normal-knee group (22.8±2.8) differed significantly from that of the OA-knee group (27.7±4.6). The shape of the medial sulcus (of the 100 knees) on the “TEA section” was classified as follows: type I (well recognizable), 19 knees; type II (barely recognizable), 49 knees; and type III (not recognized), 32 knees (Table 1). Thus, the value of PCA and errors in the measurement of PCA were measured for 68 knees excluding type III.

The mean PCA was 2.8±1.1° (range 0.5–6.8), and the mean CTA was 7.0±1.6° (range 0.4–11.7) for the 3D reconstruction models (*p*<0.001). The mean PCA values were 2.1±2.0° (range -4.3–5.8) for the 1-plane method, 2.0±1.9° (range -3.3–5.8) for the 2-plane method, and 2.0±1.9° (range -4.0–5.3) for the assumed resection method (*p*=0.566). The mean PCA values for each of the 2D-CT methods were significantly smaller than that of the 3D reconstruction model (*p*<0.001) (Table 2). The mean CTA was 5.9±2.1° (range -3.1–9.1) for the 1-plane method, 5.9±2.0° (range -1.2–9.1) for the 2-plane method, and 6.0±1.8° (range -0.3–9.7) for the assumed resection method (*p*=0.481). The mean CTA of the three measurement methods were significantly smaller than that of the reference value obtained from the 3D reconstruction model (*p*<0.001) (Table 2).

We evaluated the degree of errors in measurements for each method to determine the method with the smallest error, compared to the 3D reference value. Mean errors in the measurement of PCA were -0.8±1.8° for the 1-plane method, -0.8±1.6° for the 2-plane method, and -0.9±1.6° for the assumed resection method. There were no significant differences among the mean errors in the PCA measured using the three different CT methods. Six outliers (9%) of PCA measurement were observed for each of the 1-plane and 2-plane methods, and five outliers (7%) were observed in the assumed resection method. The mean error in the measurement of CTA was -1.1±1.7° in the

1-plane method, $-1.1 \pm 1.6^\circ$ in the 2-plane method, and $-1.0 \pm 1.6^\circ$ in the assumed resection method. There was no significant difference in the error of CTA measured using the three methods. There were 14 outliers (14%) in the measurement of CTA with the 1-plane method, 11 outliers (11%) in the 2-plane method, and 12 outliers (12%) in the assumed resection method (Table 3).

DISCUSSION

In this study, we compared the PCA and CTA values obtained from 2D-CT using three different methods with those measured on 3D reconstruction models. The PCA and CTA values derived from the 2D-CT were similar to each other, with a difference of 0.1° , which was not significant. However, the PCA value obtained from the 2D plane was significantly smaller (by 0.7 to 0.8°) than the reference value obtained from the 3D reconstruction models, while the CTA values obtained from the

2D plane was 1.0 – 1.1° smaller than that obtained from the 3D models. Thus, the PCA and CTA values obtained from preoperative 2D-CT could include an IR of about 1° , compared to 3D reference values. An increase in the internal malrotation of the femoral components may be involved in postoperative knee pain, patellofemoral mal-tracking, or instability of the flexion gap.¹⁹ Therefore, we suggest that surgeons should be aware of the risk of misunderstanding PCA and CTA by considering only the measured values from 2D-CT.

Placing the femoral component into the proper rotation alignment is an important factor affecting the clinical outcomes of TKA.³ Femoral rotation parallel to the sTEA is accepted to be biomechanically reasonable because the sTEA is considered to be reliable and almost vertical to the mechanical axis.⁶ However, Poilvache, et al.²⁰ reported that the sulcus of the medial epicondyle was difficult to locate during TKA. In our study, the sulcus of the medial epicondyle could not be identified in 32 knees (32%), and we classified such knees as type III. The PCL is easy to recognize intraoperatively and is

Table 1. Demographics of the Study Cohort

Characteristics	Total	OA	Non-OA	p value
No. of knees	100	50	50	
Side (knees)	Rt: 50; Lt: 50	Rt: 25; Lt: 25	Rt: 25; Lt: 25	
Age (yr)	58.3 ± 13.4 (40–81)	70.6 ± 6.6 (55–81)	46.0 ± 3.1 (40–50)	<0.001
Body mass index (kg/m ²)	25.2 ± 4.5 (17.6–38.6)	27.7 ± 4.6 (18.7–38.6)	22.8 ± 2.8 (17.6–29.8)	<0.001
Hip-Knee-Ankle angle (°)	4.3 ± 5.8 varus (10.3 valgus–16.5 varus)	4.7 ± 6.6 varus (10.3 valgus–16.5 varus)	3.9 ± 5.0 varus (9.0 valgus–15.6 varus)	0.503
Kellgren-Lawrence grading scale (knees)	G0: 50; G3: 13; G4: 37	G3: 13; G4: 37	G0: 50	<0.001
No. of types of medial sulcus (knees)	I: 19; II: 49; III: 32	I: 6; II: 19; III: 25	I: 13; II: 30; III: 7	<0.001

Data are presented as mean \pm standard deviation (range).

Table 2. Comparison of PCA and CTA Values from 3D and 2D Measurement

	PCA				CTA			
	Total	OA	Non-OA	p value	Total	OA	Non-OA	p value
3D model	$2.8 \pm 1.1^*$	2.6 ± 0.8	3.0 ± 1.2	0.064	$7.0 \pm 1.6^*$	6.6 ± 1.6	7.3 ± 1.7	0.031
1-Plane method	2.1 ± 2.0	1.6 ± 2.1	2.3 ± 1.9	0.189	5.9 ± 2.1	5.4 ± 2.4	6.4 ± 1.7	0.021
2-Plane method	2.0 ± 1.9	1.5 ± 1.9	2.3 ± 1.8	0.099	5.9 ± 2.0	5.4 ± 2.1	6.4 ± 1.7	0.010
Assumed resection method	2.0 ± 1.9	1.4 ± 1.8	2.3 ± 1.9	0.067	6.0 ± 1.8	5.5 ± 1.9	6.4 ± 1.7	0.021

PCA, posterior condylar angle; CTA, condylar twist angle; 3D, three-dimensional; 2D, two-dimensional; CT, computed tomography. All values in the table are in degrees. We obtained the results of PCA in 68 knees (OA: 25, Non-OA: 43 knees) and CTA in 100 knees (OA: 50, Non-OA: 50 knees) due to the recognition of the medial sulcus.

*The PCA and CTA values of the 3D reconstruction model were significantly larger with each value obtained from the 2D CT using three methods of measurement.

Table 3. Errors in Measurement of PCA and CTA Values Using Three Different 2D-CT Methods

	1-Plane method	2-Plane method	Assumed resection method
Errors in measurement of PCA*	$-0.8 \pm 1.8^\circ$	$-0.8 \pm 1.6^\circ$	$-0.9 \pm 1.6^\circ$
Outliers, n (%) [†]	6 (9)	6 (9)	5 (7)
Errors in measurement of CTA*	$-1.1 \pm 1.7^\circ$	$-1.1 \pm 1.6^\circ$	$-1.0 \pm 1.6^\circ$
Outliers, n (%) [†]	14 (14)	11 (11)	12 (12)

PCA, posterior condylar angle; CTA, condylar twist angle; 2D, two-dimensional; CT, computed tomography

*Errors in the measurement of PCA were measured for 68 knees and those for CTA were measured for 100 knees, [†]The outlier was defined as the range in which the 2D-CT measured angle differed from the value obtained from the 3D reconstruction model by 3° .

normally internally rotated by approximately 3° with respect to the sTEA.¹⁶ We also found that the PCA on our 3D reconstruction models was 2.8±1.1°, which, although similar to that reported by previous studies, ranged from 0.5°–6.8°. Therefore, determining the rotational alignment of the femoral component based on the individual preoperative CT would provide a more accurate PCA value than that obtained by routinely placing the implant with 3° of external rotation with respect to the PCL, as performed in other studies.¹² Some studies suggested determining the rotational alignment of the femoral component for each patient by measuring the PCA and CTA values using individual preoperative CT due to variations between individuals.^{21,22}

In this study, we analyzed the most accurate 2D-CT measurement method compared to the 3D reconstruction models. There was no significant difference among the degree of errors in the measurements obtained from the three different methods. We confirmed the lack of a significant difference in the PCA and CTA values measured using only one slice of 2D CT and those measured using two slices of CT. However, 2D-CT provided PCA and CTA values that were about 1° smaller than the 3D models. Considering that 2D-CT imaging is performed in a variety of non-uniform postures, we believe that the 3D model measuring the PCA and CTA on a plane perpendicular to the femoral mechanical axis helps to select the non-distorted PCL or medial epicondyle.

The incidence of error outliers was 7–14% for our methods of 2D-CT measurement and approximately 90% of outliers pertained to internal malrotation. Thus, cutting the distal femur only on the basis of preoperative 2D-CT during TKA could result in a severe IR error exceeding 3°.

It is difficult to select the epicondyles precisely during surgery, due to soft tissue coverage. Moreover, the sTEA is not a consistent anatomical landmark, with variations in inter- and intrarater reliability. Also, there may be considerable variations in the actual surgical procedure because the PCL is detected intraoperatively along the surface of the remaining cartilage of the posterior condyles and progression of articular cartilage degeneration varies individually. PCL and TEA values cannot be used in some cases due to obscuring and distortion of the bony landmarks. Previous studies recommended using an additional supplemental axis in cases where it is difficult to determine the rotational alignment, such as valgus knee or severe OA.^{10,11} We also suggest that a combination of TEA and PCL obtained from preoperative CT and surrogate axes, including other bony landmarks, such as the anterior cortex of the distal femur and anterior trochlear line, can contribute to the determination of the optimal rotational alignment of the femoral component.^{23,24}

Our study has several limitations. First, all participants involved in this study were Korean women. We could not analyze racial and sexual differences in the study population. Second, our results have innate limitations because it used a

3D reconstruction computer model. A few previous studies have reported on the innate inaccuracy of 3D measurements, especially due to the modifying process.²⁵ Our 3D reconstruction model may not have coincided with real anatomical structures as we corrected the original 3D reconstruction model to make it smooth. Third, our results are not applicable to all cases of TKA because preoperative CT is not performed routinely, owing to the risk of radiation exposure and concerns about the economic cost. Fourth, we did not conduct CT studies with the knees in flexion. The 2D-CT slices may not be perpendicular to the anatomical axial plane of the distal femur because every participant had a different degree of knee flexion. Finally, we measured the PCL value based on CT. However, it would have been better to measure the PCL value using magnetic resonance imaging, which accounts for the thickness of the residual cartilage in osteoarthritic knees.

We confirmed that using the 2D plane of a CT scan could include IR, which was approximately 1° smaller than the 3D reference value. Also, there was no difference among the three types of methods measuring PCA and CTA values on 2D-CT. Considering the limitation of the reliability for determining sTEA intraoperatively, we recommend measuring PCA and CTA values, even with one slice of preoperative 2D-CT, to determine the degree of external rotation of the femoral component during TKA.

AUTHOR CONTRIBUTIONS

Conceptualization: Kwan Kyu Park and Hyuck Min Kwon. **Data curation:** Hyuck Min Kwon and Jun Young Park. **Formal analysis:** Byung Woo Cho and Jun Young Park. **Investigation:** Kwan Kyu Park. **Methodology:** Byung Woo Cho and Jun Young Park. **Project administration:** Woo-Suk Lee and Kwan Kyu Park. **Resources:** Ick Hwan Yang. **Software:** Hyuck Min Kwon and Byung Woo Cho. **Supervision:** Ick Hwan Yang. **Validation:** Woo-Suk Lee. **Visualization:** Jun Young Park. **Writing—original draft:** Jun Young Park. **Writing—review & editing:** Kwan Kyu Park. **Approval of final manuscript:** all authors.

ORCID iDs

Jun Young Park	https://orcid.org/0000-0002-4713-4036
Hyuck Min Kwon	https://orcid.org/0000-0002-2924-280X
Byung Woo Cho	https://orcid.org/0000-0002-7472-4103
Woo-Suk Lee	https://orcid.org/0000-0002-0798-1660
Ick Hwan Yang	https://orcid.org/0000-0002-6959-6207
Kwan Kyu Park	https://orcid.org/0000-0003-0514-3257

REFERENCES

1. Gunaratne R, Pratt DN, Banda J, Fick DP, Khan RJK, Robertson BW. Patient dissatisfaction following total knee arthroplasty: a systematic review of the literature. *J Arthroplasty* 2017;32:3854-60.
2. Berger RA, Crossett LS, Jacobs JJ, Rubash HE. Malrotation causing patellofemoral complications after total knee arthroplasty. *Clin Orthop Relat Res* 1998;(356):144-53.
3. Pietsch M, Hofmann S. Early revision for isolated internal malro-

- tation of the femoral component in total knee arthroplasty. *Knee Surg Sports Traumatol Arthrosc* 2012;20:1057-63.
4. Dennis DA, Komistek RD, Kim RH, Sharma A. Gap balancing versus measured resection technique for total knee arthroplasty. *Clin Orthop Relat Res* 2010;468:102-7.
 5. Christensen CP, Stewart AH, Jacobs CA. Soft tissue releases affect the femoral component rotation necessary to create a balanced flexion gap during total knee arthroplasty. *J Arthroplasty* 2013;28:1528-32.
 6. Asano T, Akagi M, Nakamura T. The functional flexion-extension axis of the knee corresponds to the surgical epicondylar axis: in vivo analysis using a biplanar image-matching technique. *J Arthroplasty* 2005;20:1060-7.
 7. Kobayashi H, Akamatsu Y, Kumagai K, Kusayama Y, Aratake M, Saito T. Is the surgical epicondylar axis the center of rotation in the osteoarthritic knee? *J Arthroplasty* 2015;30:479-83.
 8. Berger RA, Rubash HE, Seel MJ, Thompson WH, Crossett LS. Determining the rotational alignment of the femoral component in total knee arthroplasty using the epicondylar axis. *Clin Orthop Relat Res* 1993;(286):40-7.
 9. Victor J. Rotational alignment of the distal femur: a literature review. *Orthop Traumatol Surg Res* 2009;95:365-72.
 10. Talbot S, Dimitriou P, Radic R, Zordan R, Bartlett J. The sulcus line of the trochlear groove is more accurate than Whiteside's Line in determining femoral component rotation. *Knee Surg Sports Traumatol Arthrosc* 2015;23:3306-16.
 11. Morizane K, Takahashi T, Konishi F, Yamamoto H. The anterior trochlear line as a reference for femoral component positioning in total knee arthroplasty. *Knee Surg Sports Traumatol Arthrosc* 2011;19:2009-15.
 12. Oshima Y, Iizawa N, Kataoka T, Majima T, Takai S. A computed-tomography-scan-based template to place the femoral component in accurate rotation with respect to the surgical epicondylar axis in total knee arthroplasty. *Knee* 2018;25:195-202.
 13. Hirschmann MT, Konala P, Amsler F, Iranpour F, Friederich NE, Cobb JP. The position and orientation of total knee replacement components: a comparison of conventional radiographs, transverse 2D-CT slices and 3D-CT reconstruction. *J Bone Joint Surg Br* 2011;93:629-33.
 14. Okamoto S, Mizu-uchi H, Okazaki K, Hamai S, Tashiro Y, Nakahara H, et al. Two-dimensional planning can result in internal rotation of the femoral component in total knee arthroplasty. *Knee Surg Sports Traumatol Arthrosc* 2016;24:229-35.
 15. Mizu-uchi H, Colwell CW Jr, Matsuda S, Flores-Hernandez C, Iwamoto Y, D'Lima DD. Effect of total knee arthroplasty implant position on flexion angle before implant-bone impingement. *J Arthroplasty* 2011;26:721-7.
 16. Yoshino N, Takai S, Ohtsuki Y, Hirasawa Y. Computed tomography measurement of the surgical and clinical transepicondylar axis of the distal femur in osteoarthritic knees. *J Arthroplasty* 2001;16:493-7.
 17. Akagi M, Yamashita E, Nakagawa T, Asano T, Nakamura T. Relationship between frontal knee alignment and reference axes in the distal femur. *Clin Orthop Relat Res* 2001;(388):147-56.
 18. Faul F, Erdfelder E, Buchner A, Lang AG. Statistical power analyses using G*Power 3.1: tests for correlation and regression analyses. *Behav Res Methods* 2009;41:1149-60.
 19. Kim CW, Lee CR, Gwak HC, Kim JH, Kwon YU, Kim DY. The effects of surgical technique in total knee arthroplasty for varus osteoarthritic knee on the rotational alignment of femoral component: gap balancing technique versus measured resection technique. *J Knee Surg* 2020;33:144-51.
 20. Poilvache PL, Insall JN, Scuderi GR, Font-Rodriguez DE. Rotational landmarks and sizing of the distal femur in total knee arthroplasty. *Clin Orthop Relat Res* 1996;(331):35-46.
 21. Luyckx T, Peeters T, Vandenuecker H, Victor J, Bellemans J. Is adapted measured resection superior to gap-balancing in determining femoral component rotation in total knee replacement? *J Bone Joint Surg Br* 2012;94:1271-6.
 22. Sharma D, Shukla A, Kumar K. Role of preoperative calculation of condylar twist angle (CTA) by CT scan in optimizing femoral component rotation during TKA. *Musculoskelet Surg* 2017;101:207-12.
 23. Yu B, Fu M, Zhang Z, Wu P, Huang Z, Sun H. The plane of the distal femur anterior cortex is a useful index for femoral component rotation in total knee arthroplasty. *J Orthop* 2016;14:59-61.
 24. Most E, Axe J, Rubash H, Li G. Sensitivity of the knee joint kinematics calculation to selection of flexion axes. *J Biomech* 2004;37:1743-8.
 25. Higgins SW, Spratley EM, Boe RA, Hayes CW, Jiranek WA, Wayne JS. A novel approach for determining three-dimensional acetabular orientation: results from two hundred subjects. *J Bone Joint Surg Am* 2014;96:1776-84.