

Pleomorphic Adenoma of the Trachea

— A case report —

Hyo Chae Paik, Sang Hyun Lim, Doo Yun Lee, and So Yah Paik*

An unusual tracheal tumor was found in a 50 year old male who was admitted due to mild dyspnea on exertion. Simple chest X-ray showed an abnormal mass shadow in the trachea and computerized chest tomogram revealed a tumor in the mid 1/3 of the trachea obstructing 80% of the lumen. Through a right thoracotomy incision, resection of a 2.5 cm segment of the trachea with end-to-end anastomosis was done and microscopic findings showed many cystic spaces with myxomatous hyalinous stroma. It was diagnosed as a pleomorphic adenoma of the trachea.

Key Words: Pleomorphic adenoma, end to end anastomosis

Primary tracheal tumors are rare disease entities (Moersch *et al.* 1954; Salm, 1964) and squamous cell carcinoma is the most common epithelial tumors encountered (Houston *et al.* 1969). Other epithelial tumors are that from the glandular tissue within the tracheal wall and it is histologically identical to tumors from the major salivary glands of the oral cavity, pharynx, nasopharynx, and respiratory tract. Among these is the adenoid cystic carcinoma, mucoepidermoid carcinoma, and pleomorphic adenoma or benign mixed tumor (Salm, 1964; Hajdu *et al.* 1970). Pleomorphic adenoma is extremely rare and as of 1988, only 16 cases have been reported in literature (Hemmi *et al.* 1988).

We report a case of pleomorphic adenoma of the trachea with a review of the literature.

REPORT OF A CASE

A 50 year old male was admitted to the hospital due to mild dyspnea on exertion for a period of three months. On physical examination, the lung sounds were clear and he was well fit for his age. Laboratory studies were unremarkable except for the pulmonary function test which revealed an obstructive defect. The chest X-ray showed normal lung parenchyme but a round mass in the mid trachea was clearly seen (Fig. 1, 2). Computed tomography of the chest showed a 1.5×1.7×1.8 cm sized homogenous mass protruding from the right inner wall of the trachea obstructing 80% of the tracheal lumen 4 cm above the carina (Fig. 3). Due to severe obstruction of the airway by mass, bronchoscopy was not performed because of high risk and therefore an operation was performed without bronchoscopy.

Under general anesthesia, right posterolateral thoracotomy was done and the trachea was dissected from the surrounding organ and the obstructing mass was palpable. After circumferential resection of 4 tracheal rings including the tumor, reconstruction of the trachea

Received November 14, 1995

Accepted November 30, 1995

Department of Thoracic and Cardiovascular Surgery, and Pathology*, Yonsei University College of Medicine, Yongdong Severance Hospital, Respiratory Center

Address reprint requests to Dr. Paik, Hyo Chae Youngdong P.O.Box 1217, Seoul 135-271, Korea

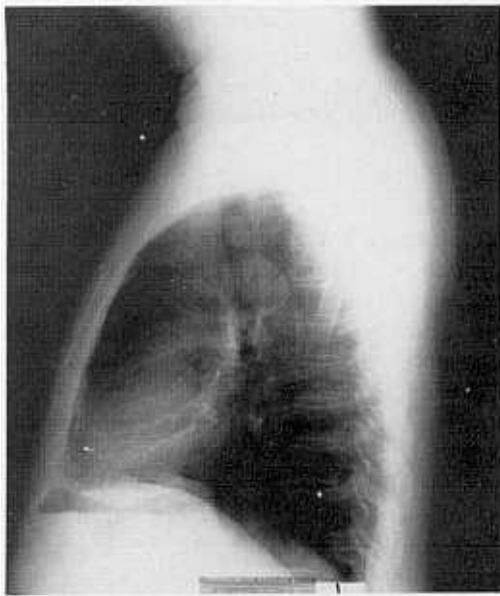
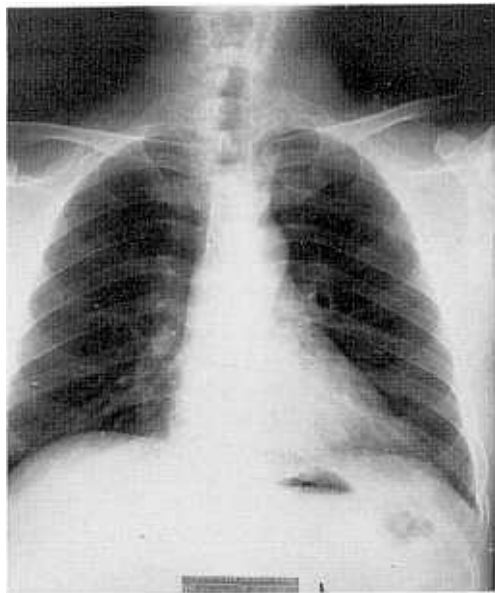


Fig. 1,2. Plain chest PA and lateral view showing mass lesion within the trachea.

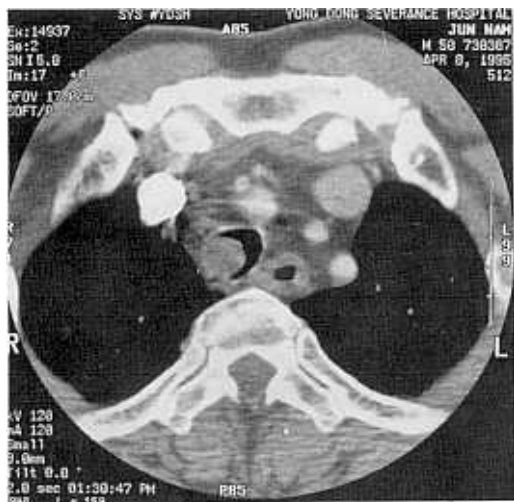


Fig. 3. Chest computerized tomogram shows a huge mass in the trachea obstructing 80% of the tracheal lumen about 4cm above the carina.

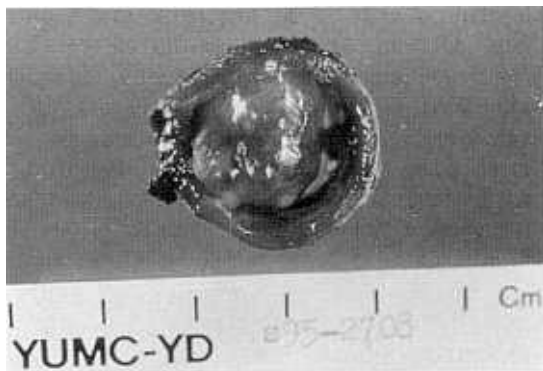

Fig. 4. A polypoid mass measuring 2x2cm which occupies about 90% of the tracheal lumen.

by end-to-end anastomosis with interrupted Vicryl 4-0 suture was performed. The gross findings showed the tracheal lumen obstructed by a firm, glistening, yellowish tumor origi-

nating from the posterior membranous part and the tumor was 1.8cm in diameter with no signs of invasion of the surrounding tissue. The resected trachea contained a solid, polypoid mass measuring 2x2cm which was completely covered by glistening mucosa. The mass occupied about 90% of the total tracheal lumen (Fig. 4). On cut section, it reveals to be composed of solid, gray-white homogeneous

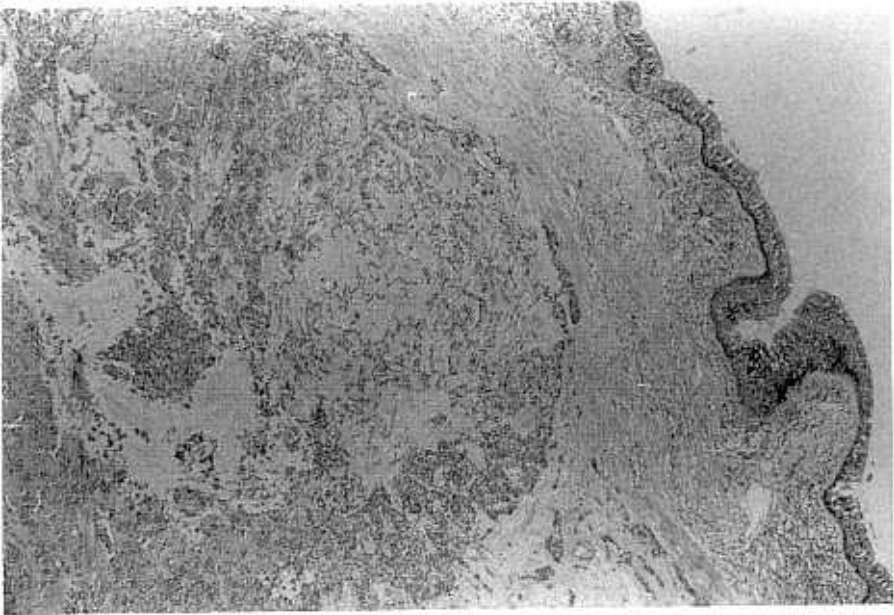


Fig.5. The tumor cell within the lamina propria encircled by a thin, fibrous capsule. Solid sheets of epithelial cells are seen scattered in the background of myxoid stroma(H & E ×40)

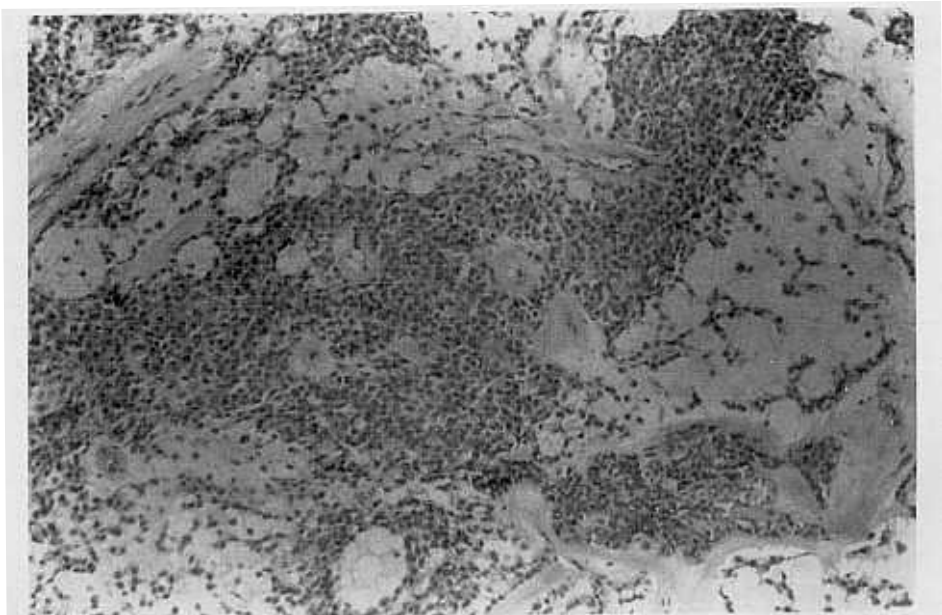


Fig.6. There are gradual immersing of epithelial cells with the myxoid stroma. (H & E ×200)

tissue with a slight myxoid tinge. There was no evidence of necrosis or hemorrhage.

Microscopically, the tumor was found within the lamina propria encircled by a thin fibrous capsule (Fig. 5). Solid sheets of epithelial cells are seen scattered in the background of the myxoid stroma with gradual immersing of these epithelial cells within the myxoid stroma (Fig. 6). Focal areas also show tubular arrangement of these epithelial components, but neither mitosis nor necrosis was present and these findings were compatible with a typical pleomorphic adenoma.

The chin and the anterior chest was immobilized by two heavy nylon sutures in-between to relieve tension at the anastomosis site. The postoperative course was uneventful, and fiberbronchoscopy performed on postoperative 18th day showed clear, well healed anastomotic site and the patient was discharged in good general condition.

DISCUSSION

The tracheal tumors are rare and when encountered, it is usually squamous cell carcinoma or adenoid cystic carcinoma. Pleomorphic adenoma occurring in the trachea is very rare and only 16 cases have been reported in literature. Pleomorphic adenoma is a common tumor found in the salivary glands of the oral cavity, pharynx, nasopharynx, and the respiratory tract, and it is characterized histologically by many cystic spaces and hyalinous connective stroma which is also found in adenoid cystic carcinoma.

Ma *et al.* (1979) reviewed 14 cases of tracheal pleomorphic adenoma that has been reported since 1922, and two more cases have been reported (Sano *et al.* 1984; Hemmi *et al.* 1988) since. The ages varied from 26 to 76 years and they complained of hemoptysis, cough, asthma, and dyspnea. There were 10 male and 6 female and 7 cases (43.7%) occurred in the upper 1/3 of the trachea, 6 cases (37.5%) in the middle 1/3, 2 cases (12.5%) in the lower 1/3, and unknown in 1 case.

The tumor has to be distinguished from

more commonly occurring squamous cell carcinoma and adenoid cystic carcinoma. It is easily differentiated from the squamous cell carcinoma by circumscribed, elevated, nodular appearance which is commonly seen in pleomorphic adenoma, but when a specific cartilaginous component is not visible, it is difficult to differentiate from the adenoid cystic carcinoma. The most important differential point from the adenoid cystic carcinoma is that adenoid cystic carcinoma shows cell nests that are sharply separated from the connective tissue as to the gradual transition between the epithelium and stromal elements seen in the pleomorphic adenoma (Sano *et al.* 1984). According to Regezi *et al.* (1985), immunoreactivities of S-100 protein and GFAP (glial fibrillary acidic protein) in 33 cases of salivary gland tumor was observed and all 17 pleomorphic adenomas showed strong positive reactions to S-100 protein and GFAP compared to only weak reactions for S-100 in adenoid cystic carcinoma.

Therefore S-100 and GFAP may be helpful markers in differentiating pleomorphic adenoma and adenoid cystic carcinoma.

Surgical excision is the optimal treatment for pleomorphic adenoma and it is probably curative. However, there has been one case of malignant pleomorphic adenoma reported by Hemmi *et al.* (1988). This patient underwent a complete resection of the tracheal tumor which was diagnosed as pleomorphic adenoma, and after 11 years, the patient was seen with the metastatic lesion in the lung and the chest wall. Therefore, pleomorphic adenoma of the trachea can not be conclusively called a benign tumor.

Since only a few cases of pleomorphic adenoma have been reported in literature, further accumulation of cases are necessary in order to define its biological behavior and clinical course of this disease.

REFERENCES

- Hajdu SI, Juvos AG, Goodner JT, Foote FW, Beattie EJ: Carcinoma of trachea. *Cancer* 25: 1448-1456, 1970

Pleomorphic Adenoma of the Trachea

- Hemmi A, Hiraoka H, Mori Y, Wataya T, Sato H, Jinnai M, Yamaguchi H, Arai Y: Malignant Pleomorphic Adenoma (Malignant Mixed Tumor) of the Trachea. *Acta Pathol Jpn* 38: 1215-1226, 1988
- Houston HE, Payne WS, Harrison EG, Losen AM: Primary cancers of the trachea. *Arch Surg* 99: 132-140, 1969
- Ma CK, Fine G, Lewis J, Lee MW: Benign Mixed Tumor of the Trachea. *Cancer* 44: 2260-2266, 1979
- Moersch HJ, Clagett OT, Ellis FH: Tumors of the trachea. *Med Clin North Am* 38: 1091-1096, 1954
- Regezi JA, Lloyd RV, Zarbo RJ, McClatchey KD: Minor salivary gland tumor: A histologic and immunohistochemical study. *Cancer* 55: 108-115, 1985
- Salm R: Primary carcinoma of trachea. A review. *Br J Dis Chest* 58: 61-72, 1964
- Sano T, Hirose T, Hizawa K, Harada K, Komori A, Tanaka N, Morimoto S, Yano Y: A Case of Pleomorphic Adenoma of the Trachea. *Jpn J Clin Oncol* 14: 93-98, 1984
-