

# Anterior cervical discectomy and fusion vs posterior laminoplasty for the treatment of myelopathy due to two-level localized ossification of the posterior longitudinal ligament

Sung Hyun Noh, MD<sup>a,b</sup>, Kyung Hyun Kim, MD, PhD<sup>c</sup>, Jeong Yoon Park, MD, PhD<sup>c</sup>, Sung Uk Kuh, MD, PhD<sup>c</sup>, Dong Kyu Chin, MD, PhD<sup>c</sup>, Keun Su Kim, MD, PhD<sup>c</sup>, Yong Eun Cho, MD, PhD<sup>c,\*</sup>

## Abstract

We conducted a retrospective study to compare the clinical and radiological results of anterior cervical discectomy and fusion (ACDF) and posterior laminoplasty for two-level localized ossification of the posterior longitudinal ligament (OPLL).

ACDF and posterior laminoplasty are performed for localized OPLL at the disc and vertebral body levels, respectively.

Eighty six patients with two-level localized OPLL who underwent surgery from January 2011 to December 2016 were retrospectively investigated (41, ACDF group; 45, laminoplasty group). Clinical outcomes were reviewed, and radiologic results such as occupying ratio (OR), space available in the spinal cord, cranial and caudal OPLL-to-disc distance (ODD)/posterior body height (PBH) ratios, segmental angle, C2–C7 Cobb angle, T1 slope, C2–C7 sagittal vertical axis (SVA), and range of motion were investigated.

Patients were followed-up for an average of  $42.7 \pm 10.5$  months. Clinical outcomes, postoperative OR, and space available in the spinal cord were significantly improved at the final follow-up in both groups. Preoperatively, the OR and cranial and caudal ODD/PBH ratios were not significantly different between the groups. Compared to pre-operative values, differences in the segmental and C2–C7 Cobb angles at the final follow-up were statistically significant for the ACDF group ( $P < .05$ ). The mean operative time, bleeding volume, and the duration of hospitalization were significantly lower in the ACDF group than in the laminoplasty group ( $P < .05$ ). Complications occurred in 1 ACDF case and in 5 laminoplasty cases.

Both ACDF and laminoplasty provided satisfactory clinical and radiologic outcomes for two-level localized OPLL. However, ACDF was associated with a lower operation time, bleeding loss, duration of hospitalization, and complications.

**Abbreviations:** ACCF = anterior cervical corpectomy and fusion, ACDF = anterior cervical discectomy and fusion, CSF = cerebrospinal fluid, CT = computed tomography, JOA = Japanese orthopaedic association, MRI = magnetic resonance imaging, NDI = neck disability index, ODD = ossification of the posterior longitudinal ligament -to-disc distance, OPLL = ossification of the posterior longitudinal ligament, OR = occupying ratio, PBH = posterior body height, PEEK = polyetheretherketone, ROM = range of motion, SVA = sagittal vertical axis, VAS = visual analogue scale.

**Keywords:** anterior cervical discectomy and fusion, complication, laminoplasty, myelopathy, ossification of posterior longitudinal ligament

Editor: Nicandro Figueiredo.

The authors report no conflict of interest concerning the materials or methods used in this study or the funding sources specified in this paper.

The datasets generated during and/or analyzed during the current study are available from the corresponding author on reasonable request.

<sup>a</sup> Department of Neurosurgery, National Health Insurance Service Ilsan Hospital, Goyang, <sup>b</sup> Department of Neurosurgery, <sup>c</sup> Department of Neurosurgery, Spine and Spinal Cord Institute, Gangnam Severance Hospital, Yonsei University College of Medicine, Seoul, Korea.

\* Correspondence: Yong Eun Cho, Department of Neurosurgery, Spine and Spinal Cord Institute, Gangnam Severance Hospital, Yonsei University College of Medicine, Seoul 06273, Korea (e-mail: YECHO@yuhs.ac).

Copyright © 2020 the Author(s). Published by Wolters Kluwer Health, Inc. This is an open access article distributed under the terms of the Creative Commons Attribution-Non Commercial License 4.0 (CCBY-NC), where it is permissible to download, share, remix, transform, and buildup the work provided it is properly cited. The work cannot be used commercially without permission from the journal.

How to cite this article: Noh SH, Kim KH, Park JY, Kuh SU, Chin DK, Kim KS, Cho YE. Anterior cervical discectomy and fusion versus posterior laminoplasty for the treatment of myelopathy due to two-level localized ossification of the posterior longitudinal ligament. *Medicine* 2020;99:33(e20955).

Received: 16 November 2019 / Received in final form: 8 May 2020 / Accepted: 13 May 2020

<http://dx.doi.org/10.1097/MD.00000000000020955>

## 1. Introduction

Ossification of the posterior longitudinal ligament (OPLL) of the cervical spine is perceived as a cause of cervical myelopathy. Various surgical methods for cervical OPLL have been applied and involve surgery using an anterior or a posterior approach. Some surgeons have recommended that the best surgical procedure is an anterior approach with strong fixation after the bone graft, thereby relieving spinal compression with removal of the ossification.<sup>[1]</sup>

Anterior cervical discectomy and fusion (ACDF) can decompress the spinal cord with removal of the OPLL at the disc level and preserve the stability of the cervical spine. Graft migration is rare in ACDF. However, ACDF has some drawbacks, including incomplete decompression, spinal cord injury, limited visibility, and increased rate of pseudoarthrosis.<sup>[2]</sup> Posterior laminoplasty has been considered to be ideally appropriate for patients with multi-level cervical degenerative diseases.<sup>[3]</sup> Laminoplasty enlarges the spinal canal to allow the spinal cord to float away from the ventral OPLL.<sup>[4]</sup> However, laminoplasty involves some risk factors that lead to poor outcomes due to progression of the OPLL, kyphotic alteration of the cervical spine, axial pain, and C5 palsy.<sup>[5,6]</sup> Iwasaki et al reported that the results of

laminoplasty were poor when the occupation rate was >60%, and there was a hill-shape ossification.<sup>[5]</sup> In case of localized OPLL, ACDF and laminoplasty are performed when the OPLL is at the disc and vertebral body levels, respectively. In case of two-level localized OPLL, it is difficult to decide whether to choose laminoplasty or ACDF. We performed ACDF and laminoplasty to treat myelopathy due to two-level localized OPLL. Clinical and radiological outcomes of ACDF and laminoplasty for two-level localized OPLL have not been compared previously. Therefore, this is a retrospective analysis to evaluate the clinical and radiological results of ACDF and laminoplasty for two-level localized OPLL.

**2. Materials and methods**

**2.1. Patients**

The inclusion criteria were as follows: symptoms of cervical myelopathy, with or without radiculopathy caused by OPLL, such as numbness in the hands, weakness of the arms and legs, or trouble using the hands and walking; cervical spine radiograph, computed tomography (CT), and magnetic resonance imaging (MRI) findings showing two-level localized cervical OPLL; and surgery involving ACDF and laminoplasty. The exclusion criteria were as follows: no symptoms caused by OPLL; patients with a history of cervical spine surgery or other cervical spine diseases, including fractures, tumors, and others; and simultaneous anterior and posterior cervical surgery. Eighty six patients with two-level localized OPLL who underwent surgery using ACDF and laminoplasty from January 2011 to December 2016 were retrospectively investigated. Patients were divided into 2 groups: 45 were included in the laminoplasty group and 41 in the ACDF group. The average postoperative follow-up period was 42.7 ± 10.5 months (range, 28–72 months). Demographics and clinical characteristics of all 86 patients are shown in Table 1. This study was approved by the institutional review board of our hospital.

**Table 1**

**Patient demographics.**

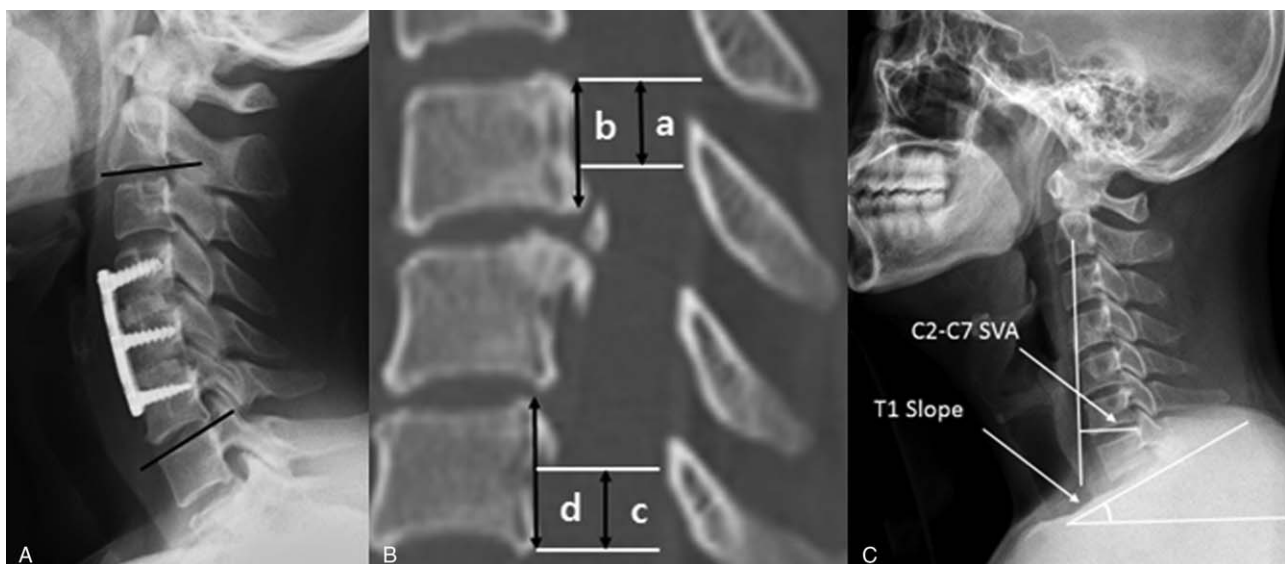
	ACDF (n = 41)	Laminoplasty (n = 45)	P value
Sex			
Female	11	20	
Male	30	25	.089
Mean age, year	55.24 ± 9.12	55.6 ± 7.75	.864
BMI, kg/m <sup>2</sup>	25.07 ± 3.57	24.93 ± 3.76	.86
Smoking			
Yes	7	6	
No	34	39	.629
DM			
Yes	4	8	
No	37	37	.284

\*P < .05 comparing between ACDF and laminoplasty.

ACDF = anterior cervical discectomy and fusion, BMI = body mass index, DM = diabetes mellitus.

**2.2. Radiologic measurements and clinical outcomes**

According to lateral radiographs and/or CT findings, localized OPLL was confirmed. Localized OPLL occurs at the disc level. The extent of the OPLL and space available in the spinal cord were calculated. The occupying ratio (OR) of the OPLL was determined by the ratio of the maximum anteroposterior diameter of the OPLL to the anteroposterior diameter of the spinal canal according to the CT level. The preoperative study included plain radiographs, CT, and MRI. Plain radiological studies of the cervical spine were also performed immediately after surgery and at the last follow-up visit for all patients. All plain radiologic studies were performed with the patient in the standing position. Cervical alignment was measured by the Cobb angle at C2–C7 using the method designed by Borden<sup>[7]</sup>; this angle was arranged by the lines along the inferior endplate of C2 to the inferior endplate of C7 with the patient in the standing position (Fig. 1A). The segmental angle was calculated using the



**Figure 1.** A: Cervical alignment is formed by the lines along the inferior endplate of C2 to the inferior endplate of C7 in the neutral position. The segmental angle is assessed using the Cobb angle of the vertebral bodies adjacent to the involved disc. B: The upper cephalad and lower caudal OPLL-to-disc distance (ODD) and the ODD/anterior body height (ABH) ratio are measured. C: The C2–C7 SVA is defined as the length from the posterosuperior corner of C7 and the vertical line from the center of the C2 body. The T1 slope is defined as the angle between the upper endplate of T1 and the horizontal line.

Cobb angle of the vertebral bodies adjacent to the involved disc. The upper cranial OPLL-to-disc distance (ODD) and lower caudal ODD were also measured. Then, the ODD-to-posterior body height (PBH) ratio was determined using CT (Fig. 1B). The C2–C7 sagittal vertical axis (SVA) was decided as the length from the postero-superior corner of C7 and the vertical line from the center of the C2 body. The T1 slope was defined as the angle between the upper endplate of T1 and the horizontal line (Fig. 1C). The range of motion (ROM) was defined as the difference of the Cobb angle at the extension position from that at the flexion position. We compared the 2 groups using the clinical Japanese Orthopaedic Association (JOA), visual analogue scale (VAS), and neck disability index (NDI) scores, which were assessed preoperatively, immediately postoperatively, and at the last follow-up. The length of the operation; intraoperative blood loss; intraoperative complications such as spinal cord injury, vessel injury, esophageal damage, superior laryngeal nerve injury, and recurrent laryngeal nerve injury; and postoperative complications such as C5 palsy, hematoma, axial neck pain, and implant dislocation were reviewed and analyzed retrospectively.

**2.3. Operative method**

**2.3.1. ACDF.** Patients were placed under general anesthesia in the supine position. ACDF was performed using a standard Smith-Robinson technique. After confirmation and exposure of the appropriate vertebral levels corresponding to the compressive materials, a discectomy was conducted, and a high-speed burr was used to eliminate the anterior and posterior bony spurs and OPLL. If the OPLL did not exceed or only slightly exceeded the vertebral body level at the disc level, then we performed ACDF with removal of the OPLL. The OPLL behind the vertebral body was removed by grinding and thinning the OPLL using a drill and then detaching the OPLL from the dura with a hook. The OPLL was dissected, and other compressive materials were removed to ensure proper dural and neural decompression. Trial spacers were used to decide the relevant size of the polyetheretherketone (PEEK) cage. Using an impactor, the cage was inserted into the center of the disc space. Then, screws were used to place the anterior cervical plate.

**2.3.2. Laminoplasty.** Patients were placed under general anesthesia in the prone position, and the Mayfield skull clamp (Integra LifeSciences Corp., Plainsboro, NJ, USA) was used to stabilize and fixate the position of the head of each patient. Somatosensory- and motor-evoked potentials were monitored for neurologic changes. A midline incision was made at the appropriate region, the paracervical muscle was dissected from the lamina, and the open side of the lamina was determined according to the side of the main symptoms and findings of the preoperative radiologic study. A high-speed electric drill was used to create a gutter and perform laminectomy. To elevate the lamina, the supraspinous, interspinous, and yellow ligaments were removed. After lifting the lamina approximately 1 cm, the Centerpiece open-door plate (Medtronic Sofamor Danek USA, Inc., Memphis, TN, USA) was inserted at each segment. Two screws were inserted in the side of the lateral mass and 2 screws in the lamina side to tightly fix the plate. A hemovac drain was inserted at the surgical site, and the wound was attached along the margin. If there were no surgical complications, all patients were able to sit upright and walk with a neck collar on the first day after surgery. The patients wore a cervical collar for 1 month after surgery.

**2.4. Statistical analysis**

Findings are presented as means ± standard deviations or counts. The *t* test and Chi-Squared test results were used to compare both groups. The OR, space available for the spinal cord, cranial and caudal ODD/PBH, segmental angle, C2–C7 Cobb angle, T1 slope, C2–C7 SVA, and ROM were subjected to univariate analyses. A *P* value <.05 was considered statistically significant, and all statistical analyses were performed using IBM SPSS Statistics version 23.0 (SPSS, Inc., Chicago, IL, USA) and SAS version 9.2 (SAS, Cary, NC, USA).

**3. Results**

**3.1. Patient demographics**

Eighty six patients underwent ACDF and laminoplasty. Table 1 shows detailed demographics of the 2 groups of patients. This study included 55 (64%) men and 31 (36%) women. Patient age ranged from 41 to 75 years (average age, 55.7±8.92 years). Patients were followed-up for an average of 42.7±10.5 months. All patients had two-level localized OPLL.

**3.2. Comparisons of intraoperative blood loss, operative time, hospital length of stay, clinical parameters, and complications**

Intraoperative blood loss, operative time, hospital length of stay, and clinical parameters of the 2 groups are shown in Table 2. The operative time, intraoperative blood loss, and hospital length of stay were lower for the ACDF group than for the laminoplasty group (*P*<.05). The ACDF group showed better clinical recovery. However, differences between the 2 groups for all clinical outcomes were not statistically significant. The NDI, JOA, and VAS scores were improved at the last follow-up (*P*<.0001). There was 1 case of cerebrospinal fluid (CSF) leakage

**Table 2**  
**Comparisons of intraoperative blood loss, operative time, hospital day, clinical parameters, and complications.**

	ACDF(n=41)	Laminoplasty(n=45)	<i>P</i> value
Intraoperative blood loss, ml	88.33±19.69	260.12±22.29	<.001*
Operative time, min	125.56±11.3	251.18±77.07	<.001*
Duration of hospitalization, day	6.23±1.14	8.47±2.55	<.001*
NDI scores			
Preoperative	38.68±1.89	39.72±2.15	
Postoperative	13.56±1.87	14.48±1.56	
Last follow-up	14.68±2.27	15.6±2.35	<.001†
VAS			
Preoperative	8.6±0.65	8.48±0.77	
Postoperative	2.9±0.12	3.02±0.56	
Last follow-up	3.2±0.96	3.32±0.95	<.001†
JOA			
Preoperative	9.32±1.25	8.64±1.35	
Postoperative	15.89±1.74	14.88±1.13	
Last follow-up	15.16±1.14	14.68±1.46	<.001†
Complication			
CSF leakage	1	0	
Axial pain	0	3	
C5 palsy	0	2	

\* *P*<.05 comparing between ACDF and laminoplasty.

† *P*<.05 compared with the preoperative value.

CSF = cerebrospinal fluid, JOA = Japanese orthopedics association, NDI = neck disability index, VAS = visual analog scale.

in the ACDF group, and there were 3 cases of axial pain and 2 cases of C5 palsy in the laminoplasty group.

### 3.3. Comparisons of the radiologic parameters

A representative radiological image is shown for 1 patient in each group in Figures 2 and 3. The segmental angle, C2–C7 Cobb angle, T1 slope, C2–C7 SVA, ROM, OR, space available in the spinal cord, upper cranial and lower caudal ODD/PBH ratios for the 2 groups are shown in Table 3. The postoperative OR and space available in the spinal cord were significantly improved at the final follow-up in both groups. The segmental and C2–C7 Cobb angles at the final follow-up were markedly improved in the ACDF group compared to those at the preoperative assessment ( $P < .05$ ), although clinical outcomes were not significantly different between the 2 groups. The ROM of the laminoplasty group at the final follow-up was better than that of the ACDF group, although there was no significant difference between the 2 groups ( $P > .05$ ).

### 4. Discussion

In many retrospective studies and meta-analyses, there is still controversy about the best surgical method and approach for treating cervical spondylotic myelopathy. In particular, the proper surgical approach for OPLL has been extensively debated. In a systematic review, Li et al<sup>[8]</sup> reported that surgical complications of cervical OPLL are relatively high compared to that of other cervical degenerative diseases. Many studies have compared anterior cervical corpectomy and fusion (ACCF) with laminoplasty, ACCF, and ACDF as methods of treatment for OPLL.<sup>[9,10]</sup> There was no comparison of ACDF and laminoplasty for two-level localized OPLL. In our study, the clinical and radiologic outcomes of ACDF and laminoplasty for two-level localized OPLL were analyzed.

The retrovertebral OPLL below or above the disc level can be easily removed with ACDF, which qualifies for a grade of “B” according to the North American Spine Society (NASS) grades of recommendation.<sup>[11]</sup> However, in case of severe adhesion of the dura to the OPLL, a high degree of technical skill in performing the ACDF is required to successfully remove the OPLL.<sup>[12]</sup> Furthermore, a narrow surgical space increases the risk of CSF leakage and iatrogenic neurological deterioration.<sup>[12]</sup> Currently, there is a growing desire to perform laminoplasty as a routine treatment for extensive posterior decompression of the spinal cord when there are multiple levels of stenosis. Because the posterior cervical paraspinal muscles and ligaments are invaded, many patients suffer posterior neck pain after surgery.<sup>[13]</sup> Because of the indirect decompression of the nerve tissue through laminoplasty, the spinal cord shifts backward, resulting in C5 palsy, and the anterior OPLL may continue to grow.

Subodh et al<sup>[14]</sup> reported no significant difference in the short-term recovery rates between the anterior and posterior approaches to remove the OPLL, but the posterior approach was recommended for multi-segment OPLL. Shamji et al<sup>[15]</sup> conducted a nationwide database study on the length and cost of anterior and posterior approaches, and the anterior approach was found to be associated with less hospitalization and lower cost. Lau et al<sup>[16]</sup> and Ren et al<sup>[17]</sup> reported that the operation time and blood loss associated with ACDF were less than those associated with laminoplasty. This is because it takes a long time to detach the paracervical muscle from the lamina in a

**Table 3**

**Comparisons of radiologic parameters.**

	ACDF (n=41)	Laminoplasty (n=45)	P value
C2-C7 Cobb angle, degree			
Preoperative	13.68±6.42	13.21±7.99	
Postoperative	15.89±5.45	13.45±6.12	
Last follow-up	16.78±6.34	13.44±8.33	
Last follow-up - Preoperation	3.1±0.23	0.2±1.77	<.05*
Segmental angle, degree			
Preoperative	5.8±3.8	4.9±3.89	
Postoperative	6.1±4.49	5.3±3.15	
Last follow-up	6.6±6.17	5.3±3.69	
Last follow-up - Preoperation	1.5±2.03	0.4±1.31	<.05*
T1 slope			
Preoperative	23.5±6.43	24.4±5.01	
Postoperative	22.7±6.08	23.9±4.35	
Last follow-up	22.6±6.28	24.4±5.67	.471
C2-C7 SVA			
Preoperative	20.1±6.02	19.2±5.97	
Postoperative	18.5±6.51	18.9±9.03	
Last follow-up	17.2±1.28	17.1±11.47	.785
Range of motion			
Preoperative	31.2±18.02	33.5±12.4	
Postoperative	19.2±8.21	20.2±7.24	
Last follow-up	18.3±7.57	19.4±9.8	.621
Occupation ratio, %			
Preoperative	44.22±3.52	43.56±3.52	
Postoperative	9.87±6.54	10.87±3.56	
Last follow-up	10.03±2.7	11.52±1.01	<.001†
Space available for the spinal cord, mm			
Preoperative	7.26±1.88	7.23±1.57	
Postoperative	10.23±0.56	10.35±1.12	
Last follow-up	10.11±0.12	10.02±1.35	<.001†
ODD (cranial), mm	6.73±2.68	6.55±2.73	.486
ODD (caudal), mm	6.86±2.69	6.52±3.59	.578
ODD/PBH (cranial)	0.21±0.21	0.23±0.19	.324
ODD/PBH (caudal)	0.34±0.15	0.35±0.23	.678

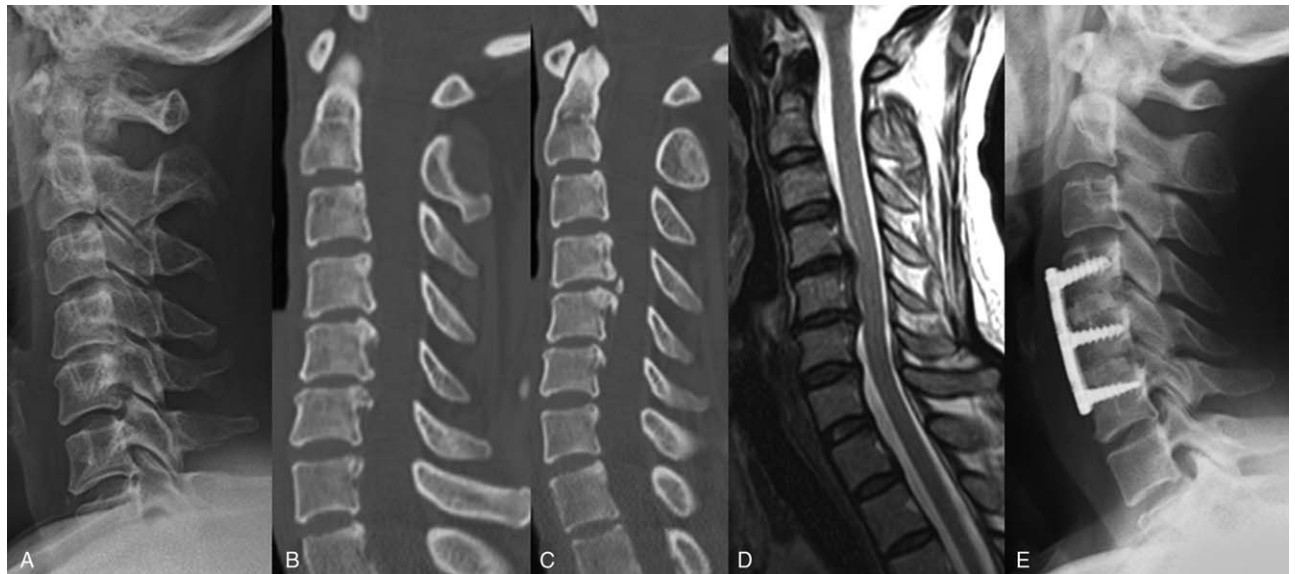\*  $P < .05$  comparing between ACDF and laminoplasty.

†  $P < .05$  compared with the preoperative value.

ACDF = anterior cervical discectomy and fusion, ODD = OPLL-to-disc distance, PBH = posterior body height, SVA = sagittal vertical axis.

laminoplasty, resulting in more blood loss. In our study, intraoperative blood loss, operative time, and duration of hospitalization for the ACDF group were lower than those for the laminoplasty group. There were significant differences in intraoperative blood loss, operative time, and duration of hospitalization ( $P < .05$ ). Additionally, the anterior surgical approach was sufficient for the ACDF group.

Feng et al<sup>[18]</sup> reported that in patients with canal occupation >50% to 60%, the anterior approach group showed a significantly higher postoperative JOA score than the posterior approach group. In meta-analyses, postoperative JOA scores and recovery rates were similar between the 2 groups, especially when the canal occupation was <50% to 60%.<sup>[18]</sup> Fang et al<sup>[19]</sup> reported similar clinical outcomes in ACDF and expansion open-door laminoplasty for treating multilevel cervical myelopathy. But, Dobran et al<sup>[20]</sup> reported that patients treated with posterior fixation had chronic pain associated with stiffness of the neck after cervical spinal trauma surgery. In our study, the mean preoperative canal occupation ratio was 44.22±3.52%. There was no difference between the 2 groups in clinical outcomes. This is probably because the posterior approach does not cause much



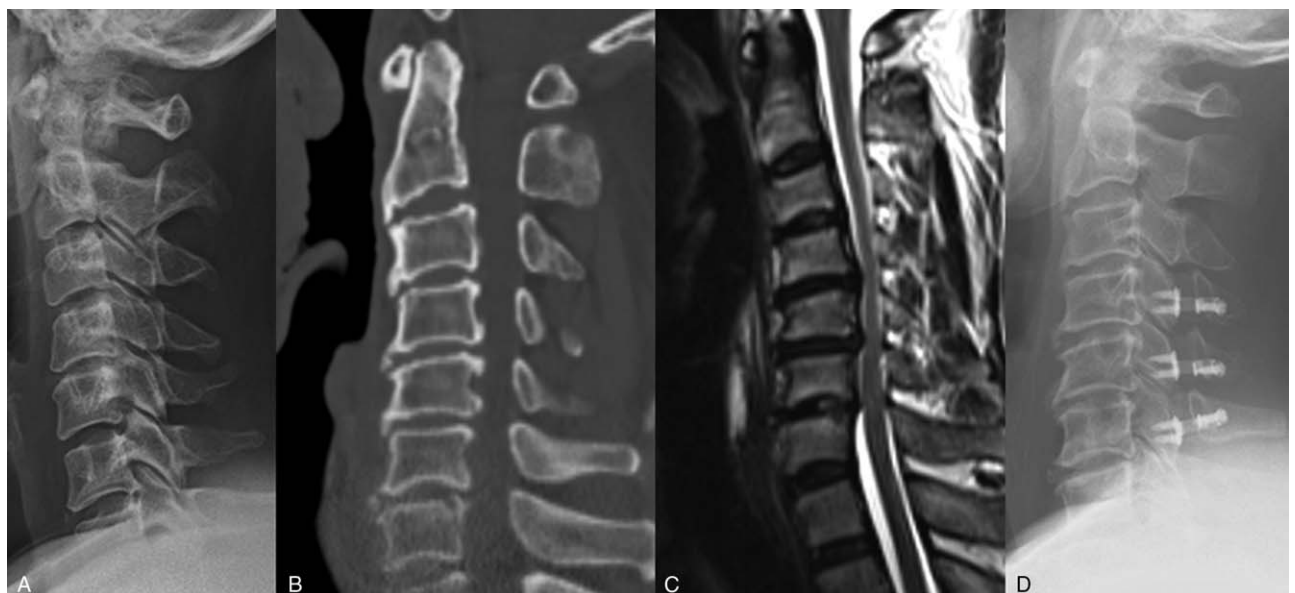
**Figure 2.** A 43-year-old woman presents with cervical spondylotic myelopathy due to OPLL at C4-5-6. Preoperative radiograph (A) and CT (B, C) examinations are performed. Localized OPLL at C4-5-6 on CT; T2W sagittal MRI (D) showing cord compression due to OPLL; ACDF is performed at C4-5-6 (E).

muscle injury when operating the OPLL. Moreover, preoperative clinical outcomes of both groups improved after surgery. There were significance differences in the clinical outcomes between the preoperative period and at the final follow-up ( $P < .001$ ).

In a study by Xu et al,<sup>[21]</sup> major complications of the ACDF group included problems with the graft, adjacent segment degeneration, and postoperative hematoma, while the laminoplasty group had complications such as C5 palsy, axial pain, and posterior arch collapse. Feng et al<sup>[18]</sup> reported that the postoperative complication rate was significantly higher in the anterior surgery group than in the posterior surgery group. This may be due to the inclusion of ACCF and ACDF in the anterior

approach. In our study, complications occurred in 1 case (CSF leakage) in the ACDF group and in 5 cases (3: axial pain, 2: C5 palsy) in the laminoplasty group.

Our study demonstrated that the preoperative segmental angle and C2–C7 Cobb angle were improved after ACDF ( $P < .05$ ). The meta-analysis by Shamji et al<sup>[22]</sup> indicated that preoperative cervical alignment was enhanced after surgery via the anterior approach, and greater changes occurred after ACDF. This was because ACDF can support more distraction and fixation, except for the graft and shaping of the interbody space. ACDF can also restore alignment by pulling the involved vertebral bodies toward the lordotic ventral plate.<sup>[21]</sup> Sakai et al



**Figure 3.** A 57-year-old man presents with cervical spondylotic myelopathy due to OPLL at C4-5-6. Preoperative radiograph (A) and CT (B) examinations are performed. Localized OPLL at C4-5-6 on CT; T2W sagittal MRI (C) showing cord compression due to OPLL; Laminoplasty is conducted at C4-5-6 (D).

reported that C2-C7 lordosis decreased in the laminoplasty group. Using preoperative CT, we measured the cranial and caudal ODD, and the ODD/PBH ratio was calculated. There was no difference between the 2 groups in the cranial ODD, caudal ODD, and ODD/PBH ratio.

Our study has certain limitations. The number of patients who underwent ACDF or laminoplasty was small. Because our study did not have a randomized controlled design, we could not completely control the possibility of selection bias. However, the results of this study suggest that ACDF would be more advantageous in treating two-level localized OPLL.

## 5. Conclusion

ACDF and laminoplasty provided satisfactory clinical and radiologic outcomes for two-level localized OPLL. However, ACDF was associated with a lower operation time, bleeding loss, duration of hospitalization, and complications.

## Author contributions

XXX.

## References

- [1] Sugrue PA, McClendon J, Jamal , et al. Surgical management of cervical ossification of the posterior longitudinal ligament: natural history and the role of surgical decompression and stabilization. *Neurosurg Focus* 2011;30:E3.
- [2] Iwasaki M, Kawaguchi Y, Kimura T, et al. Long-term results of expansive laminoplasty for ossification of the posterior longitudinal ligament of the cervical spine: more than 10 years follow up. *J Neurosurg* 2002;96(2 Suppl):180–9.
- [3] Park AE, Heller JG. Cervical laminoplasty: use of a novel titanium plate to maintain canal expansion—surgical technique. *J Spinal Disorder Tech* 2004;17:265–71.
- [4] Yifu Sun, Le Li, Jianhui Zhao , et al. Comparison between anterior approaches and posterior approaches for the treatment of multilevel cervical spondylotic myelopathy: a meta-analysis. *Clin Neurol Neurosurg* 2015;134:28–36.
- [5] Iwasaki M, Okuda S, Miyauchi A, et al. Surgical strategy for cervical myelopathy due to ossification of the posterior longitudinal ligament: Part 1: clinical results and limitations of laminoplasty. *Spine (Phila Pa 1976)* 2007;32:647–53.
- [6] Kaneyama S, Sumi M, Kanatani T, et al. Prospective study and multivariate analysis of the incidence of C5 palsy after cervical laminoplasty. *Spine (Phila Pa 1976)* 2010;35:E1553–8.
- [7] Borden AG, Rechtman AM, Gershon-Cohen J. The normal cervical lordosis. *Radiology* 1960;74:806–9.
- [8] Li Hai, Li-Yang Dai. A systematic review of complications in cervical spine surgery for ossification of the posterior longitudinal ligament. *Spine J* 2011;11:1049–57.
- [9] Niedzielak TR, Palmer J, Malloy JP4th. Clinical comparison of surgical constructs for anterior cervical corpectomy and fusion in patients with cervical spondylotic myelopathy or ossified posterior longitudinal ligament: a systematic review and meta-analysis. *Clin Spine Surg* 2018;31:247–60.
- [10] Qin R, Chen X, Zhou P, et al. Anterior cervical corpectomy and fusion versus posterior laminoplasty for the treatment of oppressive myelopathy owing to cervical ossification of posterior longitudinal ligament: a meta-analysis. *Eur Spine J* 2018;27:1375–87.
- [11] Kaiser MG, Eck JC, Groff MW, et al. Guidelines for the performance of fusion procedures for degenerative disease of the lumbar spine. *J Neurosurg: Spine* 2014;21:2–16.
- [12] Epstein N. Cervical surgery for ossification of the posterior longitudinal ligament: one spine surgeon's perspective. *Surg Neurol Int* 2014;5(Suppl 3):S88–92.
- [13] Hosono N, Yonenobu K, Ono K. Neck and shoulder pain after laminoplasty. A noticeable complication. *Spine (Phila Pa 1976)* 1996;21:1969–73.
- [14] Jain Subodh K, Salunke Pravin S, Vyas KH, et al. Multisegmental cervical ossification of the posterior longitudinal ligament: anterior vs posterior approach. *Neurol India* 2005;53:283–5.
- [15] Shamji , Mohammed F, Cook , et al. Impact of surgical approach on complications and resource utilization of cervical spine fusion: a nationwide perspective to the surgical treatment of diffuse cervical spondylosis. *Spine J* 2009;9:31–8.
- [16] Lau D, Chou D, Mummaneni PV. Two-level corpectomy versus three-level discectomy for cervical spondylotic myelopathy: a comparison of perioperative, radiographic, and clinical outcomes. *J Neurosurg Spine* 2015;23:280–9.
- [17] Da-Jiang Ren, Fang Li, Zhi-Cheng Zhang, et al. Comparison of functional and radiological outcomes between two posterior approaches in the treatment of multilevel cervical spondylotic myelopathy. *Chin Med J (Engl)* 2015;128:2054–8.
- [18] Feng Fan, Ruan Wenfeng, Liu Zhengye, et al. Anterior versus posterior approach for the treatment of cervical compressive myelopathy due to ossification of the posterior longitudinal ligament: a systematic review and meta-analysis. *Int J Surg* 2016;27:26–33.
- [19] Fang Z, Tian R, Sun T, et al. Expansion open-door laminoplasty with foraminotomy versus anterior cervical discectomy and fusion for coexisting multilevel cervical myelopathy and unilateral radiculopathy. *Clin Spine Surg* 2016;29:E21–7.
- [20] Dobran M, Nasi D, Benigni R, et al. Cervical lordosis after subaxial spinal trauma surgery: relationship with neck pain and stiffness. *G Chir* 2019;40:513–9.
- [21] Xu L, Xu G, Sun H, et al. Anterior cervical discectomy and fusion versus posterior laminoplasty for multilevel cervical myelopathy: a meta-analysis. *Int J Surg* 2017;48:247–53.
- [22] Shamji M, Massicotte E, Traynelis V, et al. Comparison of anterior surgical options for the treatment of multilevel cervical spondylotic myelopathy: a systematic review. *Spine (Phila Pa 1976)* 2013;38(22 Suppl 1):S195–209.