



Two Cases of Facioscapulohumeral Muscular Dystrophy 2 in Korea

Jung Hwan Lee^{1,2}, Hyung Jun Park², Moon-Woo Seong³, Sung Sup Park³, and Young-Chul Choi²

¹Department of Neurology, Seoul St. Mary's Hospital, College of Medicine, The Catholic University of Korea, Seoul;

²Department of Neurology, Yonsei University College of Medicine, Seoul;

³Department of Laboratory Medicine, Seoul National University Hospital, Seoul, Korea.

Facioscapulohumeral muscular dystrophy (FSHD) is an autosomal dominant muscular disorder characterized by weakness of facial, shoulder, abdominal, hip girdle, humeral, and anterior distal leg muscles, with descending progression from the face to the legs in an asymmetric pattern. In about 5% of patients with FSHD, no D4Z4 repeat contraction on chromosome 4q35 is observed; this disease entity is called FSHD2. FSHD2 is characterized by DNA hypomethylation on the 4q-subtelomeric macrosatellite repeat array D4Z4. In Korea, there have been no previous reports of FSHD2. We report the first two cases of FSHD2 in Korea, carrying c.3801delG and c.1580C>T mutations in the *SMCHD1* gene, respectively. For rapid and accurate diagnosis of FSHD2, genetic analysis of the D4Z4 haplotype and methylation with next-generation sequencing are required.

Key Words: Facioscapulohumeral muscular dystrophy, high-throughput nucleotide sequencing, DNA methylation

INTRODUCTION

Facioscapulohumeral muscular dystrophy (FSHD, MIM #158900) is the most common myopathy in adults, with an overall incidence greater than 1:10000. FSHD is transmitted as an autosomal dominant inherited muscle disorder and is clinically characterized by asymmetric weakness of facial, shoulder girdle, trunk, and upper arm muscles that progresses to involve humeral, anterior lower leg, and pelvic girdle muscles, with prominent abdominal muscle weakness. It can also be accompanied by retinal telangiectasia or central nervous system involvement (mental retardation and epilepsy).¹

FSHD1, the major subtype of FSHD, is the result of chroma-

tin relaxation by pathogenic contraction of a macrosatellite repeat, called D4Z4, on the 4q subtelomere of a 4qA allele and a functional polyadenylation signal. However, not all patients with the FSHD clinical phenotype manifest D4Z4 pathogenic contraction.² Five percent of FSHD patients have a low to normal number of repeats on chromosome 4q35. Instead, they show profound DNA hypomethylation with pathogenic variants of the *SMCHD1* or *DNMT3B* gene and the 4qA variant with a polyadenylation signal.³ These patients are diagnosed with FSHD2 due to the similar clinical phenotype with FSHD1. While FSHD2 patients were first reported in Western countries and then in Japan, there have been no reports of FSHD2 in Korea. We report two Korean patients with FSHD2 due to a novel frameshift and a reported point mutation in the *SMCHD1* gene.

Received: June 16, 2020 **Revised:** October 27, 2020

Accepted: November 2, 2020

Corresponding author: Young-Chul Choi, MD, PhD, Department of Neurology, Gangnam Severance Hospital, Yonsei University College of Medicine, 211 Eonju-ro, Gangnam-gu, Seoul 06273, Korea.

Tel: 82-2-2019-3323, Fax: 82-2-3462-5904, E-mail: ycchoi@yuhs.ac

Case 1 in our case report was presented in 15th International Congress on Neuro-muscular Diseases.

•The authors have no potential conflicts of interest to disclose.

© Copyright: Yonsei University College of Medicine 2021

This is an Open Access article distributed under the terms of the Creative Commons Attribution Non-Commercial License (<https://creativecommons.org/licenses/by-nc/4.0>) which permits unrestricted non-commercial use, distribution, and reproduction in any medium, provided the original work is properly cited.

CASE REPORT

Case 1

A 40-year-old male visited our clinic for asymmetric upper and lower extremity weakness. The patient reported that he had suffered bilateral shoulder weakness since the age of 10 years. When he was 13-years-old, he presented with a right winged scapula. In addition, he reported bilateral leg weakness since he was 24 years old. Physical examination revealed a trans-

verse smile; winged scapula; “Popeye” arm appearance; facial weakness; and asymmetric, proximal dominant arm and leg weakness (right side more severe than the left). Serum creatinine kinase levels were mildly elevated at 319 unit/L. His father and elder brother had similar symptoms (Fig. 1A). His elder brother had been visiting another hospital for similar symptoms since he was 10 years old, and his muscle pathology showed severe chronic myopathic changes (marked increased size variability, hypertrophic fibers, degenerating and atrophic fibers, endomysial fibrosis and mild fatty infiltration, disruption of intermyofibrillar network, and lobulated fibers) with normal dystrophin immunoreactivity. The elder brother was diagnosed with FSHD based on clinical phenotype, but refused a genetic study. However, our patient agreed to undergo genetic analysis for diagnosis. Therefore, we performed conventional Southern blot analysis with *EcoRI* and *BlnI* enzymes, but the D4Z4 repeat size was 12, which is normal. Next, whole exome sequencing revealed a novel frameshift mutation (c.3801delG, p.Glu1267Aspfs*5) in *SMCHD1* [Fig. 1B, upper (patient) and lower (mother) panels], a mutation that has not been described in previous reports or public databases (ExAC, ESP6500, 1000 genome). Finally, methylation-sensitive Southern blot analysis with *FseI* showed mildly reduced D4Z4 repeat size on 4q (41kb/39kb) and reduced D4Z4 methylation ratio (14.6%). Accordingly, we could report our case 1 as “pathogenic” and carrying a novel variant, as indicated in ACMG-AMP guidelines.⁴

Case 2

A 38-year-old male visited our clinic for asymmetric upper extremity weakness. The patient reported that, at the age of nine, he had difficulty performing iron bar gymnastics. Since his third decade, he experienced prominent right shoulder and arm weakness, and he presented with facial asymmetry and

weakness. Physical examination showed a transverse smile, positive Beevor’s sign, and winged scapula (Fig. 2B). In addition, he showed facial and bilateral arm and leg weakness with proximal dominance and asymmetry (right side more severe than the left) on neurological examination. Serum creatinine kinase levels were mildly elevated at 224 unit/L. His mother and elder sister had similar symptoms (Fig. 2A). We performed genetic analysis for FSHD. Southern blotting analysis by the *EcoRI/BlnI* digestion method using genomic DNA revealed that a fragment size of 37 kb, and the number of D4Z4 repeats was nine. Bisulfite sequencing to determine the haplotype of D4Z4 using digestion with *HindIII* and hybridized with 4qA probe and target sequencing analysis to screen for mutations in the *SMCHD1* gene by a next-generation sequencer (Ion PGMTM) were performed for FSHD2 diagnosis. We found reduced DNA methylation ratio (16.8%), D4Z4 haplotype 4qA (homozygous), and c.1580C>T (p.T527M) *SMCHD1* mutation, which was previously reported to be a pathogenic allele.⁵

Informed consent was obtained from the two patients regarding the reporting and publication of this case report.

DISCUSSION

We report the first two cases of FSHD2 in Korea. Since 2008, there have been some reports in patients with FSHD1. In Korea, all studies of FSHD have been performed in patients with confirmation of D4Z4 contraction.⁶⁻⁸ Those studies reported the following; 1) facial muscles are initially affected, and an asymmetric face and shoulder girdle weakness, winging scapular, transverse smile, and Beevor’s sign are important findings;⁷ 2) most Korean FSHD1 patients (102/108 patients, 94.4%) carry one to six units of D4Z4 repeat;^{6,8} 3) female are more severely affected than male, even though there are no differences

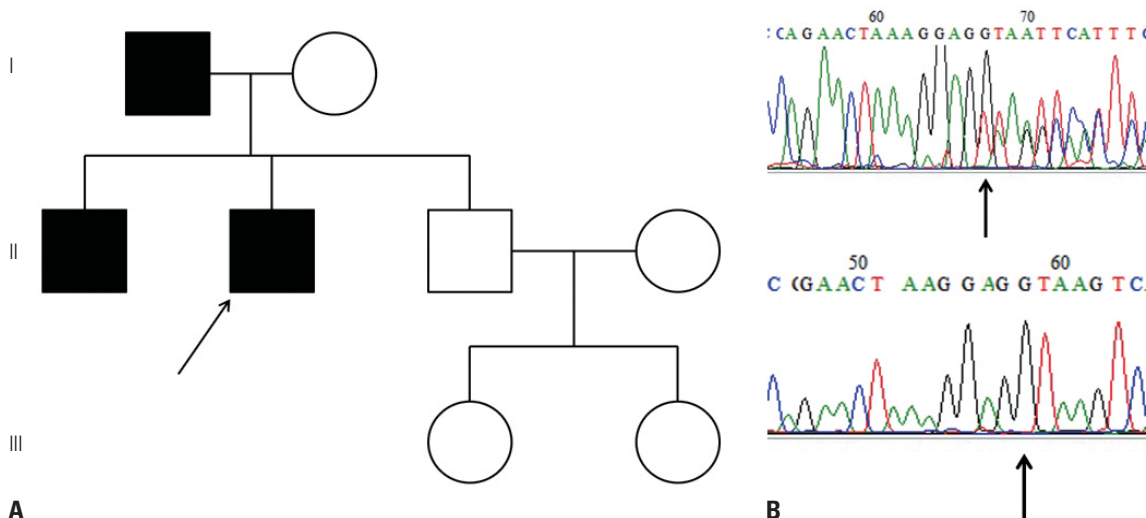


Fig. 1. Family pedigree and validation data of case 1. (A) Pedigree. The patient’s father and elder brother showed similar symptoms. Arrow: patient. (B) Validation. Upper, patient; Lower, patient’s mother.

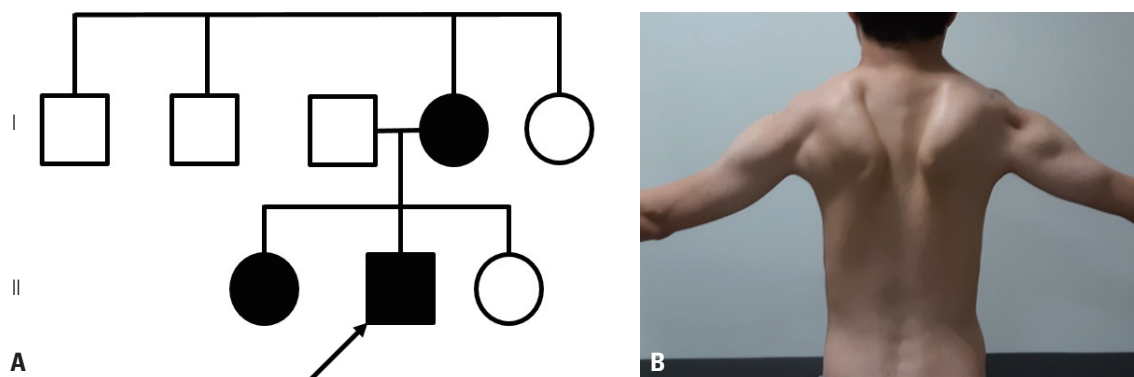


Fig. 2. Family pedigree and winged scapula of case 2. (A) Pedigree. The patient's mother and elder sister showed similar symptoms. Arrow: patient. (B) Winged scapula.

in age at examination or in D4Z4 copy number between the two sexes.⁸

In case 1, the patient and his brother showed the typical FSHD phenotype; however, a conventional Southern blot study showed low to normal D4Z4 repeat size. Re-analysis of the D4Z4 repeat size showed mild contraction (nine repeats). In case 2, Southern blot analysis showed nine D4Z4 repeats. Previous Korean and Japanese reports of patients with FSHD,^{8,9} revealed that most East Asian FSHD1 patients have one to six D4Z4 repeats, although four of 13 FSHD2 patients in Japan had nine to 10 D4Z4 repeats.⁹ The two present cases had nine homozygous repeats or 9/10 repeats of D4Z4. Considering previously reported genetic profiles of East Asian FSHD1 and FSHD2 cases, FSHD2 is a more likely diagnosis than FSHD1+2 or FSHD1 for diagnosis in our cases. *SMCHD1* mutation has been reported as modifier of disease severity in FSHD families,⁵ although through some case series and studies, researchers have suggested that mildly contracted D4Z4 repeats with *SMCHD1* mutation may be important for the development.⁹

The mutation in case 1 was a frameshift mutation causing a truncated protein, and we confirmed that DNA methylation was decreased. Lemmers, et al.² previously reported 45 mutations in 51 of 60 families with FSHD2. Two families from the USA and South Korea showed a splicing site mutation (c.3801+1G>A, exon 29 skipping) near the site of the mutations, similar to the present cases, but a different type of mutation.

Mild dysphagia in early stages was observed in some patients (3 of the 13 patients) with *SMCHD1* mutations in a Japanese study,⁹ and they did not find any other clinical findings of FSHD2. Dysphagia is commonly presented in FSHD at late advanced stages.¹ Our patients did not have any subjective swallowing difficulty. Unfortunately, we did not perform objective evaluation for dysphagia, and thus we do not know whether they had “silent aspiration” without any cough or outward signs of aspiration. Dysphagia could be a distinctive feature of FSHD2, but needs additional study.

We report the first confirmed cases of FSHD2 due to novel frameshift mutation and reported point mutation in Korea with detailed clinical manifestation. We suggest genetic analy-

sis of the D4Z4 haplotype and methylation as important diagnostic steps for accurate diagnosis of FSHD, and whole exome sequencing is another option in Korea.

AUTHOR CONTRIBUTIONS

Conceptualization: Young-Chul Choi. **Data curation:** Jung Hwan Lee, Moon-Woo Seong, and Sung Sup Park. **Formal analysis:** Jung Hwan Lee, Moon-Woo Seong, and Sung Sup Park. **Funding acquisition:** Young-Chul Choi. **Investigation:** Jung Hwan Lee and Hyung Jun Park. **Methodology:** Jung Hwan Lee and Young-Chul Choi. **Project administration:** Young-Chul Choi. **Resources:** Young-Chul Choi. **Software:** Jung Hwan Lee. **Supervision:** Hyung Jun Park and Young-Chul Choi. **Validation:** Young-Chul Choi. **Visualization:** Jung Hwan Lee. **Writing—original draft:** Jung Hwan Lee. **Writing—review & editing:** Jung Hwan Lee and Young-Chul Choi. **Approval of final manuscript:** all authors.

ORCID iDs

Jung Hwan Lee	https://orcid.org/0000-0002-0040-7236
Hyung Jun Park	https://orcid.org/0000-0003-4165-8901
Moon-Woo Seong	https://orcid.org/0000-0003-2954-3677
Sung Sup Park	https://orcid.org/0000-0003-3754-4848
Young-Chul Choi	https://orcid.org/0000-0001-5525-6861

REFERENCES

1. Sacconi S, Salviati L, Desnuelle C. Facioscapulohumeral muscular dystrophy. *Biochim Biophys Acta* 2015;1852:607-14.
2. Lemmers RJ, Goeman JJ, van der Vliet PJ, van Nieuwenhuizen MP, Balog J, Vos-Versteeg M, et al. Inter-individual differences in CpG methylation at D4Z4 correlate with clinical variability in FSHD1 and FSHD2. *Hum Mol Genet* 2015;24:659-69.
3. Hamel J, Tawil R. Facioscapulohumeral muscular dystrophy: update on pathogenesis and future treatments. *Neurotherapeutics* 2018;15:863-71.
4. Richards S, Aziz N, Bale S, Bick D, Das S, Gastier-Foster J, et al. Standards and guidelines for the interpretation of sequence variants: a joint consensus recommendation of the American College of Medical Genetics and Genomics and the Association for Molecular Pathology. *Genet Med* 2015;17:405-23.
5. Sacconi S, Lemmers RJ, Balog J, van der Vliet PJ, Lahaut P, van Nieuwenhuizen MP, et al. The FSHD2 gene *SMCHD1* is a modi-

- er of disease severity in families affected by FSHD1. *Am J Hum Genet* 2013;93:744-51.
6. Ki CS, Lee ST, Kim KS, Kim JW, Hong YH, Sung JJ, et al. Clinical and genetic analysis of Korean patients with fascioscapulohumeral muscular dystrophy. *J Korean Med Sci* 2008;23:959-63.
 7. Hong JM, Kim SM, Sunwoo IN, Seo KD, Shim DS, Suh BC, et al. Clinical features and genetic analysis of fascioscapulohumeral muscular dystrophy. *J Korean Neurol Assoc* 2009;27:42-8.
 8. Park HJ, Hong JM, Lee JH, Lee HS, Shin HY, Kim SM, et al. Low D4Z4 copy number and gender difference in Korean patients with fascioscapulohumeral muscular dystrophy type 1. *Neuromuscul Disord* 2015;25:859-64.
 9. Hamanaka K, Goto K, Arai M, Nagao K, Obuse C, Noguchi S, et al. Clinical, muscle pathological, and genetic features of Japanese fascioscapulohumeral muscular dystrophy 2 (FSHD2) patients with *SMCHD1* mutations. *Neuromuscul Disord* 2016;26:300-8.