Anatomical Consideration For Effective Botulinum Neurotoxin Injection In Masseteric Hypertrophy

Su-Jin Jung, D.D.S.

Department of Dentistry

The Graduate School, Yonsei University

Anatomical Consideration For Effective Botulinum Neurotoxin Injection In Masseteric Hypertrophy

Directed by Professor Hee-Jin Kim, D.D.S., Ph.D.

The Doctoral Dissertation
submitted to the Department of Dentisry,
and the Graduate School of Yonsei University
in partial fulfillment of the requirements
for the degree of Doctor of Philosophy

Su-Jin Jung

June 2020

This certifies that the Doctoral Dissertation of Su-Jin Jung is approved.

Thesis Supervisor : **Prof. Hee-Jin Kim**

Thesis Committee Member : **Prof. Kyung-Seok Hu**

Thesis Committee Member : **Prof. Han-Sung Jung**

Thesis Committee Member : **Prof. Sung-Won Cho**

Thesis Committee Member : **Prof. Young-Chun Gil**

The Graduate School
Yonsei University

June 2020

ACKNOWLEDGEMENTS

대학 졸업 후, 7년의 시간이 지나 다시 공부를 시작하는 것이 쉽지않은 선택이었는데, 석사 과정을 힘겹게 마친 후 박사 과정에 또다시 도전한다는 것은 정말 힘든 결정이었습니다.

'과연 내가 해낼 수 있을까?' 라는 의구심으로 주저하고 고민할 때, 저를 격려하고 지지해주는 주변 분들의 많은 도움이 있었기에 다시 시작할 수 있다는 용기를 낼 수 있었고, 6년의 시간을 포기하지 않고 끝까지 노력하여 소중한 결실을 맞이할 수 있었습니다. 이제 그동안 제가 흔들리지 않고 목표를 향해 나아갈 수 있도록 격려하고 응원해주신 많은 분들에게 감사의 마음을 전하고자 합니다.

먼저, 저의 멘토이자 지도교수이신 김희진 교수님께 무한한 감사의 마음을 전하고 싶습니다. 처음 석사 과정을 시작할 때도, 다시 박사 과정을 결정할 때도 불안해하는 저를 다독이고 격려하며 용기를 주셨습니다. 교수님의 넓고 깊은 가르침과 끊임없는 격려, 애정이 담긴 질타가 없었다면 지금 이 자리에서 감사의 말을 전하는 저 또한 없었을 것입니다. 그리고 긴 시간 동안 아낌없는 조언과 애정으로 대학원 생활에 잘 적응할 수 있도록 보살펴 주신 허경석 교수님께 마음 깊이 감사드립니다. 또한, 논문 심사 과정에서 아낌없는 지도로 많은 가르침을 주신 정한성 교수님, 조성원 교수님, 길영천 교수님, 매 학기마다 열정적으로 심도 있는 강의를 해주신 치과대학 모든 교수님들께 고개 숙여 감사드립니다.

학업과 본업(병원일)을 병행하느라 힘들어 하는 저를 물심양면으로 도와준 해부학 교실 이형진 선생님과 나이 많은 제가 대학원 생활에 잘 적응할 수 있도록 따뜻하게 감싸주며 챙겨준 해부학교실 식구들에게도 진심으로 고마운

마음을 전합니다. 여러 선생님들의 도움이 없었다면 병원을 운영하면서 평택(서정리)에서 서울까지 대학원을 다니면서 논문을 완성한다는 것은 불가능했을 것입니다.

대학원 수강으로 바쁜 원장을 위해 병원의 여러 가지 일들을 꼼꼼하게 챙기고 성심을 다해 준 이경 실장을 비롯한 병원 식구들에게도 고마운 마음과 사랑을 전합니다.

마지막으로, 뒤늦게 공부를 다시 시작한 딸의 뒷바라지를 위하여 헌신하신 부모님께 존경과 사랑을 전합니다. 대학원 수업이 있는 날이면 새벽 4시에 저와 같이 일어나 챙겨주시고, 역까지 배웅해 주신 어머니의 희생과 사랑이 없었더라면 오늘의 이 결실도 없었으리라 생각합니다. 늦은 공부로 육체적으로나 정신적으로 힘들 때마다 걱정해주고 격려해준 수연 언니와 형부, 동생 성헌이에게도 고마운 마음을 전합니다. 다시 한번 나를 믿고 지지해주는 부모님과 가족들에게 감사와 사랑을 전하며 이 논문을 바칩니다.

2020 년 6 월

저자 씀

TABLE OF CONTENTS

LIST OF FIGURES

LIST OF TABLES

Abstract

Anatomical Consideration For Effective Btolinum Nerotoxin Injection In Masseteric Hyperetrophy

Su-Jin Jung, D.D.S

Department of Dentistry
The Graduate School, Yonsei University

(Directed by Professor Hee-Jin Kim D.D.S., Ph.D.)

Masseter muscle consist of three layers with the superficial part being the biggest among them. The three layers of the masseter muscle fiber interweave at the inferior region, therefore, thickens it. However, it has recently been reported that the superficial part of the superficial muscle belly of the masseter muscle is composed not only of the muscle belly but also of the strong deep inferior tendon (DIT) within the muscle belly at the inferior region of the masseter muscle. But previous studies lacked information regarding the depth of the DIT. Therefore, the purpose of this study was to offer a safer and more effective BoNT injection point and strategy by determining the type of DIT via US that has been revealed through the previous cadaveric study. We also measured the precise depth

and location of the DIT of the masseter muscle.

Thirty two healthy volunteers [16 males and 16 females: age, 25.4±4.1 years (mean±SD)] participated in this study and the masseter muscle were scanned both longitudinally and transversely via ultrasonography (E-CUBE 15 EX, ALPINION, SEOUL, KOREA, IRB NO. 2-2017-0023).

All the subjects with both sides had DIT of the masseter muscle observed in the US images. Type A with DIT covering the reference line B and C (anterior two thirds of masseter muscle) was observed in 21.8% (7/32). Type B with DIT covering the reference line C and D (posterior two thirds) was observed in 9.4% (3/32). Type C with DIT covering the reference line B, C, and D, was observed in 68.8% (22/32). The depth of DIT tends to be deeply located inferiorly and superficially superiorly. However, DIT maintained constant depth transversely from anterior to posterior of the masseter muscle. Depending on the point of location, the depth of skin to mandible in masseteric region was ranged from 15 to 25 mm. The DIT was located approximately 2 to 5 mm deep from the mandible.

Based on complex DIT form, we believe that ultrasound can be used to observe the patient's internal structure of the masseter muscle in advance including the DIT, and reduce side effects of masseteric bulging by applying retrograde or dual plane injection methods depending on the type of DIT. Additional data regarding the depth of the deep tendon will become critical anatomic data and be helpful in managing the masseteric bulging following the botulinum neurotoxin injection for masseteric hypertrophy, bruxism, or asymmetrical face.

Key words :masseter muscle; deep inferior tendon (DIT); depth of DIT; type of DIT; masster hypertrophy; BoNT injection; ultrasonography;

Anatomical Consideratioin for Effective Botulinum Neurotoxin Injection In Masseteric Hypertrophy

Su-Jin Jung, D.D.S

Department of Dentistry,
The Graduate School, Yonsei University

(Directed by Professor Hee-Jin Kim D.D.S., Ph.D.)

I. Introduction

As the world-wide trend towards the beauty in women is to have a smooth line of the face and a slim jawline, the botulinum neurotoxin (BoNT) injection for facial contouring is widely performed since procedure has been introduced by Moore in 1994 (Liew, et al., 2016; Moore and G.D., 1994; Rhee and S.H., 2010). Especially, hypertrophied masseter muscle is

commonly treated for Asians because they have relatively angular faces than Caucasian.

The masseter muscle is situated on the lateral side of the face and works strongly in mastication with the temporalis muscle. Lower one-third of masseter muscle is known to be thickest part (Kim et al., 2016). The conventional BoNT injection to masseter muscle is by deep injection after bony touch of mandible, primarily into the lower part (Kwon et al., 2009; Shim et al., 2010; Xie et al., 2014). Even if BoNT treatment is valuable for alleviating facial asymmetry and nasal flare (Carruthers, J. and A., 2003) or facial rhytids of upper, mid, and lower face (Kim et al., 2016; Chang and G.C., 2016; Lee et al., 2019; Lee et al., 2018), several iatrogenic side effects have been continually reported. Thorough understanding of the anatomical knowledge of locations and morphology, relationship between the masseter and risorius muscle, and related vascular structure is required for practitioners to avoid side effects. Most common side effect is local swelling caused by mechanical vascular damage that is observed in 6.3%-22.7% of the patients, which normally recovers within two to three days or a week. (Al-Muharraqi et al., 2009; Gaofeng et al., 2010; Kim et al., 2007; Wei et al., 2015; ; Yeh, J.H. and H.P., 2018). The masseteric bulging is another side effect, observed in 0.49~18.8%, can occur two or four weeks later after BoNT injection (Lee et al., 2016; Lee et al., 2019). Presence of abnormal facial expression is another side effect observed in 15~27.3% of the patients. This is due to overspread of the toxin to the risorius muscle next to anterior part of the masseter muscle (Yeh, J.H. and H.P., 2018; Bae et al., 2014).

The masseteric bulging can be managed with additional injection of BoNT, which usually disappears within 12 weeks. However, frequent injection of BoNT results in production of antibodies reducing the efficacy of treatment (Hsu, J.S. and K.A., 2004; Lepage et al., 2005; Kinett, 2004;). Therefore, various clinical studies have been performed to provide the BoNT injection point to avoid masseteric bulging and increase in durability of the BoNT (Lee et al, 2016; Lee et al., 2019). These studies regarding BoNT injection to the masseter muscle have focused on the volume changes evaluated by ultrasonography, 3-dimensional laser scanning, computed tomography, or magnetic resonance imaging. In all evaluations, it has been concluded that the BoNT injection to masseter muscle was effective for the aesthetic purposes. However, there are remaining concerns about masseteric bulging and other side-effects due to lack of internal architecture of the masseter muscle suggesting the most effective BoNT injection points or strategy to manage the masseteric bulging.

The deep inferior tendon (DIT) of the masseter muscle is located within the superficial part of the masseter muscle. The DIT blocks the BoNT from spreading evenly throughout the superficial masseter. This DIT can be easily observed using ultrasound imaging of masseter muscle. Masseteric bulging can be prevented by ultrasound guided injection by locating DIT of masseter muscle within the accurate depth.

Ultrasonography (US) is a device which monitors internal anatomical structure in real-time. Although it is less commonly used in the facial area, it is often used in observing masticatory muscles for diagnosing the bruxism and temporomandibular joint diseases. Recently, the anatomical

morphology regarding temporomandibular joint or masseter muscle are continuously conducted in clinical and cadaveric researches (Lee et al, 2016; Lee et al., 2019; Friedman et al., 2020; Cha et al., 2019). Therefore, the purpose of this study was to offer a safer and more effective BoNT injection point and strategy by determining the type of DIT via US that has been revealed through the previous cadaveric study. We also measured the precise depth and location of the DIT of the masseter muscle.

II. Materials and Methods

All the experimental procedures in this study were performed in accordance with the Declaration of Helsinki of the World Medical Association. The research was approved by the institutional review board of the Yonsei University College of Dentistry (Approval No. 2-2016-0024, granted on September 29, 2016). A real-time two-dimensional B-mode US system (ECUBE 15, ALPINION Medical Systems, Seoul, Korea) with a 60-mm-wide linear-array transducer (3.0 - 15.0 MHz; L8-17X, ALPINION Medical Systems) was used to obtain US images of the masseter muscle in healthy young subjects.

Ultrasonography scanning of healthy young subjects

Signed written informed consents were obtained from 32 healthy young subjects [16 males and 16 females: age, 25.4±4.1 years (mean±SD)].The exclusion criteria were orthodontic treatment, temporomandibular joint disorder, plastic surgery, or receiving a BoNT injection within the previous 6 months. The subjects were asked to clench their jaws to ensure that the precise anterior and posterior borders of the masseter muscle could be identified in prior to performing US scanning. The following lines were designated as a longitudinal and transverse reference lines for US imaging of the masseter muscle (**Fig. 1**).

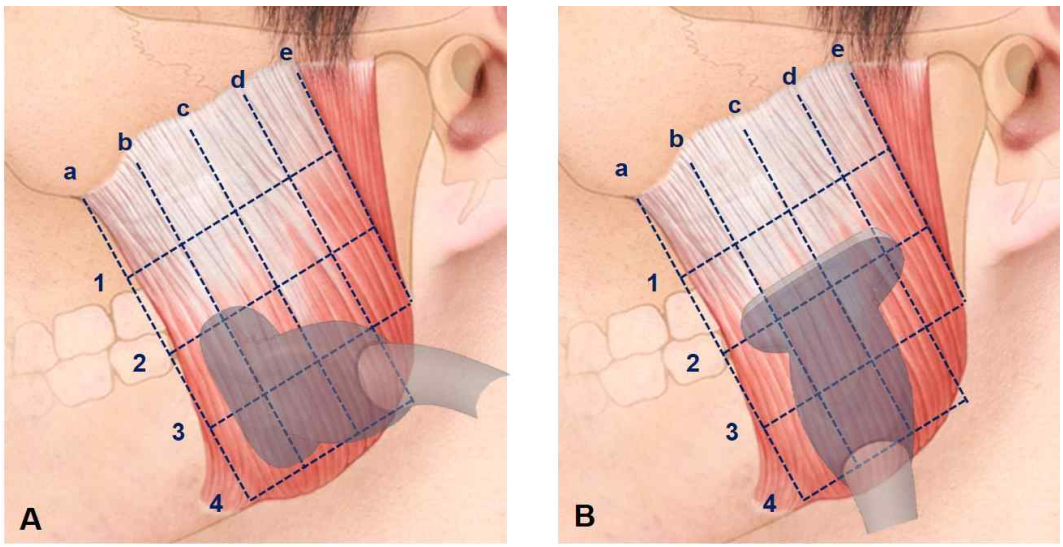

Figure 1. Ultrasonography scanning sites. Longitudinal section scanning was performed along the reference lines b, c, and d of the masseter muscle (A). Transverse section scanning was performed along the reference line 2 and 3 of the masseter muscle (B). Longitudinal reference lines is as follow: anterior border of the masseter m. (a); half-way point between a and c (b); half-way point between anterior (a) and posterior border (e) of the masseter m. (c); half-way point between c and e (d); posterior border of the masseter m. (e). Transverse reference lines (4 lines) are as follow: half-way point between inferior margin of zygomatic arch and line (1); half-way point between origin and insertion of the masseter m. (2); half-way point between line 2 and line 4 (3); inferior margin of the mandible (4).

Longitudinal reference lines (5 lines)

A: anterior border of the masseter m.

B: half-way point between A and C

C: half-way point between anterior (A) and posterior border (E) of the masseter m.

D: half-way point between C and E

E: posterior border of the masseter m.

Transverse reference lines (4 lines)

1: half-way point between inferior margin of zygomatic arch and line 2

2: half-way point between origin and insertion of the masseter m.

3: half-way point between line 2 and line 4

4: inferior margin of the mandible

The US sampling frequency was set to 15.0 MHz, which is an ideal frequency for observing depth between 2.5 cm and 4 cm, depending on the histological components (skin, fat, and muscle) of individuals. The water-soluble gel was applied to the skin to optimize the acquisition of images to prevent artifacts. The US transducer was positioned over the area of the masseter muscle perpendicular to the skin surface. The imaging was performed on both sides of the face. The DIT of the masseter muscle and its location were confirmed by cross checking the transverse and longitudinal US image.

The morphology of the DIT was classified based on the previous study that divided into three types. The pattern, in which the DIT covered the reference line B and C, was designated as a Type A. The pattern, in which the DIT covered the reference line C and D, was designated as a Type B. The pattern, in which the DIT covered the reference line B, C, and D, was designated as a Type C.

The depth from the skin to mandible and from the mandible to DIT at each reference lines were measured using an Image J software (**Fig. 2**).

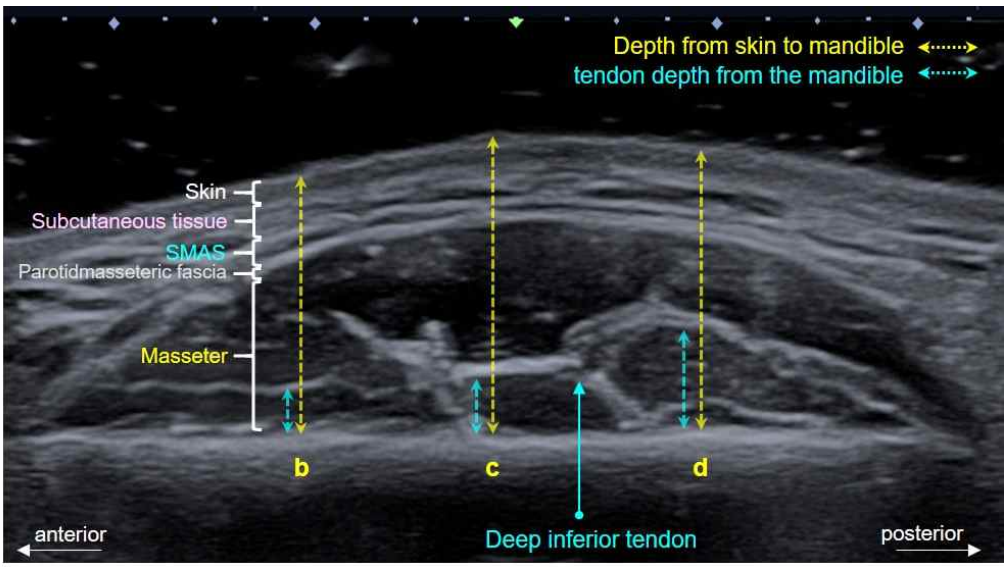

Figure 2. Transverse ultrasonography image depicting the masseteric area including deep inferior tendon within the muscle. The depth from the skin to mandible (yellow dashed line) and from mandible to DIT (blue dashed line) at reference lines B, C, and D were measured on the transverse ultrasonography. Longitudinal reference lines is as follow: half-way point between anterior border of the masseter m. and c (b); half-way point between anterior and posterior border of the masseter m. (c); half-way point between c and posterior border of the masster m. (d).

III. Results

Types of the DIT from the healthy young subjects

All the subjects with both sides had DIT of the masseter muscle observed in the US images. The DIT was classified into three types according to the covered area within the masseter muscle (**Fig. 3**). Type A with DIT covering the reference line B and C (anterior two thirds of masseter muscle) was observed in 9.4% (7/32). Type B with DIT covering the reference line C and D (posterior two thirds) was observed in 21.9% (3/32). Type C with DIT covering the reference line B, C, and D, was observed in 68.8% (22/32). The DIT was more easily detectable on the longitudinal image than the transverse image. There were no significant differences in classification between the gender, age, and left and right sides.

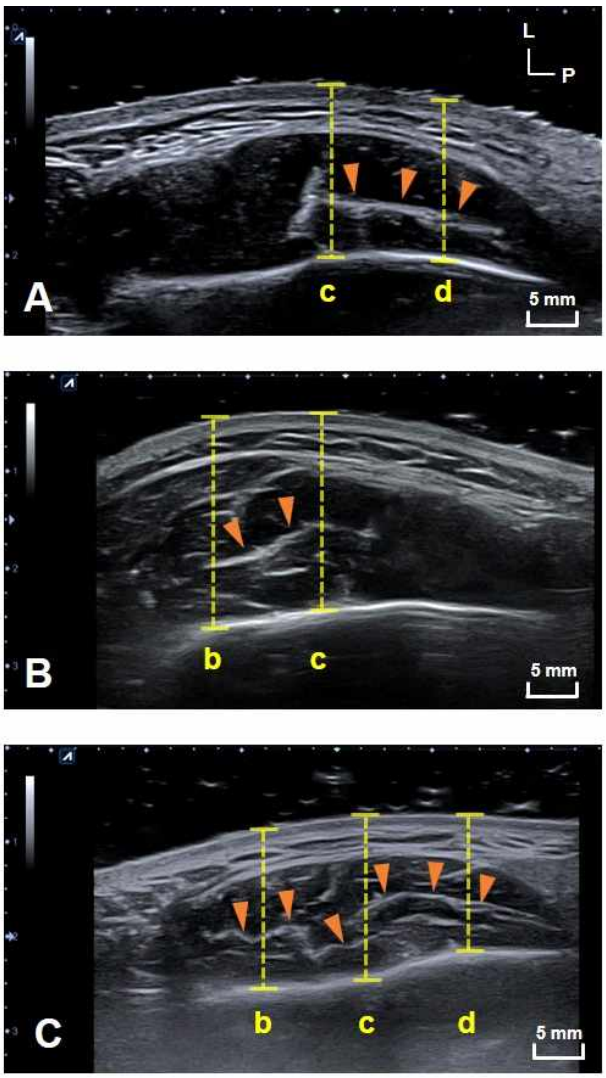

Figure 3. Transverse ultrasonography images showing the three pattern of the deep inferior tendon (DIT). An ultrasonography image of the C and D covered pattern (A) and B and C covered pattern (B). An ultrasonography image of the B, C, and D covered pattern (C). The yellow dashed line indicates depth from the skin to mandible. Longitudinal reference lines is as follow: half-way point between anterior border of the masseter m. and

c (b); half-way point between anterior and posterior border of the masseter m. (c); half-way point between c and posterior border of the masster m. (d). L, lateral; P, posterior; orange arrow he ads, DIT.

Depth at each reference lines

The depth of the DIT at each reference lines is presented in Figure 4 and detailed information regarding the depth of the DIT is presented in Table 1. The depth of DIT tends to be deeply located inferiorly and superficially superiorly. However, DIT maintained constant depth transversely from anterior to posterior of the masseter muscle (**Fig. 4**).

Depending on the point of location, the depth of skin to mandible in masseteric region was ranged from 15 to 20 mm. The DIT was located approximately 2 to 4 mm deep from the mandible. Proportionally, the DIT can be found in the range between 15 to 25%, respective from the skin to the mandibular surface (**Fig. 5**).

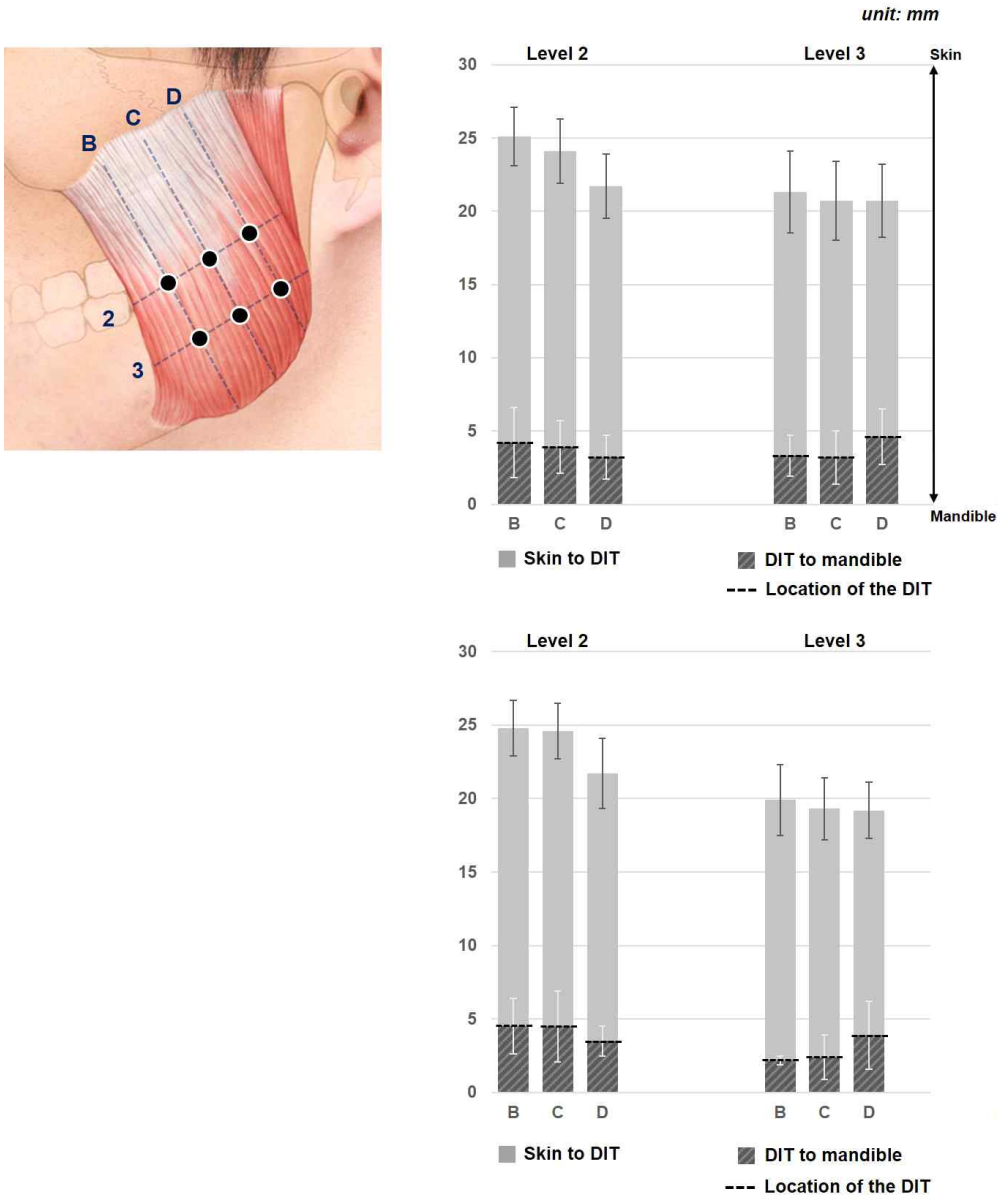

Figure 4. Graphical depth from the skin to DIT and from the DIT to mandible at the masseteric area. The dashed line indicates the location of the DIT within the master muscle. Dark gray which is superior part of the

DIT in the graph includes thickness of the skin, subcutaneous, and superficial belly of the superficial part of masseter muscle. The DIT could be estimated that is located in the range between 15 to 25%, respective from the skin to the mandibular surface. Longitudinal reference lines is as follow: half-way point between anterior border of the masseter m. and c (b); half-way point between anterior and posterior border of the masseter m. (c); half-way point between c and posterior border of the masster m. (d). Transverse reference lines are as follow: half-way point between origin and insertion of the masseter m. (2); half-way point between line 2 and inferior border of the mandible (3).

Table 1. Detailed depth from the skin to mandible and from the DIT (deep inferior tendon) to mandible at left and right side.

	2				3			
	Skin to DIT		DIT to mandible		Skin to DIT		DIT to mandible	
	Rt	Lt	Rt	Lt	Rt	Lt	Rt	Lt
b	20.9±2.0	20.3±1.9	4.2±2.4	4.5±1.9	18.0±2.8	17.7±2.4	3.3±1.4	2.2±0.3
c	20.2±2.2	20.1±1.9	3.9±1.8	4.5±2.4	17.5±2.7	16.9±2.1	3.2±1.8	2.4±1.5
d	18.5±2.2	18.2±2.4	3.2±1.5	3.5±1.0	16.1±2.5	15.3±1.9	4.6±1.9	3.9±2.3

half-way point between origin and insertion of the masseter m. 2; half-way point between line 2 and inferior border of the mandible 3; half-way point between anterior border of the masseter m. and c b; half-way point between anterior and posterior border of the masseter m. c; half-way point between c and posterior border of the masster m. d.

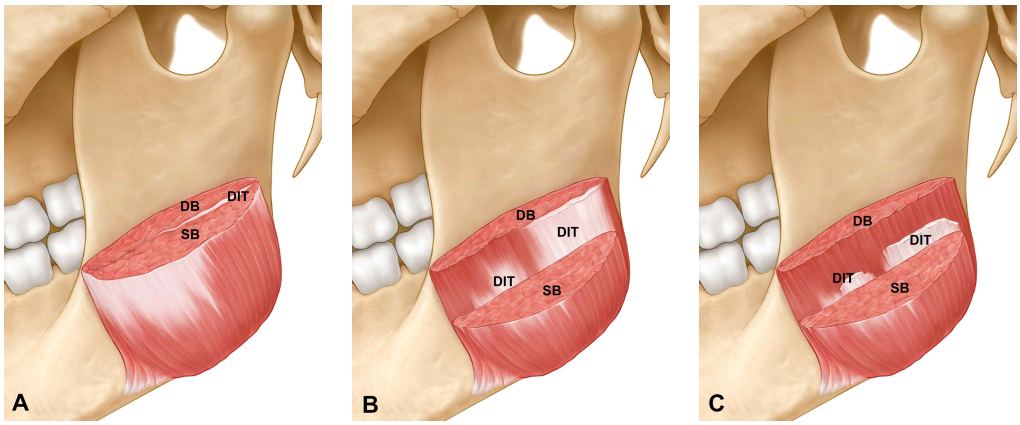

Figure 5. Layer by layer masseter muscle depicting superficial belly (SB) and deep belly (DB) of the superficial part of the masseter including DIT. The masseter muscle was cut at the midpoint level between the origin and insertion of the masseter muscle. DIT divides the superficial part of the masseter muscle into two layers (A). The superficial belly of the superficial part of the masseter muscle partially removed and DIT was shown (B). The deep belly of the superficial part of the masseter muscle was shown following the removal of the DIT (C). DIT was present within 25% or 5mm deep to the entire masseter muscle. Retrograde, dual plane or ultrasound-guided injection methods depending on the type of DIT would reduce side effects of masseteric bulging. DIT, deep inferior tendon; DB, deep belly of the superficial part of the masseter muscle; SB, superficial belly of the superficial part of the masseter muscle.

IV. Discussion

The present study used ultrasonography to verify DIT of the masseter muscle in healthy young volunteers, which was previously reported by dissecting the cadavers. Ultrasonographic scanning the same sites as the cadaveric study demonstrated the DIT structural patterns.

The previous cadaveric study classified the patterns of the DIT into three different types (Lee et al., 2016). Our results demonstrated similar results by observing via ultrasonography. The DIT was observed in all subjects while the presence of the DIT was differed according to the reference lines. The DIT was observed at the reference line B and C at 9.4% of specimens (3/32 cases). While the B and C covered patterns were the smallest patterns observed, in these cases, reference line B should be considered carefully for it is adjacent to the anterior border of the masseter muscle. Anterior border of the masseter collapses with the risorius muscle which may be located superficially. Consequently, the superficial injection to anterior border area should be performed with utmost care in order to prevent side effects of facial muscles changes due to damage to the risorius. The C and D covered patterns were observed in 21.9% of specimens (7/32 cases), where the reference line D is adjacent to the parotid gland. If the BoNT spreads to the parotid gland, xerostomia or dry mouth can be caused as a potential side effect of the inaccurate BoNT treatment. The incidence rate for xerostomia is 6.3-13.3% and the recovery time is roughly 3-4 weeks (Kim et al., 2007; Seo, 2017). Detailed injection

is recommended when injecting into the posterior part of the masseter muscle, which is the location of the reference line D and where the parotid gland is located superficial to the masseter muscle. The most frequently observed pattern was B, C, and D covered patterns that divides the superficial part of the masseter muscle into superficial and deep muscle belly, in which the pattern was observed in 68.8% of specimens (22/32 cases). This pattern was also the most frequently observed pattern of the previous cadaveric study in the Korean specimens. Since the DIT divides the superficial part of the masseter muscle into two layers, dual plane and retrograde injection would be advantageous to prevent the masseter bulging.

The injection technique such as injection point and depth are crucial to obtain positive result of masseteric BoNT treatment. Several previous studies have evaluated the durability and formation of the antibodies into the muscle but did not reveal the detailed depth of the related structure of the masseter muscle, such as depth of the masseter muscle and DIT and its related depth from the master muscle. In the present study, the DIT was found at the reference line 2 and 3 of the masseter muscle. At the reference line 2, the DIT was generally positioned at a constant depth from anterior to posterior direction. At the reference line 3, it was observed to be similar to reference line 2, while attaching close to the mandible. Therefore, the depth of the DIT could be estimated that it is located within 25% of the deeper area of the entire masseter muscle at the reference line 2 and 3, which is the level of the midpoint between the origin and insertion of the masseter muscle, and the midpoint of the

reference line 2 and inferior border of the mandible. When observing the DIT of the masseter via US, its entire pattern could be easily found via transverse US image, while the longitudinal US image is better to observe the entire presence of the DIT into the masseter muscle.

There have been various studies published regarding the intramuscular nerve distribution of the masseter muscle (Kim et al., 2010), the course of the marginal mandibular branch of the facial nerve (Hu et al., 2010), and location, morphology, and proportion of the DIT (Lee et al., 2016). in relation to the effective BoNT injection into the masseter muscle. Cioffi et al reported that the masseter muscle consists of several aponeurosis into the muscle like lamellar-like structure by observing via magnetic resonance imaging. In the present study, the DIT was observed to be single DIT rather than multiple tendinous structures in most of the cases. However, in some cases, the DIT was found to be more than two tendinous structures. The discrepancy with description of the previous cadaveric study of Lee et al is the different usage of the research materials and methods. The previous study dissected the cadavers and showed only two-dimensional plane structure of the DIT of the masseter muscle. However, three-dimensional observation is possible via MRI and US. In most cases, the DIT was even observed as a single DIT into the masseter muscle, however, the US-guided BoNT injection would be helpful to prevent masseteric bulging by confirming the DIT pattern for the patients those who showed multiple DIT pattern.

In summary, the DIT was observed at a similar depth from the anterior to the posterior, and as it went from superior to inferior, it was gradually

attached to the bone and attached to the inferior border of the mandible. DIT was present within 25% or 5 mm deep to the entire masseter muscle. In addition, more than one DIT was observed in some cases. Based on this complex DIT form, we believe that ultrasound can be used to observe the patient's internal structure of the masseter muscle in advance including the DIT, and reduce side effects of masseteric bulging by applying retrograde or dual plane injection methods depending on the type of DIT.

V. Conclusions

The conclusions of this study are as follows:

1. DIT was present within 25% or 5 mm deep to the entire masseter muscle.
2. Ultrasound can be used to observe the patient's internal structure of the masseter muscle in advance including the DIT.
3. Since the DIT divides the superficial part of the masseter muscle into two layers, dual plane and retrograde injection would be advantageous to prevent the masseter bulging..

References

Liew S, Wu WTL, Chan HH, Ho WWS, Kim HJ, Goodman GJ: *Consensus on Changing Trends, Attitudes, and Concepts of Asian Beauty.* Aesthetic Plast Surg, 2016. **40**(2): p. 193-201.

Moore AP, Wood GD: *The medical management of masseteric hypertrophy with botulinum toxin type A.* Br J Oral Maxillofac Surg, 1994. **32**(1): p. 26-8.

Rhee SC, Lee SH: *Attractive Composite Faces of Different Races.* Aesth Plast Surg Aesthetic Plastic Surgery, 2010. **34**(6): p. 800-801.

Kim HJ,. Seo KK, Lee HK, Kim J: *Clinical Anatomy of the Face for Filler and Botulinum Toxin Injection.* 2016.

Kwon JS, Kim ST, Jeon YM, Choi JH: *Effect of botulinum toxin type A injection into human masseter muscle on stimulated parotid saliva flow rate.* International journal of oral and maxillofacial surgery, 2009. **38**(4): p. 316-320.

Shim WH, Yoon SH, Park JH, Choi YC, Kim ST: *Effect of botulinum toxin type A injection on lower facial contouring evaluated using a three dimensional laser scan.* Dermatologic surgery, 2010. **36**: p. 2161-2166.

Xie Y, Zhou J, Li H, Cheng C, Herrler T, Li Q: *Classification of masseter hypertrophy for tailored botulinum toxin type A treatment.* Plast Reconstr

Surg, 2014. **134**(2): p. 209e-218e.

Carruthers J, Carruthers A: *Aesthetic botulinum A toxin in the mid and lower face and neck.* Dermatol Surg, 2003. **29**(5): p. 468-76.

Chang CS, Kang GCW: *Achieving Ideal Lower Face Aesthetic Contours: Combination of Tridimensional Fat Grafting to the Chin with Masseter Botulinum Toxin Injection.* Aesthetic Surgery Journal, 2016. **36**(10): p. 1093-1100.

Lee HJ, Lee KW, Tansatit T, Kim HJ: *Three-Dimensional Territory and Depth of the Corrugator Supercilii: Application to Botulinum Neurotoxin Injection.* Clin Anat, 2019.

Lee HJ, Kim JS, Youn KH, Lee JW, Kim HJ: *Ultrasound-Guided Botulinum Neurotoxin Type A Injection for Correcting Asymmetrical Smiles.* Aesthet Surg J, 2018. **38**(9): p. NP130-NP134.

Al-Muharraqi MA, Fedorowicz Z, Al Bareeq J, Al Bareeq R, Nasser M: *Botulinum toxin for masseter hypertrophy.* Cochrane Database Syst Rev, 2009(1): p. CD007510.

Gaofeng L, Jun T, Bo P, Bosheng Z, Qian Z, Dongping L: *Evaluation and selecting indications for the treatment of improving facial morphology by masseteric injection of botulinum toxin type A.* J Plast Reconstr Aesthet Surg, 2010. **63**(12): p. 2026-31.

Kim JH, Shin JH, Kim ST, Kim CY: *Effects of two different units of*

botulinum toxin type a evaluated by computed tomography and electromyographic measurements of human masseter muscle. Plast Reconstr Surg, 2007. **119**(2): p. 711-7.

Wei J, Xu H, Dong J, Li Q, Dai C: *Prolonging the duration of masseter muscle reduction by adjusting the masticatory movements after the treatment of masseter muscle hypertrophy with botulinum toxin type a injection.* Dermatol Surg, 2015. **41 Suppl 1**: p. S101-9.

Yeh YT, Peng JH, Peng HP: *Literature review of the adverse events associated with botulinum toxin injection for the masseter muscle hypertrophy.* J Cosmet Dermatol, 2018. **17**(5): p. 675-687.

Lee HJ, Kang IW, Seo KK, Choi YJ, Kim ST, Hu KS: *The Anatomical Basis of Paradoxical Masseteric Bulging after Botulinum Neurotoxin Type A Injection.* Toxins (Basel), 2016. **9**(1).

Lee HJ, Choi YJ, Lee KW, Hu KS, Kim ST, Kim HJ: *Ultrasonography of the internal architecture of the superficial part of the masseter muscle in vivo.* Clin Anat, 2019. **32**(3): p. 446-452.

Bae JH, Choi DY, Lee JG, Seo KK, Tansatit T, Kim HJ: *The risorius muscle: anatomic considerations with reference to botulinum neurotoxin injection for masseteric hypertrophy.* Dermatol Surg, 2014. **40**(12): p. 1334-9.

Hsu TS, Dover JS, Arndt KA: *Effect of volume and concentration on the diffusion of botulinum exotoxin A.* Arch Dermatol, 2004. **140**(11): p. 1351-4.

Lepage D, Parratte B, Tatu L, Vuiller F, Monnier G: *Extra- and intramuscular nerve supply of the muscles of the anterior antebrachial compartment: applications for selective neurotomy and for botulinum toxin injection.* Surg Radiol Anat, 2005. **27**(5): p. 420-30.

Kinett D: Botulinum toxin A injections in children: technique and dosing issues. Am J Phys Med Rehabil, 2004. **83**(10 Suppl): p. S59-64.

Friedman SN, Grushka M, Beituni HK, Rehman M, Bressler HB, Friedman L: Advanced Ultrasound Screening for Temporomandibular joint (TMJ) internal Derangement. Radiol Res Pract, 2020. **2020**: p. 1809690.

Cha YH, O J, Park JK, Yang HM, Kim SH: *Ultrasound-guided versus blind temporomandibular joint injections: a pilot cadaveric evaluation.*IInt J Oral Maxillofac Surg, 2019. **48**(4): p. 540-545

Seo KK: *Botulinum Toxin for Asians*. 2017, Singapore: Springer Singapore.

Kim DH, Hong HS, Won SY, Kim HJ, Hu KS, Choi JH: *Intramuscular nerve distribution of the masseter muscle as a basis for botulinum toxin injection.* J Craniofac Surg, 2010. **21**(2): p. 588-91.

Hu KS ,Kim ST, Hur MS, Park JH, Song WC, Koh KS: *Topography of the masseter muscle in relation to treatment with botulinum toxin type A.* Oral Surg Oral Med Oral Pathol Oral Radiol Endod, 2010. **110**(2): p. 167-71.

Abstract (in korean)

사각턱 시술에 효과적인 보툴리눔 주사방법을 위한 해부학적 고려

<지도교수 김 희 진>

연세대학교 대학원 치의학과

정 수 진

깨물근은 3개의 층으로 이루어져 있으며 얕은 층의 근육힘살은 근육 밑부분에서 겹쳐져 아랫부분이 가장 크고 두꺼운 형태를 이룬다. 최근 연구에서는 깨물근의 얕은 층이 단순히 근육힘살로만 이루어져 있는 것이 아니라, 근육힘살과 강력한 힘줄이 기왓장처럼 엇갈려 층판으로 존재하는 복잡한 형태인 것으로 보고되었다. 이러한 힘줄은 깊은아래힘줄 (Deep inferior tendon, DIT)로 명명되었고, 이 깊은아래힘줄은 사각턱 교정 및 이갈이 완화를 위한 깨물근 보툴리눔독소 시술 시 깨물근 불거짐 현상을 초래할 수 있는 것으로 알려져 있다. 그러나 더욱 효과적인 주사 방법을 위한 깊은아래힘줄 깊이와 형태에 대한 해부학적 연구가 부족한 실정이다. 따라서 본 연구에서는 시신에서 분류된 깊은아래힘줄의 형태를 초음파를 이용하여 임상시험 피험자를 통해 비교하고, 힘줄의 부위별 깊이를 제시하여 안전하고 효과적인 보툴리눔독소 주사방법을 제시하고자 하였다.

32명의 임상시험 피험자를 모집하여 초음파 가로 및 세로단면 촬영을 진행하였다 (E-CUBE 15 EX, ALPINION, SEOUL, KOREA, IRB NO. 2-2017-0023).

깊은아래힘줄은 모든 피험자에서 관찰되었다. 깊은아래힘줄은 양쪽 깨물근 모두 앞쪽 2/3, 뒤쪽 2/3 그리고 전체를 덮는 형태가 각각 9.4%, 21.9%, 68.8%로관찰되었다. DIT의 깊이는 앞쪽에서 뒤쪽으로 갈수록 아래턱뼈에서부터 얕은쪽으로 4~5mm의 일정한 깊이로 위치해 있었으나, 위에서 아래방향으로 갈수록 점점 아래턱뼈에 부착하는 형태를 나타내었다. 피부에서부터 아래턱뼈의 깊이는 약 15~25mm 였으며, DIT는 아래턱뼈에서 얕은쪽으로 2~5mm 떨어진 위치에서 관찰되었다.

깨물근의 깊은아래힘줄은 초음파를 이용하여 모든 피험자에서 관찰되었으며 시신과 살아있는 사람에서 공통적으로 관찰되는 구조로 생각된다. 시신을 이용한 선행연구와 비교하였을 때 한국인에서 가장 높게 관찰된 깊은아래힘줄의 형태는 깨물근의 아래쪽 전체를 덮고 있었고 시신 연구에서는 66.7%, 본 연구에서는 68.8%로 유사하게 관찰되었다. 따라서 본 연구결과를 바탕으로 효과적인 깨물근의 보툴리눔 독소 치료를 위해서는 다음과 같은 시술 과정을 제시하고자 한다. 1) 시술 전 초음파 가로 단면 촬영을 통해 환자의 깨물근과 깊은아래힘줄의 형태를 확인하고, 2) 깊은아래힘줄 형태에 근거한 주사를 한다면 부작용을 줄일 수 있을 것으로 생각한다.

핵심되는 말 : 깨물근, 깊은아래힘줄의 형태와 깊이, 사각턱 , 보툴리눔 독소 주사, 초음파