[UCI]I804:11046-000000521150

The feasibility of multiple burr hole surgery in pediatric moyamoya disease as a rescue for failed mEDAS

Jun kyu Hwang

Department of Medicine

The Graduate School, Yonsei University

The feasibility of multiple burr hole surgery in pediatric moyamoya disease as a rescue for failed mEDAS

Jun kyu Hwang

Department of Medicine

The Graduate School, Yonsei University

The feasibility of multiple burr hole surgery in pediatric moyamoya disease as a rescue for failed mEDAS

Directed by Professor Kyu-won Shim

The Master's Thesis
submitted to the Department of Medicine,
the Graduate School of Yonsei University
in partial fulfillment of the requirements for the degree of
Master of Medicine

Jun kyu Hwang

June 2019

This certifies that the Master's Thesis of
Hwang Junkyu is approved.

Thesis Supervisor: Jinna Kim

Thesis Committee Member #1: Hoon-chul Kang

Thesis Committee Member #2: Kyu-won Shim

The Graduate School
Yonsei University

June 2019

Acknowledgement

Firstly, I would like to thank Professor Kyu-won Shim for helping me complete this thesis, and I would also like to thank Professor Hoon-chul Kang and Professor Jinna Kim for giving me advice and encouragement. I thank Professor Dong-seok Kim and Professor Eun-kyung Park of Severance Pediatric Neurosurgery for their warm attention and teaching.

I would like to share this joy with my neurosurgery colleagues Jae-young So, Beom-seok Yoo, Sun-joon Yoo and Sun Yoon. I would like to thank my wife Sojin and my son Ewon for their enormous understanding and I promise to make them happy for the rest of my life. Lastly, I would like to return this glory to my grandfather, grandmother, father, mother, aunt, and sister for their constant encouragement and consolation until this present day.

June 2019

Jun kyu Hwang

<TABLE OF CONTENTS>

LIST OF FIGURES

LIST OF TABLES

ABSTRACT

The feasibility of multiple burr hole surgery in pediatric moyamoya disease as a rescue for failed mEDAS

Jun kyu Hwang

Department of Medicine
The Graduate School, Yonsei University

(Directed by Professor Kyu-won Shim)

Objective: The objective of this study is to prove the feasibility and clinical effectiveness of multi burr-hole surgery(MBS) as a rescue when treating pediatric moyamoya patients with failed mEDAS.

Materials and methods: From January 2014 to May 2018, MBS surgery was conducted on 16 hemispheres(12 patients) as a secondary treatment after mEDAS. Male to female ratio was 1:2 and the average age was 6 at the time of mEDAS. Patient age was in average 9±3 year old(range 7-17) at the time of MBS(46 months in average after mEDAS) and 10 holes were made on average. TTP images are divided to 20 axial cuts. Among these 20 axial cuts, two consecutive cuts on the lateral ventricle were selected to calculate the average

value because most of holes were made on these two consecutive cuts. The value was modified by subtracting the value of the cerebellum. ROI value was analyzed using a paired t-test by SPSS 20(SPSS Inc., Chicago, IL, USA).

Results: All 16 cases presented with clinical symptom improvement. Such effectiveness was proved by ROI analysis of the TTP MRI images. The average of ROI value was 5.03(±6.36) before MBS and -15.54(±9.42) after surgery. The average of changes in ROI value was -20.58(±12.59) and all cases expressed decrease in ROI after MBS surgery. The positive effect of vascularization was also shown on MRA.

Conclusion: In pediatric MMD, MBS surgery is recommended as secondary option after the failure of mEDAS. Its clinical effectiveness could be proved by using TTP image and assisted by MRA and DSA.

Key words: moyamoya disease, revascularization, time to peak map

The feasibility of multiple burr hole surgery in pediatric moyamoya disease as a rescue for failed mEDAS

Jun kyu Hwang

Department of Medicine
The Graduate School, Yonsei University

(Directed by Professor Kyu-won Shim)

I. INTRODUCTION

Moyamoya disease(MMD) is an idiopathic disease first reported by Suzuki and Takaku in 1969.[1] Its clinical symptom includes arterial ischemic stroke, transient ischemic attacks, intracranial hemorrhage, chorea, dementia, and headache.[2-4] Medical treatment has not shown effectiveness in preventing the clinical event.[5,6] Revascularization surgery has been shown to be a relatively safe and effective treatment for MMD. Various surgical options are available, however, there is no clinical evidence demonstrating which one of the indirect surgeries is more effective in treating pediatric MMD.[7-11]

In Severance Hospital, Seoul, South Korea, modified encephaloduroarteriosynangiosis(mEDAS) was used as the first surgical choice for children with MMD because of its aforementioned advantages. Though mEDAS can lead to favorable clinical outcomes, some patients had increased frequency of transient ischemic attack(TIA) in the immediate postoperative

period, and some suffered cerebral infarction.[12] In these patients, multi burr-hole surgery(MBS) was chosen as a secondary option at the same site with mEDAS and all 16 cases showed symptom improvement.

Cerebral perfusion imaging has become increasingly important in the diagnosis and treatment of MMD in children because of its noninvasive character, susceptibility to microvascular hemodynamic alteration, short acquisition times, and use of nonionizing radiation. Mean transit time(MTT), cerebral blood flow(CBF), and time to peak(TTP) can be used to compare the hemodynamic variation before and after vascular reconstruction.[13] Among them, changes in TTP perfusion maps after revascularization surgery correspond to clinical outcome in patients with MMD.[14-18]

This study analyzed the feasibility of MBS as a rescue for failed mEDAS and effectiveness was proved by region of interest(ROI) analysis of time-to -peak(TTP) in perfusion MRI image.

II. MATERIALS AND METHODS

From January 2014 to May 2018, MBS surgery was conducted on 16 hemispheres(12 patients) as a secondary treatment after mEDAS, in Severance Hospital, Seoul, South Korea. Male to female ratio was 1:2 and the average age was 5 years at diagnosis. Suzuki grading system was used to check the condition when MMD was first diagnosed and immediately before MBS(Table 1).[1]

Table 1. Suzuki grading system

Grades	Definition
I	Narrowing of ICA apex
II	Apparition of deep Moyamoya collateral vessels
III	Progression of Moyamoya collateral vessels
IV	Apparition of transdural collateral vessels originating from ECA
V	Progression of transdural collateral vessels and reduction of Moyamoya vessels
VI	Occlusion of ICA and disappearance of Moyamoya collateral vessels

According to the Suzuki grading system, 4 cases(25%) were grade II, 11 cases(68.75%) were grade III and 1 case(6.25%) was grade IV before mEDAS. Before MBS, 2 cases(12.5%) were grade II, 13 cases(81.25%) were grade IV and 1 case(6.25%) was grade V. In the case of MBS surgery, patient age was 9 years old(46 months after mEDAS) and 10 holes were made in average(Table 2).

Table 2. Summary of patients

Number of patients	12
Male to female ratio	1:2 (M=4, F=8)
Number of hemispheres	16
Average patient age at mEDAS	5±1 years (range 2-7)
Average patient age at MBS	9±3 years (range 7-17)
Average number of multi burr hole	10±1 (range 8-13)
Suzuki stage before mEDAS	II=4 (25%) III=11 (68.75%) IV=1 (6.25%)
Suzuki stage before MBS	III=2 (12.5%) IV=13 (81.25%) V=1 (6.25%)

MRA was chosen for follow up image due to the young age of the affected children. TTP image was used to confirm the surgical outcome. MBS was considered in 16 cases because clinical symptoms deteriorated after mEDAS and the progression of MMD was verified through MRA and perfusion MRI. Although the invasiveness of digital subtraction angiography(DSA), it should be conducted before MBS to confirm failed mEDAS. DSA is also effective when determining MBS surgery as a secondary treatment, and it is important for finding the correct site of new holes. From the 16 cases, DSA after MBS surgery was conducted in only 10 cases. By analyzing the DSA images, Matsushima grade was checked for each case and the results of the operations were compared.

8cm linear skin incision was made on the parietal branch of superficial temporal artery(STA) for mEDAS. The previously used skin incision was reused for MBS

surgery with a slight posterior extension. When planning the new burr hole site and number of holes, it is important to preserve the parietal branch which was previously inserted below the bone flap. To find the direction of the parietal branch, it was useful to mark a line between the two holes made during mEDAS operation. The area where the parietal branch enters and exits can be detected with tactile sensation before the skin incision. It can also be assisted by preop DSA image. Burr holes were made by using high speed drill, and bleeding control was done by packing bone wax. Crucifix shape dura mater incision was made at each burr-hole site. Outer layer of dura mater was incised carefully with a blade and inner layer of dura mater was exposed. After removal of inner layer, cerebrospinal fluid(CSF) was detected and completely formed burr holes were packed with gel foam respectively to prevent post-op hemorrhage and CSF leakage. On average, 10 burr holes were made, and their locations were determined by comparing the perfusion MR with angiography. Most of new holes were located on the upper site of mEDAS bone flap due to the motor cortex coverage. One Jackson-Pratt drain was kept for 2 days after operation(Figure 1,2).

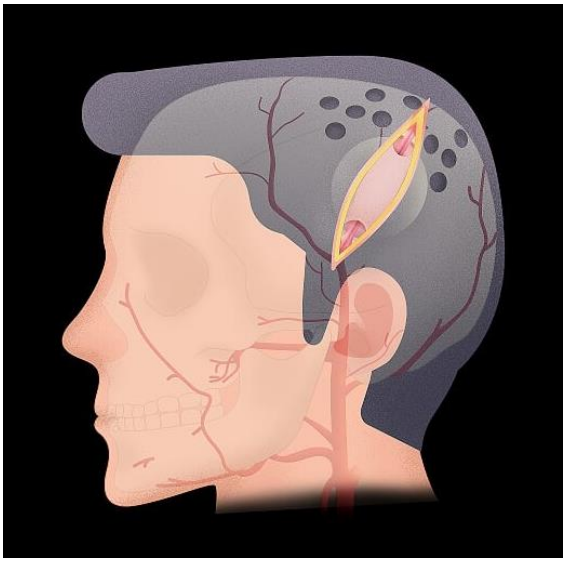

Figure 1. Illustration of MBS surgery after mEDAS

Figure 2. Lateral X-ray after mEDAS(left) and MBS(right)

Changes in time to peak(TTP) and cerebral blood volume perfusion maps can depict the hemodynamic status after revascularization surgery in patients with MMD. Some studies showed that changes in TTP can correspond with clinical outcome after revascularization surgery in patients with MMD. [14,15]

To compare each TTP on MRI(magnetic resonance imaging) image, ROI analysis was used. At Severance hospital, TTP images are divided to 20 axial cuts. Among these 20 axial cuts, two consecutive cuts on the lateral ventricle were selected to calculate the average value because these two cuts mostly reflect the effectiveness of revascularization after MBS. The value was modified by subtracting the value of the cerebellum due to minimize potential errors caused by differences in arterial input function associated with bolus delay and dispersion(Figure 3).[19,20]

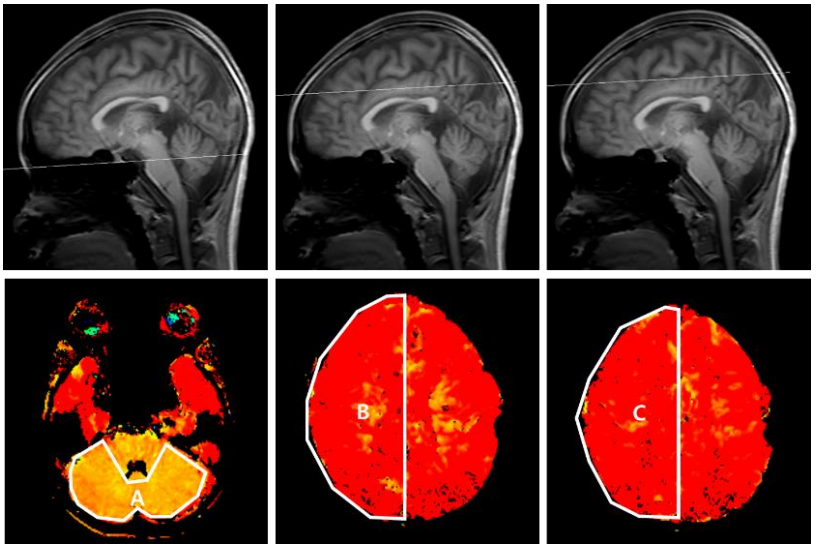

Figure 3. ROI analysis

Most frequent clinical symptoms were headache, TIA, infarction and epilepsy. The clinical results were checked by telephone interview and hospital medical record. The interviews were conducted in a day and the time period was 24 months on average after MBS surgery.

All MRI examinations were performed using a 3.0T MRI system(Achieva 3.0T, Philips Medical Systems, Netherlands and Ingenia 3.0T CX, Philips Medical Systems, Netherlands) and temporal resolution of perfusion image was 1.6 seconds. Extended MR Workspace(Philips Medical Systems, Nederland) was used for modifying grey scale image to color scale image. TTP images conducted by other machines were excluded in this study. ROI was calculated by using Centricity PACS(GE healthcare, USA).

III. RESULTS

mEDAS was primarily conducted and MBS was subsequently carried out in all 16 cases. Patients' symptoms were compared at three time periods: before mEDAS surgery, before MBS and after MBS. Before mEDAS surgery, 13 patients presented with TIA, 6 patients with infarction, 2 patients with headache and 1 patient with epilepsy. Before MBS surgery, 14 patients presented with TIA, 11 patients with infarction, 3 patients with headache and 5 patients with epilepsy. Symptoms were aggravated in all patients. Multi burr hole was subsequently conducted, and the numbers of patients with symptoms were decreased to 5 patients with TIA, 1 patient with infarction, 1 patient with headache and 1 patient with epilepsy. The one infarction case after multi burr hole surgery was an immediate post operation complication which presented 3 days after the operation. All 5 patients with TIA who underwent multi burr hole surgery, complained their symptom within once a month and the severity of TIA decreased. The rest of the 11 cases did not complain TIA(Figure 4, 5).

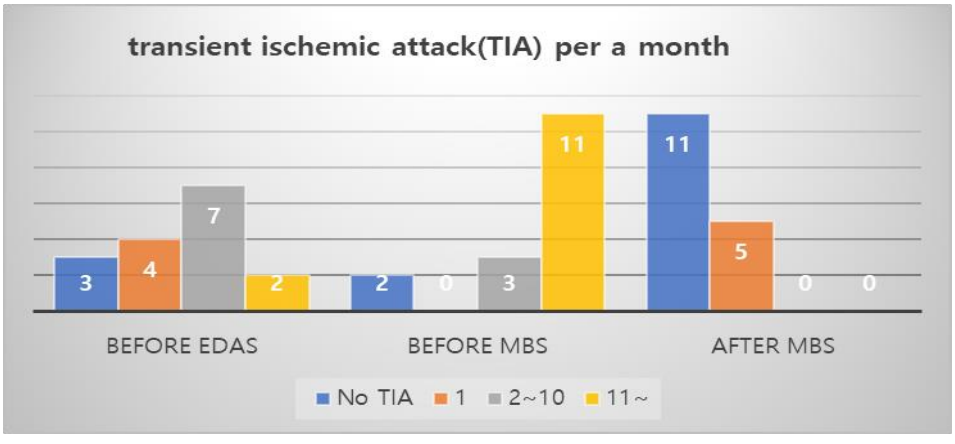

Figure 4. Number of TIA per month

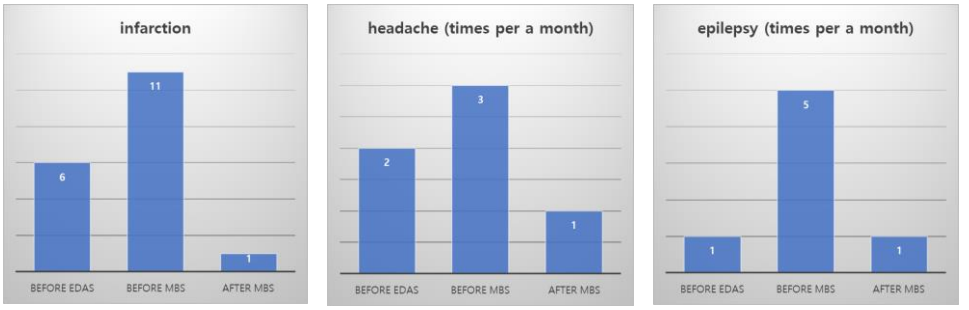

Figure 5. Changes in clinical symptoms

Clinical symptom improvement can be proved by TTP of perfusion MRI image. The average of ROI value was 5.03(±6.36) before MBS and -15.54(±9.42) after surgery. The average of changes in ROI value was -20.58 (±12.59) and all cases expressed decrease in ROI after MBS surgery(Figure 6). It was analyzed using a paired t-test by SPSS 20(SPSS Inc., Chicago, IL, USA) (Table 3). Positive result of vascularization could be explained by following up MRA(Figure 7).

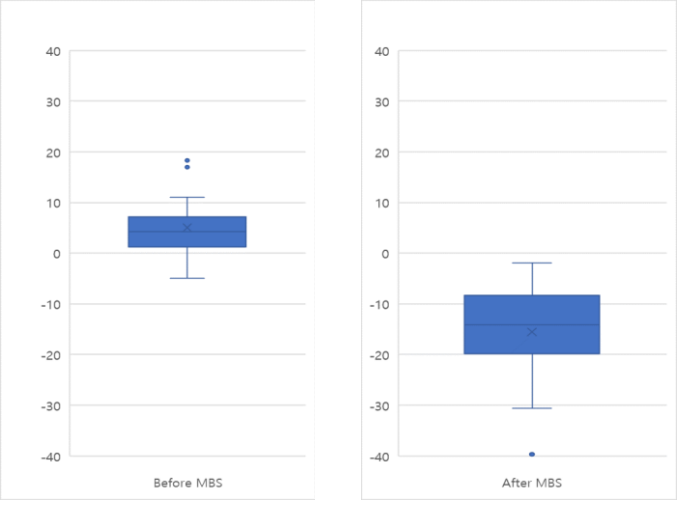

Figure 6. ROI value before(left) and after(right) MBS

Table 3. MBS effect in ROI value

	Average	Standard deviation	P
ROI value (before MBS-after MBS)	20.58	±12.59	<0.001

paired t-test

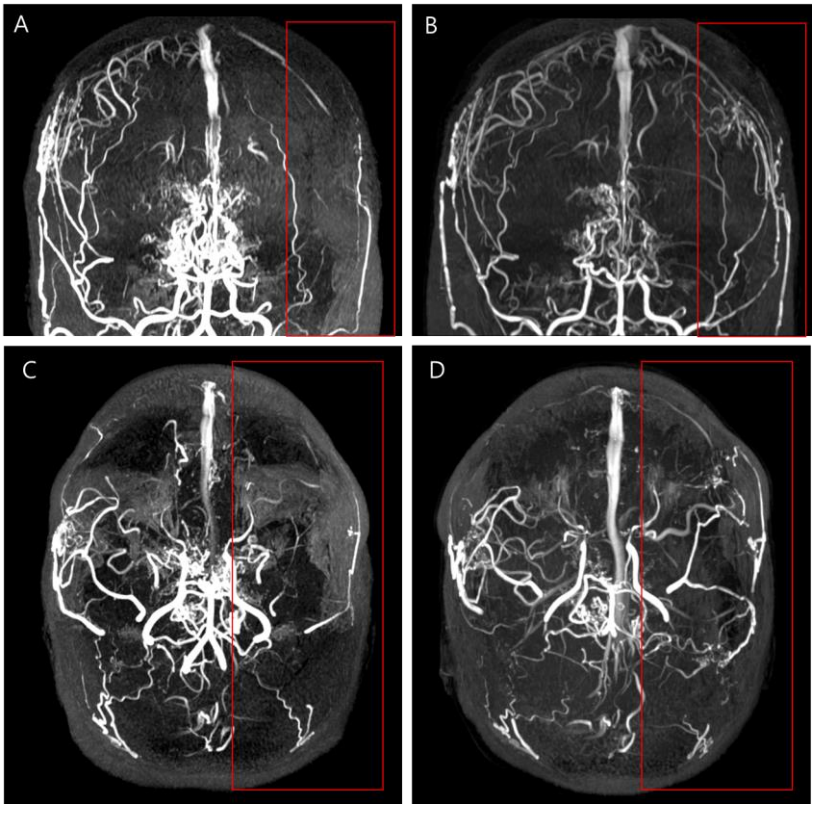

Figure 7. Revascularization on MRA. Pre-op(A, C) and post-op(B, D) image

DSA conducted to all cases before MBS surgery. Matsushima grading system was used to analyze the effects of MBS(Table 4).[11]

Table 4. Matsushima grading system

Grade	Angiographic findings
A	Area perfused by the synangiosis is greater than 2/3 of the MCA territory
B	Area perfused by the synangiosis is between 1/3 and 2/3 of the MCA territory
C	Area perfused by the synangiosis is less than 1/3 of the MCA territory

(MCA: middle cerebral artery)

According to Matsushima grading system, 2 cases were grade B(12.5%), and 14 cases were grade C(87.5%). It shows that patients in the study had a poor result of mEDAS(Figure 8).

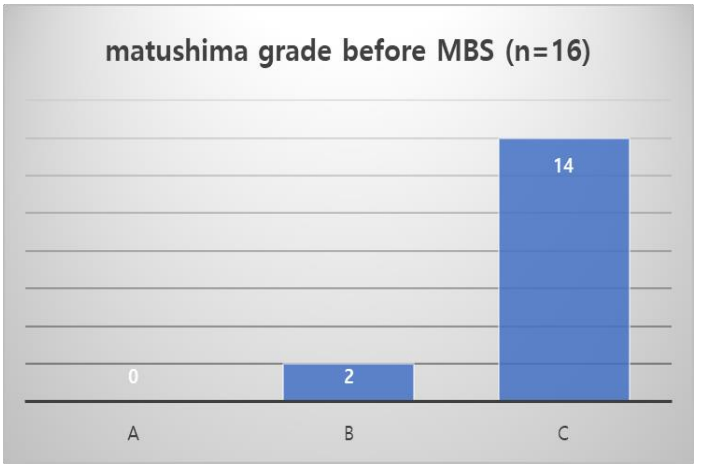

Figure 8. Matsushima grade before MBS

Only 10 cases checked post-op DSA after MBS surgery, because all patients were children and noninvasive tool was preferred. Improvement of vascularization after MBS surgery can be seen on DSA, even though they had the poor result after mEDAS(Figure 9).

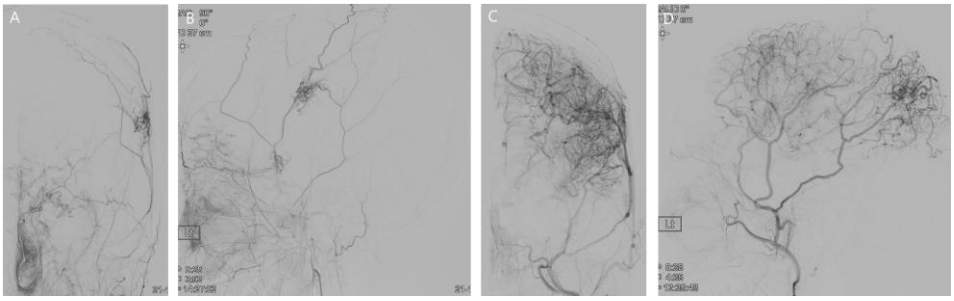

Figure 9. Revascularization on DSA(Pre-op(A, B) and post-OP(C, D) image)

Among these 10 cases, comparing Matsushima grade, 1 case was grade B (10%) and remained 9 cases were grade C(90%) before MBS surgery. After the operation, however, 8 cases improved up to grade A(80%) and 2 cases were grade B(20%). No case belonged to grade C(Figure 10).

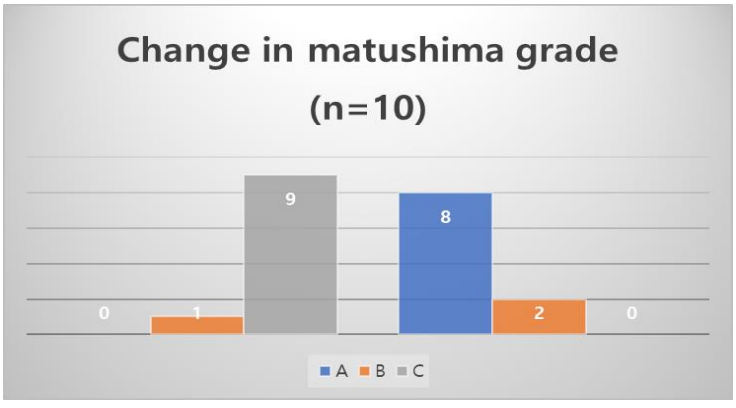

Figure 10. Change in matsushima grade

IV. DISCUSSION

The treatment of pediatric MMD has its own characteristics, primarily because the vessels on the brain surface are slender and fragile, and therefore making direct vascular reconstruction more difficult than adult MMD. There is no clinical evidence demonstrating which one of the indirect surgeries is more effective in treating pediatric MMD.[7-10,21] Compared to direct surgery, indirect surgery is less traumatic, easier technical requirements, and shorter surgical time. On the other hand, it requires longer period for vascular reconstruction.[22] Therefore, indirect surgery is preferred over direct surgery in pediatric MMD. Of the indirect surgeries, however, there is no clinical evidence demonstrating which one is more effective. In Severance Hospital, mEDAS was conducted as a first-choice treatment for pediatric MMD and it has been proved considerably positive effect for many years.[6] From January 2014 to May 2018, out of the 480 conducted cases, only 16 cases were considered MBS surgery as secondary option. It was only 3.3% comparing to mEDAS. These 16 hemispheres had no satisfactory result of mEDAS, and their clinical symptom worsened. MBS offered them a positive result as a second treatment option. Up to now, all patients in the study presented with clinical symptom improvement. Of the 16 hemispheres in those patients, no operational complication such as infection, CSF leakage and hemorrhage, occurred except only 1 immediate post-op infarction.

In this study, it is recommended that mEDAS should be chosen as first treatment and MBS surgery could be considered as second treatment after mEDAS failure. MBS after mEDAS failure has some advantages. Firstly, minimal scar can be occurred by using the same skin incision. In Severance Hospital, only 8cm curvilinear incision was done on parietal branch of superficial artery for mEDAS. Previously used incision line of mEDAS was reused at MBS surgery and posteriorly extension was needed minimally. Secondly, it is useful for making superficial artery safe during secondary

surgery. After mEDAS, parietal branch of superficial artery was hidden below large bone flap and its direction could be anticipated in between palpable two holes. On the contrary, if MBS surgery was chosen as first treatment option, it is dangerous to conduct mEDAS at the same area due to adhesion of first operation. When making multiple burr hole, the area between palpable two holes should be excluded. Thirdly, it can reduce operational complications. The duration of surgery for MBS surgery and mEDAS were both within 90 minutes. In Severance Hospital, mEDAS conducted independently from MBS had a favorable result.[12] Conducting mEDAS and MBS simultaneously, however, can increase post-op complications in pediatric MMD such as acute infarction and epidural hemorrhage. Therefore, it is more effective to leave MBS surgery as a second option.

In pediatric MMD, invasiveness of DSA procedure can lead to TIA or infarction event due to hyperventilation. Even though it is only an examination not a treatment, general anesthesia was needed at each DSA procedure. Some studies proved that MRA and perfusion MRI image can be useful when following up MMD.[14,23] Among them, MR TTP had relative correlation with change of clinical symptom in MMD patients. With those noninvasive procedures, this study can prove the effectiveness of MBS surgery as secondary operation. Moreover, its advantage was proved by DSA in some cases. Nevertheless, more cases are needed to prove of its effectiveness and additional study for adult MMD patient is recommended.

V. CONCLUSION

In pediatric MMD, MBS surgery is recommended as secondary option after the failure of mEDAS. Its clinical effectiveness could be proved by using TTP image and assisted by MRA and DSA.

REFERENCES

1. Suzuki J, Takaku A. Cerebrovascular "moyamoya" disease. Disease showing abnormal net-like vessels in base of brain. Arch Neurol 1969;20:288-99.
2. Ganesan V. Moyamoya: to cut or not to cut is not the only question. A paediatric neurologist's perspective. Dev Med Child Neurol 2010;52:10-3.
3. Suzuki J, Kodama N. Moyamoya disease--a review. Stroke 1983;14:104-9.
4. Ma Y, Zhao M, Zhang Q, Liu X, Zhang D, Wang S, et al. Risk Factors for Epilepsy Recurrence after Revascularization in Pediatric Patients with Moyamoya Disease. J Stroke Cerebrovasc Dis 2018;27:740-6.
5. McLaughlin N, Martin NA. Effectiveness of burr holes for indirect revascularization in patients with moyamoya disease-a review of the literature. World Neurosurg 2014;81:91-8.
6. Zhang H, Zheng L, Feng L. Epidemiology, diagnosis and treatment of moyamoya disease. Exp Ther Med 2019;17:1977-84.
7. Liu JJ, Steinberg GK. Direct Versus Indirect Bypass for Moyamoya Disease. Neurosurg Clin N Am 2017;28:361-74.
8. Fung LW, Thompson D, Ganesan V. Revascularisation surgery for paediatric moyamoya: a review of the literature. Childs Nerv Syst 2005;21:358-64.
9. Mizoi K, Kayama T, Yoshimoto T, Nagamine Y. Indirect revascularization for moyamoya disease: is there a beneficial effect for adult patients? Surg Neurol 1996;45:541-8; discussion 8-9.
10. Czabanka M, Pena-Tapia P, Scharf J, Schubert GA, Munch E, Horn P, et al. Characterization of direct and indirect cerebral revascularization for the treatment of European patients with moyamoya disease. Cerebrovasc Dis 2011;32:361-9.
11. Matsushima Y, Inaba Y. Moyamoya disease in children and its surgical treatment. Introduction of a new surgical procedure and its follow-up angiograms. Childs Brain 1984;11:155-70.
12. Park SE, Kim JS, Park EK, Shim KW, Kim DS. Direct versus indirect revascularization in the treatment of moyamoya disease. J Neurosurg

2018;129:480-9.
13. Togao O, Mihara F, Yoshiura T, Tanaka A, Noguchi T, Kuwabara Y, et al. Cerebral hemodynamics in Moyamoya disease: correlation between perfusion-weighted MR imaging and cerebral angiography. AJNR Am J Neuroradiol 2006;27:391-7.
14. Yun TJ, Cheon JE, Na DG, Kim WS, Kim IO, Chang KH, et al. Childhood moyamoya disease: quantitative evaluation of perfusion MR imaging--correlation with clinical outcome after revascularization surgery. Radiology 2009;251:216-23.
15. Lin YH, Kuo MF, Lu CJ, Lee CW, Yang SH, Huang YC, et al. Standardized MR Perfusion Scoring System for Evaluation of Sequential Perfusion Changes and Surgical Outcome of Moyamoya Disease. AJNR Am J Neuroradiol 2019;40:260-6.
16. Yamada I, Himeno Y, Nagaoka T, Akimoto H, Matsushima Y, Kuroiwa T, et al. Moyamoya disease: evaluation with diffusion-weighted and perfusion echo-planar MR imaging. Radiology 1999;212:340-7.
17. Quon JL, Kim LH, Lober RM, Maleki M, Steinberg GK, Yeom KW. Arterial spin-labeling cerebral perfusion changes after revascularization surgery in pediatric moyamoya disease and syndrome. J Neurosurg Pediatr 2019:1-7.
18. Hirai S, Inaji M, Tanaka Y, Hara S, Nariai T, Maehara T. Correlation between Clinical Presentations and Hemodynamic Parameters Measured by Dynamic Susceptibility Contrast Magnetic Resonance Imaging in Adult Patients with Moyamoya Disease. J Stroke Cerebrovasc Dis 2017;26:2814-20.
19. Calamante F, Thomas DL, Pell GS, Wiersma J, Turner R. Measuring cerebral blood flow using magnetic resonance imaging techniques. J Cereb Blood Flow Metab 1999;19:701-35.
20. Tanaka Y, Nariai T, Nagaoka T, Akimoto H, Ishiwata K, Ishii K, et al. Quantitative evaluation of cerebral hemodynamics in patients with moyamoya disease by dynamic susceptibility contrast magnetic resonance imaging--comparison with positron emission tomography. J Cereb Blood Flow Metab 2006;26:291-300.

21. Wang KC, Phi JH, Lee JY, Kim SK, Cho BK. Indirect revascularization surgery for moyamoya disease in children and its special considerations. Korean J Pediatr 2012;55:408-13.
22. Thines L, Petyt G, Aguettaz P, Bodenant M, Himpens FX, Lenci H, et al. Surgical management of Moyamoya disease and syndrome: Current concepts and personal experience. Rev Neurol (Paris) 2015;171:31-44.
23. Choi HS, Kim DS, Shim KW, Kim J, Kim ES, Lee SK. Focal time-to-peak changes on perfusion MRI in children with Moyamoya disease: correlation with conventional angiography. Acta Radiol 2011;52:675-9.

ABSTRACT (IN KOREAN)

모야모야 병에서 뇌경막 동맥 간접 문합술 실패 이후 다발성 천공술이 가지는 이점

<지도교수 심 규 원>

연세대학교 대학원 의학과

황 준 규

연구 목적: 본 연구는 소아 모야모야 환자에서 1차적으로 시행한 뇌경막 동맥 간접 문합술이 실패하였을 경우 2차적으로 시행한 다발성 천공술이 가지는 임상적 효과를 증명하고자 하였다.

실험 방법: 2014년 1월부터 2018년 5월까지 다발성 천공술은 12명의 환자에게서 16 사례를 시행하였다. 남녀 비율은 1:2였으며, 뇌경막 동맥 간접문합술을 시행할 당시의 평균 나이는 6살이었다. 이후 다발성 천공술 시행 나이는 평균 9살이었으며, 수술을 할 시에 평균 10개의 구멍을 만들었다. Perfusion MRI에서 Axial은 20개로 분할하였으며, Lateral ventricle이 보이는 바로 위의 연속적인 두 cut을 이용하여 평균을 낸 뒤, Cerebellar region의 값을 차감하여 ROI analysis를 분석하였다.

실험 결과: 16 사례 모두의 경우에서 증상의 호전됨을 확인하였다. ROI analysis 값 또한 다발성 천공술을 시행한 이후 값이 모두 감소하였으며 이를 통하여 긍정적인 효과를 확인할 수 있었다.

수술 후 재혈관화의 결과도 뇌혈관 조영검사 및 자기 공명 혈관 조영술을 통해서도 확인이 가능하였다.

결론: 모야모야병에서 뇌경막 동맥 간접문합술 이후에도 증상이 악화되었을 경우 다발성 천공술을 통하여 증상의 호전을 기대할 수 있다.

핵심 되는 말: 모야모야 병, 재혈관화, 관류영상