

Primary Hypertrophic Osteoarthropathy Accompanied by Crohn's Disease : A Case Report

Yong-Woon Shim and Jin-Suck Suh

Primary hypertrophic osteoarthropathy is a rare hereditary disease without evidence of underlying diseases. We report a very unusual case of primary HOA accompanied by Crohn's disease with the primary HOA mimicking secondary HOA, which is a rare manifestation of Crohn's disease. We also review the literature to find the correlation, if any, between the two.

Key Words: Osteoarthropathy, hypertrophic, Crohn's disease

Primary hypertrophic osteoarthropathy (HOA, pachydermoperiostosis) is a rare hereditary disease (Martinez-Lavin *et al.* 1988), characterized by clubbing and hypertrophy of the digits, periosteal new bone formation of tubular bones, and hypertrophic skin changes (pachyderma). Skin manifestations include marked furrowing of the brow, seborrhea and hyperhidrosis (Vogl and Goldfisher, 1962). No underlying diseases have yet been documented. There are just a few reports documenting gastric ulcer, gastric hypertrophy and endocrine abnormalities as accompanying features (Venencie *et al.* 1988; Matsui *et al.* 1991).

In contrast, secondary forms of HOA are not uncommon and arise in association with pulmonary diseases such as lung cancer, pulmonary tuberculosis, and chronic obstructive pulmonary diseases. Secondary HOA can be caused by extra-pulmonary diseases such as Crohn's disease and ulcerative

colitis (Neale *et al.* 1968).

The authors report a case of primary HOA mimicking secondary HOA as a rare manifestation of Crohn's disease.

CASE REPORT

A 42-year-old man was admitted via our emergency center because of right lower quadrant abdominal pain and diarrhea, which had first been noticed 6 months previously and had become recently aggravated. Twelve years before admission, he had visited our hospital because he noticed a slowly progressive enlargement of his fingers over a 10-year duration without evidence of gastrointestinal trouble at that time. The skin of the hands and face was coarse and clubbing of the digits was noted. Hyperhidrosis, visual impairment, cyanosis, dyspnea, and murmur were absent. No joint tenderness was observed. The following tests were normal at that time: Blood chemistry, serologic test for syphilis (VDRL) and rheumatoid factor, hormonal studies such as T3, T4, fT4, thyroid stimulating hormone, and growth hormone, and he-

Received June 23, 1997

Accepted October 8, 1997

Department of Diagnostic Radiology, Yonsei University College of Medicine

Address reprint request to Dr. J.S. Suh, Department of Diagnostic Radiology, Yonsei University College of Medicine, C.P.O. Box 8044, Seoul 120-752, Korea

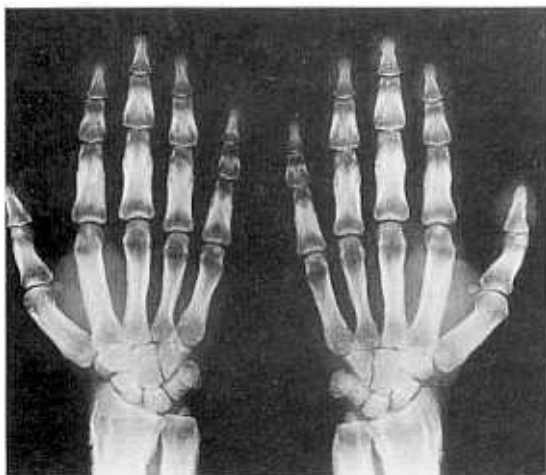


Fig. 1. A radiograph of both hands shows diffuse periosteal thickening of metacarpals and phalanges. Soft tissues are also thickened. Distal radius and ulnae show nodular form of periosteal new bone involving epiphysis as well as metaphysis in a symmetric fashion.

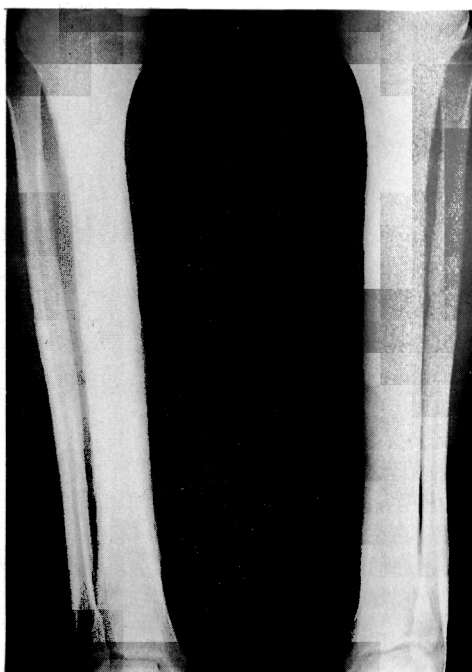


Fig. 2. Both tibiae and fibulae show diffuse periosteal thickenings.

matologic studies such as hemoglobin level, red and white cell counts. A postero-anterior radiograph of both hands showed symmetrically thick cortices of phalanges, metacarpals, ulnae and radius including epiphysis (Fig. 1). Soft-tissue thickening of finger tufts was seen. The diaphyses were wider and thicker than the epiphyses. Symmetric, periosteal new bone formations were seen on tibiae and fibulae (Fig. 2). No joint abnormalities were found. Two younger brothers and a cousin (Fig. 3) were found to have similar clinical and radiographic features. Chest PA study showed normal appearance. Eight years prior to admission, the patient received an operation (duodenojejunostomy) due to superior mesenteric artery syndrome.

At this admittance, physical examination revealed direct tenderness at the right lower quadrant abdomen. Skin thickening of the face and hands was also noted. Hematologic and blood chemistry data were normal except for 8.8 g/dL of hemoglobin. C-reactive protein, T3, T4, TSH and glycated hemoglobin were not remarkable. Colonoscopy was performed to look for causes of chronic uncontrolled diarrhea and severe abdominal pain. Colonoscopic findings and biopsy results revealed chronic ulcerative colitis with active inflammation and crypt

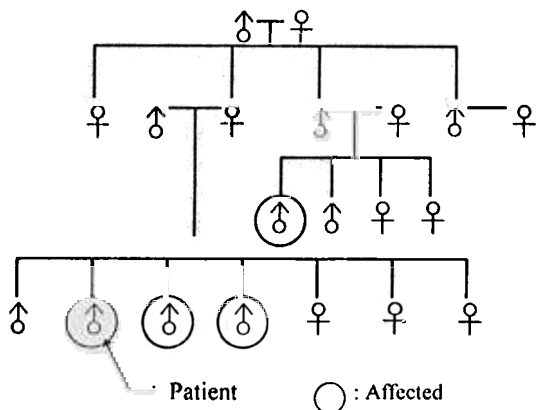


Fig. 3. A pedigree of the patient's family. Encircled family members were found to have features of primary HOA.

distortion, which were consistent with Crohn's disease (Fig. 4). A barium study, performed a few days later, showed numerous ulcerations and multiple luminal narrowing of the entire colon (Fig. 5). Eso-

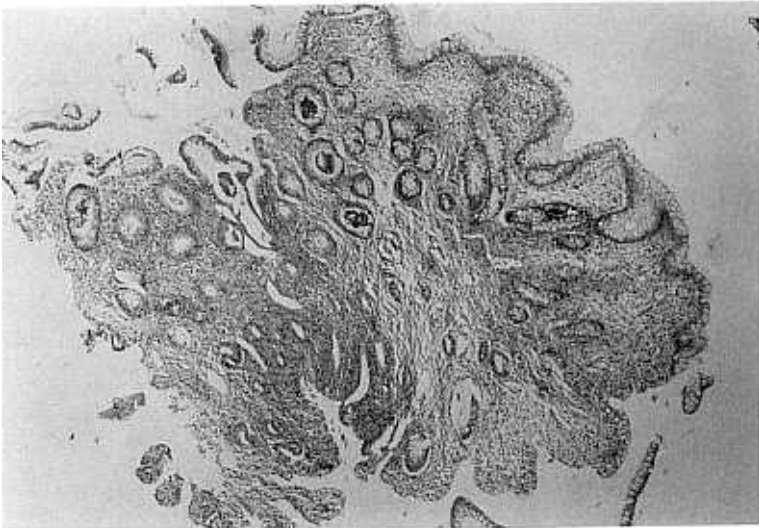


Fig. 4. A biopsy specimen. The colonic mucosa shows chronic crypt distortion, focal inflammation with chronic inflammatory cells and crypt abscess.

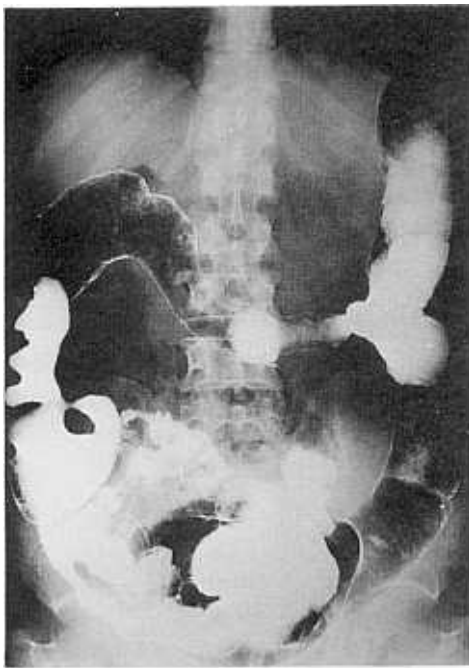


Fig. 5. Double contrast barium study for colon reveals loss of colonic haustral marking and narrowed bowel lumens in multiple regions. Mesenteric borders are involved predominantly.

phagogastroduodenoscopy revealed hypertrophic gastric folds. With sulfasalazine treatment and fluid replacement, gastrointestinal symptoms were relieved. A radiograph of both hands showed no changes of periosteal thickening of metacarpals, phalanges, distal radius and ulnas as compared with his previous admission.

No bowel habit changes suggestive of inflammatory bowel disease were noticed in his relatives.

DISCUSSION

Primary HOA is an inherited disease (Martinez-Lavin *et al.* 1988), with autosomal dominant transmission with variable expression. One third of previously reported patients have relatives with primary HOA. Any particularly associated diseases have not been described. No gastrointestinal abnormalities have been documented, except for gastric ulcer and hypertrophy, in previous reports (Venencie *et al.* 1988; Matsui *et al.* 1991). Our case also showed gastric hypertrophy, but no other diseases which may be related with HOA to define our case as a secondary form.

Histology revealed periosteal proliferation with

round cell infiltration and new bone formation between the periosteum and the original cortex (Vogl and Goldfisher, 1962). Thickened skin showed hyalinization of collagen and elastic fibers with interposed foci of necrosis and inflammation (Vogl and Goldfisher, 1962). Radiography can demonstrate primary HOA, characterized by bilateral, symmetric periostitis of tubular bones. Periosteal new bones showed shaggy, irregular excrescence.

Crohn's disease is a chronic granulomatous inflammatory bowel disease. The pathogenesis of Crohn's disease is unknown, although many investigators have studied about immunologic factors, ingestion of exogenous compounds, and genetic linkage (MacDonald, 1993). Crohn's disease may present osteoarticular manifestations (Pastershank and Tchang, 1972; McAllister *et al.* 1986). HOA may appear rarely in the course of chronic Crohn's disease. This secondary form of HOA also presents symmetric periostitis which often has single or laminated appearance (Resnick, 1995). On the basis of radiographic findings, it is well known that differentiation of primary and secondary HOAs is difficult.

The authors believed that the patient of this case report had primary HOA accompanied by Crohn's disease. Genetic inheritance was evident and no preexisting diseases which may induce secondary HOA. It was also supported by the fact that HOA had been presented 12 years earlier than Crohn's disease. The association of primary HOA and Crohn's disease, if it exists at all, has still to be solved.

Although the authors cannot exclude the possi-

bility of the coincidence of primary HOA and Crohn's disease, both are extremely rare diseases in Asian countries. Here, the authors report a rare case of primary HOA, accompanied by Crohn's disease metachromatically.

REFERENCES

- MacDonald TT: Aetiology of Crohn's disease. *Arch Dis Child* 68: 623-625, 1993
- Martinez-Lavin M, Pineda C, Valdez T, Cajigas JC, Weisman M, Gerber N, Steigler D: Primary hypertrophic osteoarthropathy. *Semin Arthritis Rheum* 17: 156-162, 1988
- Matsui Y, Nishii Y, Maeda M, Okada N, Yoshikawa K: Pachydermoperiostosis- report of a case and review of 121 Japanese cases. *Nippon Hifuka Gakkai Zasshi* 101: 461-467, 1991
- McAllister C, McNulty JG, Fielding JF: Is hypertrophic osteoarthropathy really so rare in regional enteritis? *J Clin Gastroenterol* 8: 562-566, 1986
- Neale G, Kelsall AR, Doyle FH: Crohn's disease and diffuse symmetrical periostitis. *Gut* 9: 383-387, 1968
- Pastershank SP, Tchang PK: Regional enteritis and hypertrophic osteoarthropathy. *J Can Assoc Radiologists* 23: 35-37, 1972
- Resnick D: Diagnosis of bone and joint disorders, 3rd ed. Philadelphia, W.B. Saunders 1995, 4421-4427
- Venencie PY, Boffa GA, Delmas PD, Verola O, Benkaali I, Frija J, Pillet B, Puissant A: Pachydermoperiostosis with gastric hypertrophy, anemia, and increased serum bone Gla-protein level. *Arch Dermatol* 124: 1831-1834, 1988
- Vogl A, Goldfisher S: Pachydermoperiostosis : Primary or idiopathic hypertrophic osteoarthropathy. *Am J Med* 33: 166-187, 1962