

급성심근경색 후 가역적 심실벽운동장애의 예측도구로서 도부타민부하 심초음파검사의 유용성

고충원¹ · 임세중¹ · 하종원¹ · 권 준² · 최동훈¹
김지영¹ · 황은경¹ · 장양수¹ · 정남식¹

Prognostic Value of Dobutamine Echocardiography in Prediction of Late Recovery of Regional Myocardial Dysfunction in Patients with Acute Myocardial Infarction

Choong-Won Goh, MD¹, Se-Joong Rim, MD¹, Jong-Won Ha, MD¹,
June Kwan, MD², Donghoon Choi, MD¹, Ji-Young Kim¹,
Eun-Kyung Hwang¹, Yangsoo Jang, MD¹ and Namsik Chung, MD¹

¹Cardiology Division, Yonsei Cardiovascular Center, College of Medicine, Yonsei University, Seoul,

²Cardiology Division, College of Medicine, Inha University, Seoul, Korea

ABSTRACT

Background and Objectives : Determining the presence of viable myocardium has prognostic and therapeutic implications in the treatment of acute myocardial infarction (AMI). The aim of this study was to assess the ability of dobutamine echocardiography (DE) to detect viable myocardium and predict the late improvement of regional left ventricular dysfunction after AMI. **Methods** : Twenty-five patients (male 24, mean age 57 ± 9.6) with AMI underwent DE (dobutamine : 0, 5, 10 and 20 μg/kg/min) in 4.8 ± 2.2 days after infarction. Revascularization of infarct related artery was performed in 20 patients (percutaneous coronary angioplasty 18, coronary artery bypass graft surgery 2). A follow-up 2D-echocardiography was performed at 7.1 ± 2.3 months after AMI. **Results** : 1) Improvement of regional wall motion abnormality (RWMA) was observed in 12 patients during DE [DE (+) group]. Thirteen patients showed no improvement of RWMA [DE (-) group]. 2) In follow-up 2D-echocardiography, 10 patients showed improvement of RWMA among DE (+) group (positive predictive value = 83.3%). Two patients showed improvement of RWMA among DE (-) group (negative predictive value = 84.6%). Sensitivity and specificity of DE in predicting late recovery of RWMA were 83.3% and 84.6% each. DE performed in the early stage of AMI seems to be useful in prediction of late recovery of regional left ventricular dysfunction. (**Korean Circulation J 1998;28(9):1473-1479**)

KEY WORDS : Dobutamine echocardiography · Viable myocardium · Acute myocardial infarction.

: 1998 8 25
: 1998 9 25
: , 120 - 752 134
: (02) 361 - 7071, 7049 · : (02) 393 - 2041
E - mail : gohrick@yahoo.com

서 론

(stunned myocardium)¹⁾
(hibernating myocardium)²⁾
3)4) 가 가
5-8) 가
7 가
가

재료 및 방법

연구대상
1995 9 1996 3
도부타민부하 심초음파검사
2 7 2.5 MHz
(Hewlett - Packard
Sonos 1500).
(2 - dimensional echocardiography)
(5, 10 and 20 μ gm/kg/min 5)
12 - lead 가

nitroglycerin
parasternal
long axis view, parasternal short axis view, apical 4
chamber view, apical 2 chamber view

digital 4
(Prism imaging,
Freeland systems, USA). 2
가

심실벽운동의 평가
(American Society of Echocardiography) 16
1 ,
2 , 3 , 4
(dyskinesia)
5 2
1

관상동맥조영술
7 10
가 (revascularization
therapy)
추적 심초음파검사
5 10 2

(baseline view) 2
1

결 과

대상환자의 임상적 특성 31
25
가 (81%).
57 ± 9.6 (37 76)

가 24 1 4.8 ± 2.2
 14
 , Q
 가 (Table 1).

도부타민부하 심초음파검사 및 추적 심초음파검사

20 µ/kg/min

7.1 ± 2.3

[dobutamine - responsive group : DE(+) group]
 12 10
 [positive predictive value = 83.3%].

[dobutamine - unresponsive group : DE(-) group] 13
 2

Table 1. Clinical and angiographic characteristics of patients

	Viable	Nonviable	P value
Patients(M : F)	12(11 : 1)	13(13 : 0)	NS
Age(yrs)	56 ± 9.9	58 ± 9.4	NS
Thrombolysis	7(58%)	7(54%)	NS
Q wave MI	10(83%)	13(100%)	NS
Anterior MI	7(58%)	8(62%)	NS
% stenosis of IRA(%)	86 ± 12.2	86 ± 11.7	NS
TVR	9(75%)	10(77%)	NS
Multi-vessel disease	5(42%)	8(62%)	NS

IRA : Infarct related artery
 TVR : Target vessel revascularization

Table 2. Response to dobutamine echocardiography (DE) and recovery of regional wall motion abnormality (RWMA)

		Recovery of RWMA		Total
		+	-	
DE	(+)	10	2*	12
	(-)	2	11	13
Total		12	13	25

Sensitivity = 10/12 = 83.3%

Specificity = 11/13 = 84.6%

* : No revascularization

(negative predictive value = 84.6%).
 가
 (sensitivity) 83.3%
 (specificity) 84.6% (Table 2).

관상동맥조영술

10 ± 3

15 3

7
 12 13 (9
 4) 85.9 ± 11.
 7% DE(+) group DE(-) group
 (85.4% vs 86.5%). 18

2
 5 (Fig. 1).
 6

4
 가 2
 가
 4 1 2
 (grade 1/3)
 1
 (grade 3/3).

고찰

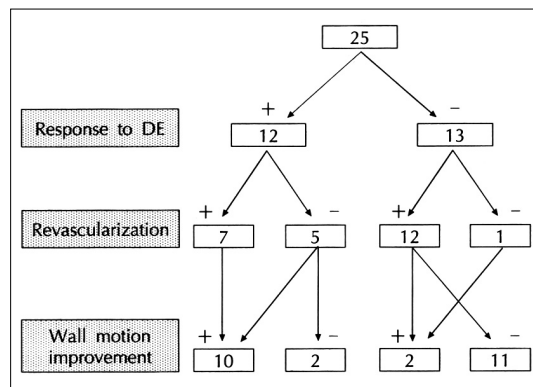


Fig. 1. Diagram of response to dobutamine echocardiography (DE), revascularization and late wall motion improvement.

(infarct myocardium) (stunned myocardium) myocardium) .¹⁾ (hibernating myocardium) .³⁾⁴⁾ (positive inotropic effect) (positive chronotropic effect) .¹⁹⁾

가 가 가

3) 9) Knudsen ¹⁰⁾ (contractile reserve) 3 1990 Pierard

가 가 가 가

2)11) 가 가 가 16)17)

가 가 evitali 가 Pr-

6)12-14) SPECT (single photon emission computed tomography),¹¹⁾¹⁵⁾ (positron emission tomography, PET)가¹³⁾¹⁶⁾ (contractile reserve) .⁵⁻⁸⁾ Smart .²⁰⁾ Shim¹²⁾¹⁴⁾ (10) Shim²¹⁾

가 Lee ¹⁷⁾ 가 .²²⁾

83.3% 84.6% Lee ²³⁾ Jeong . Lee²⁴⁾ 4

60% 100% 가 가

23)

가 가 가 가 가
(, false positive) 가 가 가
^{20)27 - 29)}

가 가 가 가 가
(PTCA, CABG) 가 연구의 제한점
가 25
(subendocardial area)

20% 가 가 가
20%
²⁵⁾ dobutamine isop - 7
roterenol

가 가 가 가 가
가 가 가 가 가
80%
(ventricular remodeling)

가 가 가 가 가 가 가 가 가 가 가
Afridi 가 연구목적 :
100%
(positive predictive value) ²⁶⁾
방 법 :
1995 9 1996 3
25 (24 , 57 ± 10)
5 μgm/kg/min 20 μ/kg/

min

결 과 :

1) 1995 9 1996 3
 25
 (24 , 57 ± 9.6 range ; 37
 76) 4.8 ± 2.2 (2 10)
 DE
 2) 12
 [DE(+)].
 3) 15
 , 3 7
 12 , 13 . 17
 2
 . 5
 4) DE(+) 10
 (=83.3%). DE(-)
 2 (=8
 4.6%).
 DE 83.3%
 84.6%

결 론 :

가

중심 단어 :

감사문

sonographer

REFERENCES

1) Braunwald E, Kloner RA. *The stunned myocardium: Prolonged, postischemic ventricular dysfunction.* *Circulation* 1982;66:1146-6.
 2) Rahimtoola SH. *A perspective on the three large multic-*

enter randomized clinical trials of coronary bypass surgery for chronic stable angina. *Circulation* 1985;72 (Suppl):V-123-35.
 3) Picano E, Lattanzi F, Sicari R, Silvestri O, Polimeno S, Pingitore A, et al. *Role of stress echocardiography in risk stratification early after an acute myocardial infarction. EPIC (Echo Persantin International Cooperative) and ED-IC (Echo Dobutamine International Cooperative) Study Groups.* *Eur Heart J* 1997;18 Suppl (D):D78-85.
 4) Williams MJ, Odabashian J, Lauer MS, Thomas JD, Marwick TH. *Prognostic value of dobutamine echocardiography in patients with left ventricular dysfunction.* *J Am Coll Cardiol* 1996;27(1):132-9.
 5) Kaul S. *Dobutamine echocardiography for determining myocardial viability after reperfusion: Experimental and clinical observations.* *Eur Heart J* 1995;16 (Suppl M):17-23.
 6) Haque T, Furukawa T, Takahashi M, Kinoshita M. *Identification of hibernating myocardium by dobutamine stress echocardiography: Comparison with thallium-201 reinjection imaging.* *Am Heart J* 1995;130(3 Pt 1):553-63.
 7) Leclercq F, Messner-Pellenc P, Moragues C, Rivalland F, Carabasse D, Davy JM, et al. *Myocardial viability assessed by dobutamine echocardiography in acute myocardial infarction after successful primary coronary angioplasty.* *Am J Cardiol* 1997;80(1):6-10.
 8) Lualdi JC, Douglas PS. *Echocardiography for the assessment of myocardial viability.* *J Am Soc Echocardiogr* 1997; 10(7):772-80.
 9) Pi' rard LA, De Landsheere CM, Berthe C, Rigo P, Kullbertus HE. *Identification of viable myocardium by echocardiography during dobutamine infusion in patients with myocardial infarction after thrombolytic therapy: Comparison with positron emission tomography.* *J Am Coll Cardiol* 1990;15:1021-31.
 10) Knudsen AS, Darwish AZ, NGgaard A, GGzschke O, Thygesen K. *Time course of myocardial viability after acute myocardial infarction: An echocardiographic study.* *Am Heart J* 1998;135(1):51-7.
 11) Kostopoulos KG, Kranidis AI, Bouki KP, Antonellis JP, Kappos KG, Rodogianni FE, et al. *Detection of myocardial viability in the prediction of improvement in left ventricular function after successful coronary revascularization by using the dobutamine stress echocardiography and quantitative SPECT rest-redistribution-reinjection 201TI imaging after dipyridamole infusion.* *Angiology* 1996;47(11): 1039-46.
 12) Iliceto S, Galiuto L, Marchese A, Cavallari D, Colonna P, Biasco G, et al. *Analysis of microvascular integrity, contractile reserve, and myocardial viability after acute myocardial infarction by dobutamine echocardiography and myocardial contrast echocardiography.* *Am J Cardiol* 1996; 77(7):441-5.
 13) Dilsizian V, Bonow RO. *Current diagnostic techniques of assinnmycdlvaility in patients whih brangand stuned myocardium.* *Circulation* 1993;87:1-20.
 14) Meza MF, Kates MA, Barbee RW, Revall S, Perry B, Murgu JP, et al. *Combination of dobutamine and myocardial contrast echocardiography to differentiate postischemic from infarcted myocardium.* *J Am Coll Cardiol* 1997; 29(5):974-84.
 15) Dilsizian V, Rocco TP, Freedman NMT, Leon MB, Bonow

- RO. Enhanced detection of ischemic but viable myocardium by the reinjection of thallium after stress-redistribution imaging. *N Engl J Med* 1990;323:141-6.
- 16) Sawada S, Elsner G, Segar DS, O'Shaughnessy M, Khouri S, Foltz J, et al. Evaluation of patterns of perfusion and metabolism in dobutamine-responsive myocardium. *J Am Coll Cardiol* 1997;29(1):55-61.
 - 17) Lee HH, Džvila-Romžn VG, Ludbrook PA, Courtois M, Walsh JF, Delano DA, et al. Dependency of contractile reserve on myocardial blood flow: Implications for the assessment of myocardial viability with dobutamine stress echocardiography. *Circulation* 1997;96(9):2884-91.
 - 18) Waku S, Ohkubo T, Takada K, Ishihara T, Ohsawa N, Adachi I, et al. Prediction of wall motion improvement after coronary revascularization in patients with postmyocardial infarction: Diagnostic value of dobutamine stress echocardiography and myocardial contrast echocardiography. *J Cardiol* 1997;30(4):197-203.
 - 19) Picane E. Stress echocardiography: From pathophysiological toy to diagnostic tool. *Circulation* 1992;85:1604-12.
 - 20) Previtali M, Lanzarini L, Poli A, Fetiveau R, Barberis P. Dobutamine stress echocardiography early after myocardial infarction treated with thrombolysis. Identification of myocardial viability and ischemia and relation to spontaneous functional recovery. *Int J Card Imaging* 1996;12(2):97-104.
 - 21) Shim WJ, Song WH, Jin DK, Lim DS, Park CG, Kim YH, et al. Comparison of dobutamine echocardiography and contrast echocardiography in patients with myocardial infarction. *Korean Circulation J* 1996;26(1):62-8.
 - 22) Smart SC, Sawda S, Ryan T, Segar D, Atherton L, Berkovitz K, et al. Low-dose dobutamine echocardiography detects reversible dysfunction after thrombolytic therapy of acute myocardial infarction. *Circulation* 1993;88(2):405-15.
 - 23) Lee K, Kang DH, Song JK, Lee CW, Hong MK, Kim JJ, et al. Comparison of dobutamine echocardiography and thallium scan in assessment of viable myocardium after acute myocardial infarction. *Korean Circulation J* 1998;28:215-21.
 - 24) Jeong JW, Oh SK, Lim SB, Ko KI, Park BH, Park YK, et al. Usefulness of dobutamine stress echocardiography for identification of viable myocardium in acute myocardial infarction. *J Korean Soc Echocardiogr* 1997;5(2):94-102.
 - 25) Lieberman AN, Weiss JL, Jugdutt BI, Becker LC, Bulkley BH, Garrison JG, et al. Two-dimensional echocardiography and infarct size: Relationship of regional wall motion and thickening to the extent of myocardial infarction in the dog. *Circulation* 1981;63(4):739-46.
 - 26) Afridi I, Main ML, Grayburn PA. Accuracy of dobutamine echocardiography for detection of myocardial viability in patients with an occluded left anterior descending coronary artery. *J Am Coll Cardiol* 1996;28(2):455-9.
 - 27) Beckmann S, Bocksch W, Meller C, Scharlt M. Does dobutamine stress echocardiography induce damage during viability diagnosis of patients with chronic regional dysfunction after myocardial infarction? *J Am Soc Echocardiogr* 1998;11(2):181-7.
 - 28) Elsässer A, Meller KD, Vogt A, Strasser R, Gagel C, Schleppe M, Klövekorn WP. Assessment of myocardial viability: Dobutamine echocardiography and thallium-201 single-photon emission computed tomographic imaging predict the postoperative improvement of left ventricular function after bypass surgery. *Am Heart J* 1998;135(3):463-75.
 - 29) Kranidis A, Bouki T, Kostopoulos K, Anthopoulos P, Kappos K, Antonellis J, et al. Stress echocardiography using adenosine combined with nitroglycerin-dobutamine in the detection of viable myocardium in patients with previous myocardial infarction. *Angiology* 1997;48(2):127-33.