



The Journal of
NUCLEAR MEDICINE

Cerebral Perfusion Impairment in a Patient with Toluene Abuse

Young Hoon Ryu, Jong Doo Lee, Pyeong Ho Yoon, Pyoung Jeon, Dong Ik Kim and Dong Won Shin

J Nucl Med. 1998;39:632-633.


This article and updated information are available at:
<http://jnm.snmjournals.org/content/39/4/632>

Information about reproducing figures, tables, or other portions of this article can be found online at:
<http://jnm.snmjournals.org/site/misc/permission.xhtml>

Information about subscriptions to JNM can be found at:
<http://jnm.snmjournals.org/site/subscriptions/online.xhtml>

The Journal of Nuclear Medicine is published monthly.
SNMMI | Society of Nuclear Medicine and Molecular Imaging
1850 Samuel Morse Drive, Reston, VA 20190.
(Print ISSN: 0161-5505, Online ISSN: 2159-662X)

© Copyright 1998 SNMMI; all rights reserved.

 SOCIETY OF
NUCLEAR MEDICINE
AND MOLECULAR IMAGING

Cerebral Perfusion Impairment in a Patient with Toluene Abuse

Young Hoon Ryu, Jong Doo Lee, Pyeong Ho Yoon, Pyoung Jeon, Dong Ik Kim and Dong Won Shin

Division of Nuclear Medicine, Departments of Diagnostic Radiology and Psychiatry, Yonsei University College of Medicine, Seoul, Korea

We report the case of a 17-yr-old man diagnosed as a toluene abuser. He had an 8-mo history of toluene inhalation exposure and was admitted to this hospital with symptoms of auditory and visual hallucination. Magnetic resonance imaging (MRI) revealed no structural abnormalities both on T1- and T2-weighted images, whereas SPECT using ^{99m}Tc -ethyl cysteinate dimer (ECD) showed multifocally decreased perfusion in the cerebral cortex, basal ganglia and thalami. Our case indicates that SPECT detects early central nervous system injury from toluene inhalation even when neurological examination and neuroanatomic imaging such as MRI are normal.

Key Words: toluene; SPECT; cerebral perfusion; magnetic resonance imaging; technetium-99m-ethyl cysteinate dimer

J Nucl Med 1998; 39:632-633

Toluene is one of the most commonly used and abused organic solvents and is a major component of many paints, lacquers and glues. Toluene has a high potential for abuse primarily from inhaling toluene vapors from products such as glue or spray paint (1-3). Toluene has a low general toxicity, but chronic inhalation by abusers has been reported to cause several impairments including tremors, changes in visual intelligence, disturbance of sensory function, memory function and verbal intelligence, convulsions, cerebellar ataxia and dementia (4-8). Acute toluene intoxication releases behavioral inhibition and causes a loss of consciousness at higher concentrations (9). Neuroanatomic imaging findings of toluene abuse using magnetic resonance imaging (MRI) have been reported (4-7,10-14); however, cerebral perfusion changes of toluene abuse using brain SPECT had not been previously reported.

This case report describes the SPECT findings of a patient with toluene abuse and compares them with correlative gross morphological MRI findings.

CASE REPORT

A 17-yr-old man who had a 2 wk-history of auditory and visual hallucinations and decreased memory function was admitted to psychiatry for delinquent behavior and substance abuse. Medical history was notable for chronic and frequent glue sniffing for 8 mo. According to a survey of the glue labels he had used, toluene was the major agent. He had no history of neurological or psychological problems before he began to abuse toluene. The family history was negative for neurological disease.

General physical examination showed no abnormalities except for emaciation. He was submissive, attentive and cooperative during the interview. Detailed neurological and substance abuse histories were obtained. The patient received a psychological test battery consisting of the Wechsler Adult Intelligence Scale, Wechsler Memory Scale, the modified Halstead-Reitan neuropsychological test battery and computerized neuropsychological test. Verbal,

performance and full-scale IQ were 81, 106 and 92, respectively. He showed impairment of short-term memory and mild abnormalities on tactual performance test, finger tapping test and fingertip number writing test; however, other neurological abnormalities were not present. Normal results were obtained for the following laboratory tests: complete blood count, urinalysis, Venereal Disease Research Laboratories, fluorescent troponomal antibody absorption, serum electrolytes, liver function test, blood urea nitrogen, serum creatinine and chest and skull radiographs. An electroencephalographic mapping revealed mild cortical dysfunction of the right frontal lobe. Visual evoked potential and brainstem auditory evoked potential were normal.

We performed both brain MRI and SPECT on the same day. SPECT using ^{99m}Tc -ethyl cysteinate dimer (ECD) showed multifocal impairment of perfusion in bilateral frontal, parietal cortex, basal ganglia and thalami (Fig. 1A), whereas MRI revealed no perceptible morphological and signal abnormalities on either T1- or T2-weighted images (Fig. 1B).

After discharge from the hospital, he discontinued sniffing glue. A follow-up SPECT study taken 14 mo after toluene abstinence revealed nearly complete normalization perfusion (Fig. 1A).

DISCUSSION

Recently, solvent abuse became an important public health problem particularly among school-aged children. Inhalation of toluene-based products such as glue or spray paint is popular with solvent sniffers because of the euphoric effect and easy accessibility of these substances. The neurotoxicity of toluene in humans has been discussed for many years, and the brain seems to be the main target organ for toluene toxicity (1). The mechanism of the toluene neurotoxicity is not clearly understood; however, toluene is known to enter the blood rapidly through the respiratory tract, and asymptomatic levels are reached within approximately 60 min (15). Toluene has a high lipid solubility and no protein binding capability and distributes according to lipid contents of the brain (16). By the results, toluene may cause progressive multifocal impairments. Pancerbellar dysfunction, pyramidal tract abnormality, personality changes, emotional instability, paranoid psychosis, cognitive impairment and frank dementia have been attributed to toluene abuse (1-4,7). Persistent neurologic abnormality has been seen in spite of variable degree of spontaneous recovery within months after the cessation of toluene inhalation (3).

Previous investigations using CT combined with gross necropsy findings have described diffuse cortical atrophy in toluene inhalant abusers (3,17). In addition, MRI of toluene abuse has been reported to show poor differentiation of gray and white matter, increased periventricular signal intensity and moderate hypointensity of thalami and basal ganglia on T2-weighted images (4-7,10-14). Our case, unlike other studies, showed no structural abnormality on MRI. SPECT findings depicted multifocal cerebral cortical and basal ganglia and thalamic perfusion impairments. Only a few reports dealing with perfusion

Received Mar. 14, 1997; revision accepted Aug. 6, 1997.

For correspondence or reprints contact: Jong Doo Lee, MD, Division of Nuclear Medicine, Department of Diagnostic Radiology, Yonsei University College of Medicine, Seodaemun-Gu Shinchon Dong 134, Seoul, Korea.

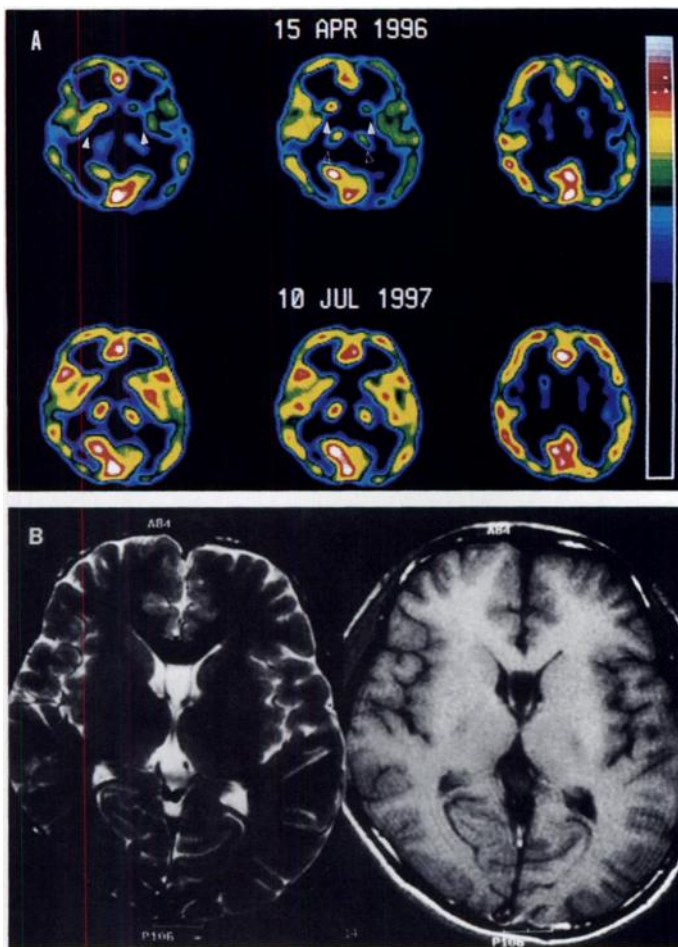


FIGURE 1. (A) Initial ^{99m}Tc -ECD brain SPECT using annular crystal gamma camera revealed multiple areas of decreased perfusion involving bilateral basal ganglia (solid arrow), thalami (open arrow) and cerebral cortex irregularly (upper panel). A follow-up SPECT 14 mo after initial study revealed nearly complete normalization perfusion. (lower panel). (B) T2 (left)- and T1 (right)-weighted axial MRI at level of basal ganglia and thalami showed no morphological or signal intensity abnormalities.

changes of toluene intoxication had been documented (6). In a study to examine effects of toluene on synaptic transmission and neuronal morphology using guinea pig hippocampal slices, toluene at high concentrations (1000 $\mu\text{g}/\text{ml}$) inhibits synaptic transmission selectively and causes lasting physiological effects unaccompanied by gross morphological changes with longer exposures (9). Neurobehavioral abnormalities are the most disabling and frequent features of chronic toluene abuse, and they may herald the onset of permanent central nervous system (CNS) dysfunction. Moreover, Stengard and O'Conner (18) suggested that toluene-induced behavioral effects were associated with the decreased release of γ -aminobutyric acid within

the globus pallidus in a rat toluene inhalation study. Thus, multifocal perfusion impairments in the basal ganglia, thalami and cerebral cortex on initial SPECT without corresponding abnormalities on MRI in our case may reflect functional alterations rather than structural abnormalities.

On a follow-up SPECT study, significant restoration of perfusion abnormalities after discontinuing glue sniffing was noted with clinical improvement. The behavioral effects of inhaling toluene after a single exposure are reversible, but although reversible, they may also be an early sign of CNS impairment leading to irreversible losses in performance with repeated exposures (19,20).

CONCLUSION

SPECT detects early CNS injury from toluene inhalation even with normal MRI findings and only subtle neurological abnormalities.

REFERENCES

- Benignus VA. Neurobehavioral effects of toluene: a review. *Neurobehav Toxicol Teratol* 1981;3:407-415.
- Lazar RB, Ho SU, Melen O, Daghestani AN. Multifocal central nervous system damage caused by toluene abuse. *Neurology* 1983;33:1337-1340.
- Hormes JT, Filley CM, Rosenberg NL. Neurologic sequelae of chronic solvent abuse. *Neurology* 1986;36:698-702.
- Rosenberg NL, Spitz MC, Filley CM, Davis KA, Schaumburg HH. Central nervous system effects of chronic toluene abuse-clinical, brainstem evoked response and magnetic resonance imaging studies. *Neurotoxicol Teratol* 1988;10:489-495.
- Filley CM, Heaton RK, Rosenberg NL. White matter dementia in chronic toluene abuse. *Neurology* 1990;40:532-534.
- Hirai H, Ikeuchi Y. MRI of chronic toluene intoxication. *Rinsho Shinkeigaku-Clin Neurology* 1993;33:552-557.
- Ikeda M, Tsukagoshi H. Encephalopathy due to toluene sniffing. Report of a case with magnetic resonance imaging. *Eur Neurol* 1990;30:347-349.
- Byrne A, Kirby B, Zibin T, Ensminger S. Psychiatric and neurological effects of chronic solvent abuse. *Can J Psychiatry* 1991;36:735-738.
- Ikeuchi Y, Hirai H. Toluene inhibits synaptic transmission without causing gross morphological disturbances. *Brain Res* 1994;664:266-270.
- Rosenberg NL, Kleinschmidt-Demasters BK, Davis KA, Dreisbach JN, Hormes JT, Filley CM. Toluene abuse causes diffuse central nervous system white matter changes. *Ann Neurol* 1988;23:611-614.
- Caldemeyer KS, Pascuzzi RM, Moran CC, Smith RR. Toluene abuse causing reduced MR signal intensity in the brain. *Am J Roentgenol* 1993;161:1259-1261.
- Kojima S, Hirayama K, Furumoto H. Magnetic resonance imaging in chronic toluene abuse and volitional hyperkinesia. *Clin Neurol* 1993;33:477-482.
- Xiong L, Matthes JD, Jinkins R. MR imaging of "spray heads": toluene abuse via aerosol paint inhalation. *Am J Neuroradiol* 1993;14:1195-1199.
- Unger E, Alexander A, Fritz T, Rosenberg N, Dreisbach J. Toluene abuse: physical basis for hypointensity of the basal ganglia on T2 weighted MR images. *Radiology* 1994;193:473-476.
- Benignus VA, Muller KE, Graham JA, Barton CN. Toluene levels in blood and brain of rats as a function of toluene level in inspired air. *Environ Res* 1984;33:39-46.
- Kiriu T, Ameno K, Fuke C, Ameno S, Ijiri I. The distribution of toluene in the brain and its effects on the brain catecholamines in acute toluene poisoning. *Japanese J Leg Med* 1990;44:25-33.
- Escobar A, Aruffo C. Chronic thinner intoxication: clinico-pathologic report of a human case. *J Neurol Neurosurg Psychiatry* 1980;43:986-994.
- Stengard K, O'Conner WT. Acute toluene exposure decreases extracellular γ -aminobutyric acid in the globus pallidus but not in striatum: a microdialysis study in awake, freely moving rats. *Eur J Pharmacol* 1994;292:43-46.
- Echverria D, Fine L, Langolf G, Schork A, Sampaio C. Acute neurobehavioral effects of toluene. *Br J Ind Med* 1989;46:483-495.
- Baker E, Fine L. Solvent neurotoxicity: the current evidence. *J Occup Med* 1986;28:126-128.