

Malocclusion with Congenital Missing of Lower Incisors

Kyung-Ho Kim¹⁾, Kwang-Chul Choy²⁾, Kil-Yong Chung³⁾, Hee-Sun Yun⁴⁾

Positions, angulation and mesiodistal dimension of lower incisors are important in esthetics, occlusion and post-treatment stability of lower arch. When lower incisor is congenitally missing, problems such as increased overjet and overbite, closing in of adjacent teeth and size/space discrepancies may occur.

When creating treatment plans, incisor position and angulation, lip support, anteroposterior skeletal relationship, canine-molar relationship, overjet, overbite, remaining growth potential, crowding and anterior tooth ratio have to be considered. For an accurate analysis of incisal size discrepancy, diagnostic model set-up may be helpful.

The two patients in this presentation both had two lower incisor missing, but the degree of crowding, skeletal relationship, lip support, molar relationship are different, and therefore treatment plan was different as well. Long term follow-up may be necessary for stability and retention.

Key Words : Lower incisor, Missing, Tooth size analysis, Size discrepancy

Missing of permanent tooth excluding 3rd molar is found in 3.5-6.5%, occurring more frequently in girls (3:2)⁵⁾. Missing of lower anterior tooth occurs in frequency next to 3rd molar, lower 2nd premolar, upper lateral incisor and upper 2nd premolar. In a study of 500 missing tooth cases, lower anterior tooth was missing in 6 cases with 7 teeth missing, and in 5 of those cases the space was closed⁴⁾.

If lower incisor is congenitally missing, number of orthodontic problems such as large overjet and

overbite, closing in of adjacent teeth and disharmony of space and tooth size may occur^{8,12)}. Since location, angulation, shape and mesiodistal dimension of lower incisors are significant factors in terms of esthetics, function and stability of anterior occlusion, such factors have to be considered in treating congenital missing of lower anterior tooth¹⁾.

Orthodontic approaches to missing of one lower incisor include: space provision followed by restoration; extraction of two upper premolars and one lower premolar or extraction of one lower incisor followed by conversion of a lower canine into a lower incisor; leaving the missing state and make class III anterior and posterior occlusion. If two lower incisors are missing, prosthodontic approach or extraction of two upper premolars may be considered.

When creating treatment plans, incisor angulation, lip support, anteroposterior skeletal relationship, canine-molar relationship, overjet, overbite, remaining growth

¹⁾ Assistant Professor, Department of Orthodontics, College of Dentistry, Yonsei University

²⁾ Assistant Professor, Department of Orthodontics, College of Dentistry, Yonsei University

³⁾ Resident, Department of Orthodontics, College of Dentistry, Yonsei University

⁴⁾ Resident, Department of Orthodontics, College of Dentistry, Yonsei University

potential, crowding and anterior tooth ratio have to be considered. Advantages and disadvantages must be weighed in order to choose between orthodontic and prosthodontic treatment¹²⁾.

When only one anterior tooth is missing, prosthodontic option may be considered if lips and facial features are sound, incisal angulation is within normal limits, and minimal crowding or slight spacing exists in mandibular arch. If tooth size analysis reveals that lower incisors are relatively larger than upper incisors, leaving the mandibular arch with three incisors may be considered. Indications for having three lower incisors include relatively large lower incisors compared to upper incisors, sound molar relationship and facial profile, missing of upper incisors and minimal crowding of upper anterior teeth. Contraindications include large overjet expected on diagnostic model set-up, crowding cases with no tooth size discrepancies or open bite cases with horizontal growth patterns^{2,7,11)}. In 'three incisors' cases, dimensional discrepancies between upper and lower incisors with large overjet may occur, and this problem can be managed by interproximal stripping of upper incisors, compensatory adjustment of incisal angulation or leaving as Class III canine and molar relationships⁶⁾.

If there are lip protrusion, labioverted incisors and anterior crowding, extraction of two upper premolars and one lower premolar or incisor may be indicated. In this case, one lower canine has to be converted to smaller lateral incisor, and the canine must be recontoured with smaller mesiodistal dimension in order to achieve esthetics and appropriate overjet.

When two lower incisors are missing and there are lip protrusion, labioverted upper incisors and slight crowding of upper incisors, two upper premolars are extracted. Reshaping of lower canine is required in this case as well. If the facial profile is sound with normal incisal angulation and minimal crowding, space provision and restorative treatment may be the option.

Poor occlusion due to size discrepancy between upper and lower incisors frequently occurs if lower incisors are congenitally missing, and incisal dimension has to be accurately analyzed with diagnostic model set-up^{1,12)}.

Bolton analysis includes overall ratio of 12 upper and

lower incisors and anterior ratio of 6 upper and lower incisors, and 91.3% and 77.2% are the normal values, respectively³⁾. Neff's anterior coefficient is the ratio between 6 upper incisors and 6 lower incisors, with 1.20-1.22 as the normal range⁹⁾. Sum of incisors is the ratio between 4 upper and lower incisors, with 4:3 as the normal value. If the dimensional analysis reveals that either upper or lower incisors are relatively large, reducing the larger side with interproximal stripping or disking, or leaving space in the smaller side are considered.

When interproximal stripping is done, enamel thickness must be considered. Enamel thickness is large in the distal side of central incisors and mesial side of canines, and small in the mesial side of lateral incisors. Incisors with wide incisal edge may be more conductive to interproximal stripping. Overzealous stripping may leave the tooth vulnerable to decay, sensitive to thermal stimulus and with reduced papilla space⁶⁾. In some studies, however, SEM analysis revealed no evidence of increased dental caries after enamel stripping¹⁰⁾.

The present clinical presentation includes two cases with missing of lower incisors.

Case 1

1. Patient : 11 years 6 months aged female
2. Chief complaint : Upper anterior protrusion
3. Intraoral findings
 Discoloration of upper incisors, missing of two lower incisors, Class III molar key, upper and lower anterior crowding, and large overjet and overbite are the existing features (Fig. 1, A-E).
4. Extraoral findings
 Slight lip fullness can be observed (Fig. 1, G-H).
5. Cephalometric analysis (Fig. 1, I-J)

SNA	80.5	SN to MP	33.0
SNB	78.5	1 to SN	112.0
ANB	2.0	IMPA	84.0
Wits	1.0	Rickett's esthetic line	
		Upper	0
		Lower	0

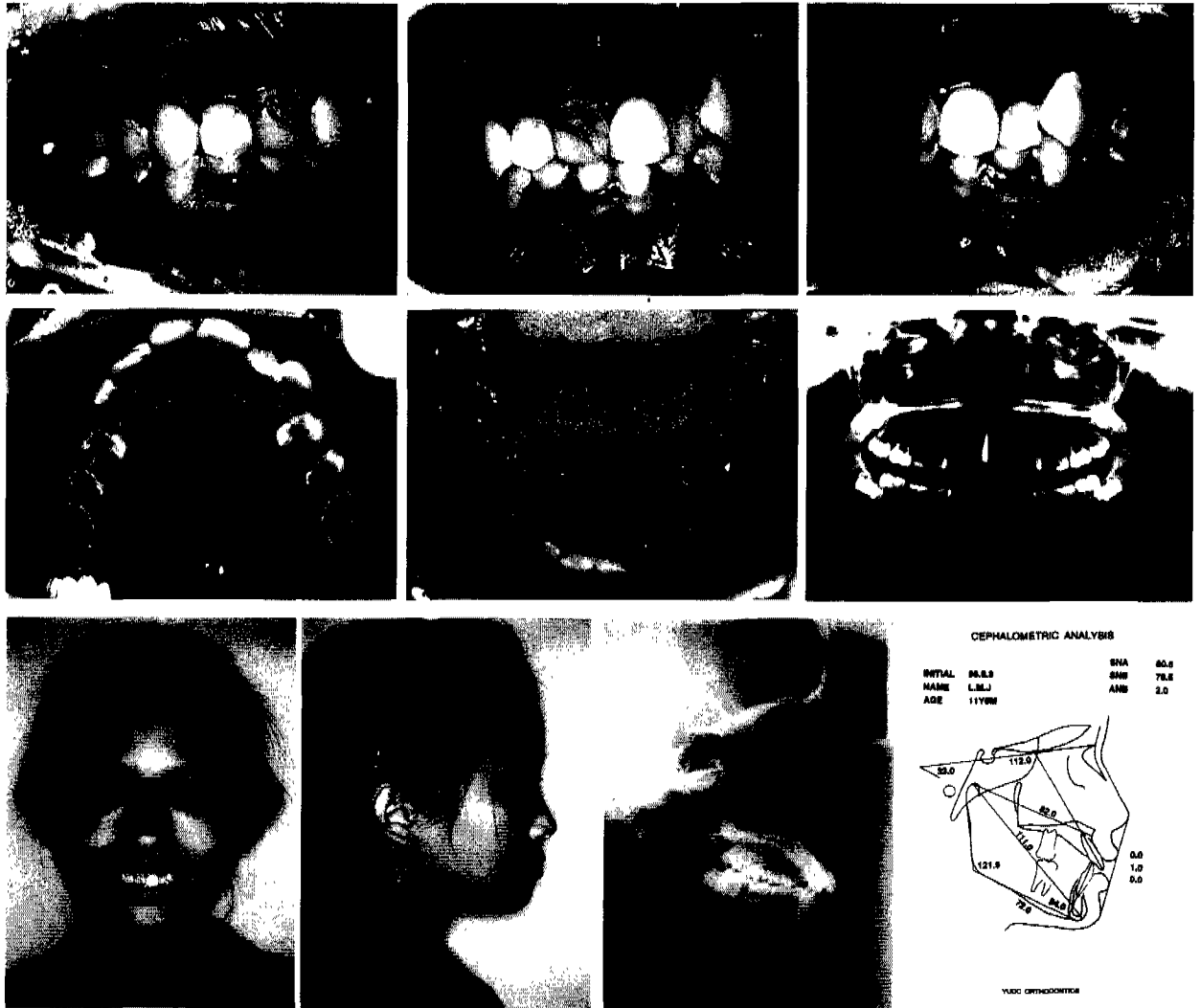


Fig. 1. Pre-treatment intraoral, extraoral photos and X-ray of case 1

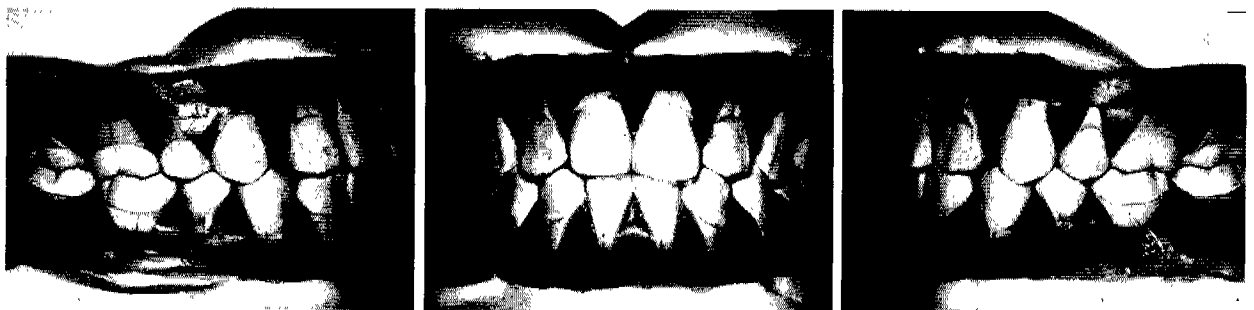


Fig. 2. Diagnostic model set-up of case 1 (Continued)

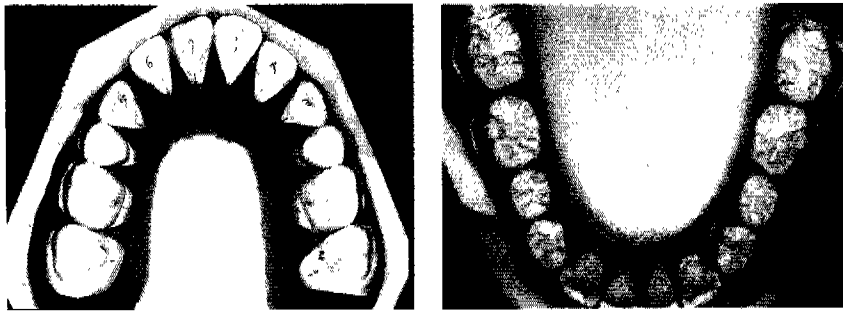


Fig. 2. Diagnostic model set-up of case 1

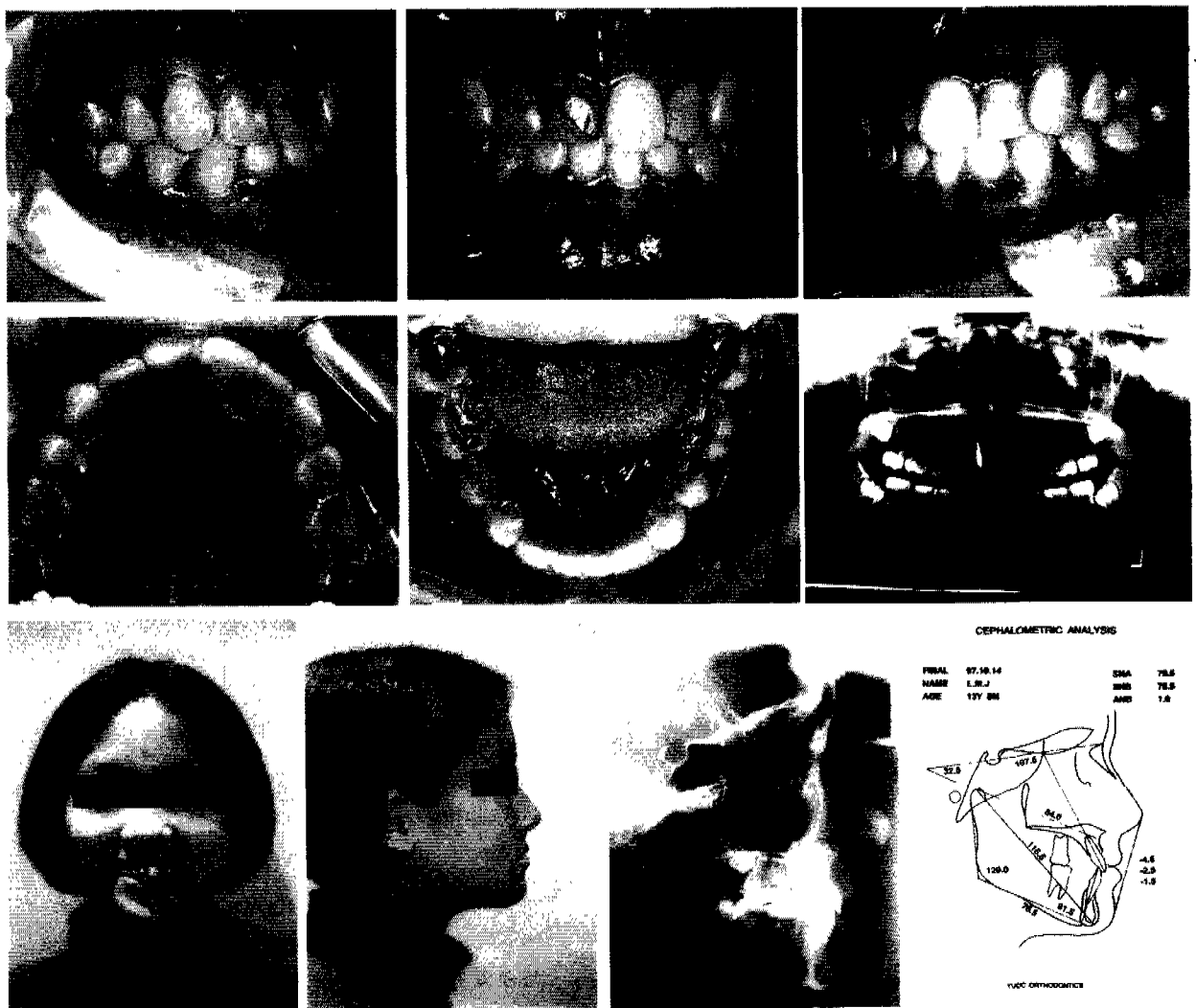


Fig. 3. post-treatment intraoral, extraoral photos and X-ray of case 1

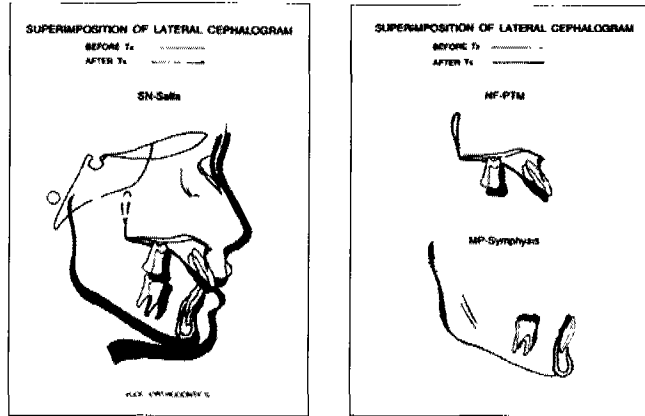


Fig. 4. Pre- and post-treatment lateral cephalometric X-ray superimposition

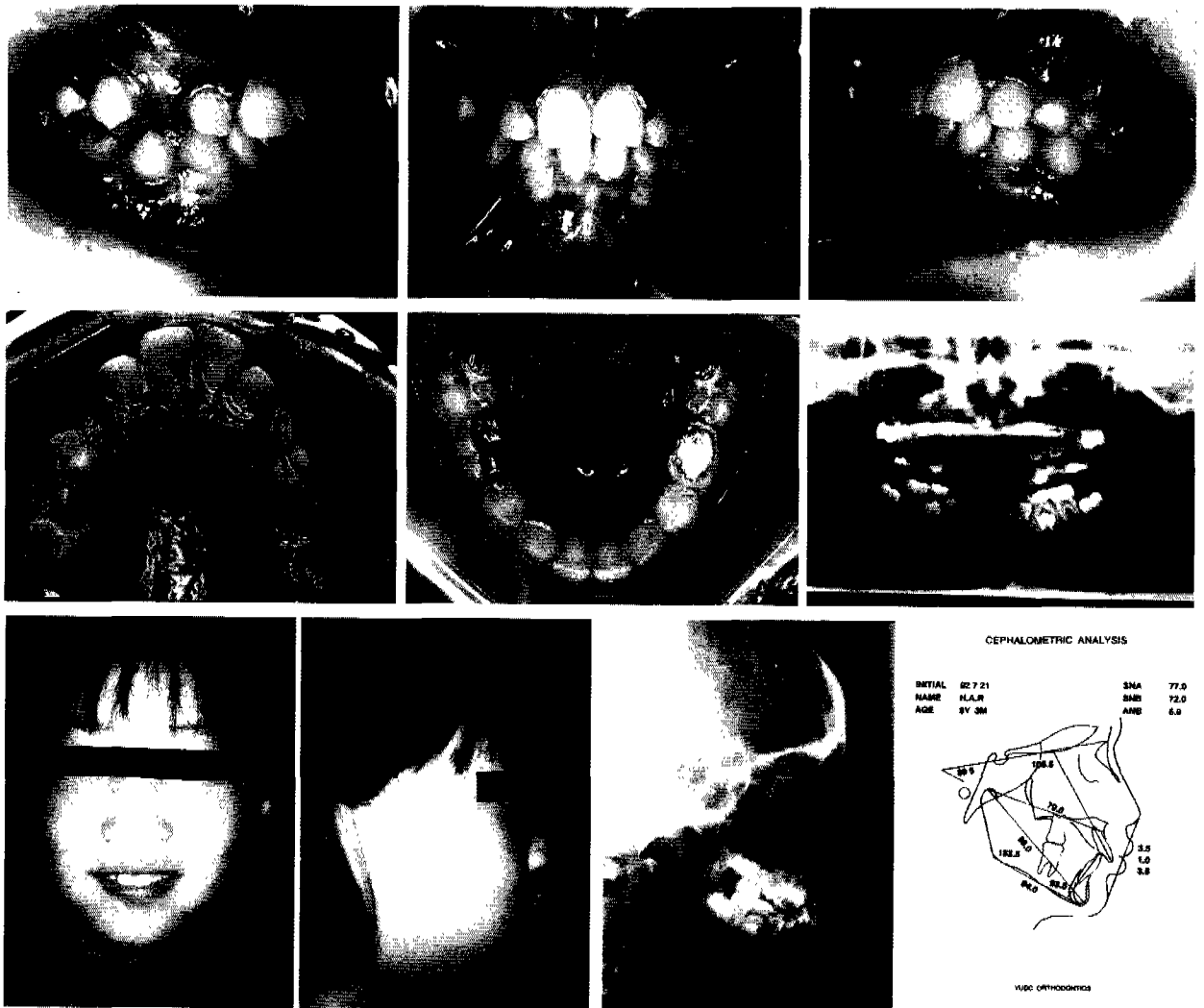


Fig. 5. Pre-treatment intraoral, extraoral photos and X-ray of case 2

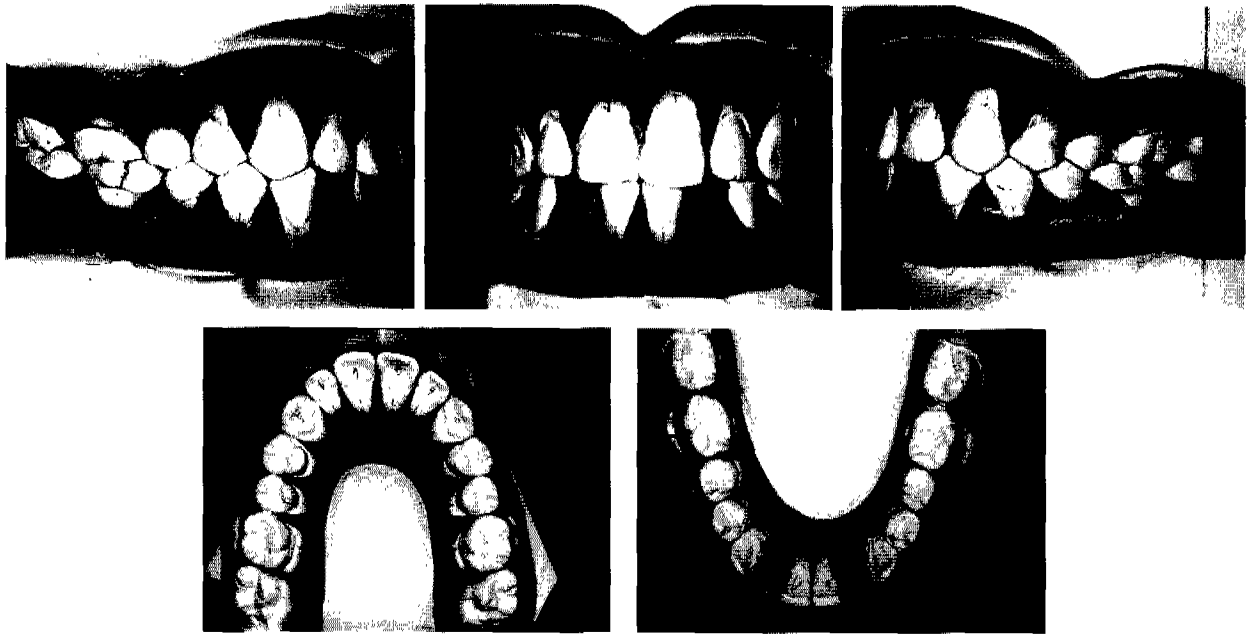

Fig. 6. Diagnostic model set-up of case 2

6. Diagnosis

Skeletal Class I with missing of two lower incisors

7. Treatment plan and treatment outcomes

For relief of upper anterior crowding, retraction of upper incisors and improvement of profile, extraction of premolars was planned. A diagnostic model set-up was done for the extraction case of upper premolars(Fig. 2, A-F). The lower canines were reshaped and brought to the size of lateral incisors in order to eliminate the space distally to the upper lateral incisors. After the extraction of upper 1st premolars headgear was used for anchorage reinforcement and lower canines were reshaped to lateral incisors.

8. Post-treatment cephalometric analysis (Fig. 3, I-J)

SNA 79.5	SN to MP	32.5
SNB 78.5	┘ to SN	107.5
ANB 1.0	IMPA	81.5
Wits -2.5	Rickett's esthetic line	
	Upper	-4.5
	Lower	-1.5

9. Treatment results and superimposition

The occlusion was relatively satisfactory but, facial

profile became concave because the mandible showed more growth than the maxilla (Fig. 3, 4).

Case 2

1. Patient : 8 years 3 months aged female
2. Chief complaint : Upper anterior protrusion
3. Intraoral findings

Two lower incisors are missing, Class II molar relationship, large overjet and overbite and spacing on lower incisor area can be observed (Fig. 5, A-E).

4. Extraoral findings

Lip incompetence and retrognathic mandible can be observed (Fig. 5, G-H).

5. Cephalometric analysis (Fig. 5, I-J)

SNA 77.0	SN to MP	39.5
SNB 72.0	┘ to SN	106.5
ANB 5.0	IMPA	93.5
Wits 1.0	Rickett's esthetic line	
	Upper	3.5
	Lower	3.5

6. Diagnosis

Skeletal Class II with missing of lower incisors

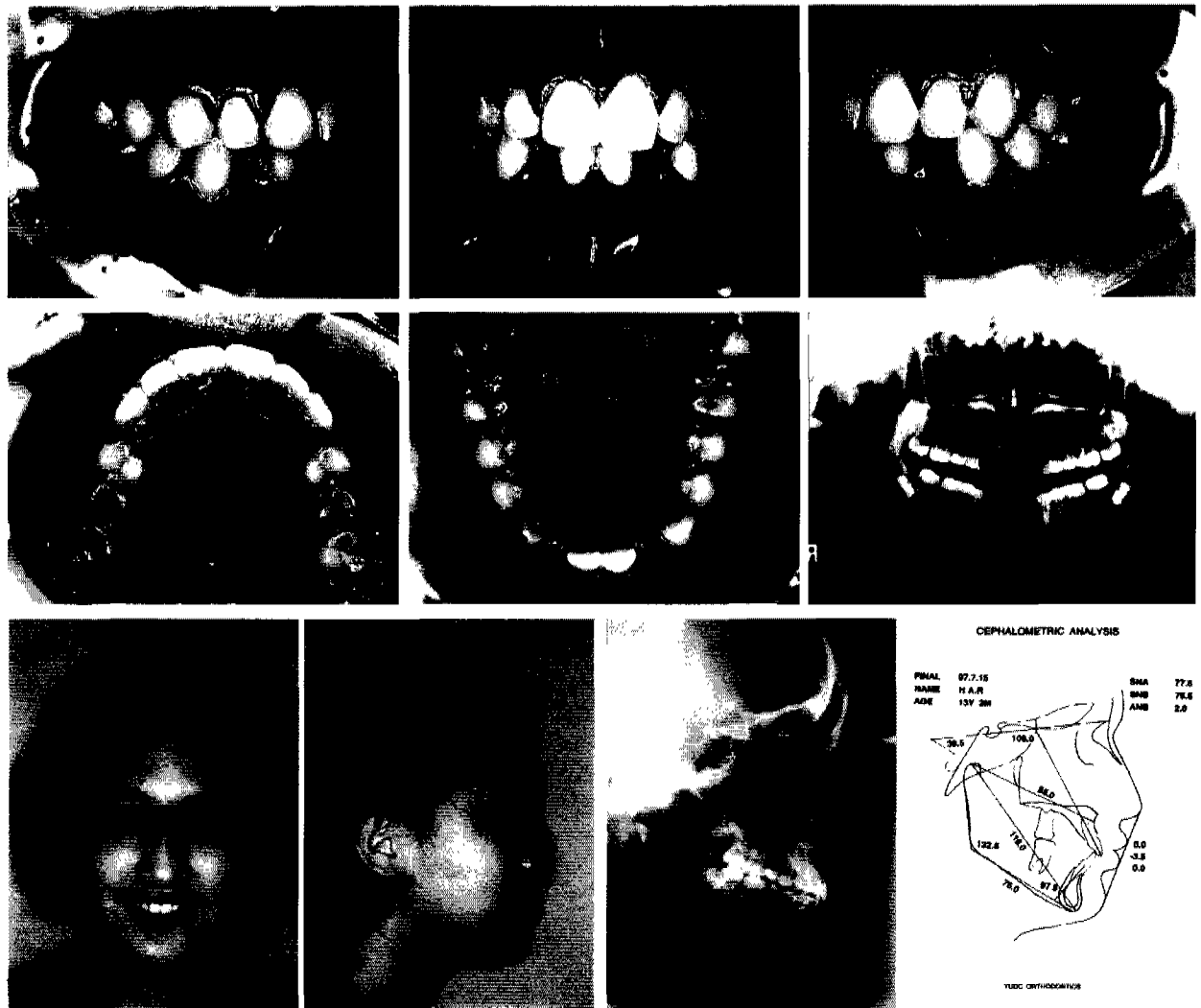


Fig. 7. Post-treatment intraoral, extraoral photos and X-ray of case 2

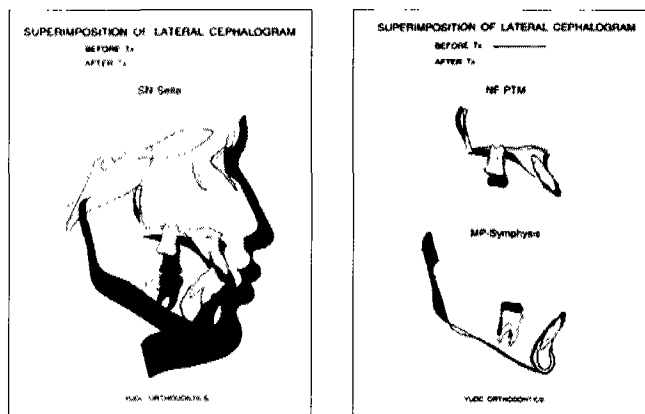


Fig. 8. Pre- and post-treatment lateral cephalometric X-ray superimposition

7. Treatment plan and treatment outcomings

On the basis that the patient was a growing child, had a Class II dental and skeletal relationship, and had mild crowding and normal upper and lower incisor angulation, headgear activator treatment with space regaining and prosthetic treatment was planned.

A diagnostic model set-up according to this treatment plan was done assuming all permanent teeth to be erupted (Fig. 6, A-E).

8. Post-treatment cephalometric analysis (Fig. 7, I-J)

SNA 77.5	SN to MP	39.5
SNB 75.5	⊥ to SN	108.0
ANB 2.0	IMPA	97.5
Wits -3.5	Rickett's esthetic line	
	Upper 0	
	Lower 0	

9. Treatment results and superimposition

Through long-term orthopedic treatment a significant amount of maxillary and mandibular growth was achieved and the occlusion was relatively satisfactory (Fig. 7, 8).

Summary

Positions, angulation and mesiodistal dimension of lower incisors are important in esthetics, occlusion and post-treatment stability of lower arch. When lower incisor is congenitally missing, problems such as increased overjet and overbite, closing in of adjacent teeth and size/space discrepancies may occur.

When creating treatment plans, incisor angulation, lip support, anteroposterior skeletal relationship, canine-molar relationship, overjet, overbite, remanining growth potential, crowding and anterior tooth ratio have to be considered. For and accurate analysis of incisal size

discrepancy, diagnostic model set-up may be helpful.

The two patients in this presentation both had two lower incisor missing, but the degree of crowding, skeletal relationship, lip support, molar relationship are different, and therefore treatment plan was different as well. Long term follow-up may be necessary for stability and retention.

REFERENCES

1. Chang YI, Baek SH, Park KJ. Consideration of orthodontic aspect in three lower incisor cases. *Korea J Orthod* 1994 : 24 : 759-72.
2. Bahreman AA. Lower incisor extraction in orthodontic treatment. *Am J Orthod* 1977 : 72 : 560-67.
3. Bolton WA. The clinical application of a tooth size analysis. *Am J Orthod* 1962 : 48 : 504-29.
4. Buchner HJ. Orthodontic treatment of cases complicated by absence of permanent teeth. *Angle Orthod* 1945 : 15 : 67-77.
5. Dermaut LR et al. Prevalence of tooth agenesis correlated with jaw relationship and dental crowding. *Am J Orthod Dentofac Orthop* 1986 : 90 : 204-10.
6. Kokich VG, Shapiro PA. Lower incisor extraction in orthodontic treatment. *Angle Orthod* 1984 : 54 : 139-53.
7. Levin S. An indication for the three incisor case. *Angle Orthod* 1964 : 34 : 16-24.
8. Moyer RE. *Handbook of Orthodontics* 4th ed. Year Book Medical Publishers. INC. 1988
9. Neff CW. The size relationship between the maxillary and mandibular anterior segments of the dental arch. *Angle Orthod* 1957 : 27 : 138-47.
10. Radlanski R. Morphology of interdental stripped enamel one year after treatment. *J Clin Orthod* 1989 : 23 : 748-50.
11. Tuverson DL. Anterior interocclusal relations. *Am J Orthod* 1980 : 78 : 361-93.
12. Van der Linden FPGM. & Boersma H. *Diagnosis & Treatment Planning in Dentofacial Orthopedics*. Quintessence Publishing Co., Ltd. 1987

국문초록

하악 전치의 선천적 결손을 동반한 부정 교합의 치험례

연세대학교 치과대학 교정학교실 (영동세브란스 병원)

김 경 호 · 최 광 철 · 정 길 용 · 윤 회 선

하악 전치의 위치와 각도, 형태와 근원심 폭경 등은 심미성, 전치부의 적절한 교합, 그리고 치료 후 안정성 측면에서 중요한 의미를 갖는다. 하악 전치가 선천적으로 결손된 경우 수평피개 및 수직피개의 증가, 인접치의 이동, 공극 및 치아 크기 부조화 등 교정적으로 복잡한 문제를 야기할 수 있으므로 하악 전치 결손시 이에 대한 충분한 고려가 필요하다.

하악 전치 결손의 치료계획 수립시 전치의 위치와 각도, 입술 모양, crowding양, 견치와 대구치 관계, 수평 및 수직피개, 전후방적 골격 관계 및 치아 크기 비율 등이 고려되어야 하며, 전치부 치아 크기 부조화에 대한 정확한 평가를 위해 diagnostic model set up을 시행하는 것이 많은 도움이 된다.

본 증례의 두 환자는 모두 하악 전치 2개가 결손되었지만 crowding양, 골격 관계 및 입술 모양, 구치 관계 등이 달랐으며 이에 따른 치료 계획 역시 발치 및 비발치로 상이하였다.

앞으로 두 환자의 치료후 안정 및 유지에 대한 장기간의 관찰이 필요하리라 사료된다.

주요 단어 : 하악전치, 결손, 치아 크기 분석, 치아 크기 부조화