

Effects of Small Molecular Antioxidants on Cerulein-induced Acute Pancreatitis in Rat

Joo Young Choi and Kyung Hwan Kim

Department of Pharmacology, Yonsei University College of Medicine, Seoul 120–752, Korea

It has been suggested that oxygen free radicals are involved in the initiation process of acute pancreatitis, although its pathogenesis is not clear. This study evaluates the roles of oxygen radicals and the effects of small molecular antioxidants (rebamipide, N-acetyl-cysteine, allopurinol, β -carotene) on the development of cerulein-induced acute pancreatitis. Acute edematous pancreatitis was induced by the intravenous infusion of cerulein at supramaximal dose of 10 μ g/kg/hour for 3.5 hours. The effects of antioxidants, rebamipide (100 mg/kg, i.p.), N-acetyl-cysteine (200 mg/kg, i.v.), allopurinol (20 mg/kg/hour), β -carotene (50 mg/kg, i.p.), were examined. Cerulein administration resulted in a significant increase in serum amylase activity and pancreatic malondialdehyde (MDA), but not glutathione peroxidase (GSHpx). The glutathione (GSH) content in pancreatic tissue decreased dramatically. Pretreatment of N-acetyl-cysteine significantly decreased the cerulein-induced hyperamylasemia and maintained GSH content in pancreas, but MDA was slightly decreased. In addition, N-acetyl-cysteine ameliorated histological damage. Allopurinol and β -carotene attenuated cerulein-induced hyperamylasemia, but histologically there was no difference from control. These results indicate that oxygen free radicals play an important role in the initiation of experimental acute pancreatitis. N-acetyl-cysteine is an effective antioxidant that ameliorates the cerulein-induced acute pancreatitis, and the possible therapeutic application of antioxidants against acute pancreatitis needs a further evaluation.

Key Words: Oxygen radicals, Cerulein, Acute pancreatitis, N-Acetyl-cysteine

INTRODUCTION

Acute pancreatitis is a disease with a high morbidity and mortality rate in man and can be initiated by a variety of stimuli including alcohol, hyperlipemia, migrating gallstone, and ischemia. It causes severe acinar cell damage, extensive interstitial edema, hemorrhage, and the migration of neutrophils into the damaged pancreatic gland. The pathogenesis of acute pancreatitis at the cellular level and the mechanisms that determine the clinical severity of illness are yet to be clarified (Alder & Kern, 1984).

As yet, researchers have been unable to find a common denominator that links the development of

the pancreatic injury in these different forms of the disease. Except for the protease inhibitor which is nonspecific and supportive, beneficial therapy for disease has not been established.

It has been demonstrated that oxygen free radicals play important roles in the development of the inflammation (Buldley, 1983). The involvement of oxygen radicals in the pathogenesis of acute pancreatitis was explained by Sanfey et al (1984), who used an *ex vivo* perfused canine pancreas preparation. Later, it was reported that oxygen radicals are generated at an early stage of disease and contributes to the tissue damage in various experimental models of pancreatitis (Schoenberg et al, 1992).

Oxidative injury is caused by an imbalance between oxidants and antioxidants. The primary defense is provided by the enzymes, such as superoxide dismutase (SOD), catalase, and glutathione peroxidase

Corresponding to: Kyung Hwan Kim, Department of Pharmacology, Yonsei University College of Medicine, #134 Sinchon-Dong, Seodaemun-Gu, Seoul 120-752, Korea. (Tel) 02-361-5224

(GSHpx). The second line of defense against oxygen-induced cellular injury are nonenzymatic scavengers such as thiols, especially reduced glutathione (GSH), α -tocopherol, carotenoids, ascorbate, uric acid, and methionine (Sies, 1991). However, if the rate of oxygen radical production exceeds the capacity of the endogenous antioxidant mechanisms, serious cell injury may ensue (Freeman & Crapo, 1982). In cerulein-induced acute pancreatitis, elevated concentration of lipid peroxidation products have been found in the early phase of the inflammation, in parallel with decreased activity of the radical scavenger, SOD (Dabrowski et al, 1988).

N-Acetyl-cysteine is an antioxidant that maintains intracellular GSH concentration and scavenges oxidants (Moldeus et al, 1986). Clinically N-acetyl-cysteine has been used to humans in order to treat various respiratory disease mediating oxygen radicals (Bernard, 1990). Rebamipide {2-(4-chlorobenzoylamino)-3-[2(1H)-quinolinone-4-yl]propionic acid} has been introduced as an antiulcer agent (Yamasaki et al, 1989). It inhibits production of superoxide by neutrophils, scavenges the hydroxy radical, and inhibits lipid peroxidation as well as increases endogenous prostaglandin in gastric mucosal (Yoshikawa et al, 1993). Xanthine oxidase uses molecular oxygen as a cofactor and converts xanthine and hypoxanthine to uric acid and superoxide anion as byproducts. Allopurinol is a xanthine oxidase inhibitor, and its effect on acute pancreatitis in animal model is controversial (Alessandre, 1995). β -Carotene is a precursor of vitamin A, which plays a role in vision, reproduction, and control of epithelial growth and differentiation. β -Carotene protected rats and mice against experimental tumors at various sites such as stomach, lung, colon, skin, and buccal mucosa (Tsuda et al, 1994). In addition, it has been reported that antioxidants supplements involving β -carotene, α -tocopherol, selenium, vitamin C, and methionine alleviated the symptoms of acute pancreatitis (Uden et al, 1990).

The present study used the experimental model of cerulein-induced acute pancreatitis to monitor the generation of oxygen radicals by measuring the level of MDA (malondialdehyde), product of polyunsaturated fatty acid oxidation, which is an indirect parameter of the formation of lipid peroxides, and GSH and GSHpx as indicators of the antioxidant defense system. In addition, the therapeutic effects of pretreatment with small molecular antioxidants on these cerulein-induced pancreatic alterations in rats were

examined.

METHODS

Animal preparation and drug administration

Male Sprague-Dawley rats, 180~200 g, were fasted 16 hour before the experiment and allowed to drink tap water *ad libitum*. The rats were anesthetized with urethane (1.25 g/kg, sc), and polyethylene catheter (PE 50) was placed in the jugular vein. The animals were randomly allocated into six groups. Acute edematous pancreatitis was induced by intravenous infusion of cerulein at supramaximal dose of 10 μ g/kg/hour (1 ml/hour) during 3.5 hours in accordance with the method described by Lampel and Kern (1977). Control experiments were performed by administration of physiological saline instead of cerulein. Rebamipide was dissolved in 0.5% carboxymethyl cellulose (100 mg/kg, i.p.), while N-acetyl-cysteine (200 mg/kg, i.v.) and β -carotene (50 mg/kg, i.p.) were dissolved in soybean oil. The drugs were given 1 hour before the induction of acute pancreatitis. Allopurinol (20 mg/kg/hour) dissolved in saline was concomitantly infused with cerulein simultaneously.

Isolation of pancreatic tissue

After the end of experiment, blood was taken from abdominal aorta for serum amylase assay and pancreas was quickly removed, blotted dry, and weighed. Small pieces of pancreas were excised from the body portion for histological examination (haematoxylin and eosin stain). The remainder of each pancreas was divided into two portions. One portion of remainder pancreatic tissue was homogenized with a teflon pestle homogenizer with 4 volume of 10 mM Tris-HCl buffer (pH 7.4) and centrifuged at 7,000 xg for 15 min. The supernatant was collected and used for MDA concentration and GSHpx assays. The other portion of pancreas was homogenized with 4 vol of 5% 5-sulfosalicylic acid and centrifuged at 12,000 xg for 15 min, and supernatant was used for measuring GSH concentration.

Assay for amylase and protein

Serum amylase activity was determined by method of Bernfeld (1955). Protein content of pancreatic tis-

sue was assessed by the method of Lowry et al (1951), using bovine serum albumin as the standard.

Assay for GSH concentration

GSH concentration was assayed according to the method described by Griffith (1980). Phosphate buffer containing 0.3 mM NADPH, 0.6 mM 5,5'-dithiobis-2-nitrobenzoic acid, and pancreatic tissue homogenates are pipetted into each cuvette. The cuvettes are incubated at 25°C for 5 min, and the reaction started with glutathione reductase in a concentration of 0.0625 U/ml. The changes in absorbance were monitored spectrophotometrically at 412 nm, and exogenous GSH was used as a standard. Results were expressed as the total nmoles of GSH per g tissue.

Assay for MDA

MDA was measured by the method modified from Ohkawa et al's (1979), using 1,1,3,3-tetramethoxypropane as a standard. Briefly, 0.2 ml of tissue homogenates was added to 20% acetic acid, adjusted to pH 3.5, 0.4 ml of 8% sodium dodecyl sulfate, and 0.4 ml of 0.8% 2-thiobarbituric acid. The mixture was vortexed and then boiled for 60 min at 95°C. The colored product was cooled and centrifuged at 12,000 xg for 15 min. The supernatant was collected and optical density was read in spectrophotometer at 535 nm.

Assay for GSHpx

GSHpx activity was measured by the method of Kim et al (1996). Tissue homogenates were added to 900 μ l of potassium phosphate buffer (pH 7.0) containing 0.2 mM NADPH, 1 mM GSH, and glutathione reductase (1 EU/ml), and incubated at 25°C for 5 min. The reaction was started with 100 μ l of 2.5 mM H₂O₂ and the changes in absorbance were determined spectrometrically at 340 nm. Enzyme activity of GSHpx was calculated by measuring the amount of μ mol NADPH oxidized per min and by using a molar extinction coefficient of 1M NADPH at 340 nm, $6.3 \times 10^3 \text{ M}^{-1}\text{cm}^{-1}$.

Statistics

All data were expressed in mean \pm S.E.M. Overall significance was tested by ANOVA, and the significant level was set at $p < 0.05$.

RESULTS

Histological examination

Cerulein-induced acute pancreatitis was evident with the appearance of prominent interstitial edema and acinar vacuolization, but inflammatory infiltrate was scant (Fig. 1). N-Acetyl-cysteine attenuated pan-

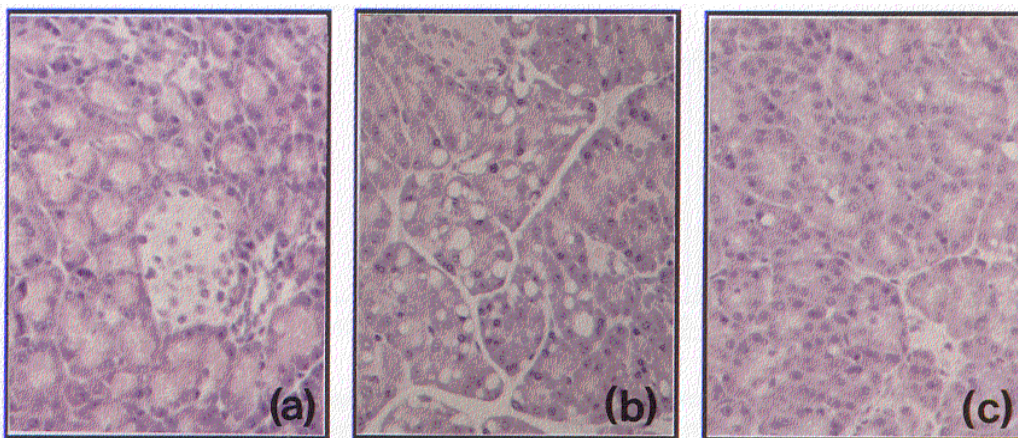


Fig. 1. Light photomicroscopy of the rat pancreas (H&E, $\times 200$). (a) Normal pancreas (b) Acute pancreatitis induced by cerulein ($10 \mu\text{g}/\text{kg}/\text{hr}$, for 3.5 hours) is evident with interstitial edema and acinar vacuolization. (c) N-Acetyl-cysteine pretreated pancreatic rats illustrate less interstitial edema and less acinar vacuolization.

creatic acinar vacuolization and edema induced by cerulein treatment. However, rebamipide, allopurinol, and β -carotene had little effect on cerulein-induced histological changes in pancreas.

Ratio of wet weight to dry weight of pancreas

The water content of pancreas of the rats treated with cerulein increased. The ratio of wet weight to dry weight of pancreas (%) of control rats was $0.312 \pm 0.013\%$ to 0.401 ± 0.03 at 3.5 hour after cerulein infusion (Fig. 2), but there was no significant difference between groups. This slight increase in the ratio of wet weight to dry weight of pancreas was attenuated by rebamipide, N-acetyl-cysteine, allopurinol, and β -carotene.

Serum amylase activity

The serum level of amylase, as a enzymatic marker representing the pancreatic cellular injury, increased significantly from a control level of 6843 ± 420 IU/L to 16400 ± 1012 IU/L ($p < 0.01$) in cerulein treatment (Fig. 3). N-acetyl-cysteine and β -carotene significantly reduced serum amylase levels increased by cerulein infusion. However, these antioxidants didn't completely reduce hyperamylasemia caused by cerulein infusion.

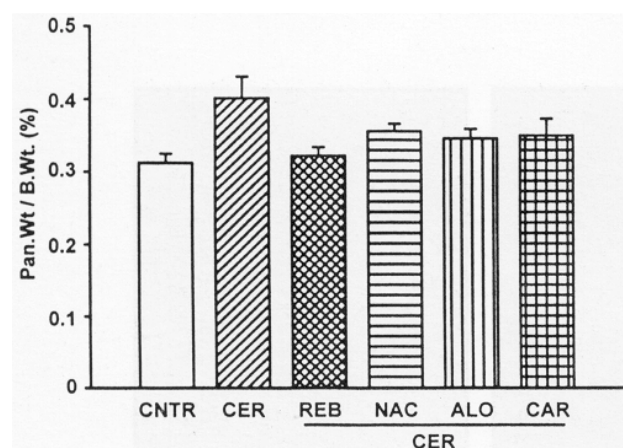


Fig. 2. Changes in pancreatic weight in cerulein-induced acute pancreatitis. Control (CNTR), cerulein (CER), rebamipide (REB), N-acetyl-cysteine (NAC), allopurinol (ALO), and β -carotene (CAR) were administered as described in methods.

GSH concentration

The changes in pancreatic tissue GSH concentration are shown in Fig. 4. GSH concentration markedly decreased from 0.991 ± 0.045 $\mu\text{mol/g}$ tissue to 0.509 ± 0.050 $\mu\text{mol/g}$ tissue in cerulein infusion ($p < 0.01$). The depletion of tissue GSH concentration by

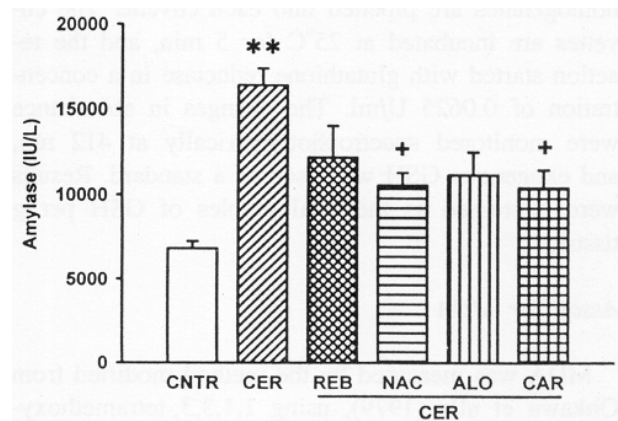


Fig. 3. Changes in serum amylase level in cerulein-induced acute pancreatitis. Control (CNTR), cerulein (CER), rebamipide (REB), N-acetyl-cysteine (NAC), allopurinol (ALO), and β -carotene (CAR) were administered as described in methods. $**p < 0.01$ vs control; $+p < 0.05$ vs cerulein alone

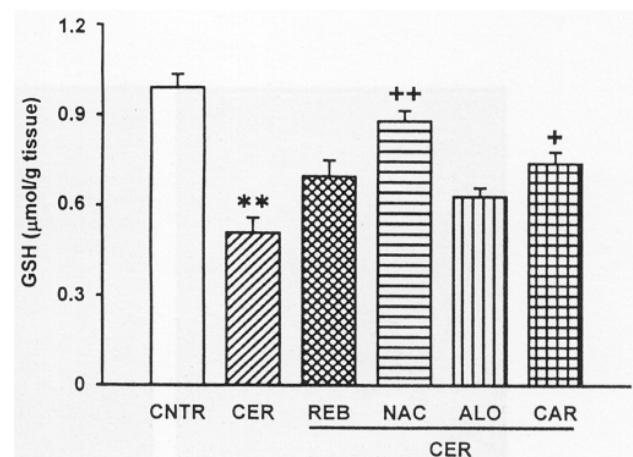


Fig. 4. Changes in pancreatic glutathione concentration in cerulein-induced acute pancreatitis. Control (CNTR), cerulein (CER), rebamipide (REB), N-acetyl-cysteine (NAC), allopurinol (ALO), and β -carotene (CAR) were administered as described in methods. $**p < 0.01$ vs control; $+p < 0.05$, $++p < 0.01$ vs cerulein alone

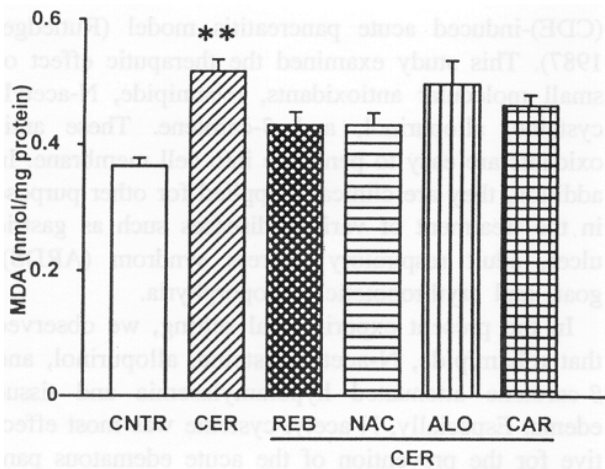


Fig. 5. Changes in pancreatic MDA concentration in cerulein-induced acute pancreatitis. Control (CNTR), cerulein (CER), rebamipide (REB), N-acetyl-cysteine (NAC), allopurinol (ALO), and β -carotene (CAR) were administered as described in methods. ** $p < 0.01$ vs control

cerulein treatment was ameliorated by N-acetyl-cysteine (from $0.509 \pm 0.050 \mu\text{mol/g}$ tissue to $0.880 \pm 0.035 \mu\text{mol/g}$ tissue, $p < 0.01$) and β -carotene (to $0.740 \pm 0.039 \mu\text{mol/g}$ tissue, $p < 0.05$). Rebamipide and allopurinol had little effect on GSH depletion caused by cerulein.

Lipid peroxidation

As shown in Fig. 5, a significant increase occurred in tissue MDA concentration after cerulein infusion. MDA concentration in cerulein treated group increased approximately 41% ($0.517 \pm 0.02 \text{ nmol/mg}$, $p < 0.01$) more than that in control rat ($0.366 \pm 0.013 \text{ nmol/mg}$). Rebamipide and N-acetyl-cysteine significantly decreased MDA concentration increased by cerulein, while allopurinol had no effect on cerulein-induced lipid peroxidation.

GSHpx activity

GSHpx activity of pancreas was not altered by cerulein infusion and antioxidant treatment (Fig. 6). The GSHpx activities of control, cerulein alone, cerulein with rebamipide, N-acetyl-cysteine, allopurinol, and β -carotene were $53.16 \pm 3.37 \text{ nmol/mg}$, $55.12 \pm 2.75 \text{ nmol/mg}$, $48.33 \pm 3.18 \text{ nmol/mg}$, and $45.24 \pm 2.19 \text{ nmol/mg}$, respectively.

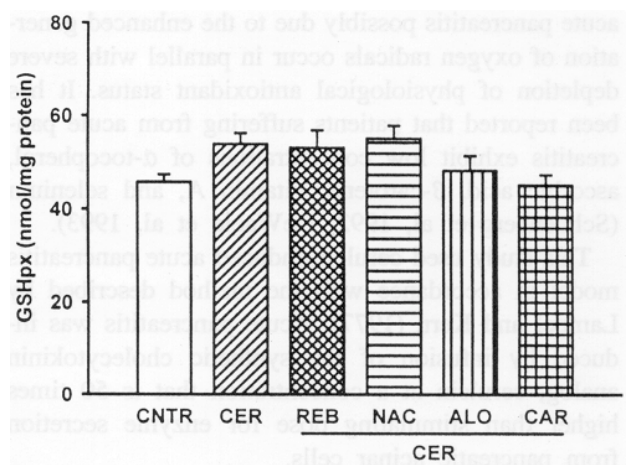


Fig. 6. Changes in pancreatic glutathione peroxidase in cerulein-induced acute pancreatitis. Control (CNTR), cerulein (CER), rebamipide (REB), N-acetyl-cysteine (NAC), allopurinol (ALO), and β -carotene (CAR) were administered as described in methods.

DISCUSSION

A growing evidence suggests that oxygen radicals are generated in acute pancreatitis at an early stage of disease, as in many other inflammatory diseases (Sanfey et al, 1984). Moreover, the indirect observations suggest that oxygen free radicals generated exaggerate pancreatic damage in human acute and chronic pancreatitis. However, the source of enhanced production of oxygen radicals still remains unclear. Antioxidants scavenge reactive oxygen species (O_2^- , H_2O_2 , $\cdot\text{OH}$, HOCl , ferryl, peroxy, and alkoxy) and thus prevent tissue damage which may be caused by excess production of reactive oxygen species (Halliwell, 1991). If cellular antioxidants are low, or the production of free radical species exceeds cellular antioxidant defense, oxidative stress is imposed on the cells. This leads to a disturbance in cellular homeostasis, including activation of the glutathione redox cycle, DNA damage, depletion of ATP, and peroxidation of membrane lipids. The lipid peroxidation eventually leads to increased membrane permeability and cell death (Sies, 1991).

Under physiological conditions, these cytotoxic oxygen radicals are eliminated by enzymatic and non-enzymatic antioxidants (Schoenberg et al, 1995). These cellular protections include endogenous antioxidants such as α -tocopherol, ascorbic acid, and β -carotene. In fact, increases in lipid peroxidation in patients with

acute pancreatitis possibly due to the enhanced generation of oxygen radicals occur in parallel with severe depletion of physiological antioxidant status. It has been reported that patients suffering from acute pancreatitis exhibit low concentrations of α -tocopherol, ascorbic acid, β -carotene, vitamin A, and selenium (Schoenberg et al, 1992, DeWaele et al, 1993).

This study used cerulein-induced acute pancreatitis model in accordance with the method described by Lampel and Kern (1977). Acute pancreatitis was induced by infusion of the synthetic cholecystokinin analog, cerulein at a concentration that is 50 times higher than stimulating dose for enzyme secretion from pancreatic acinar cells.

Since the histological picture of cerulein-induced acute pancreatitis resembles the early phase of acute edematous pancreatitis in humans, and it is easy to induce transient interstitial pancreatitis within the first hour (Alder et al, 1979), this model has been commonly used for human edematous pancreatitis. This study presents that both serum amylase level and MDA concentration in pancreatic tissue increased in cerulein-induced acute pancreatitis. In addition, we observed a marked decrease in pancreatic GSH content after cerulein treatment. These data are in agreement with others (Dabrowski & Chroiecko, 1990), and these results suggest an involvement of oxygen radicals at an early stage of acute pancreatitis. Excess lipid peroxide produced by a chain reaction of oxygen radicals can cause increased GSHpx activity and GSH consumption. It has been reported that the changes in GSHpx activity were similar to changes in the level of MDA (Nonaka A, 1989). Pancreatic MDA concentration increased at an early stage after the cerulein infusion. On the other hand, GSHpx activity tended to increase later from the basal level. In the present study, GSHpx activity changed little at 3.5 hours after the cerulein infusion.

Some researchers have tried to use the antioxidants for the therapeutic purpose by using experimental model of acute pancreatitis. Sanfey et al (1984, 1985) demonstrated that SOD and catalase, added to the perfusate, attenuated tissue damage and hyperamylasemia in all forms of pancreatitis. CV-3611, synthetic ascorbic acid derivative, ameliorated acinar cell injury and tissue necrosis, which was not prevented by SOD and catalase (Nonaka et al, 1991). It has been reported that allopurinol and DMSO reduced pancreatic edema, but they did not alter other features shown in choline-deficient ethionine supplemented

(CDE)-induced acute pancreatitis model (Rutledge, 1987). This study examined the therapeutic effect of small molecular antioxidants, rebamipide, N-acetylcysteine, allopurinol, and β -carotene. These antioxidants are easy to penetrate into cell membrane. In addition, they are clinically applied for other purpose in the treatment of various diseases such as gastric ulcer, adult respiratory distress syndrome (ARDS), goat, and erythropoietic protoporphyria.

In the present experimental setting, we observed that rebamipide, N-acetylcysteine, allopurinol, and β -carotene attenuated hyperamylasemia and tissue edema. Especially, N-acetylcysteine was most effective for the prevention of the acute edematous pancreatitis caused by the administration of supramaximal dose of cerulein, by decreasing pancreatic edema, MDA concentration, hyperamylasemia, GSH depletion, and morphological severity.

Although we could not evaluate the source of oxygen free radical, we confirmed that oxygen-derived free radicals play an important role in the initiation of cerulein-induced acute pancreatitis. Also based on our studies, we suggest that attempts to scavenge oxygen free radicals or interference with their generation might be clinically beneficial in the mitigation of severity of acute pancreatitis. Further studies should be performed to determine the source of oxygen radicals and to apply these small molecular antioxidants in more severe forms of experimental pancreatitis. These efforts will lead us to a more effective therapy for pancreatitis.

In summary, we suggest that oxygen free radicals mediate an important step in initiation of cerulein-induced acute pancreatitis. Increase in MDA and depletion of GSH after cerulein treatment seem to be important in pancreatic tissue injury. N-Acetylcysteine is an effective antioxidant which ameliorates hyperamylasemia and tissue damage in cerulein-induced acute pancreatitis.

ACKNOWLEDGEMENT

The study was supported by the Basic Medical Research Fund from the Ministry of Education, Republic of Korea, 1997.

REFERENCES

Alder G, Hupp T, Kern HF. Course and spontaneous

- regression of acute pancreatitis in the rat. *Virchows Arch A Pathol Anat Histol* 382: 31–47, 1979
- Adler G, Kern HF. Fine structure and biochemical studies in human acute pancreatitis. In: Gyr KE, Singer MV, Sarles H eds, *Pancreatitis*. Excerpta Medica, Amsterdam: p37–42, 1984
- Alessandro B. Microsurgical evaluation of experimental pancreatitis after allopurinol: A secretory serological and morphological study. *Pancreas* 11: 55–62, 1995
- Bernard GR. Potential of N-acetyl-cysteine as treatment: for the adult respiratory distress syndrome. *Eur Resp J* 3(suppl 11): 4965–4985, 1990
- Bernfeld P. Amylase α and β . In *methods in enzymology* vol 1, New York: Academic press, p149–150, 1955
- Bulkley GB. The role of oxygen free radicals in human disease process. *Surgery* 94: 407–411, 1983
- Dabrowski A, Chwiecko M. Oxygen radicals mediate depletion of pancreatic sulfhydryl compounds in rats with cerulein-induced acute pancreatitis. *Digestion* 47: 15–19, 1990
- Dabrowski A, Gabryelewicz A, Wereszczyńska-Siemiątkowska U. Oxygen-derived free radicals in cerulein-induced acute pancreatitis. *Scand J Gastroenterol* 23: 1245–1249, 1988
- Dewaele LB, Vierendeels LT, Willems G. Vitamin status in patients with acute pancreatitis. *Clin Nutr* 11: 83–86, 1992
- Freeman BA, Crapo JD. Biology of defense: Free radicals and tissue injury. *Lab Invest* 47: 412–426, 1982
- Griffith OW. *Anal Biochem* 106: 207, 1980
- Halliwell B. Reactive oxygen species in living systems. Source, Biochemistry and Role in human disease. *Am J Med* 91(suppl 3c): 3C–14S–22S, 1991
- Kim H, Lee YH, Kim SI. Protective effect of panoxylthiol against tumorigenesis in mouse skin. *Kor Biochem J* 23: 175–184, 1990
- Lampel M, Kern HF. Acute interstitial pancreatitis in the rat induced by excess dose of a pancreatic secretagogue. *Virchows Arch(A)* 373: 97–117, 1977
- Lowry OM. *J Biol Chem* 193: 209, 1951
- Moldeus P, Cotgreave JA, Berggren M. Lung protection by a thiol-containing antioxidant: N-acetyl-cysteine. *Respiration* 50(suppl 1): 31–42, 1986
- Nonaka A, Manabe T, Tamura K. Changes of xanthine oxidase, lipid peroxide and superoxide dismutase in mouse acute pancreatitis. *Digestion* 43: 41–46, 1989
- Nonaka A, Manabe T, Toke T. Effect of a new synthetic ascorbic acid derivative as a free radical scavenger on the development of acute pancreatitis in mice. *Gut* 32: 520–532, 1991
- Ohkawa H, Ohishi N, Yagi K. Assay of lipid peroxides in animal tissues by thiobarbituric acid reaction. *Anal Biochem* 351, 1979
- Rutledge PL, Saluja AK, Powers RE, Steer ML. Role of oxygen-derived free radicals in diet-induced hemorrhage pancreatitis in mice. *Gastroenterology* 93: 41–49, 1987
- Sanfey H, Bulkley GB, Cameron JL. The pathogenesis of acute pancreatitis: The source and role of oxygen-derived free radicals in three different experimental models. *Ann Surg* 201: 633–639, 1985
- Sanfey H, Bulkley GB, Cameron JL. The role of oxygen derived free radicals in the pathogenesis of acute pancreatitis. *Ann Surg* 200: 405–413, 1984
- Schoenberg MH, Büchler M, Beger HG. The role of oxygen radicals in experimental acute pancreatitis. *Free Radic Biol Med* 12: 515–522, 1992
- Sies H. Oxidative stress: from basic research to clinical application. *Am J Med* 91(suppl 3c): 31–38, 1991
- Tsuda H, Uehara N, Iwahori Y, Asamoto M, Ligo M, Nagao M, Matsamoto K, Ito M, Hirono I. Chemopreventive effects of β -carotene, α -tocopherol, and five naturally occurring antioxidants on initiation of hepatocarcinogenesis by 2-amino-3-methylimidazo[4,5-f]quinoline the rat. *Jpn J Cancer Res* 85: 1214–1219, 1994
- Uden S, Bilton D, Guyan PM, Kay PM, Braganza JM. Rationale for antioxidant therapy in pancreatitis and cystic fibrosis. *Adv Exp Med Biol* 264: 555–572, 1990
- Yamasaki K, Ishiyama H, Imaizumi T, Kanbe T, Yabuchi Y. Effect of OPC-12759, a novel antiulcer agent, on chronic and acute experimental gastric ulcer, and gastric secretion in rats. *Jpn J Pharmacol* 49: 441, 1989
- Yoshikawa T, Naito Y, Tanigawa T, Kondo M. Free radical scavenging activity of novel antiulcer agent rebamipide studied by electron spin resonance, *Arzneim-Forsch. Drug Res* 43: 363, 1993