

정위적 생검으로 확진이 되지 않았던 예의 분석

,¹ BK21 ,² ,³ ,⁴
,⁵

김경현¹ · 박용숙⁴ · 정현호¹ · 장종희^{1,2,3} · 장진우^{1,2,3} · 박용구^{1,2,3} · 정상섭⁵

Analysis of the Non-diagnostic Results after Stereotactic Biopsy

Kyung Hyun Kim, MD¹, Yong Sook Park, MD⁴, Hyun Ho Jung, MD¹, Jong Hee Chang, MD, PhD^{1,2,3},
Jin Woo Chang, MD, PhD^{1,2,3}, Yong Gou Park, MD, PhD^{1,2,3}, Sang Sup Chung, MD, PhD⁵

¹Department of Neurosurgery, ²Brain Korea 21 Project for Medical Science and ³Brain Research Institute,
Yonsei University College of Medicine, Seoul, Korea

⁴Department of Neurosurgery, Kosin University College of Medicine, Gospel Hospital, Busan, Korea

⁵Department of Neurosurgery, Bundang CHA Hospital, CHA Medical University, Seongnam, Korea

Objective: Although stereotactic brain biopsy has played an important role in the diagnosis and management of brain lesions, there is a significant number of patients in whom a histologic diagnosis is not achieved. The non - diagnostic result of stereotactic biopsy poses a management dilemma. The goal of this study was to analyze the non - diagnostic results after stereotactic biopsy, subsequent management, progress and final diagnosis.

Methods: The authors reviewed the clinical and radiological records of 158 patients who underwent stereotactic brain biopsies using Leksell stereotactic frame. We included 138 patients who were followed more than 6 months in this study.

Results: The results were diagnostic in 118 cases and the overall diagnostic yield of the procedure was 85.6%. A definite histological diagnosis was not made in 20 patients: gliosis in 10, normal white matter in 5, necrosis in 2, infiltration of inflammatory cell in 2, and insufficient material in 1. The subsequent managements, progress and their final diagnoses were described.

Conclusion: Stereotactic biopsy has evolved as a powerful and safe tool to provide tissue diagnoses with minimal disruption of normal functioning brain. Multiple serial biopsy, intraoperative histological diagnosis, and updated imaging - guided biopsy should be tried to minimize the sampling error. Clinical and radiological follow - up are essential for further diagnosis and management in non - diagnostic cases.

KEY WORDS: Diagnostic accuracy · Diagnostic yield · Intracranial lesion · Non - diagnostic result · Stereotactic biopsy.

서 론

10~20

(stereotactic biopsy)

1)2)6)9 - 11)13)15)16)19)23)

Address for correspondence: Jong Hee Chang, MD, PhD,
Department of Neurosurgery, Yonsei University College of Medicine, Seoul 120 - 752, Korea
Tel: +82 - 2 - 2228 - 2162, Fax: +82 - 2 - 393 - 9979
E - mail: changjh@yumc.yonsei.ac.kr

대상 및 방법

1997 11 2003 2 Leksell
stereotactic system(Elekta AB, Stockholm, Sweden)
(intrinsic lesion)

158 6
138 . , ,

Leksell stereotactic system MRI
(stereotactic frame)
(target point,
end point) T1 - MR

T2 - MR

K - Neuroplan®
(sulcus)
(entry point) , 3
(trajectory)

(Fig. 1).
(sampling error) 가

MR
가
side - coring (Sedan -
type biopsy needle)

CT

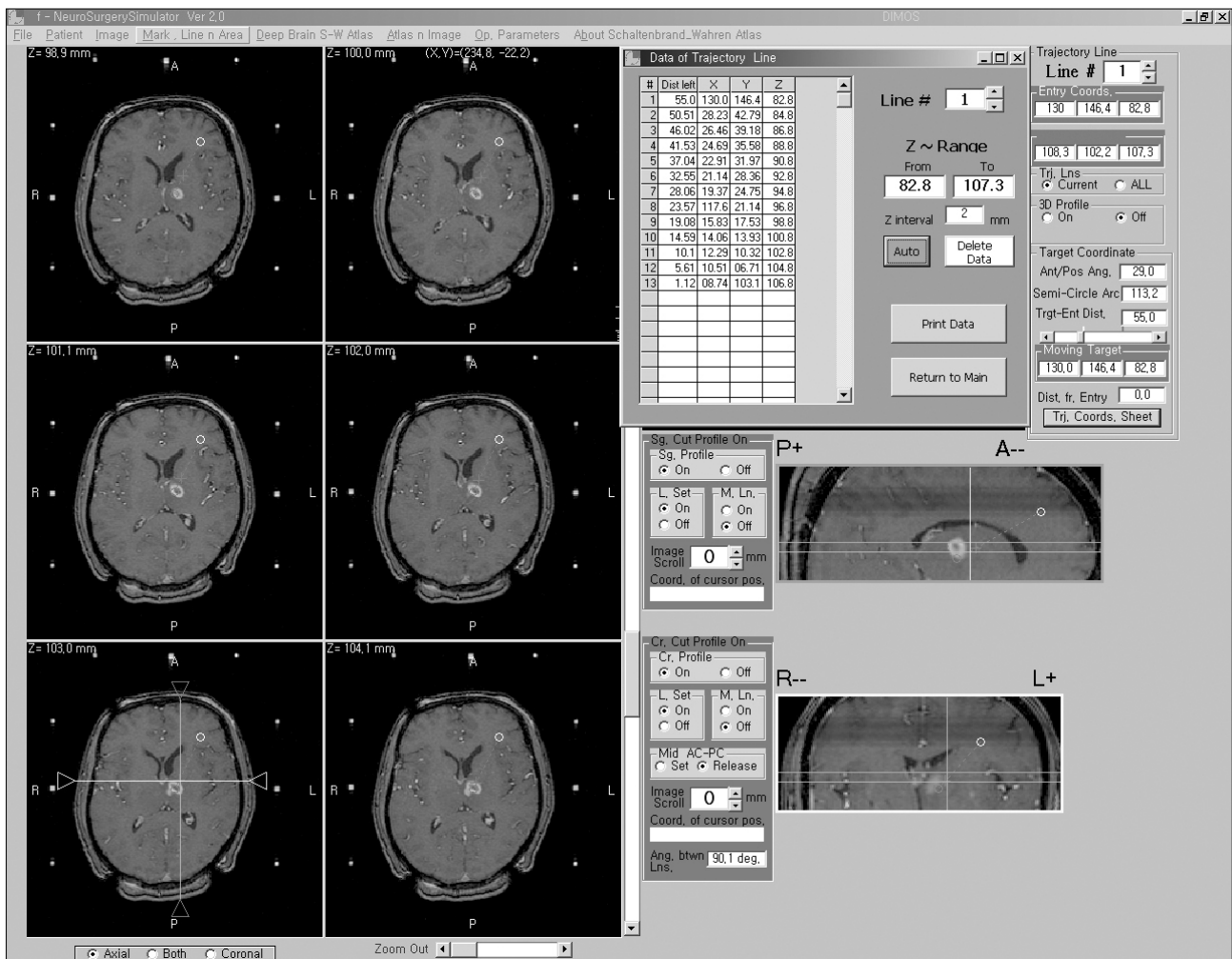


Fig. 1. Planning for stereotactic biopsy using K-Neuroplan®.

Table 1. Histopathologic results of stereotactic biopsy

Pathology	No. of patients (%)
Neoplastic	110 (79.7%)
Pilocytic astrocytoma	1
Diffuse astrocytoma	20
Oligodendroglioma	1
Anaplastic astrocytoma	17
Glioblastoma	29
Gliomatosis cerebri	2
Lymphoma	25
Germinoma	4
Choriocarcinoma	1
Mixed germ cell tumor	1
PNET*	1
Medulloblastoma	2
Pineocytoma	1
Central neurocytoma	1
Metastatic tumor	4
Non-neoplastic	8 (5.8%)
PML**	4
Radiation necrosis	3
Abscess	1
Non-diagnostic	20 (14.5%)
Gliosis	10
Normal white matter	5
Necrosis	2
Inflammatory cell infiltration	2
Insufficient material	1
Total	138 (100%)

*PNET : primitive neuroectodermal tumor

**PML : progressive mul-tifocal leukoencephalopathy

(targeting error) .
 138
 20 (14.6%) , (gliosis)가 10 (50%),
 5 (25%), (necrosis)
 (infiltration of inflammatory cell) 2 (10%),
 (insufficient material)
 가 1 (5%) . ,
 Table 2 .
 가 7 (35%),
 (glioblastoma) 4 (20%), (low
 grade astrocytoma) 2 (10%),
 (pilocytic astrocytoma), (malignant lympho-
 ma), (germinoma), (Lan-
 gerhans 'cell histiocytosis) 가 1 (5%)
 3 (15%)
 (Figs. 2 and 3).

고 찰

MRI (functional imaging)

결 과

, 24 , 21) ,
 가
 , CT MRI 10~40%
 1)2)6)9 - 11)13)15)16)19)23)
 138
 118 (85.6%) ,
 Table 1 .
 34.3(8.1~87.4) .
 52 (37.7%), 20 (14.5%), 11 , 가
 (8.0%), 8 (5.8%), 7 (5.1%), ,
 5 (3.6%), 4 (2.9%), ,
 3 (2.2%) , 가 25 (18.1%)
 CT ,

Table 2. Subsequent management, progress and final diagnosis of non-diagnostic results after stereotactic biopsy*

Stereotactic diagnosis & subsequent management	Follow-up	Final diagnosis	No. of patients (%)
Gliosis			10 (50%)
Conservative	Regressed	Inflammatory lesion	3
Conservative	Regressed	Encephalitis	2
Conservative	Growing	Low grade glioma	2
Conservative & angiography	Regressed	Vasculitis	1
Repeated biopsy		Langerhans' cell histiocytosis	1
Conservative	No change for 9 months	Unknown	1
Normal white matter			5 (25%)
GKS	Regressed	Pilocytic astrocytoma	1
Conservative	Growing and then repeated biopsy	Glioblastoma	1
RTx	Growing and then repeated biopsy	Glioblastoma	1
Conservative	No change for 12 & 24 months	Unknown	2
Necrosis			2 (10%)
RTx	Growing and then open removal	Glioblastoma	2
Inflammatory cell infiltration			2 (10%)
Conservative	Regressed	Vasculitis	1
RTx & CTx	PR	Lymphoma	1
Insufficient material			1 (5%)
RTx & CTx	CR	Germinoma	1
Total			20 (100%)

*conservative : conservative management, regressed : regressed lesion on follow-up MR images, growing : tumor growing on follow-up MR images, no change : no change of lesion on follow-up MR images, GKS : Gamma Knife radiosurgery, RTx : radiation therapy, CTx : chemotherapy, PR : partial remission, CR : complete remission

Fig. 2. A 75 year-old female with a periventricular lesion. A : Initial T1-weighted MR image shows a well-enhanced and necrotic lesion. B : Immediately postoperative CT shows well targeted biopsy, but the pathological result of the 1st stereotactic biopsy was normal white matter. C : Follow-up T1-weighted MR image (1 month after 1st biopsy) shows growing of the lesion. Repeated stereotactic biopsy was performed and the final diagnosis was glioblastoma.

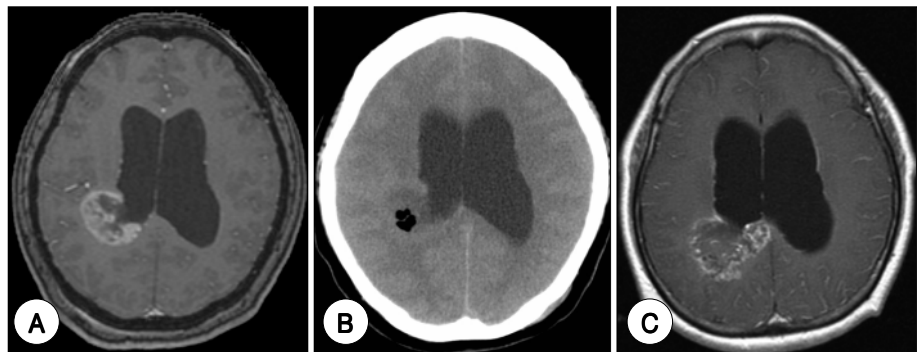
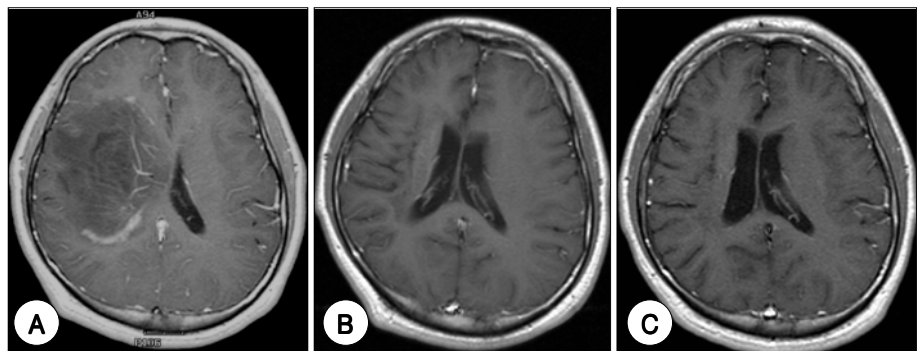


Fig. 3. A 22 year-old male with a periventricular and periinsular lesion. A : Initial T1-weighted MR image shows a diffuse, large, and partially enhanced lesion that has mass effect. The pathological result of stereotactic biopsy was gliosis. B : Follow-up T1-weighted MR image (13 months after 1st biopsy) shows a shrunk lesion. C : Follow-up T1-weighted MR image (40 months after 1st biopsy) shows a large area of leukomalacia and no evidence of active disease. At last, this patient was clinically diagnosed as encephalitis.



가 , 가 가 가 .
 , 가 가 가 .
 , 4)8)9)11)12)15)23) , 80~97%
 , 1)4)8)10)
 , (choriocarcinoma), ,
 , , 가 ,
 (brain - pial interface) 가 ,
 , 가 15) 가
 , 가 (oligodendroglioma), (ependymoma),
 , (primitive neuroectodermal tumor),
 , 가 , (germ cell
 tumor) 가
 , (diag-
 nostic yield) (diagnostic accuracy) 2가 가 1~2 가 .
 가 (targeting error),
 , 가 , 가 ,
 (non - diagnostic) 가 가
 , 1)3 - 5)7)8)10 - 12)14)15)17)18)20)22)23)
 , 가 ,
 . CT 가 ,
 80~99% , (cytology)가 5)
 85.4% MRI
 , 가 (frozen section)
 가 (MR spectroscopy),
 , MRI(perfusion MRI),
 가 (positron emission tomography ; PET)
 , 1)4)8 - 12)15)17)18)20)

- tumors. *Semin Surg Oncol* 14:13-25, 1998
16. Lunsford LD, Martinez AJ: *Stereotactic exploration of the brain in the era of computed tomography. Surg Neurol* 22:222-230, 1984
 17. Kwiek SJ, Bierzynska-Macyszyn G, Wlaszczuk P, Bazowski P, Maciejewski B, Tarnawski R, et al: *Non-neoplastic, degenerative brain pathologies and fibroses diagnosed on the basis of ultra-small samples obtained by stereotactic biopsy. Folia Neuropathol* 42:197-201, 2004
 18. McGirt MJ, Villavicencio AT, Bulsara KR, Friedman AH: *MRI-guided stereotactic biopsy in the diagnosis of glioma: comparison of biopsy and surgical resection specimen. Surg Neurol* 59:277-282, 2003
 19. McGirt MJ, Woodworth GF, Coon AL, Frazier JM, Amundson E, Garonzik I, et al: *Independent predictors of morbidity after image-guided stereotactic brain biopsy: a risk assessment of 270 cases. J Neurosurg* 102:897-901, 2005
 20. Ranjan A, Rajshekhar V, Joseph T, Chandy MJ, Chandi SM: *Non-diagnostic CT-guided stereotactic biopsies in a series of 407 cases-influence of CT morphology and operator experience. J Neurosurg* 79:839-844, 1993
 21. Vaquero J, Martinez R, Manrique M: *Stereotactic biopsy for brain tumors: is it always necessary? Surg Neurol* 53:432-437, 2000
 22. Warnick RE, Longmore LM, Paul CA, Bode LA: *Postoperative management of patients after stereotactic biopsy: results of a survey of the AANS/CNS section on tumors and a single institution study. J Neurooncol* 62:289-296, 2003
 23. Yu X, Liu Z, Tian Zengmin, Li S, Huang H, Xiu B, et al: *Stereotactic biopsy for intracranial space-occupying lesions: clinical analysis of 550 cases. Stereotact Funct Neurosurg* 75:103-108, 2000