

=		=	
	16 ( : 9 , : 7 , : 39.3 ) 26		14.7
	84.6%		
	SRK/T		65.4%
20/40	, 23.1%	20/25	
	, 20/40	69.2%	100% 가
20/25	3.8%	80.8%	가
	- 15.85D ( - 10.25 - 23D)	50%	1
	100%		2
		42.3%	1 (3.8%)
	22 YAG		
가	가		( 41:
916~922, 2000).			

= Abstract =

### The Clinical Results of Clear Lens Extraction with Posterior Chamber Intraocular Lens Implantation for the Correction of High Myopia

Hyun Dong Lee, M.D., Dong Wook Lee, M.D.,  
 Young Ghee Lee, M.D., Eung Kweon Kim, M.D.

< : 1999 11 1 , : 2000 3 13 >

Address reprint requests to Young Ghee Lee, M.D.  
 The Institute of Vision Research, Department of Ophthalmology, College of Medicine, Yonsei University, #134 Shinchon-dong, Sodaemun-ku, Seoul, 120-140, Korea  
 Tel : 82-2-361-8538, Fax : 82-2-312-0541

\* 1999 4 16 82

We retrospectively studied 26 eyes of 16 patients (male : 9 patients, female : 7 patients, mean age: 39.3 years) who received clear lens extraction by phacoemulsification and low-power posterior chamber intraocular lens implantation. To investigate the effectiveness of clear lens extraction, visual acuity, refractive results, and intraoperative and postoperative complications were analyzed. The mean follow-up was 14.7 months.

For reasons of lattice degeneration, retinal tear, or hole, we performed argon laser photocoagulation before clear lens extraction in 84.6% of patients. The IOL power was calculated using the SRK/T formula. Uncorrected visual acuity improved in all cases, with 65.4% of eyes achieving 20/40 or better and 23.1%, 20/25 or better. Corrected visual acuity improved in all cases, the percentage of eyes achieving corrected visual acuity of 20/40 or better increased from 69.2% preoperatively to 100% postoperatively and the percentage of 20/25 or better, from 3.8% to 80.8%. The mean postoperative spherical equivalent was -15.85D ( - 10.25 to - 23D ), 50% of eyes were within 1.0D of the goal diopter and 100% were within 2.0D of the goal diopter. No intraoperative complications occurred. During the follow-up, 42.3% of eyes developed mild posterior capsule opacification and 1 eye (3.8%) received a YAG laser posterior capsulotomy 22 months postoperatively. No retinal tear, retinal detachment, or cystoid macular edema was observed.

Clear lens extraction with low-power IOL implantation was effective for the correction of high myopia but additive cases and longer follow-up periods are needed to fully assess the complication (J Korean Ophthalmol Soc 41:916~922, 2000).

Key Words : Clear lens extraction, High myopia

가

1890 Fukala

1) 가

가 가 2-4),

1997 5 1999 1

16 ( : 9 , : 7 ) 26  
39.3 (27~51 )

10

5) (Table 1), 가



out pressure)

21

360

11

20/40

,

가

65.4%

20/25

24 (92.3%)

Table 2. Comparison between preoperative and postoperative visual acuity

V/A	corrected		uncorrected
	Preop.(N)	Postop.(N)	Postop.(N)
20/20 ~	0	11	0
20/25 ~ 20/22	1	10	6
20/40 ~ 20/28	17	5	11
20/125 ~ 20/50	8	0	9
~ 20/200	0	0	0

2  
20/40

(Fig. 1).  
69.2%

100% 가 , 20/25

3.8% 80.8% 가

(Table 2).

- 0.50D 가 가

가

- 0.76D . 50%

1 , 100%

2

(Table 3)

- 0.97

( - 2.63 + 0.75 )

(Table 4).

Table 3. The differences between goal diopter and postoperative spherical equivalent

the difference(D)*	No.	%
2 ~ 1.51	3	11.5
1.5 ~ 1.01	2	7.7
1 ~ 0.51	3	11.5
0.5 ~ 0	3	11.5
0 ~ - 0.5	3	11.5
- 0.51 ~ - 1	4	15.4
- 1.01 ~ - 1.5	6	23.1
- 1.51 ~ - 2	2	7.7

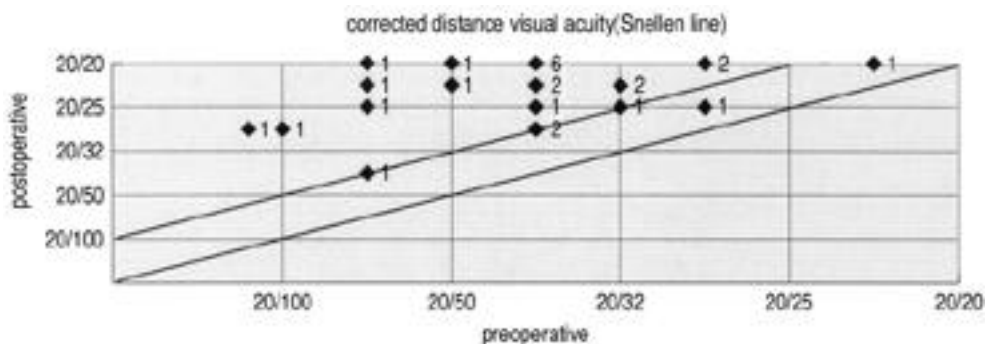
Table 4. Final results of postoperative spherical equivalent

Range(D)	No.	%
1 ~ 0.1	5	19.2
0 ~ - 0.9	7	26.9
- 1 ~ - 1.9	10	38.5
- 2 ~ - 2.9	4	15.4

\* postoperative spherical equivalent minus goal diopter

# mean difference = - 0.21 ± 1.12D(minor myopic shift)

\* mean postoperative spherical equivalent = - 0.97 ± 1.04D



\* Numbers next to triangles refer to number of patients

Figure 1. Scattergram of preoperative versus postoperative corrected visual acuity

가 .

10 가 ( , 가 0.3

, , mm 5 5.14,15)

, 가 , SRK SRK/T

) . 28.4mm

- 8 가 28.4mm

6) SRK/T

7- 16,17) 18) 19)

9) 가 SRK/T

(LASIK) - 6 - 12 가 가 5,20)

10,11) - 0.50 - 1.00

가 가

. Colin

가

( -0.50 가 )

12)

가

50%, 2

20

100%

1

13)

21) (85%)

가

1

46.2%

Colin

5)

(63%), Jimenez-Alfaro

20)

(76.91%)

가

42.3%

가

(3.8%)

22

YAG

, 1

5).

10

5,20)

가

20/40

가

Colin 5)

65.4%

(31%),

(7%),

(47%),

(39%)

가가

가

가

20) 가가 1 6 2 Barraquer 가<sup>4)</sup>  
 25%  
 가  
 가 Barraquer  
 4) 165 ( )<sup>27)</sup>  
 1980 1990  
 7.3%  
 30 가 가 84.6%  
 2.5 가  
 가 YAG  
 가 가  
 YAG  
 가 가 가

## REFERENCES

가<sup>4, 5, 22)</sup>  
 Colin Robinet<sup>5)</sup> - 12  
 52  
 4  
 - 20 30  
 18 1 (1.9%)가  
 23) Schinz Schutte<sup>24)</sup> 803  
 가  
 가  
 Barraquer 가<sup>4)</sup> 75%, Sethi 가<sup>25)</sup> 88%, Free-  
 man 가<sup>26)</sup> 80%  
 가  
 Colin Robinet<sup>5)</sup>

- 1) Rodriguez A, Gutierrez E, Alvira G : Compli - cations of clear lens extraction in axial myopia. Arch Ophthalmol 105:1522-1523, 1987.
- 2) Coonan P, Fung WE, Webster RG Jr, et al : The incidence of retinal detachment following extracapsular cataract extraction; a ten-year study. Ophthalmol 92:1096-1101, 1985.
- 3) Nielen NE, Naeser K : Epidemiology of retinal detachment following extracapsular cataract extraction: a follow-up study with an analysis of risk factors. J Cataract Refract Surg 19:675-680, 1993.
- 4) Barraquer C, Cavelier C, Mejia LF : Incidence of retinal detachment following clear-lens extraction in myopic patients; retrospective analysis. Arch Ophthalmol 112:336-339, 1994.
- 5) Colin J, Robinet A : Clear lensectomy and implantation of low-power posterior chamber intraocular lens for the correction of high myopia. Ophthalmol 101:107-112, 1994.
- 6) Waring GO 3rd, Lynn MJ, Nizam A, Kutner MH, Cowden JW, Culbertson W, Laibson PR,

- McDonald MB, Nelson JD, Obstbaum SA, et al : Results of the prospective evaluation of radial keratotomy(PERK) study five years after surgery. *Ophthalmol* 98:1164-1176, 1991.
- 7) Kremer I, Kaplan A, Novikov I, Blumenthal M : Patterns of late corneal scarring after photorefractive keratectomy in high and severe myopia. *Ophthalmol* 106:467-473, 1999.
- 8) Vorotnikova EK, Kourenkov VV, Polunin GS : Retreatment of regression after photorefractive keratectomy for myopia. *J Refract Surg* 14: S197-198, 1998.
- 9) Buratto L, Ferrari M : Photorefractive keratectomy for myopia from 6.00D to 10.00D. *Refract Corneal Surg* 9:S34-36, 1993.
- 10) Perez-Santonja JJ, Bellot J, Claramonte P, et al : Laser in situ keratomileusis to correct high myopia. *J Cataract Refract Surg* 23:372-385, 1997.
- 11) Guell JL, Muller A : Laser in situ keratomileusis(LASIK) for myopia from -7 to -18 diopters. *J Refract Surg* 12:S222-S228, 1996.
- 12) Colin J, Mimouni F, Robinet A, et al : The surgical treatment of high myopia: comparison of epikeratoplasty, keratomileusis and minus power anterior chamber lenses. *Refract Corneal Surg* 6:245-251, 1990.
- 13) Perez-Santonja JJ, Iradier MT, Benitez del Castillo JM, et al : Chronic subclinical inflammation in phakic eyes with intraocular lenses to correct myopia. *J Cataract Refract Surg* 22:183-187, 1996.
- 14) , : (clear lens extraction) . 37:63-69, 1996.
- 15) Lyle WA, Jin GJC : Phacoemulsification with intraocular lens implantation in high myopia. *J Cataract Refract Surg* 22:238-242, 1996.
- 16) Retzlaff JA, Sanders DR, Kraff MC : Development of the SRK/T intraocular lens implant power calculation formula. *J Cataract Refract Surg* 16:333-340 ; correction p 528, 1990.
- 17) Sanders DR, Retzlaff JA, Kraff MC, et al : Comparison of the SRK/T formula and other theoretical and regression formulas. *J Cataract Refract Surg* 16:341-346, 1990.
- 18) , , : 40:424-429, 1999.
- 19) , : 39:2635-2638, 1998.
- 20) Jimenez-Alfaro I, Miguelez S, Bueno JL, Puy P : Clear lens extraction and implantation of negative-power posterior chamber intraocular lenses to correct extreme myopia. *J Cataract Refract Surg* 24:1310-1316, 1998.
- 21) , , : 40:833-839, 1999.
- 22) Verzella F : Microsurgery of the lens in high myopia for optical purposes. *Cataract* 1:8-12, 1984.
- 23) Colin J, Robinet A : Clear lensectomy and implantation of low-power posterior chamber intraocular lens for the correction of high myopia. A four-year follow-up. *Ophthalmol* 104:73-78, 1997.
- 24) Schinz H, Schutte E : Aphakiemotoriorate bei myopen Augen. *Fortschr Ophthalmol* 88:142-147, 1991.
- 25) Sethi SK, Howard R, Milewski SA, Shelton P : Pseudophakic retinal detachments. *J Ocular Ther Surg* 2:180-181, 1983.
- 26) Freeman HM, Dobbie JG, Friedman MW, et al : Pseudophakic retinal detachment. *Mod Probl Ophthalmol* 20:345-353, 1979.
- 27) Zweng HC, Little HL, Hammond AH : Complications of argon laser photocoagulation. *Trans Am Acad Ophthalmol Otolaryngol* 78:OP194-OP204, 1974.