
Three Cases of Spontaneous Basilar Artery Dissection

Department of Neurology, Department of Diagnostic Radiology*, Yonsei University College of Medicine,
Department of Neurology, University of Ulsan, Asan Medical Center**, Seoul, Korea

Kyung Yul Lee, MD; Soo Bin Yim, MD; Sun Uck Kwon, MD**; Chong Kyu Chu, MD;
Ji Hoe Heo, MD; Dong Ik Kim, MD*; Jong Sung Kim, MD****

Spontaneous basilar artery dissection without vertebral artery involvement is a very rare clinical entity. We report three young patients who developed unilateral (cases 1 and 3) or bilateral (case 2) pontine infarction that produced hemiparesis and quadriparesis, respectively. The patients did not have conventional vascular risk factors or a history of trauma. The brain MRI and angiography findings were consistent with basilar artery dissection. We conclude that a possibility of basilar artery dissection should be considered when young patients with brainstem infarction are encountered even when there is no history of head trauma.

(Korean Journal of Stroke 2000;2(2): 207~211)

Key Words : Dissection, Cerebral angiography, Basilar artery

1
22 가 2
2 ,
[1,2] 가
[3-5]. 3 가
MRI,
3
(tissue plasminogen activator)

.....

388-1
TEL : 82-2-2224-34442
FAX : 82-2-2-474-4691
E-mail : jongskim@www.amc.seoul.kr

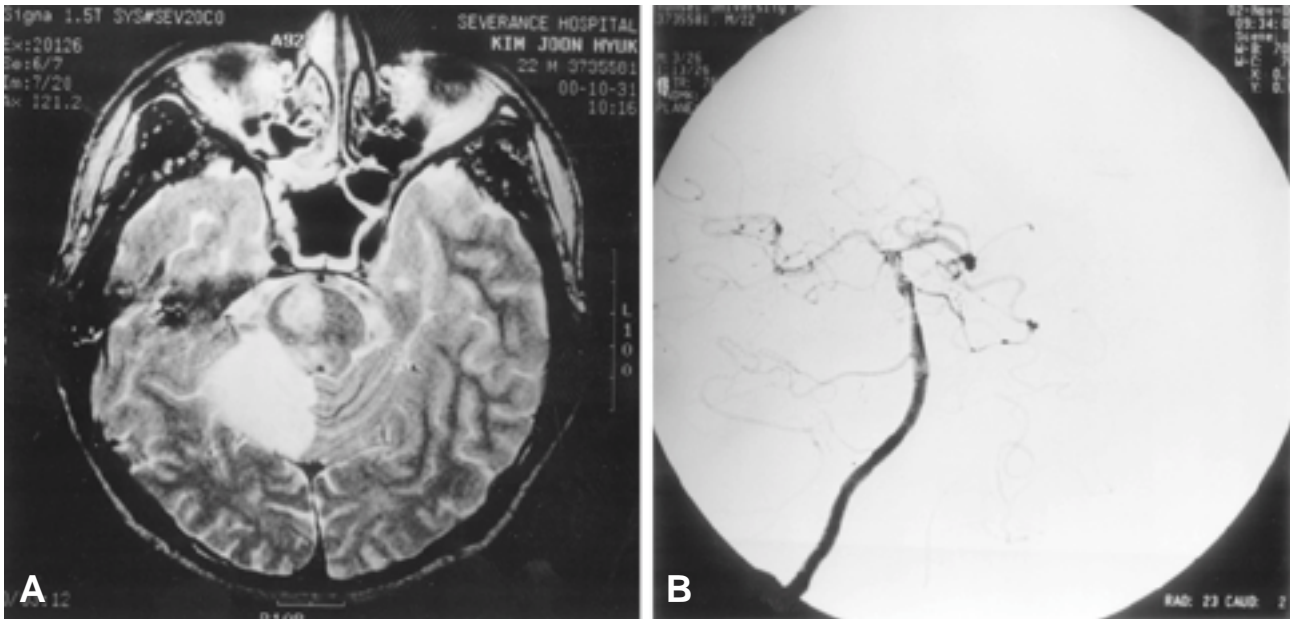


Figure 1. (A) T2 weighted brain MRI shows acute infarction of the right pons and cerebellum. (B) Vertebral angiography (oblique view) shows irregular stenosis and intimal flap of the basilar artery.

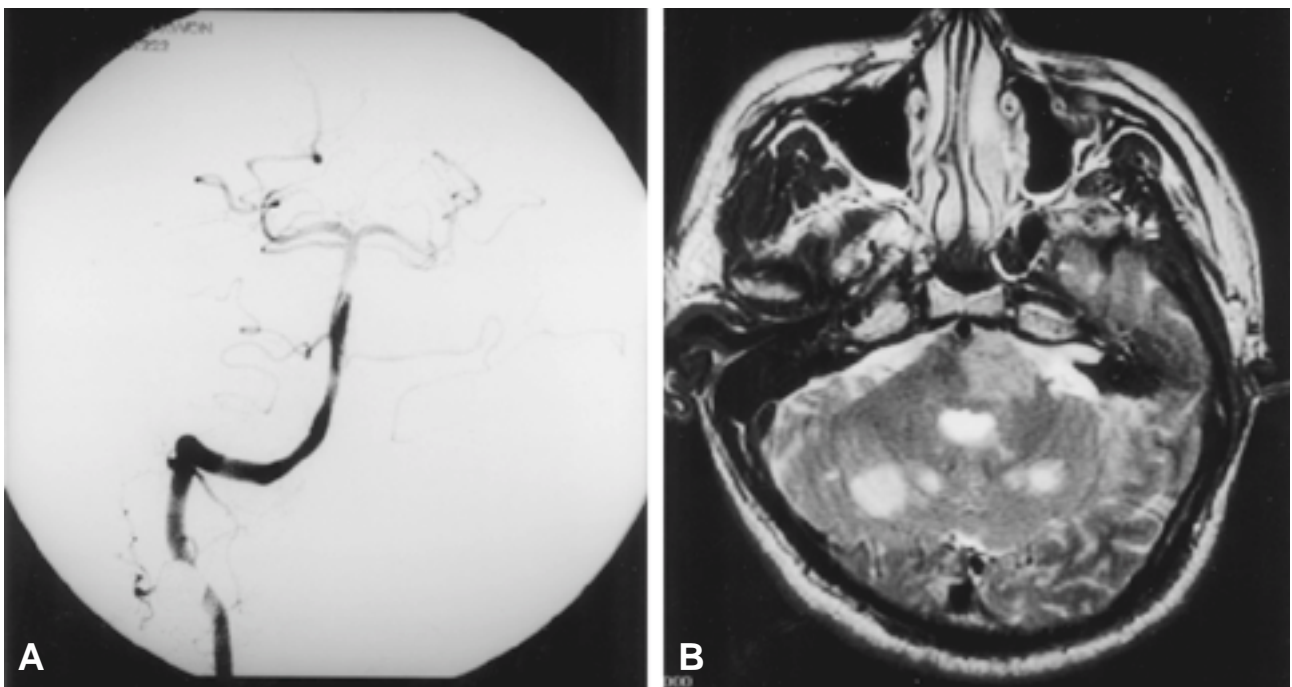


Figure 2. (A) Vertebral angiogram (anterior-posterior view) demonstrates an intimal flap originating from the anterior inferior cerebellar artery and luminal narrowing in the basilar artery. (B) Brain MR image (T2-weighted) shows acute infarction of the pons and both cerebellum due to multiple emboli.

가 167cm/sec 가
T2
(signal void) 가 (Fig. 1-A).
T1
4

가 ; 3 -

가 2

(Fig. 1-B). 6

T1 가

가 1 1 (1)

30 가 93cm/sec 가 174/98mmHg

2mm 3mm

2

34 가 가

30

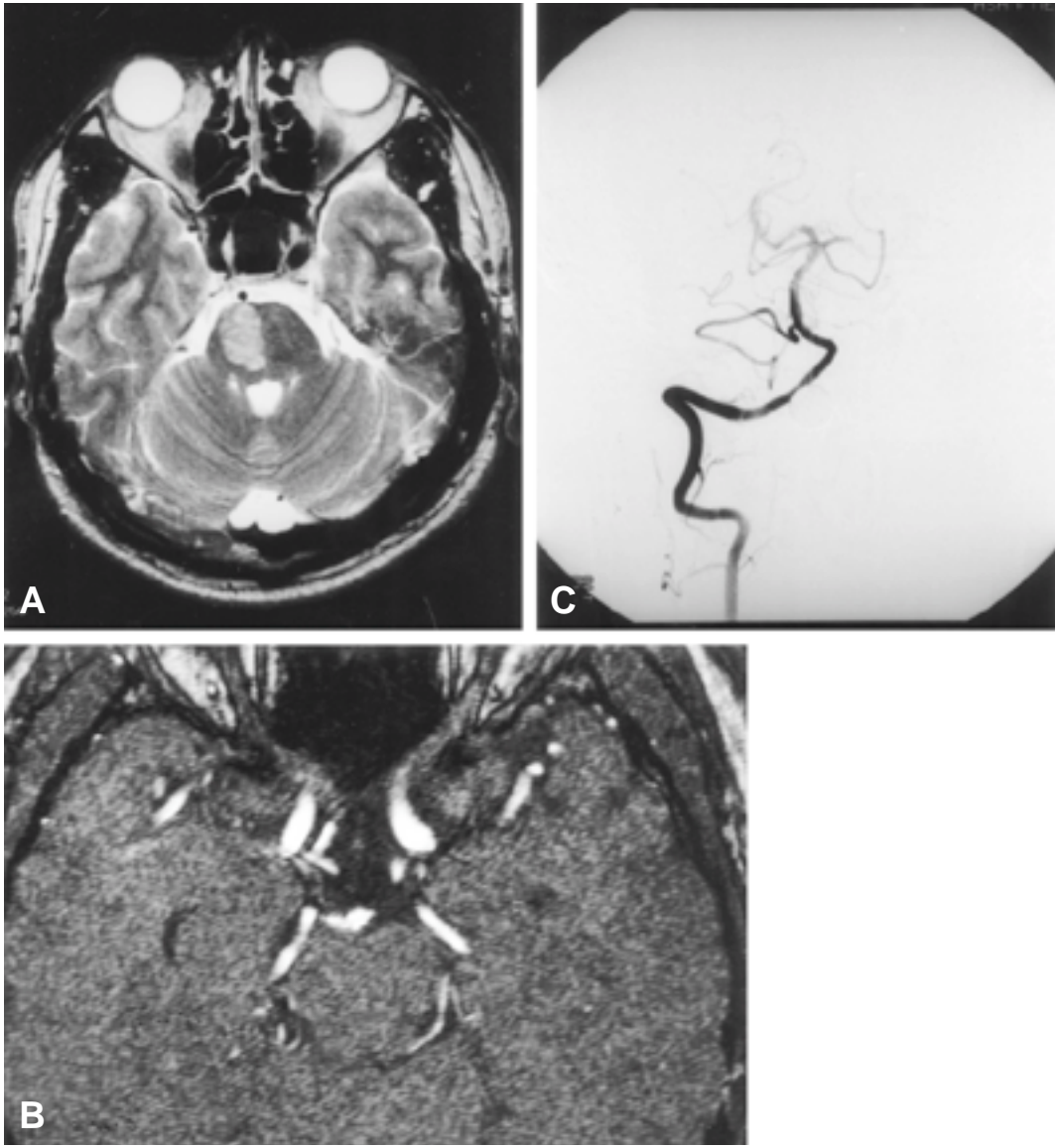


Figure 3. (A) Brain MRI (T2-weighted) shows acute infarction of the right pons. (B) Brain MRI (source image) shows a transverse intimal flap in the basilar artery. (C) Vertebral angiogram (anterior-posterior view) demonstrates segmental luminal narrowing in the basilar artery and multiple emboli in both posterior cerebral arteries.

(Source image)

(Fig. 3-

B). 3

(Fig. 3-C)

(Fig. 2-A).

3cm

4 x 25mm

가

가

40

Grade III,

Grade IV

2

(Fig. 2-B).

5

가

가

가

3

26

3

1

(pearl and/or string
(intimal flap)

Grade II)가

(sign)

[6,7].

1, 2

(Grade IV)

가

4

가

가

T1

(3).

3mm

[4-7]. Levy [8]

가 60%

84%

가

가

Grade II,

Grade III

가

(spasticity)

(rigidity)

가

PT/aPTT, Fibrinogen, Protein-C, Free Protein-C,
Protein-S, Antithrombin III, Russel viper venom
time, ESR CRP Lupus
Anticoagulant, ACA IgG & IgM, FANA,
Rheumatoid Factor

(tunica adventitia)
(external elastic lamina)

t-PA(1),

urokinase

(Fig. 3-A)

(2)

[2]
detachable coil
2 stent

가
가

가

REFERENCES

1. [unclear], [unclear], [unclear], [unclear], [unclear]. 1996;14:875-879.
2. [unclear], [unclear]. Detachable coil 1996.
3. Nakatomi H, Nagata K, Kawamoto S, Furusho JI. Basilar artery occlusion due to spontaneous basilar artery dissection in a child. *Acta Neurochir (Wien)* 1999;141:99-104.
4. Scazzari F, Mascalchi M, Calabrese R, Quilici N. Case report. MRI and MR angiography of basilar artery dissection in a child. *Neuroradiology* 1997;39:654-657.
5. Masson C, Krespy Y, Masson M, Colombani JM. Magnetic resonance imaging in basilar artery dissection. *Stroke* 1993;24:1264-1266.
6. Provenzale JM. Dissection of the internal carotid and vertebral arteries: imaging features. *AJR* 1995;165:1099-1104.
7. Kitanaka C, Tanaka J, Kuwahara M, Teraoka A. Magnetic resonance imaging study of intracranial vertebrobasilar artery dissections. *Stroke* 1994;25:571-575.
8. Levy C, Laissy JP, Raveau V, Amarenco P, Servois V, Bousser MG. Carotid and vertebral artery dissections: three-dimensional time-of-flight MR angiography and MR imaging versus conventional angiography. *Radiology* 1994;190:97-103.