

Endoscopic Snare Resection for Tumors of the Ampulla of Vater

Seung Woo Park, Si Young Song, Jae Bock Chung, Seung Keun Lee, Young Myung Moon,
Jin Kyung Kang, and In Suh Park

Abstract

Though surgical resection has been the traditional treatment for tumors of the ampulla of Vater, endoscopic maneuvers such as snare resection, laser photodestruction and electrofulguration have recently been introduced to avoid operation-related morbidity and mortality. From 1994 to 1996, 6 patients with ampullary tumor were managed by endoscopic snare resection and regularly followed. Endoscopic snare resection of the ampullary tumor was technically feasible in all patients and each procedure was performed in a single session. Histologic diagnoses of the resected specimens were adenoma in 4 patients and adenoma with coexistent adenocarcinoma in 2 patients. Resection margins were negative in all patients except 1 with coexistent adenocarcinoma and a radical pancreaticoduodenectomy was performed in that case. For the other patient with adenocarcinoma foci, no further treatment was pursued since he was 72-years-old and refused operation. Acute pancreatitis developed in 2 patients after endoscopic therapy, but was resolved with conservative management. There was no procedure-related death. Surveillance duodenoscopy performed at 1 and 6 months after endoscopic resection revealed no evidence of recurrent tumor in 4 patients with adenoma. Among them, 3 patients are alive without evidence of recurrence at 16-37 months after resection, but 1 patient was lost after 9 months of follow-up. The patient with adenocarcinoma in whom a pancreaticoduodenectomy was performed, has been alive without recurrence for 12 months. Oral 5-fluorouracil was administered for the other patient with adenocarcinoma foci. Though he experienced local recurrence at 13 months after the procedure, he has been alive for 28 months after resection. In conclusion, endoscopic snare resection may be applied as a viable alternative to surgery in selected patients with small ampullary tumors.

Key Words: Ampullary tumor, endoscopic resection

INTRODUCTION

Tumors of the ampulla of Vater, usually found in patients in their sixth to eighth decades,¹⁻⁴ represent less than 5% of all new digestive tract neoplasms and less than 10% of periampullary tumors.⁵ Though a large proportion of ampullary tumors are adenocarcinomas, adenomas are being found more frequently with the increased application of endoscopic retrograde cholangiopancreatography (ERCP).

An ampullary tumor, whether malignant or not, must be completely resected because a benign adenoma has the potential for malignant transformation.⁶⁻⁸ A radical pancreaticoduodenectomy has been widely

performed for the treatment of ampullary tumors. However, because the procedure has a significant rate of postoperative morbidity and mortality,⁹⁻¹¹ local resection has been applied as an alternative to Whipple's operation in patients with ampullary tumors.^{1,4,12,13} Moreover, endoscopic procedures such as endoscopic snare resection,^{14,15} photodynamic therapy,^{16,17} and electrofulguration¹⁸ have recently been tried for small benign ampullary tumors with acceptable safety and effect. A major pitfall of tumor ablation therapies such as photodynamic therapy and electrofulguration is the inability to detect carcinomatous foci because these modalities completely destroy the tumor and thus cannot provide the specimens to examine the resection margins. Therefore, endoscopic snare resection which provides the specimens for a pathologic examination would be a better treatment option than endoscopic tumor ablation therapies.

During a 3-year period from January 1994 to December 1996, we performed endoscopic snare

Received September 15, 1999

Accepted January 11, 2000

Department of Internal Medicine, Institute of Gastroenterology, Yonsei University College of Medicine, Seoul, Korea.

Address reprint request to Dr. J. B. Chung, Department of Internal Medicine, Yonsei University College of Medicine, C.P.O. Box 8044, Seoul 120-752, Korea. Tel: 82-2-361-5427, Fax: 82-2-365-2125, E-mail: jbchung@yumc.yonsei.ac.kr

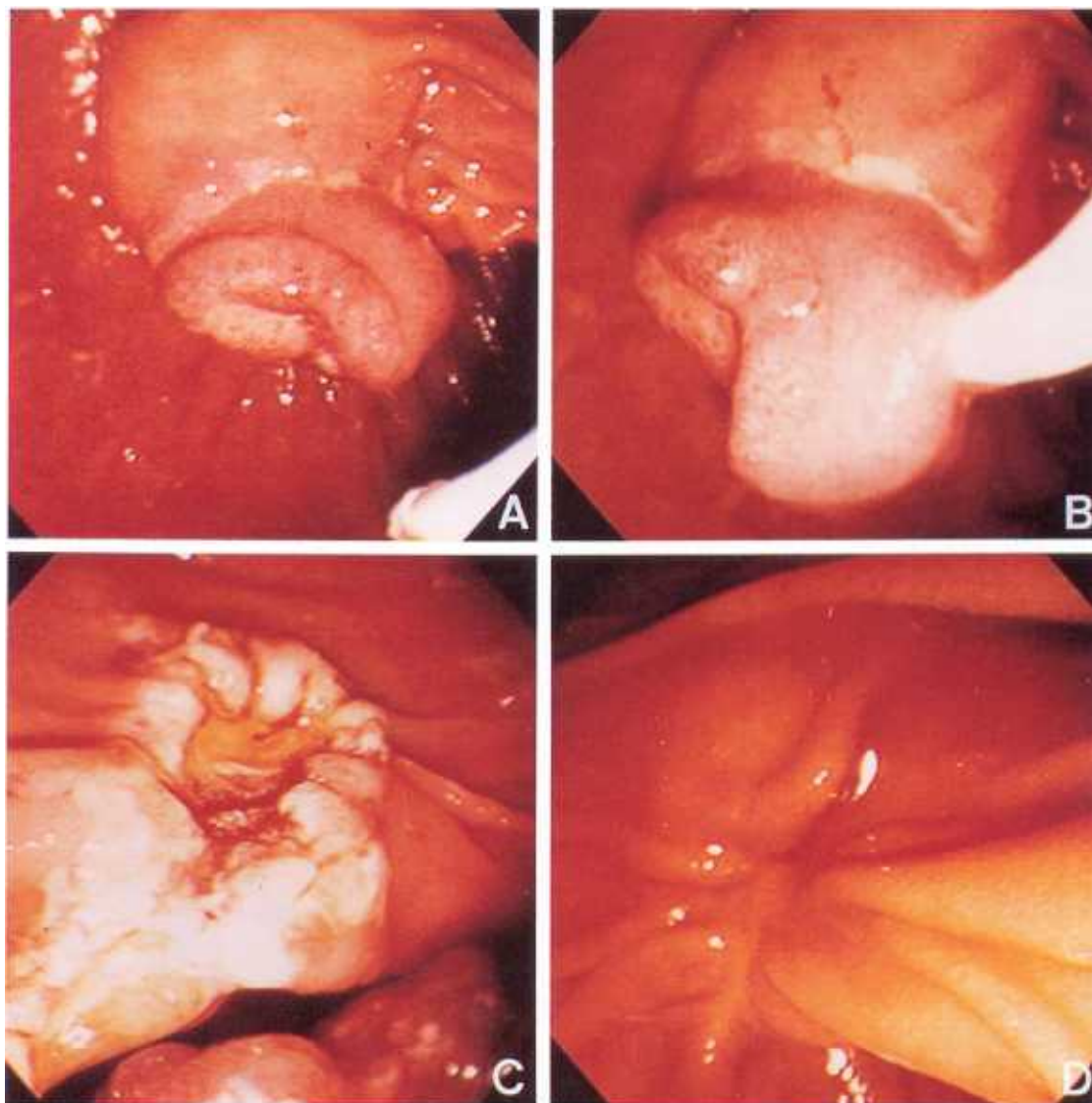


Fig. 1. Serial duodenoscopic findings of a patient (case 6). (A) Ampullary tumor before resection. (B) Appearance after grasping the tumor at the base. (C) Appearance after resection of the tumor. (D) Appearance at 2 months after resection showing no evidence of remnant tumor.

resection revealed no evidence of recurrent adenoma at the resection sites in all patients.

The patient with adenocarcinoma who underwent radical surgery after endoscopic resection has been alive without evidence of local or distant tumor recurrence for 12 months. The other patient with adenocarcinoma who refused operation after endoscopic resection, received oral 5-fluorouracil treatment. He experienced local recurrence 13 months after the procedure, but he is alive 28 months after the procedure.

DISCUSSION

The treatment options for tumors of the ampulla of Vater include radical pancreaticoduodenectomy, local resection, and endoscopic treatment. Optimal treatment for a malignant ampullary tumor is radical pancreaticoduodenectomy. Pancreaticoduodenectomy, however, is still associated with considerable morbidity and mortality,^{5,9,10,19,20} and it is limited to patients who are medically fit. For benign tumors of the ampulla of Vater, local resection can be

Table 1. Results of Ampullary Resection in 6 Patients with Ampullary Tumors

Case	Age	Sex	Symptoms	Tumor Size (mm)	Resection margin	Complication	Pathology	Other treatment	Follow up
1	56	M	Jaundice Abd. Pain	15 × 20	Negative	Pancreatitis	Adenoma	None	37 mo, alive No recurrence
2.	76	M	Jaundice	12 × 10	Negative	Pancreatitis	Adenoma	None	24 mo, alive No recurrence
3.	59	M	Abd. pain	5 × 4	Negative	None	Adenoma	None	9 mo, alive Lost to follow up
4.	50	M	Abd. pain	20 × 15	Negative	None	Adenoma	None	16 mo, alive No recurrence
5.	65	F	No symptom	25 × 20	Positive	None	Adenoma with adenocarcinoma	Pancreatico- duodenectomy	12 mo, alive No recurrence
6.	72	M	Jaundice	30 × 20	Negative	None	Adenocarcinoma	None	28 mo, alive Recurred at 13 mo.

Abd, abdominal; mo, months.

justified.^{1,3,4,21-23} However, since the false negative rates of endoscopic biopsies have been reported to be in the range of 40–85%,^{2,6,24,25} one cannot accurately differentiate between benign and malignant lesions based solely on a pathologic report of biopsy specimens. For this reason, pancreaticoduodenectomies have often been carried out for benign tumors of the ampulla of Vater.^{2,12}

Local resection has been reported to effectively control benign tumors of the ampulla of Vater and this has introduced the concept of endoscopic treatment such as endoscopic snare resection,^{14,15} photodynamic therapy,^{16,17} and electrofulguration¹⁸ for the treatment of ampullary tumors. Binmoeller et al. treated 25 patients with ampullary adenoma by endoscopic snare resection.¹⁴ Six of 25 patients (24%) had recurrences at a median follow-up of 37 months. Post-papillectomy bleeding occurred in 2 patients and acute pancreatitis in 3, but all complications were effectively managed with conservative treatment. In our series, the recurrence rate was 20% (1 of 5), but if the patients only with adenomas are included, it was 0% (0 out of 4). Acute pancreatitis developed in 2 patients, but was resolved with conservative management. Neither bleeding nor procedure or complication-related mortality was experienced. Taken together, these results suggest that endoscopic snare resection of tumors of the ampulla of Vater is associated with a relatively low recurrence rate (up to 25%), mild complications, and nil mortality, and thus should be considered a viable alternative to surgical

therapy.

Interestingly, Ponchon et al. treated 11 patients with ampullary adenoma with or without an intramucosal carcinomatous focus using endoscopic snare resection alone, laser photodestruction alone or a combination of both.²⁶ One recurrence was noted in their series (9.0%), but that case was again eligible for a repeated laser photodestruction session. Indeed, this approach may reduce the recurrence rate of endoscopic snare resection and it seems to warrant further evaluation.

Binmoeller et al. applied the following criteria for selecting patients suitable for endoscopic treatment: 1) tumor size less than 4 cm, 2) no evidence of malignancy based on endoscopic appearance (regular margins, no ulceration) and soft consistency, and 3) benign histologic findings on forcep biopsies (minimum of 6 biopsies).¹⁴ We used similar criteria to Binmoeller's except for the tumor size (< 3 cm). Endoscopic ultrasonography (EUS) may be helpful in defining the tumor and the depth of invasion for cancerous lesions. However, because EUS cannot differentiate a T1 carcinoma from a benign adenoma,²⁵ it should not be used for the purpose of differentiating between benign and malignant lesions. All patients except 1 whose endoscopic biopsy specimens were positive for malignancy met with the above-mentioned criteria. One patient (case 5) was found to have a focal malignant change with resection margins positive for tumor cells and therefore underwent a radical pancreaticoduodenectomy. This patient

remains alive without evidence of recurrence. An algorithm may be set up based on the favorable outcome of this case. If an adenoma is benign looking and malignancy negative on biopsy specimens, endoscopic snare resection is carried out first, and the decision whether or not to perform a pancreaticoduodenectomy should be made after obtaining the pathologic report of the resected specimen.

Another important finding in this series is that endoscopic snare resection may play a role in palliation in selected patients with biopsy proven adenoma with foci of adenocarcinomas. Case 6 had biopsy-proven focal cancer, but refused operation. Although the resection margins were negative for tumor cells, local recurrence occurred at 13 months but he has been alive for 28 months after endoscopic resection. Thus, endoscopic local resection can be used as a palliative measure in patients who are unfit for a major operation or who refuse surgery.

One technical point worth mentioning is that cholangiopancreatogram should be obtained after endoscopic resection. If drainage of the contrast dye is poor, temporary placement of an endoprosthesis may be helpful. However, we have not encountered a patient who needed placement of an endoprosthesis.

Obviously, local recurrence is a major drawback of endoscopic local treatments for tumors of the ampulla of Vater. Careful follow-up with repeated biopsies is required to detect residual tumor, but the problem is that the regimen of duration and frequency of follow-up is still not established.

In conclusion, endoscopic snare resection is considered as technically feasible, safe, and effective for the treatment of supposedly benign tumors of the ampulla of Vater and it can be an alternative to surgical resection in selected patients who have high surgical risks or who refuse operation.

REFERENCES

- Ryan D, Schapiro R, Warshaw AL. Villous tumors of the duodenum. *Ann Surg* 1986;203:301-6.
- Gray G, Browder W. Villous tumors of the ampulla of Vater: Local resection versus pancreaticoduodenectomy. *South Med J* 1989;82:917-20.
- Asbun HJ, Rossi RI, Munson JL. Local resection for ampullary tumors: Is there a place for it? *Arch Surg* 1993; 128:515-20.
- Neoptolemos JP, Talbot IC, Carr-Locke DL, Shaw DE, Cockleburgh R, Hall AW, et al. Treatment and outcome in 52 consecutive cases of ampullary carcinoma. *Br J Surg* 1987;74:957-61.
- Branum G, Pappas TN, Meyers WC. The management of tumors of the ampulla of Vater by local resection. *Ann Surg* 1996;224:621-7.
- Seifert E, Schulte F, Stolte M. Adenoma and carcinoma of the duodenum and papilla of Vater: a clinicopathologic study. *Am J Gastroenterol* 1992;87:37-42.
- Perzin KH, Bridge MF. Adenomas of the small intestine: a clinicopathologic review of 51 cases and a study of their relationship to carcinoma. *Cancer* 1981;48:799-819.
- Gouma DJ, Obertop H, Vismans J, Willebrand D, Soeters PB. Progression of a benign epithelial ampullary tumor to adenocarcinoma. *Surgery* 1987;101:501-4.
- Allema JH, Reinders ME, Gulik TM, Leeuwen DJ, Verbeek PCM, Wit LT, et al. Results of pancreaticoduodenectomy for ampullary carcinoma and analysis of prognostic factors for survival. *Surgery* 1995;117:247-53.
- Crist DW, Sitzmann JV, Cameron JL. Improved hospital morbidity, mortality, and survival after the whipple procedure. *Ann Surg* 1987;206:358-65.
- Monson JR, Donohue JH, McIlrath DC, Heerden JA, Shoter RG, Nagorney DM, et al. Radical resection for carcinoma of the ampulla of Vater. *Arch Surg* 1991;126: 353-7.
- Sharp KW, Brandes JL. Local resection of tumors of the ampulla of Vater. *Am Surg* 1990;56:214-7.
- Chijiwa K, Yamashita H, Kuroki S. Wide ampullectomy for patients with villous adenoma of duodenal papilla and follow-up results of pancreaticobiliary tract. *Int Surg* 1994;79:178-82.
- Binmoeller KF, Boaventura S, Ramsperger KR, Soehendra NS. Endoscopic snare excision of benign adenomas of the papilla of Vater. *Gastrointest Endosc* 1993;39:127-31.
- Siegel JH, Yatto RP. Endoscopic evaluation and therapy of periampullary adenoma. *Am J Gastroenterol* 1983;78: 225-6.
- Lambert R, Ponchon T, Chavaillon A, Berger F. Laser treatment of tumors of the papilla of Vater. *Endoscopy* 1988;20:227-31.
- Abulafi AM, Allardice JT, Williams NS, Someren N, Swain CP, Ainley C. Photodynamic therapy for malignant tumors of the ampulla of Vater. *Gut* 1995;36:853-6.
- Shemesh E, Nass S, Czerniak A. Endoscopic sphincterotomy and endoscopic fulguration in the management of adenoma of the papilla of Vater. *Surg Gynecol Obstet* 1989; 169:445-8.
- Sperti C, Pasquali C, Piccoli A, Sernagiotto C, Pedrazzoli S. Radical resection for ampullary carcinoma: long-term results. *Br J Surg* 1994;81:668-71.
- Robertson JFR, Imrie CW, Hole DJ, Carter DC, Blumgart LH. Management of periampullary carcinoma. *Br J Surg* 1987;74:816-9.
- Schulzen MF, Oyasu R, Beal JM. Villous adenoma of the duodenum: a case report and review of the literature. *Am J Surg* 1976;132:90-6.
- Farouk M, Niotis M, Braunum GD, Cotton PB, Meyers

- WC. Indications for and the technique of local resection of tumors of the papilla of Vater. *Arch Surg* 1991;126:650-2.
23. Sand JA, Nordback IH. Transduodenal excision of benign adenoma of the papilla of Vater. *Eur J Surg* 1995;161:269-72.
24. Yamaguchi K, Enjoji M, Kitamura K. Endoscopic biopsy has limited accuracy in diagnosis of ampullary tumors. *Gastrointest Endosc* 1990;36:588-92.
25. Rattner DW, Castillo F, Brugge WR, Warshaw AL. Defining the criteria for local resection of ampullary neoplasms. *Arch Surg* 1996;131:366-71.
26. Ponchon T, Berger F, Chavallon A, Bory R, Lambert R. Contribution of endoscopy to diagnosis and treatment of tumors of the ampulla of Vater. *Cancer* 1989;64:161-7.
-