

# Uterine Artery Doppler Velocimetry in the Prediction of Adverse Obstetric Outcomes in Unexplained MSAFP Elevations

Jae Eun Chung, Jae Sung Cho, Sung Shik Han, Yong Won Park, and Jae Wook Kim

## Abstract

Unexplained maternal serum-fetoprotein (MSAFP) elevation has been known to be associated with adverse obstetric outcomes, however it is not sufficiently useful as a screening test. This study was undertaken to determine whether uterine artery Doppler velocimetry could define a subset of patients with an elevated MSAFP level in whom complications of pregnancy might develop. The subjects included 179 women between 26 and 28 weeks' gestation with MSAFP  $\geq 2.5$  multiples of the median, in whom either the presence of an early diastolic notch or a resistance index 0.6 was considered as an abnormal Doppler velocimetry finding. Those subjects who displayed abnormal Doppler velocimetry findings showed an increased incidence of preeclampsia, preterm birth, IUGR, and IUFD compared to those subjects with only elevated MSAFP ( $p < 0.05$ ). No differences were observed in the incidence of LBW. Positive predictive values of adverse obstetric outcomes were significantly higher in the group having both elevated MSAFP and abnormal Doppler velocimetry compared to the group with only elevated MSAFP ( $p < 0.05$ ). Uterine artery Doppler velocimetry in the second trimester can improve the value of unexplained MSAFP elevation in the prediction of adverse obstetric outcomes.

**Key Words:** Unexplained elevated maternal serum-fetoprotein, uterine artery Doppler velocimetry, adverse pregnancy outcome

## INTRODUCTION

$\alpha$ -fetoprotein (AFP) is an oncofetal glycoprotein produced by the fetus and high levels of maternal serum  $\alpha$ -fetoprotein (MSAFP) have been used as a screening test for fetal abnormalities including neural tube defects. Since the early 1980s, a link has been noted between MSAFP elevations without any detectable causes and adverse obstetric outcomes, including preeclampsia, low birth weight (LBW, birth weight  $< 2500$  gm), preterm birth ( $< 37$  weeks' gestation), intrauterine growth restriction (IUGR, birth weight  $< 10^{\text{th}}$  percentile), and intrauterine fetal death (IUFD).<sup>1</sup> However, MSAFP cannot be considered as a screening test for the above-mentioned subsets of adverse obstetric outcomes due to the low positive predictive value.<sup>2</sup> There is evidence to suggest that abnormal placentation is responsible for MSAFP

elevations, and numerous reports have been published suggesting that adverse obstetric outcomes with raised MSAFP are limited to those with placental pathology.<sup>1,3,4</sup> Evaluation of the fetal circulatory system by Doppler ultrasonography has been utilized since the 1980s and it is regarded as an acceptable method in the evaluation of fetal well-being.<sup>5</sup> Park et al. have reported the value of uterine artery Doppler velocimetry in predicting preeclampsia or IUGR, and particularly after 26 weeks' gestation, an increased resistance index (RI) or the presence of an early diastolic notch was shown to be related to adverse obstetric outcomes.<sup>6</sup> The objective of this study was to evaluate the role of uterine artery Doppler velocimetry in predicting adverse obstetric outcomes for patients with unexplained MSAFP elevations.

## MATERIALS AND METHODS

From April 1995 through February 1999, 179 women were evaluated in the Department of Obstetrics and Gynecology, Yonsei University College of Medicine. MSAFP was measured between 16 and 18

Received May 4, 1999

Accepted October 28, 1999

Department of Obstetrics and Gynecology, Yonsei University College of Medicine, Seoul, Korea.

Address reprint request to Dr. Y. W. Park, Department of Obstetrics and Gynecology, Yonsei University College of Medicine, C.P.O. Box 8044, Seoul 120-752, Korea. Tel: 82-2-361-7761, Fax: 82-2-313-8357, E-mail: obgy@yumc.yonsei.ac.kr

weeks' gestation and adjustments for maternal factors including weight, race, and diabetes were made. In case of MSAFP elevations  $>2.5$  multiples of the median (MoM), the level was rechecked after a short interval, and targeted ultrasonographic examination was performed with ATL-UM9 HDI and ATL-HDI 3000 (Advanced Technology Laboratory, Bothell, Washington, USA), confirming the gestational age, the number of fetuses present, and anatomical malformations such as neural tube defects. The group with two consecutive levels of elevated MSAFP without a detectable anomaly in ultrasonographic examination was closely followed up, and between 26–28 weeks' gestation uterine artery Doppler velocimetry was performed. Each patient was examined in a semirecumbent position after at least 10 minutes of bed rest. The external iliac artery was visualized using color Doppler and the uterine artery Doppler waveform was obtained by identifying the crossing of the external iliac artery and the main uterine artery, followed by placing the range gate over the entire diameter of the uterine artery nearest to this site. The quality of the Doppler velocimetry was maximized by using the smallest possible angle of insonation and accepting only those waveforms with a sharp and definite outline (Fig. 1). An early diastolic notch was defined as a V-shaped deflection toward the baseline in early diastole, just after systolic flow but prior to maximum diastolic flow (Fig. 2). Resistance index (RI) was defined as (peak systolic frequency end diastolic frequency)/peak systolic frequency. The maximum systolic and minimum diastolic points were measured directly from the waveform and the RI was calculated. Abnormal uterine artery Doppler velocimetry finding was defined as the presence of an early diastolic notch or  $RI \geq 0.6$ , since that was the upper limit of the RI in a previously published study of normal pregnancies.<sup>7</sup> The RI was measured independently from the placental location, and the higher value of the right and left uterine measurement was used in the data analysis. As has become customary, we chose not to quantitate or grade the notch. Pregnancy outcome data were collected directly from the medical records or by telephone if delivery occurred outside our institution. Outcome variables examined included the gestational age at delivery, mode of delivery, Apgar scores, birth weight, occurrence of preeclampsia, preterm birth, LBW, IUGR, or IUFD. Only a single evaluation of Doppler velocimetry at

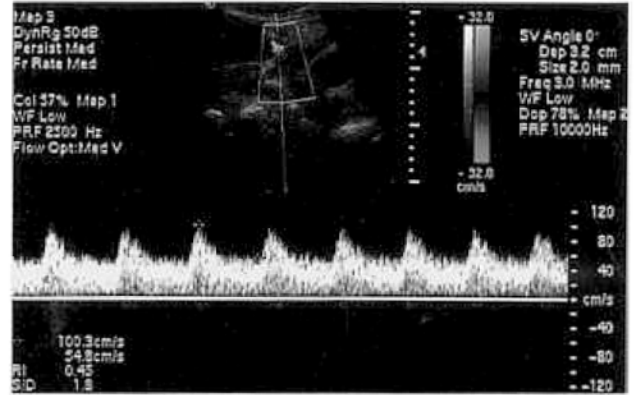


Fig. 1. Normal uterine artery blood flow velocity waveform.

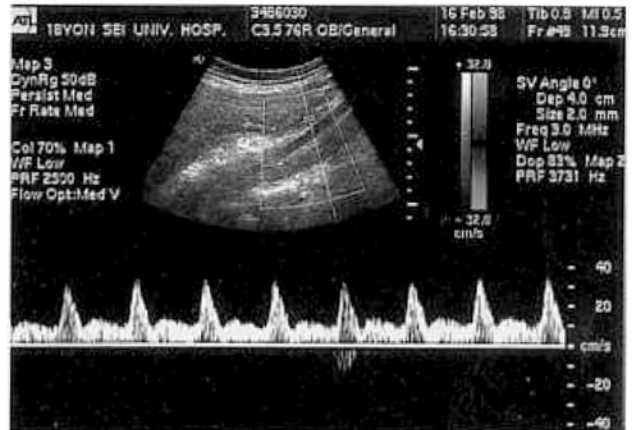


Fig. 2. Abnormal uterine artery blood velocity waveform demonstrates early diastolic notch.

the time of targeted ultrasonography was performed, which reduced time, cost, patient's inconvenience, and noncompliance, which are important features of a screening test.

This study was approved by the Institutional Review Board of the Yonsei University College of Medicine, and informed consent was obtained from each patient. Results of the Doppler examinations were not revealed to the clinicians controlling the cases. For statistical analysis, Student *t* test,  $\chi^2$  analysis, and Fisher's exact test were used. *P* value  $< 0.05$  was considered statistically significant.

## RESULTS

Of the 79 women studied with unexplained

**Table 1. Sensitivity and Specificity of Uterine Artery Doppler Velocimetry in Unexplained MSAFP Elevations**

Preeclampsia	Preterm	Birth	LBW	IUGR	IUFD
Sensitivity	88.5%	52.9%	70.0%	43.2%	100.0%
Specificity	88.9%	84.8%	83.6%	83.1%	78.5%

Abnormal Doppler Velocimetry:  $RI \geq 0.6$  or the presence of early diastolic notch.

Preterm birth: birth < 37 weeks' gestation.

LBW, low birth weight; birth weight < 2500 gm.

IUGR, intrauterine growth restriction; birth weight < 10<sup>th</sup> percentile.

IUFD, intrauterine fetal death.

**Table 2. Positive Predictive Values of Adverse Obstetric Outcomes**

	Preeclampsia	Preterm birth	LBW	IUGR	IUFD
MSAFP elevation only	14.5%	19.0%	11.2%	20.7%	1.1%
MSAFP elevation & abnormal doppler velocimetry	57.5%*	45.0%*	35.0%*	40.0%	5.0%

Abnormal Doppler Velocimetry:  $RI \geq 0.6$  or the presence of early diastolic notch.

\*  $p < 0.05$ .

MSAFP elevations, the mean maternal age was  $29.3 \pm 4.6$  (SD) years, and the mean birth weight was  $3120 \pm 249.1$  (SD) gm. Abnormal Doppler velocimetry findings occurred in 40 (22.3%), and of those who had abnormal Doppler velocimetry findings, 36 (20.1%) displayed a uterine notch, and 28 (15.6%) had  $RI \geq 0.6$ , while 24 (13.4%) had both abnormalities. No significant differences were found in the maternal age, cesarean section rate, or level of MSAFP, between the group with abnormal Doppler velocimetry and the group without it. The patients who showed abnormal Doppler velocimetry findings revealed a high sensitivity for preeclampsia (88.5%), preterm birth (52.9%), LBW (70.0%), IUGR (43.2%), and IUFD (100.0%) (Table 1). The specificity of abnormal Doppler velocimetry findings for preeclampsia was 88.9%, preterm birth was 84.8%, LBW was 83.6%, IUGR was 83.1%, and IUFD was 78.5% (Table 1). Positive predictive values of adverse obstetric outcomes including preeclampsia, preterm birth, and low birth weight, were significantly higher in the group having elevated MSAFP and abnormal Doppler velocimetry compared to the group with only elevated MSAFP ( $p < 0.05$ ). The positive predictive value of each adverse obstetric outcome was as follows: preeclampsia 57.5% vs. 14.5%, preterm

birth 45.0% vs. 19.0%, LBW 35.0% vs. 11.2%, IUGR 40.0% vs. 20.7%, and IUFD 5.0% vs. 1.1% (Table 2).

## DISCUSSION

Measurement of MSAFP is an established screening method for neural-tube defects.<sup>2</sup> The fetal liver is the dominant source of AFP production throughout pregnancy following the yolk sac involution by 11 to 12 weeks' gestation, and direct transfer across the placenta is considered to be one of the routes for delivering AFP from the fetus to the mother.<sup>4</sup> The faulty placental implantation implies a breakdown of the normal placental barrier between the two circulations with their 100,000-fold difference in AFP concentrations, theoretically allowing leakage of AFP into maternal circulation.<sup>4</sup> MSAFP elevation may be an indirect reflection of early placental damage leading to third trimester placenta-related adverse obstetric outcomes.<sup>8</sup> Early placental vascular lesions may be detectable in the second trimester by Doppler waveforms from the uteroplacental circulation.

Trophoblastic invasion of the decidual spiral arteries occur at 5 to 6 weeks' gestation.<sup>9,10</sup> There is

no noticeable blood flow within the intervillous space during most of the first trimester of a normal pregnancy, and that protects the implantation of the early gestation from the forces of arterial blood flow.<sup>7</sup> The infiltration of trophoblasts along the spiral arteries of the myometrium occurs in the first trimester and the disappearance of musculoelastic tissue in the middle layer of these vessels is concomitantly found.<sup>9</sup>

As a result of these changes, intervillous perfusion increases and vascular resistance of uteroplacental circulation significantly decreases, resulting in the increased diastolic blood flow.<sup>7,9,10</sup>

Clinically, if the RI of the uterine artery after 26 weeks' gestation exceeds 0.6 (>95<sup>th</sup> percentile) or an early diastolic notch exists, the situation signifies increased peripheral vascular resistance.<sup>6,11</sup> Bower et al. reported a uterine artery notch to be present in 16% of normal pregnancies between 18 and 22 weeks' gestation, but it disappeared after 24 to 26 weeks' gestation in normal pregnancy.<sup>12</sup> Therefore, persistent diastolic notch after 26 weeks' gestation along with increased RI can be considered abnormal. According to Aristidou et al., in some pregnancies with a normal outcome the abnormality in the uterine Doppler velocimetry at 18 to 22 weeks disappeared by 24 to 26 weeks, presumably because of delayed but normal trophoblastic invasion and placental maturation.<sup>13</sup> Bower et al. demonstrated that by including early diastolic notch in the category of abnormal uterine artery Doppler velocimetry in addition to RI, the sensitivity for predicting adverse obstetric outcomes was improved.<sup>14</sup> This is why we included only patients at 26 to 28 weeks' gestation at the time of Doppler velocimetry evaluation. All other patients who displayed a notch earlier in their gestation were discarded from this study.

The possibility that the pathology in the circulatory system can be determined by Doppler velocimetry suggests that the use of such waveforms may refine the value of previously used tests such as MSAFP level. Our study results have clearly demonstrated that patients with both unexplained MSAFP elevations and abnormal uterine artery Doppler velocimetry had an increased risk of having an adverse obstetric outcome including preeclampsia, preterm birth, LBW, IUGR, and IUFD compared to the patients who had only unexplained MSAFP elevation. Particularly the positive predictive values in the categories of preeclampsia, preterm birth, and low

birthweight statistical significance were noted between the group with only unexplained MSAFP elevations and the group with both unexplained MSAFP and abnormal Doppler velocimetry findings. The study results are another reappraisal of the value of Doppler velocimetry in the screening of adverse obstetric outcomes in the group which needs increased surveillance during pregnancy. Nevertheless, the use of Doppler velocimetry in the general population as a screening method warrants further study. A careful consideration for additional surveillance and proper counseling for patients with both unexplained MSAFP elevations and abnormal uterine artery Doppler velocimetry is warranted.

## REFERENCES

1. Thomas RL, Blakemore KJ. Evaluation of elevations in maternal serum  $\alpha$ -fetoprotein. *Obstet Gynecol Surv* 1990; 45:719-26.
2. Chard T, Rice M, Kitau MJ, Hird V, Grudzinkas JG, Nyssenbaum AM. Mid trimester levels of AFP in the screening of low birth weight. *Br J Obstet Gynaecol* 1986;93: 36-8.
3. Salafia CM, Silberman L, Herrera NE, Mahoney MJ. Placental pathology at term associated with elevated mid-trimester maternal serum-fetoprotein concentration. *Am J Obstet Gynecol* 1988;158:1064-6.
4. Thomas R, Blakemore K. Evaluation of elevations in maternal serum  $\alpha$ -fetoprotein: A review. *Obstet Gynecol Surv* 1990;45:269-83.
5. Campbell S, Diaz-Recasens J, Griffin DR, Cohen-Verbeek TE, Pearce JM, Wilson K, et al. New Doppler technique for assessing uteroplacental blood flow. *Lancet* 1983;I: 675-7.
6. Park YW, Cho JS, Kim HS, Kim JS, Song CH. The clinical implications of early diastolic notch in third trimester Doppler waveform analysis of the uterine artery. *J Ultrasound Med* 1996;15:47-51.
7. Jaffe R, Woods JR. Color Doppler imaging and in vivo assessment of the anatomy and physiology of the early uteroplacental circulation. *Fertil Steril* 1993;60:293-7.
8. Berkeley AS, Killackey MA, Cederqvist LL. Elevated MSAFP levels associated with breakdown in fetal-maternal-placental barrier. *Am J Obstet Gynecol* 1983;146:859-61.
9. Brosens I, Robertson WB, Dixon HG. The physiological response of the vessels of the placental bed to normal pregnancy. *J Pathol* 1967;93:569-79.
10. Jaffe R, Dorgan A, Abramowicz JS. Color Doppler imaging of the uteroplacental circulation in the first trimester: Value in predicting pregnancy failure or complication. *AJR* 1995;164:1255-8.
11. Meekins JW, Pijnenborg R, Hanssens M, McFayden IR,

- Van Asshe A. A study of placental bed spiral arteries and trophoblastic invasion in normal and severe pre-eclamptic pregnancies. *Br J Obstet Gynaecol* 1994;101:669-74.
12. Bower S, Schuchter K, Campbell S. Doppler ultrasound screening as part of routine antenatal screening: prediction of preeclampsia and intrauterine growth retardation. *Br J Obstet Gynaecol* 1993;100:989-94.
13. Aristidou A, Van Den Hof MC, Campbell S, Nicolaides K. Uterine artery Doppler in the investigation of pregnancies with raised maternal serum  $\alpha$ -fetoprotein. *Br J Obstet Gynecol* 1990;97:431-5.
14. Bower S, Bewley S, Campbell S. Improved prediction of preeclampsia by two-stage screening of uterine arteries using the early diastolic notch and color Doppler imaging. *Obstet Gynecol* 1993;81:78-83.
-