

Endoscopic Bone Graft for Delayed Union and Nonunion

Sung-Jae Kim¹, Sang-Jin Shin¹, Kyu Hyun Yang¹, Seong Hwan Moon¹, and Soo Chan Lee²

Abstract

We performed endoscopic bone grafting for eight patients of delayed union and nonunion which developed after femoral and humeral shaft fractures. The mean interval from initial intervention to endoscopic bone grafting was 7.3 months. Six patients of delayed union and nonunion healed at 4.1 months on average. Two patients had unsatisfactory healing and eventually underwent non-endoscopic revisional surgery. There was no intraoperative or postoperative complication. Endoscopic bone grafting can be a less invasive alternative, obtaining rapid bone union in cases of compromised healing of the diaphyseal fracture.

Key Words: Nonunion, arthroscopy, endoscopic bone graft

INTRODUCTION

Good fracture healing requires viable cells, proper stimuli and sound mechanical support. It also depends on the energy of initial impact and the method of treatment. In general, 5–10% of all fractures do not heal in the expected time, resulting in delayed union or nonunion.¹ Historically, autogenous bone graft has been a mainstay of treatment to overcome these complex problems.^{2–4} As it is an open technique, many authors have tried to develop less invasive methods such as electrical stimulation,^{5,6} electromagnetic field,^{7,8} ultrasound,⁹ and bone marrow injection.^{10,11} As these methods have many limits in their application, they are not appropriate for nonunion with wide gap and pseudarthrosis.

With the rapid development of endoscopic procedure, bone graft can be performed after curettage of fibrous tissue around the fracture gap and sclerotic fracture end under direct visual control of the endoscope. The technical details and a case of endoscopic bone graft in a delayed union of humeral shaft fracture were reported at the 13th Annual Seminar

of Arthroscopic Surgery (1991).¹²

This article reports on the results of seven cases of delayed union and one case of nonunion using this technique. Technical considerations of this procedure are discussed.

MATERIALS AND METHODS

Eight patients (five men and three women) with delayed union and nonunion after femoral and humeral shaft fractures from 1992 to 1994 were included in this study. Details of all patients are listed in Table 1. The mean age was 38 years (range 25 to 46 years). The interval from initial intervention to endoscopic bone grafting was 7.3 months on average. There were seven patients of delayed union and one patient of nonunion. The humerus was affected in four patients (middle one-third in three and distal one-third in one) and the femur in four patients (middle one-third in three and distal one-third in one). Among three patients of delayed union after femoral shaft fractures, one had been stabilized with a plate and screws and two with an external fixator. One patient of oligotrophic nonunion after femoral shaft fracture had been treated with a plate and screws. Four patients of delayed union after humerus fractures had been treated initially with a plate and screws, external fixator, flexible intramedullary nail, and rigid intramedullary nail, respectively. All eight patients had inappropriate fixation initially due to

Received September 30, 1999

Accepted December 3, 1999

¹Department of Orthopaedic Surgery, Yonsei University College of Medicine, Seoul, ²Department of Orthopaedic Surgery, Kil Hospital, Incheon, Korea.

Address reprint request to Dr. S. J. Shin, Department of Orthopaedic Surgery, Yonsei University College of Medicine, C.P.O. Box 8044, Seoul 120-752, Korea. Tel: 82-2-361-5640, Fax: 82-2-363-1139, E-mail: jinos@yumc.yonsei.ac.kr

Table 1. Summary of 8 Patients

Case	Diagnosis	Sex/Age	Site	Initial Fixation	IBIOB	IBBU	Joint	Initial ROM	Postop ROM
2	D	F/29	d-femur	Plate	9	4	Knee (F-F)	5°-85°	0°-130°
	D	F/30	m-femur	E/F	3	4.5	Knee (F-F)	0°-90°	0°-110°
	D	M/43	m-femur	E/F	3.5	5	Knee (F-F)	0°-20°	0°-50°
4	N	M/25	m-femur	Plate	15	5	Knee (F-F)	5°-40°	0°-70°
5	D	F/41	d-humerus	Plate	6	4	Elbow (F-F)	40°-100°	20°-120°
6	D	M/42	m-humerus	Rush pin	7	Fail	Shoulder (F-E)	110°-20°	180°-30°
	D	M/40	m-humerus	E/F	6	3	Elbow (F-F)	0°-90°	0°-110°
	D	M/46	m-humerus	IM nail	9	Fail	Shoulder (F-E)	70°-30°	180°-30°

D, delayed union; N, nonunion; d, distal; m, mid shaft; E/F, external fixator; IM, intramedullary; IBIOB, interval between initial operation and bone graft (month); IBBU, interval between bone graft and union (month); F-F, flexion-further flexion; F-E, flexion-extension; ROM, range of motion.

open fracture, severe comminution of fracture or technical errors.

The criteria for nonunion was pain at the fracture site with persistent fracture lines or gaps after six months. Delayed union was defined as partial formation of the callus, either periosteally or endosteally with localized pain after activity.⁴ Computerized axial tomography was used when a simple roentgenogram was not definite in determining the operation (cases 1, 7 and 8). All procedures were performed by the senior author (S-J Kim). Patients were followed up monthly at the outpatient clinic until complete union. During follow-up, plain radiography and tomography of delayed or nonunion sites were performed to confirm radiographic union.

Surgical technique

Endoscopic bone grafting was performed under general anesthesia in a supine position on a radiolucent table. In case of femoral shaft fracture, one portal was located at the lateral border of the rectus femoris and second one at the medial border of the rectus femoris muscle on the delayed or nonunion site of the femur. The two portals must be separated by at least 5 cm for good handling of the scope and instruments (Fig. 1). Fluoroscopic localization of the delayed and nonunion site was done in every case to ensure proper portal entry (Fig. 2A). In the case of humeral shaft fracture, two portals were made at the lateral border of the brachialis muscle on the delayed or nonunion site. One was at the level of the fracture site and another at 3 cm proximally or distally from

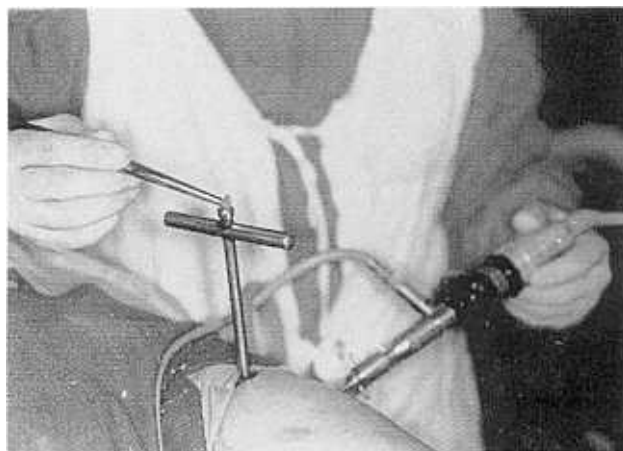


Fig. 1. Localization of the portals on the medial and lateral border of the rectus femoris muscle.

the fracture site. These portals can be switched alternately as a working portal through out the procedure. A blunt trochar with sheath was then introduced to touch the cortex of the bone. The soft tissue was peeled away from the delayed or nonunion site to gain space for the introduction of the endoscope. The fluid inflow system was maintained within 1 meter above the patient's arm to prevent excessive perfusion pressure, which might cause compartment syndrome. A mean 3 liters of fluid was enough for the procedure. The motorized shaver was introduced through the second portal and fibrous tissue was removed from the delayed or nonunion site (Fig. 2B). The sclerotic fracture ends were removed and medullary canal was opened by endoscopic burr and

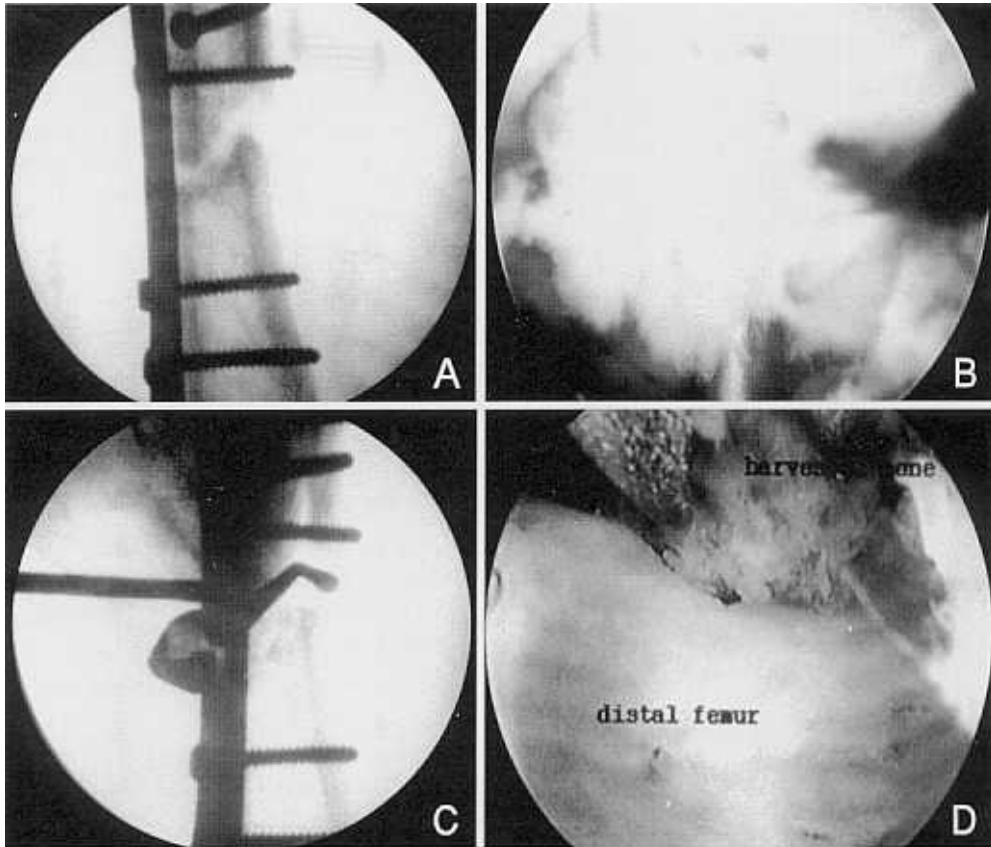


Fig. 2. (A) Localization of the delayed or nonunion site with fluoroscopic imaging. (B) Removal of fibrous tissue on the delayed union site with motorized shaver. (C) Removal of sclerotic bony ends with curved currett. (D) Placement of fresh autogenous iliac corticocancellous bone over the debrided delayed union site.

curved currett (Fig. 2C). A CORB's bone biopsy needle (Zimmer Inc, Warsaw, IN, USA), 5 mm in diameter, was introduced into the delayed union site. The corticocancellous bone chips which were harvested from the iliac crest were impacted into the fracture gap and placed over the delayed or nonunion site (Fig. 2D). Patients were discharged from the hospital three days after operation.

RESULTS

Bony union was accomplished at 4.1 months on average after endoscopic bone graft, ranging from 3 to 5 months except in two cases (cases 6 and 8). Average time for bony union was 4.6 and 3.5 months in the femur and the humerus, respectively. The adjacent joint motion was encouraged after pain subsided. In all patients, range of motion of the adjacent joints was improved (Table 1). Increase in the range

of motion was 47° on average. There was no intraoperative or postoperative complication. In patient 6 and 8, fractures were stabilized with intramedullary rush pin and intramedullary nail without interlocking which could not provide stable fixation and eventually resulted in nonunion after endoscopic bone graft. Patient 6 underwent revisional procedures which included removal of flexible intramedullary nail, plating and autogenous iliac bone graft. Patient 8 had another operation of interlocking humeral nailing and autogenous iliac bone graft. Finally the two patients achieved union after those open revisional surgeries.

Case illustrations

A 41-year-old female patient was admitted to the hospital after a motor vehicle accident. She sustained an open comminuted fracture on the distal one-third of the left humerus. An open reduction and internal fixation with dynamic compression plate was perfor-

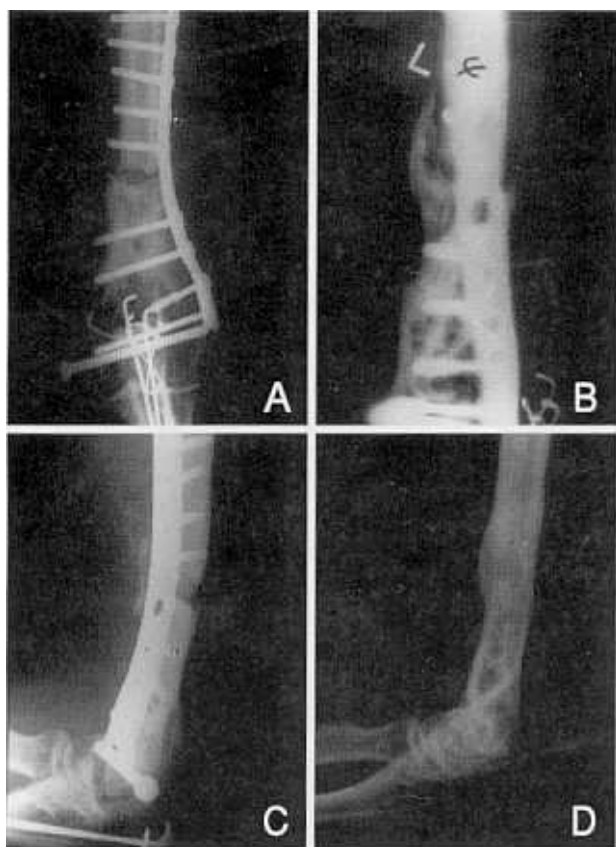


Fig. 3. Patient 5, (A) Plain radiograph of distal humerus shows gap in the fracture site. (B) Tomography demonstrated scant callus around the fracture site. (C) Plain radiograph after endoscopic bone graft showing grafted bone on the anterior aspect of the delayed union site. (D) Two years after endoscopic bone graft, plate and screws were removed and the patient regained functional range of motion of the elbow.

med with simultaneous autoiliac bone graft. At 6 months after operation, there was no evidence of solid union in plain radiograph and it showed a wide gap and scant callus formation (Fig. 3A). She complained of pain on the left arm and limited range of motion in her left elbow. Physical examination revealed tenderness on the fracture site without notable false motion. Her left elbow had flexion contracture of 40 degrees and further flexion of 100 degrees. Tomography of the left humerus confirmed a delayed union revealing scant callus around the fractured site (Fig. 3B).

Endoscopic bone grafting as described previously was performed six months after first intervention (Fig. 3C). At the end of the procedure, manipulation of the elbow joint was done to increase the range of motion. Postoperative recovery was uneventful and she was

discharged on the fourth day after the operation. Four months after endoscopic bone graft, pain disappeared and complete bony union was achieved. Her left elbow regained a functional range of motion. Two years after endoscopic bone graft procedure, the plate and screws were removed (Fig. 3D).

DISCUSSION

Autogenous cancellous bone graft has been the treatment of choice for delayed union and nonunion.²⁻⁴ However, open surgical procedure compromises the blood supply to the fracture site which was already damaged by the initial trauma and previous operations. Several non-invasive and semi-invasive methods have been developed to lessen the morbidity of the patient. In general, however, electric stimulation and an electromagnetic field are not applicable to synovial pseudarthrosis and nonunion with a wide gap.^{5-8,13} Bone marrow injection^{10,11} was introduced for the treatment of nonunion after tibial shaft fracture and pelvic reconstructive surgery.¹¹ However, fibrous tissue around the fracture site usually does not allow enough space and spreading of the injected marrow.

Bhan and Mehara reported a percutaneous bone grafting for nonunion and delayed union which developed after tibial shaft fracture,¹⁴ even though they obtained bony union in 19 of 21 cases. Their technique should be performed under the control of an image intensifier and it could not provide for complete curettage of the fibrous tissue and sclerotic bony ends.

In endoscopic bone grafting, refreshment of the fracture site can be done effectively under direct vision, provided that there is no dangerous anatomical structures around. Endoscopic procedure usually provides enough space for sufficient bone graft material to be placed. The selection of the portal may be limited due to an internal fixation device and neurovascular bundles. Johnson advocated that the advantages of endoscopic bone graft were minimal incision, accurate debridement, precise bone grafting, minimal vascular injury to the surrounding tissues, fewer complications, minimal hospital stay and reduced expense.¹²

We experienced two cases of failure out of eight cases. Since insufficient fixation of the fracture might

cause another nonunion after endoscopic bone graft, the importance of firm fixation prior to endoscopic intervention should be emphasized.

In our experience, endoscopic bone grafting has resulted in the enhancement of bone union, less morbidity and increased range of motion of the adjacent joints in selective cases. We believe these results have resulted from minimal soft tissue dissection preserving blood supply to the fracture as much as possible, as in the semi-invasive method, and good soft tissue debridement, as in the open technique. Furthermore, endoscopic bone grafting can be applied to nonunion with a large gap and synovial pseudarthrosis. The fact that minimal surgical trauma does not require transfusion is very useful in a Rh (-) blood-typed patient (case 1) because it is very difficult to find RH (-) blood typed donor in Asian countries. Control of postoperative pain was also very remarkable. Due to its minimal intervention, it requires only oral analgesics.

Endoscopic bone grafting has a few points to consider. First, it requires substantial surgical skills. Second, it may not be applicable to all cases due to local anatomy. It must be kept in mind that handling of the endoscopic instruments can jeopardize the adjacent neurovascular structure. Judicious selection of the endoscopic portals may overcome these anatomical limitations in part. Third, a potential hazard is a compartment syndrome due to fluid infusion and bone grafting in a limited space. We performed endoscopic bone grafting under low infusion pressure and did not see any sign of increased compartment pressure in the arm and thigh. Further extension of this method to the forearm and leg requires more experience and study.

In conclusion, endoscopic bone graft appears to be an efficient technique for enhancing union in delayed or non-union, and it has the potential as a treatment option for delayed and non-union.

REFERENCES

1. Praemer A, Furner S, Rice PP. Musculoskeletal conditions in the United States. In *The American Academy of Orthopaedic Surgeons*. Illinois: Park Ridge; 1992. p.85-124.
2. Burchardt H. Biology of bone transplant. *Orthop Clin North Am* 1987;18:187-96.
3. Souter WA. Autogenous cancellous strip grafts in the treatment of delayed union of long bone fractures. *J Bone Joint Surg Br* 1969;51:63-75.
4. Taylor JC. Delayed union and nonunion of fractures. In: Crenshaw AH, editor. *Campbell's Operative Orthopaedics*. 8ed. St. Louis: Mosby; 1992. p.1287-313.
5. Brighton CT, Black J, Friedenberg ZB. A multicenter study of the treatment of non-union with constant direct current. *J Bone Joint Surg Am* 1981;63:2-13.
6. Brighton CT, Pollock SR. Treatment of recalcitrant non-union with capacitatively coupled electrical field. A preliminary report. *J Bone Joint Surg Am* 1985;67:577-85.
7. Sharrard WJW, Sutcliffe ML, Robson MJ, Maceachern AG. The treatment of fibrous non-union of fractures by pulsing electromagnetic stimulation. *J Bone Joint Surg Br* 1982;64:189-93.
8. Sharrard WJW. A double-blind trial of pulsed electromagnetic fields for delayed union of tibial fractures. *J Bone Joint Surg Br* 1990;72:347-55.
9. Heckman JD, Ryaby JP, McCabe J, Frey JJ, Kilcoyne RF. Acceleration of tibial fracture-healing by non-invasive, low-intensity pulsed ultrasound. *J Bone Joint Surg Am* 1994;76:26-34.
10. Connolly JF, Gure R, Tiedeman J, Dehne R. Autologous marrow injections as a substitute for operative grafting of tibial nonunions. *Clin Orthop* 1991;266:259-70.
11. Healey JH, Zimmerman PA, McDonnell JM, Lane JM. Percutaneous bone marrow grafting of delayed union and nonunion in cancer patients. *Clin Orthop* 1990;256:280-5.
12. Johnson LL. Endoscopic bone grafting on the delayed union of the humerus. Presented at the 13th annual seminar of arthroscopic surgery; 1991; Phoenix, Arizona.
13. Scott G, King JB. A prospective, double-blind trial of electrical capacitative coupling in the treatment of non-union of long bones. *J Bone Joint Surg Am* 1994;76:820-6.
14. Bhan S, Mehara AK. Percutaneous bone grafting for non-union and delayed union of fractures of the tibial shaft. *Int Orthop* 1993;17:310-2.