

Churg-Strauss 1

, *

. . . . * . *

Abstract

A Case of Churg-Strauss Syndrome with Nephrotic Range Proteinuria

Shin Myung Kang, M.D., Chang Oh Kim, M.D., Yong Beom Park, M.D.,
Won Ki Lee, M.D., Hyeon Joo Jeong, M.D.*,
Shin Dong Hwan, M.D.*, Soo Kon Lee, M.D.

Department of Internal Medicine, Department of Pathology,
Yonsei University College of Medicine, Seoul, Korea*

Churg-Strauss syndrome or allergic granulomatosis and angiitis is a part of spectrum of systemic vasculitis characterized by asthma, eosinophilia, mono or polyneuropathy, nonfixed pulmonary infiltrates, paranasal sinus abnormality and extravascular eosinophil infiltration. We experienced a case of Churg-Strauss syndrome of 21-year-old male patient with purpura and pitting edema on both hands and feet. He also had heavy proteinuria of nephrotic range and renal failure. Renal biopsy demonstrated crescentic glomerulonephritis with massive infiltration of eosinophils, lymphocytes and plasma cells in the interstitium. Under the treatment with prednisolone and cyclophosphamide, serum creatinine level and amount of proteinuria were reduced.

Key Words : Churg-Strauss syndrome, Nephrotic range proteinuria, Crescentic glomerulonephritis

< : 2000 3 20 , : 2000 5 22 >

:

134

Tel : 02) 361-5410, Fax : 02) 393-6884, E-mail : sookonlee@yumc.yonsei.ac.kr

Churg-Strauss

, 1951 Churg Strauss가 13

, ,

가

1).

Churg-Strauss

10%

6가

4가

2). Churg-Strauss

가

3-7)

가

21

가 Churg-Strauss

가

prednisolone cyclophosphamide

1

36.5 C,

16

125/85mmHg,

96

(1)

7mm

: , 21

:

: 7

, 2

1

가

1

4

5

가

Grade

가

가

: , 가

10.6g/dL,

30.1%,

40,000/mm³

(22.7%

7.4%

67.5%

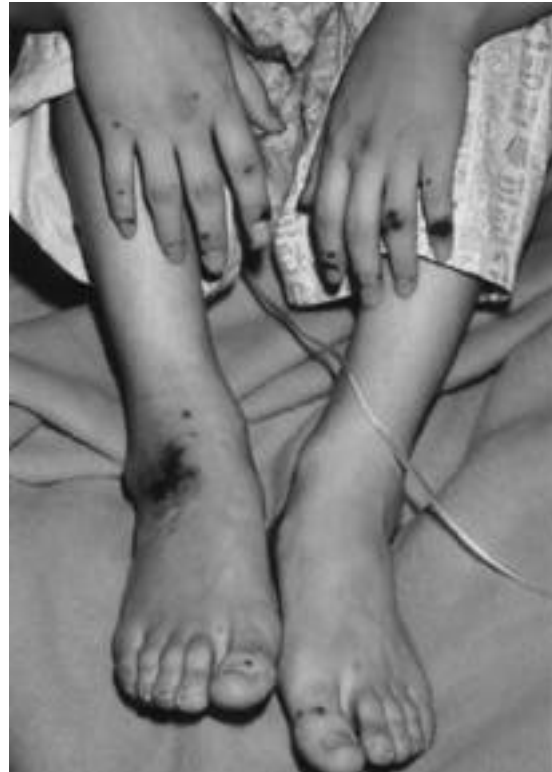

Fig. 1. Purpura on both hands and feet.

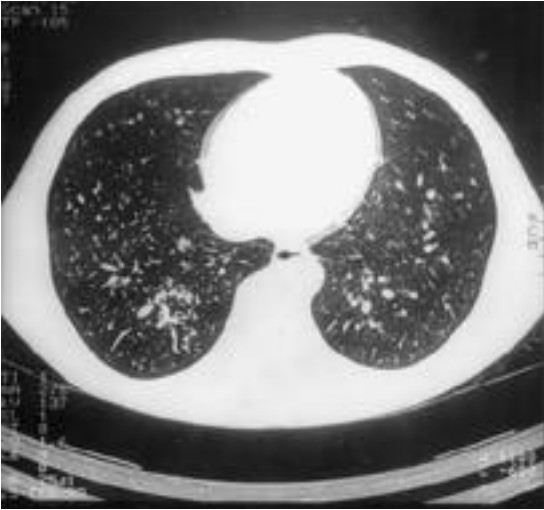

Fig. 2. Centrilobular prominence and adjacent ground glass patterns in the basal segment of both lower lobes.

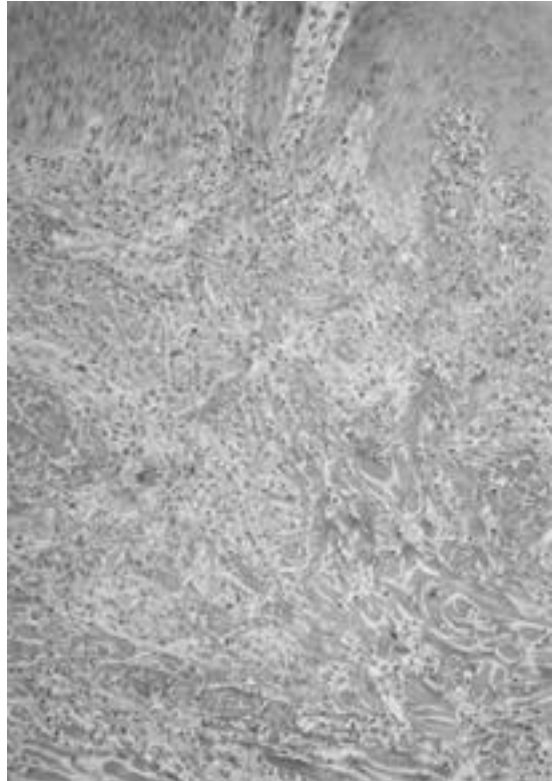


Fig. 3. Skin biopsy showing multifocal collagen degeneration associated with eosinophilic infiltrates in the superficial and deep dermis.

2.2%), 27,000/mm³, 496,000/mm³,
48mm/hour

Na 136mmol/L, K 5.7mmol/L, Cl 107mmol/L, tCO₂ 18mmol/L, BUN/Cr 53/2.3 mg/dL, 6.4g/dL 2.5g/dL, 113mg/dL, 65mg/dL, 94 mg/dL, CK 30IU/L, LDH 190IU/L

1.025, pH 5.0, 300mg/dL, many/HPF, 0/HPF 24 15,728mg/24hr,

10,722mg/24hr, 50.3ml/m/1.7 m² . C3, C4

69.9mg/dL, 28.9mg/dL IgG, IgA, IgM 990mg/dL, 268mg/dL, 136mg/dL IgG가 40.6

U/L, C 4.59mg/dL , VDRL, HBsAg, anti-HIV

myeloperoxidase 가 218.8U/mL (< 8% 5U/ml) 가 proteinase 3 chamber 가 0.5 U/mL .

(2). X

가

(collagen degeneration) (3).

myelin 20 가 12 가

53.150/m/1.7m²

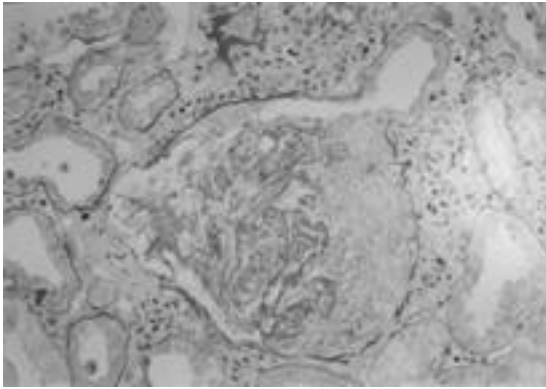


Fig. 4. The glomerulus shows a cellular crescent with collapsed and wrinkled glomerular capillary loops. The interstitium shows dense infiltration of inflammatory cells including eosinophils, plasma cells and lymphocytes (PAS, x200).

Churg-Strauss

, 1951 Churg Strauss가 13

가

¹⁾

Lanham 154
Strauss가

Churg

Churg-Strauss

(1.5x10⁹/L),

⁸⁾ Churg-Strauss

1990 American College of

Rheumatology 1)

, 2) 10%

3) , 4)

, 5) , 6)

6가 4가

85%

(27,000/mm³),

99.7% ²⁾

가,

Churg-Strauss

prednisolone 60mg/day

nisolone 3

pred-

Churg-Strauss

Churg-Strauss

nisolone 9 cyclophosphamide 100mg

/day 가 . Prednisolone cyclophosphamide 3

⁸⁾ Lanham

, Churg-Strauss

42%

7 BUN/Cr 23.3/1.5mg/dL, myeloperoxidase 가 0.5U/mL

, 122 12 (10%)

, 50 9 (18%)

22

cyclophosphamide prednisolone

/day 24 . Prednisolone 10mg

⁸⁾

Clut-

terbuck⁹⁾, Gaskin ¹⁰⁾ Churg-Strauss

3,479mg/24hr,

2,941mg/24hr,

. Clutterbuck 19 Churg-
Strauss , 13
가
가 , 12 가
3 . 14

4 prednisolone cyclophosphamide
azathioprine 3

9 2.3 9,10)
mg/dL 4
5.6mg/dL 2

Strauss Churg-
67%
myeloperoxidase 11)

myeloperoxidase 가
10,12)
myeloperoxidase 가
myeloperoxidase 가

Churg-Strauss 가
8,13,14) Guillevin
1g
(> 1.58mg/dL),
가 1
(five-factor score) 15) . 96
Churg-Strauss 0 , 1 , 2
12.5%, 34.4%, 37.5%
14) 가
가 .

가
9,10)
Gaskin 14
Churg-Strauss 11 (78%)

Churg-Strauss
Churg-Strauss
8,9,11)
Churg-Strauss 가,
Churg-Strauss
Churg-Strauss
15gm/24hr
8
pred- 1 prednisolone cyclophosphamide

1 10)
Churg-Strauss
가 pred-
nisolone
2.3mg/dL
가 9,10)
nisolone 가 가
(cyclophosphamide, azathioprine)

buck prednisolone
11 4
cyclophosphamide azathio
prine 3

REFERENCES

1) Churg J, Strauss L. Allergic granulomatosis, allergic angiitis and periarteritis nodosa. Am

- J Pathol 1951;27:277-301
- 2) Masi AT, Hunder GG, Lie JT, Michel BA, Bloch DA, Arend WP et al. The American college of rheumatology 1990 criteria for the classification of Churg-Strauss syndrome (Allergic granulomatosis and angiitis). *Arthritis Rheum* 1990;33:1094-1100
 - 3) . Churg-Strauss 1 . 1989;7:377-82
 - 4) . (Churg-Strauss Syndrome) 1 . 1993;45:369-75
 - 5) . 1 . 1995;15:658-64
 - 6) . Churg-Strauss 1 . 1996;3:97-101
 - 7) . 1 . 1998;5:298-303
 - 8) Lanham JG, Elkon KB, Pusey CD, Hughes GR. Systemic vasculitis with asthma and eosinophilia: a clinical approach to the Churg-Strauss syndrome. *Medicine* 1984;63:65-81
 - 9) Clutterbuck EJ, Evans DJ, Pusey CD. Renal involvement in Churg-Strauss Syndrome. *Nephrol Dial Transplant* 1990;5:161-7
 - 10) Gaskin G, Clutterbuck EJ, Pusey CD. Renal disease in the Churg-Strauss Syndrome. *Contrib Nephrol* 1991;94:58-65
 - 11) Guillevin L, Visser H, Noel LH, Pourrat J, Vernier I, Gayraud M. Antineutrophil cytoplasm antibodies in systemic polyarteritis nodosa with and without hepatitis B virus infection and Churg-Strauss syndrome-62 patients. *J Rheumatol* 1993;20:1345-9
 - 12) Minami J, Ueda HI, Okano Y, Inenaga T, Nakanishi N, Kunieda T. Crescentic glomerulonephritis and elevated antimyeloperoxidase antibody in a patient with Churg-Strauss syndrome. *Nephron* 1997;77:105-8
 - 13) Chumbley LC, Harrison EG, Deremee RA. Allergic granulomatosis and angiitis (Churg-Strauss Syndrome). Report and analysis of 30 cases. *Mayo Clin Proc* 1977;52:477-84
 - 14) Guillevin L, Cohen P, Gayraud M, Lhote F, Jarrousse B, Casassus P. Churg-Strauss syndrome. Clinical study and long-term follow-up of 96 patients. *Medicine* 1999;78:26-37
 - 15) Guillevin L, Lhote F, Gayraud M, Cohen P, Jarrousse B, Lortholary O, et al. Prognostic factors in polyarteritis nodosa and Churg-Strauss syndrome. A prospective study in 342 patients. *Medicine* 1996;75:17-28