

*

*

*

Abstract

Systemic Lupus Erythematosus and Thymoma
- A Case Report -

Moo Suk Park, M.D., Min Chan Park, M.D., Jungsik Song, M.D.,
Yong Beom Park, M.D., Soo Kon Lee, M.D.,
Se Hoon Kim, M.D.*, Woo Ick Yang, M.D.*

Department of Internal Medicine, Yonsei University College of Medicine, Seoul, Korea
*Department of Pathology, Yonsei University College of Medicine, Seoul, Korea**

Systemic lupus erythematosus (SLE) is an autoimmune disease with a loss of the control over B lymphocytes which is normally exerted by T-suppressor cell. The thymus play a central role in regulating and controlling immune reaction through its effects on T cell differentiation of both T helper and T suppressor cells. Tumors of the thymus are rare but have been reported in concurrence with a variety of autoimmune diseases, including most frequently myasthenia gravis and rarely SLE and other disorders. The association of thymoma and SLE is very rare, fewer than 10 case reports in the world literature. The woman had been thymectomized because of incidental thymoma. After two years, she was diagnosed as SLE with features of arthritis, leukopenia, high titer of ANA, positivity of anti-dsDNA and hypocomplementemia. We report here one case of concurrent SLE and thymoma.

Key Words : Systemic lupus erythematosus, Thymoma, Thymectomy

< : 2000 5 6 , : 2000 8 10 >

:

134

Tel : 02) 361-5430 Fax : 02) 393-6884

: 1973 18
1978 1
가

(systemic lupus erythematosus, SLE) : 110/70mmHg,
70 /min, 20 /min, 36.5

가 가 가

B- T-

^{1,2)}

T- 가

, Sjögren : (1997 8 6)

³⁾

11.2mg%,
34.3%, 3,040/mm³(44.2%,
38%), 191,000/mm³

11.0mg%,

32.1%, 3,370/mm³(55.2%,
33.2%), 192,000/mm³

10 가

²⁻⁹⁾

(ESR) 24mm/ hr

CRP, ASO, VDRL,

1:640 , homogeneous

type dsDNA 120U/ml

C3, C4 39.4mg/dl (

45~86), 8.04mg/dl(11~47)

-Ro , -La , -RNP

-Sm

: 42

: 2

6×5cm

: 97 7

6×5cm

(1).

6 () 99 8

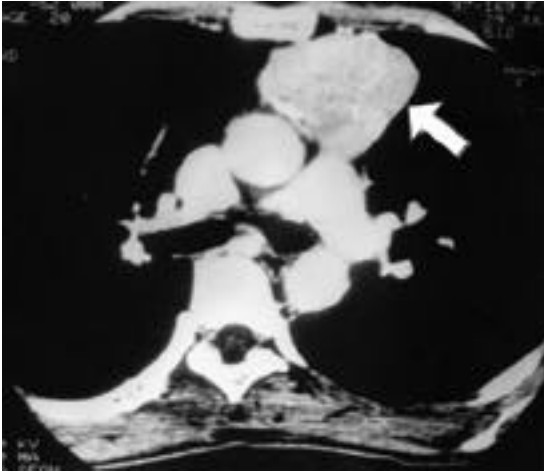


Fig. 1. The CT scan shows about 6×5cm sized solid mass which contains curvilinear multiple calcification in anterior mediastinum and no evidence of aortic or pulmonary artery invasion.




Fig. 2. The specimen consists of a well-circumscribed with a thin fibrous capsule, measuring 3×3cm from the anterior mediastinum. On resection, it reveals to be a multilobulated mass composed of homogeneous gray-white, solid tissue divided by multiple intersecting fibrotic septae.

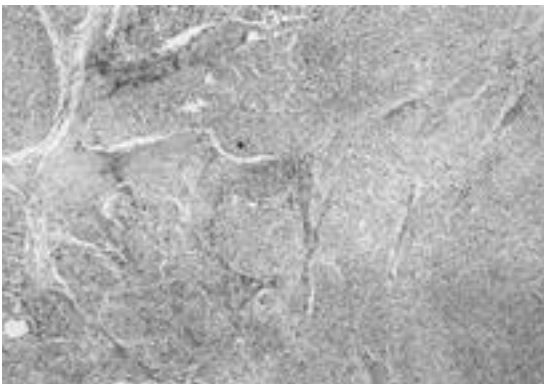


Fig. 3. The thymoma is composite type (mixed type) and focally involving capsule, and attached normal thymus shows follicular hyperplasia. Lymphocytes in cortical differentiated area are intermixed with medullary epithelial cells having spindle shape (H&E ×400).

(3) : (mixed type)

dsDNA
NSAID

1999 12

4,10)

5

10)

(2) :

가

3×3cm

2-9),

10

가

REFERENCES

- 1) Fauci AS, Steinberg AD, Haynes BF. Immunoregulatory aberration in systemic lupus erythematosus. *J Immunol* 1978;121:1473-9.
- 2) Masci AM, Palmieri G, Perna F, et al. Immunological findings in thymoma and thymoma-related syndromes. *Ann Med* 1999;31:86-9.
- 3) Loehrer PJ. Thymomas: Current experience and future directions in therapy. *Drug* 1993; 45:477-87.
- 4) Menon S, Snaith ML, Isenberg DA. The association of malignancy with SLE: an analysis of 150 patients under long-term review. *Lupus* 1993;2:177-81.
- 5) Zandman-Goddard G, Lorber M, Shoenfeld Y. Systemic lupus erythematosus and thymoma-a double-edged sword. *Int Arch Allergy Immunol* 1995;108:99-102.
- 6) Steven MM, Westedt ML, Eulderink F, et al. Systemic lupus erythematosus and invasive thymoma: reports of two cases. *Ann Rheum Dis* 1984;43:825-8.
- 7) Simeone JF, McCloud T, Putman CE, et al. Thymoma and systemic lupus erythematosus. *Thorax* 1975;30:697-700.
- 8) Calabrese LH, Bach JF, Currie T, et al. Development of systemic lupus erythematosus after thymectomy for myasthenia gravis. *Studies of suppressor cell function. Arch Intern Med* 1981;141:253-5.
- 9) Ogawa M, Ueda S, Ohto M, et al. Development of systemic lupus erythematosus after total resection of a thymoma and the adjacent thymic gland. *J Rheumatol* 1992;19:1130-2.
- 10) Abu-Shakra M, Gladman DD, Urowitz MB. Malignancy in systemic lupus erythematosus. *Arthritis Rheum* 1996;39:1050-4.
- 11) Winfield JB, Mimura T. Pathogenetic significance of anti-lymphocyte autoantibodies in systemic lupus erythematosus. *Clin Immunol Immunopathol* 1992;63:13-6.
- 12) Steinberg AD, Law LD, Yalal N. The role of NZB/NZW F1 thymus in experimental tolerance and autoimmunity. *Arthritis Rheum* 1970;13:369-77.
- 13) Shoenfeld Y, Isenberg DA. The mosaic of

autoimmunity. *Immunol Today* 1989;10:123-6.

14) Wara DW. Thymic hormones and the immune system. *Adv Pediatr* 1981;28:229-70.

15) Decker JL, Steinberg AD, Reindertsen JL, et

al. NIH conference. systemic lupus erythematosus: evolving concepts. *Ann Intern Med* 1979;91:587-604.